

Are your **MRI contrast agents** cost-effective?

Learn more about generic **Gadolinium-Based Contrast Agents**.



FRESENIUS
KABI

caring for life

AJNR

Endovascular treatment of cerebral arteriovenous malformations following radiosurgery.

M P Marks, B Lane, G K Steinberg, J I Fabrikant, R P Levy, K A Frankel and M H Phillips

AJNR Am J Neuroradiol 1993, 14 (2) 297-303

<http://www.ajnr.org/content/14/2/297>

This information is current as of April 20, 2024.

Endovascular Treatment of Cerebral Arteriovenous Malformations following Radiosurgery

Michael P. Marks,^{1,4} Barton Lane,¹ Gary K. Steinberg,² Jacob I. Fabrikant,³ Richard P. Levy,³ Kenneth A. Frankel,³ and Mark H. Phillips³

PURPOSE: Previous reports of embolization of cerebral arteriovenous malformations (AVMs) have evaluated the technique as an adjunctive therapy prior to surgery or radiosurgery; our aim is to assess the role of embolization following radiosurgery. **PATIENTS:** Six patients previously treated with radiosurgery and showing no response as judged by cerebral angiography were embolized 24 to 55 months (mean 34.3 months) after initial radiosurgery. **RESULTS:** In five of six, a significant volume reduction was achieved ranging from 60%–100% (mean 74%). One patient was treated with embolization alone and the AVM has remained fully thrombosed 2 years after treatment. Three patients underwent surgical resection for cure after embolization, and two patients had repeat radiosurgery to a significantly smaller AVM volume. One patient had an asymptomatic carotid dissection at embolization; however, no clinically apparent complications occurred in the treatment group. **CONCLUSION:** Embolization can be used after radiosurgery to assist in the management of those AVMs that have not responded to initial treatment.

Index terms: Arteriovenous malformations, cerebral; Arteriovenous malformations, embolization; Interventional neuroradiology

AJNR 14:297–303, Mar/Apr 1993

Embolization of brain arteriovenous malformations (AVMs) is an important therapeutic tool for the treatment of these congenital lesions (1–6). Staged embolization coupled with surgical excision has been of benefit in the management of AVMs, particularly those that are larger and more prone to breakthrough bleeding (3, 6, 7). Recently, patients with lesions generally not amenable to surgical therapy have undergone treatment with helium-ion radiosurgery and other forms of focused brain irradiation (8–11). There is a high obliteration rate with radiosurgery for smaller lesions (less than 2 cm in diameter), reaching approximately 90% obliteration at 2 years (8, 9). Larger lesions, however, have a lower

rate of obliteration and may benefit from size reduction prior to radiosurgery. Embolization prior to radiosurgery has been used for this purpose (12).

To our knowledge, there have been no reports thus far describing embolization and/or surgery of AVMs previously treated with radiosurgery or the management of AVMs not cured with initial radiosurgical treatment. We report six cases of AVMs previously treated with radiosurgery that did not significantly reduce in size after long-term follow-up and were then treated with embolization followed by surgery or additional radiosurgery.

Patients and Methods

Table 1 shows the clinical histories at the time of initial radiosurgery and AVM locations of the six patients treated in this study. Five of six patients had a history of hemorrhage. Three patients were treated prior to the initial radiosurgery at outside institutions. Patient 1 had attempted intraoperative embolization, patient 2 a percutaneous embolization, and patient 5 had surgery at the time of prior hemorrhage. None of these patients had a significant change in size of the AVM with treatment. All of the patients in this series were then referred from other institutions, where they were judged not to be candidates for further

Received January 7, 1992; accepted and revision requested March 18, revision received April 13.

Departments of ¹Diagnostic Radiology, and ²Neurosurgery, Stanford University School of Medicine, Stanford, CA.

³ Donner Pavilion and Donner Laboratory, Lawrence Berkeley Laboratory, University of California, Berkeley, CA.

⁴ Address reprint requests to Michael P. Marks, MD, Department of Radiology, Stanford University Hospital, Stanford, CA 94305–5105.

AJNR 14:297–303, Mar/Apr 1993 0195-6108/93/1402–0297

© American Society of Neuroradiology

TABLE 1: Clinical history and radiosurgical treatment

Patient	Age/Sex	AVM Location	AVM Diameter	Presenting Symptoms	Radiosurgery	Dose/Volume
1	28/M	Left parietal	5.0 ^a	SZ, HA, memory loss	H	18/35,000 ^b
2	20/M	Brain stem	2.0	SAH, diplopia	H	20/19,000
3	15/M	Left temporal	3.0	PH, SZ	H	35/9,000
4	36/F	Left parietal	5.0	PH×3, SZ, HA	H	25/24,000
5	32/F	Right frontal	4.5	SAH×2, SZ	H	20/14,700
6	31/F	Brain stem	3.0	SAH×2, HA	L	46/30,000

Note.—Abbreviations: H, helium-ion; L, Linac; SZ, seizure; SAH, subarachnoid hemorrhage; HA, headache; PH, parenchymal hemorrhage.

^a Diameter in cm.

^b Dose in GyE; volume indicates treatment volume in mm³.

TABLE 2: Postradiosurgery symptoms and treatment

Patient	New Symptoms (following Radiosurgery)	Embolization (months postradiosurgery)	Embolic Material	Estimated % Obliteration	Complications
1	None	34	C	60	None
2	None	36	PVA	70	None
3	None	24	PVA, S, HC	100	None
4	None	55	PVA	0	ICA dissection
5	Memory loss	27	C	70	None
6	SAH×2	30	PVA, S, HC	70	None

Note.—Abbreviations: C, cyanoacrylate; PVA, polyvinyl alcohol; S, silk; HC, hilal coils; SAH, subarachnoid hemorrhage; ICA, internal carotid artery.

embolization and surgery. Five of the patients underwent helium-ion radiotherapy with the doses indicated using previously described methods (13). One of the patients was treated with conventional Linac radiotherapy. Patients were evaluated with magnetic resonance (MR) imaging approximately every 6 months after radiosurgery, and conventional angiography was performed on an annual basis. Follow-up angiography showed no interval change in the size or configuration of the AVM nidus in any of the patients treated.

In four cases, a steerable guide wire catheter was used (Tracker catheter, Target Therapeutics, Los Angeles, CA) to perform superselective embolization. In the other two cases, a flow-directed microcatheter was used (Magic Catheter, Balt, Montmorency, France). Superselective injections of amobarbital (25–30 mg) were administered to all patients prior to embolization. In the two cases with brain stem AVMs, there was additional monitoring with brain stem auditory-evoked potentials and somatosensory-evoked potentials. Four patients were treated with polyvinyl alcohol particles (PVA). Occlusion of feeding vessels was achieved via surgical silk and platinum coil (Hilal coils, Cook, Bloomington, IN) in 2 of these patients. The progress of the embolization procedure was monitored via measurement of pressure change within the feeding pedicle in the four patients treated with PVA particles. This technique may improve the evaluation of hemodynamic changes during embolization, when compared with fluoroscopic or angiographic evaluation (14). Those patients selectively catheterized with the flow-directed catheter system were treated

with isobutyl-2 cyanoacrylate (Avacryl, Tri-point Medical, Raleigh, NC) mixed with tantalum powder and Pantopaque (iopendylate).

Control angiography was performed after embolization to compare with pretreatment size. One patient was treated with embolization alone. In two patients treatment with helium-ion radiosurgery was repeated after embolization. In three cases, the residual AVM was surgically resected after AVM embolization; control angiography was then performed after surgical resection.

Results

In all patients, the angiograms prior to embolization showed no significant change in the size, feeding pedicles, drainage or angio-architecture of the AVM when compared with the preradiosurgery angiogram. Prior to embolization, AVMs ranged in size from 2.0–5.0 cm in diameter (mean 3.4 cm). Follow-up MR did not show a diminution in AVM size or evidence of white matter injury attributable to radiosurgery (8, 15).

Table 2 shows new symptoms and timing of postradiosurgery embolization. Embolization was performed 24 to 55 months (mean 34.3 months) after initial radiosurgery. Five of six patients had staged procedures, with two embolization sessions each. Control angiography performed after

the final embolization procedure was used to estimate the degree of volume reduction in all patients. In five of six patients, a significant volume reduction was achieved ranging from 60%–100% (mean 74%). In one patient, no volume reduction was achieved.

In two patients treated with PVA particles, the pressure did not change with infusion of one bottle of 200 to 300-micron PVA particles, followed by one bottle of 300 to 500-micron PVA particles. Silk cut from 4.0 suture into pieces 2 cm in length was then injected; after this, 500 to 700-micron PVA was used in one patient and 700 to 1000-micron PVA was used in the other patient. During this infusion of larger PVA particles in these two patients, the pressure in the feeding vessel rose and visible slowing of flow was seen in portions of the AVM. One of the patients demonstrated a larger direct arteriovenous fistula after the cloud of the nidus had been partially embolized; this was treated with platinum coils. This patient (case 3) had complete obliteration of the AVM during the embolization, obviating the need for an additional staged procedure (Fig. 1).

The other two patients treated with PVA showed a pressure rise and visible slowing of flow with smaller (150 to 200-micron) particle sizes. One patient (case 4) with dural and pial supply to the AVM had only the external carotid artery supply embolized with PVA; slowing of flow with a pressure rise was observed with small PVA particles. Patient 2, with a brain stem AVM, had small feeding arteries embolized, with significant slowing of flow observed after only small amounts of 150 to 200-micron PVA.

None of the embolization procedures resulted in a clinical or symptomatic clinical complication. One patient (case 4) underwent successful embolization of external carotid artery feeders to the AVM. During the second embolization session, an intimal dissection occurred in the cervical internal carotid artery during placement of the guiding catheter; the embolization procedure was aborted. The patient remained asymptomatic and subsequently underwent surgical resection for a complete cure.

Three patients had surgical resection of AVMs following embolization. Two patients had single staged resection (cases 1 and 5) and the patient where pial supply could not be embolized (case 4) had a two-stage resection. Surgery was performed with minimal blood loss. In all cases, the AVM vessels were easier to manipulate and cauterize than AVMs not previously treated with

radiosurgery. Control angiography was performed after surgery in these cases; no residual AVM was seen (Fig. 2).

Two patients with brain stem AVMs were not judged to be surgical candidates after embolization (Fig. 3). These patients were radiated with additional doses of 15 GyE (case 6) and 17.5 GyE (case 2) to the residual AVM volume. One patient (case 6) is 18 months posttreatment with repeat radiosurgery, and had no change in AVM size or evidence of recanalization at 12 months. The other patient is less than 1 year postradiosurgery and is awaiting angiographic follow-up. The final patient in this series (case 3) was treated with embolization alone. This patient, treated with PVA, silk, and platinum coils, has not shown any recanalization on follow-up angiography at 2 years posttreatment.

Discussion

AVMs have been treated with different types of ionizing radiation including x-rays, gamma-rays, and Bragg-peak therapy (8–11). The common goal of all of these forms of radiation therapy is to induce an inflammatory response in the vessels of the AVM, which result in thickening of the vessel wall and ultimately in thrombosis of the AVM. All of the radiotherapy modalities used in the treatment of AVMs have had some lesions with partial obliteration or lesions that have been unchanged following radiosurgery after long-term follow-up (8–11). Hemorrhage has not been observed in any patient once angiography had confirmed complete AVM obliteration; however, hemorrhage has been reported even after a 95% reduction in size following radiosurgery (9). Therefore, the goal of therapy must be complete obliteration of the AVM nidus.

Obliteration rate is dependent on initial AVM size, with smaller AVMs showing a better rate of obliteration (8, 9). Generally the 12-month follow-up angiogram shows a diminution in size and, often, obliteration (8). The 24- and 36-month follow-up shows progression of this process, but significant obliteration has not been observed beyond the 36-month angiogram (8, 9). Finally, thrombosis has not been observed to begin after 24 months. Therefore, if there has been no change in AVM architecture at 24 months, or if obliteration has not been observed at 36 months, alternative or additional therapy is recommended.

The patients described in this study showed no definite change in the size of the AVM nidus after

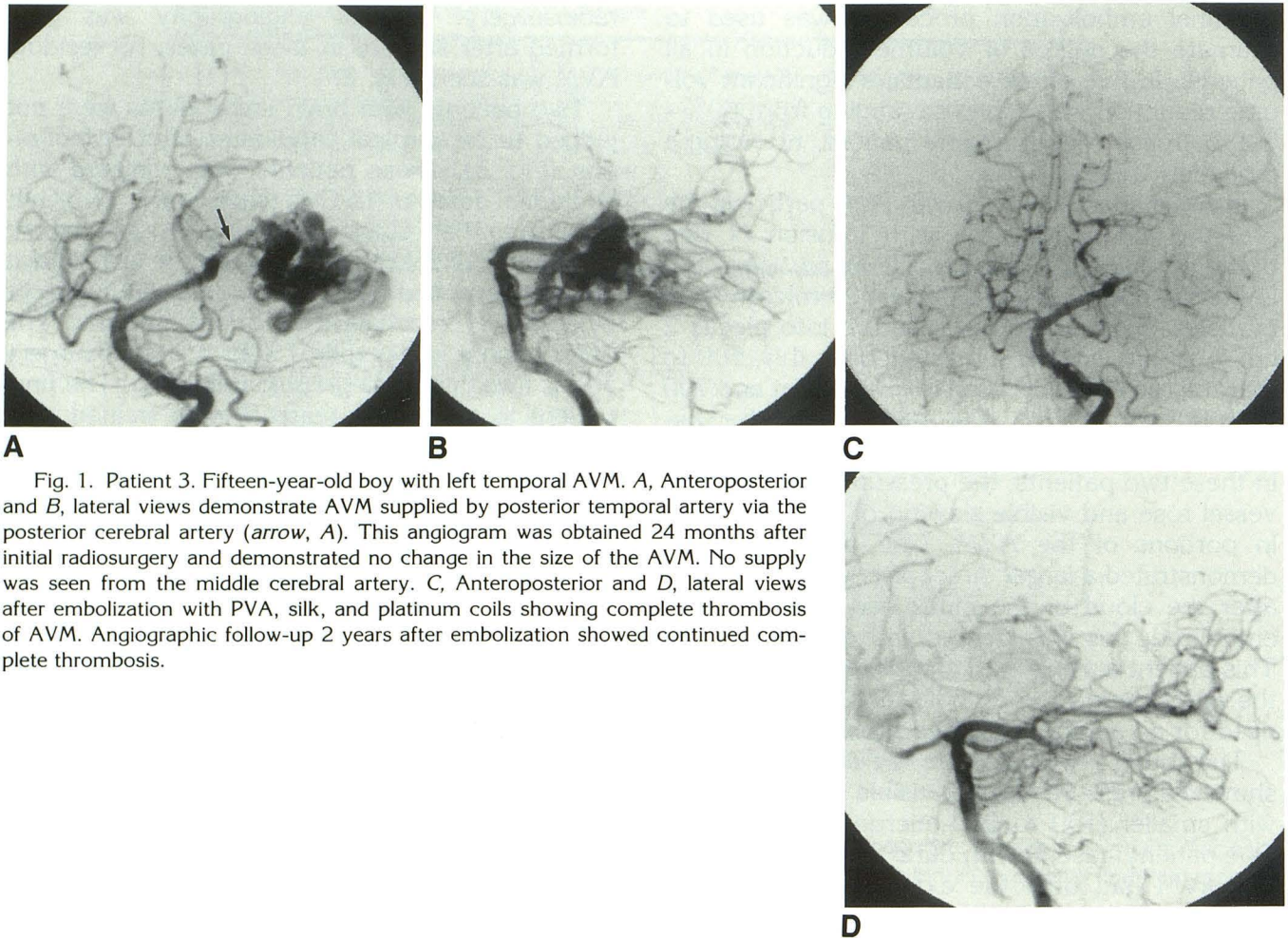


Fig. 1. Patient 3. Fifteen-year-old boy with left temporal AVM. A, Anteroposterior and B, lateral views demonstrate AVM supplied by posterior temporal artery via the posterior cerebral artery (*arrow*, A). This angiogram was obtained 24 months after initial radiosurgery and demonstrated no change in the size of the AVM. No supply was seen from the middle cerebral artery. C, Anteroposterior and D, lateral views after embolization with PVA, silk, and platinum coils showing complete thrombosis of AVM. Angiographic follow-up 2 years after embolization showed continued complete thrombosis.

radiosurgery. There was also no appreciable difference in the filling and emptying of the AVM nidus on angiograms obtained pre- and posttreatment with radiosurgery. In two of the three cases in which PVA was used to embolize pial supply to the AVM nidus (cases 3 and 6), smaller PVA particles appeared to have no significant effect on flow or measured pressure to the AVM nidus, despite using large amounts of PVA. Embolization was achieved only using larger size material capable of closing larger arteriovenous shunts, namely silk and coils. This suggests that the AVM nidus was made up of these larger shunts, and it is possible that those AVMs that are not responsive to radiosurgery may have niduses that have larger vascular channels or shunts. The AVMs in this series that underwent surgery were observed to be easier to manipulate and cauterize than AVMs not treated with radiosurgery. This may suggest there was some thickening of the vessel wall in response to radiosurgery. Despite vascular intimal injury and endothelial proliferation after

radiosurgery, the vascular channels have not undergone wall thickening significant enough to slow flow and promote eventual thrombosis.

Partial embolization of the nidus prior to surgery is of benefit because it reduces perioperative hemorrhage and operative time, and may thrombose those portions of the AVM that are more difficult to access surgically (1–6). While the prior radiosurgery appeared to make manipulation of the AVM easier, the risks from surgical excision are still present. In two cases, embolization achieved sufficient size reduction to allow the AVM to be removed in a single procedure without complication. In the case that did not have pial supply embolization, and a significant size reduction was not achieved, a two-stage resection was required to achieve complete resection.

In those patients who undergo repeat treatment with radiosurgery, there is a benefit in reducing AVM nidus size with embolization prior to repeat treatment. The risks of incremental focal irradiation are not well established. However, delayed

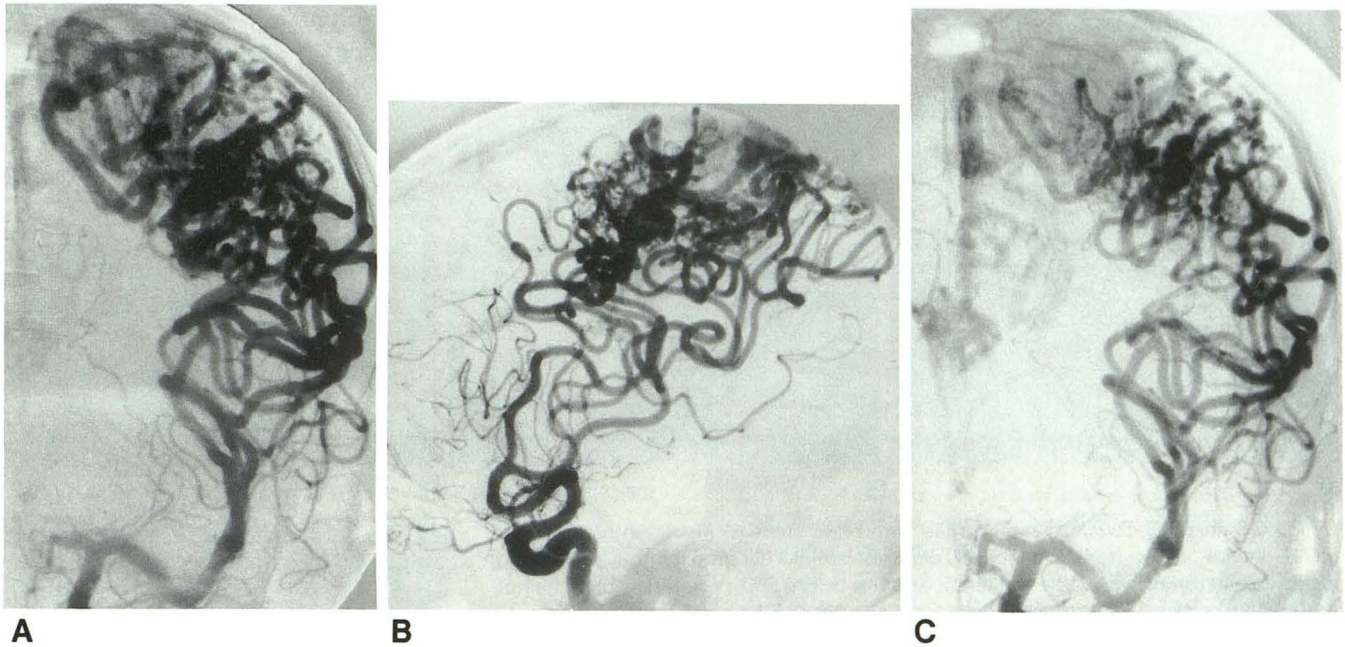


Fig. 2. Patient 1. Twenty-eight-year-old man with large left parietal AVM. A, Anteroposterior and B, lateral views demonstrate AVM supply via middle cerebral artery opercular arteries with faint filling of the anterior cerebral artery in the anterior view that also fed the AVM. This angiogram was performed 34 months after radiosurgery and showed no change in the size of the AVM. C, Anteroposterior and D, lateral after embolization.

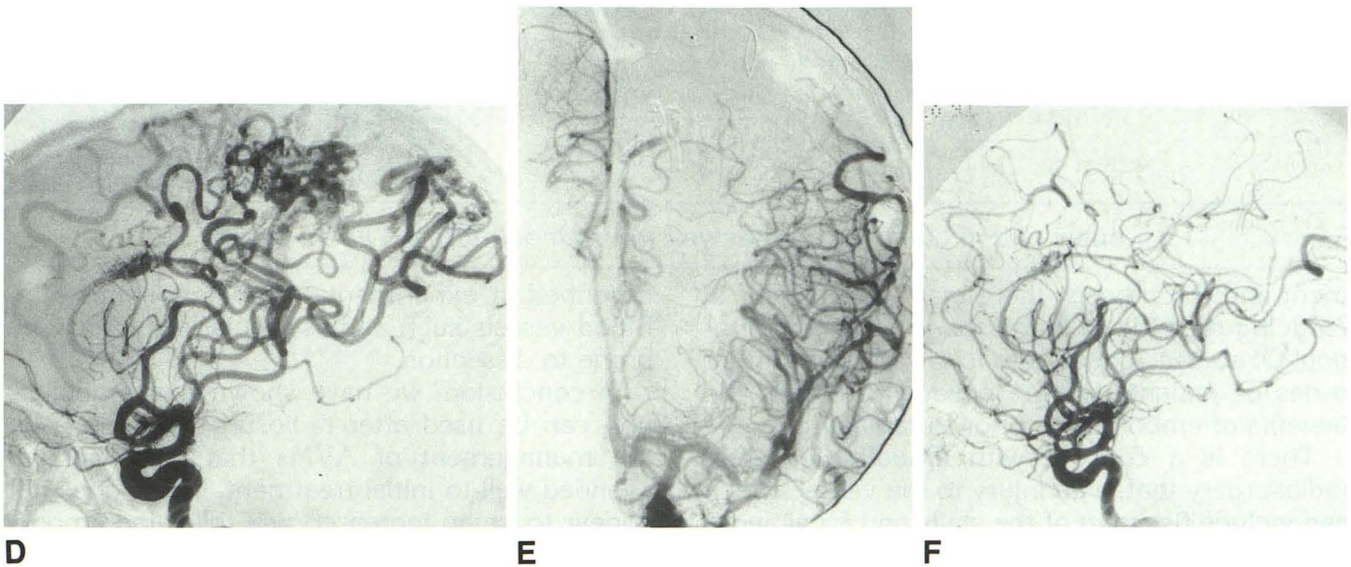


Fig. 2. —Continued. Lateral view (D) best shows postembolization change with reduction in nidus size and occlusion of several opercular branches. E, Anteroposterior and F, lateral views following surgical resection demonstrates complete excision of the AVM without evidence of early venous drainage. Note improved filling of the anterior cerebral artery after embolization (C and D), and after surgical resection (E and F) due to incremental decreases in flow through the AVM nidus with embolization and surgery.

adverse reactions appear to be dose-volume related (9), therefore embolization may be particularly helpful if the new target volume can be substantially reduced. This limits the cumulative radiation dose to adjacent normal tissues in the case in which previous radiation has been administered, if that embolization causes even a small volume reduction. In addition, analysis of risk

factors for hemorrhage has demonstrated an increased risk of hemorrhage when certain angiographic features are present, such as intranidus aneurysms (16). Embolization has been shown to be an effective method for thrombosis of these aneurysms, and may reduce the risk of subsequent hemorrhage in the AVM (17). Because radiosurgery has a longer latency between treat-

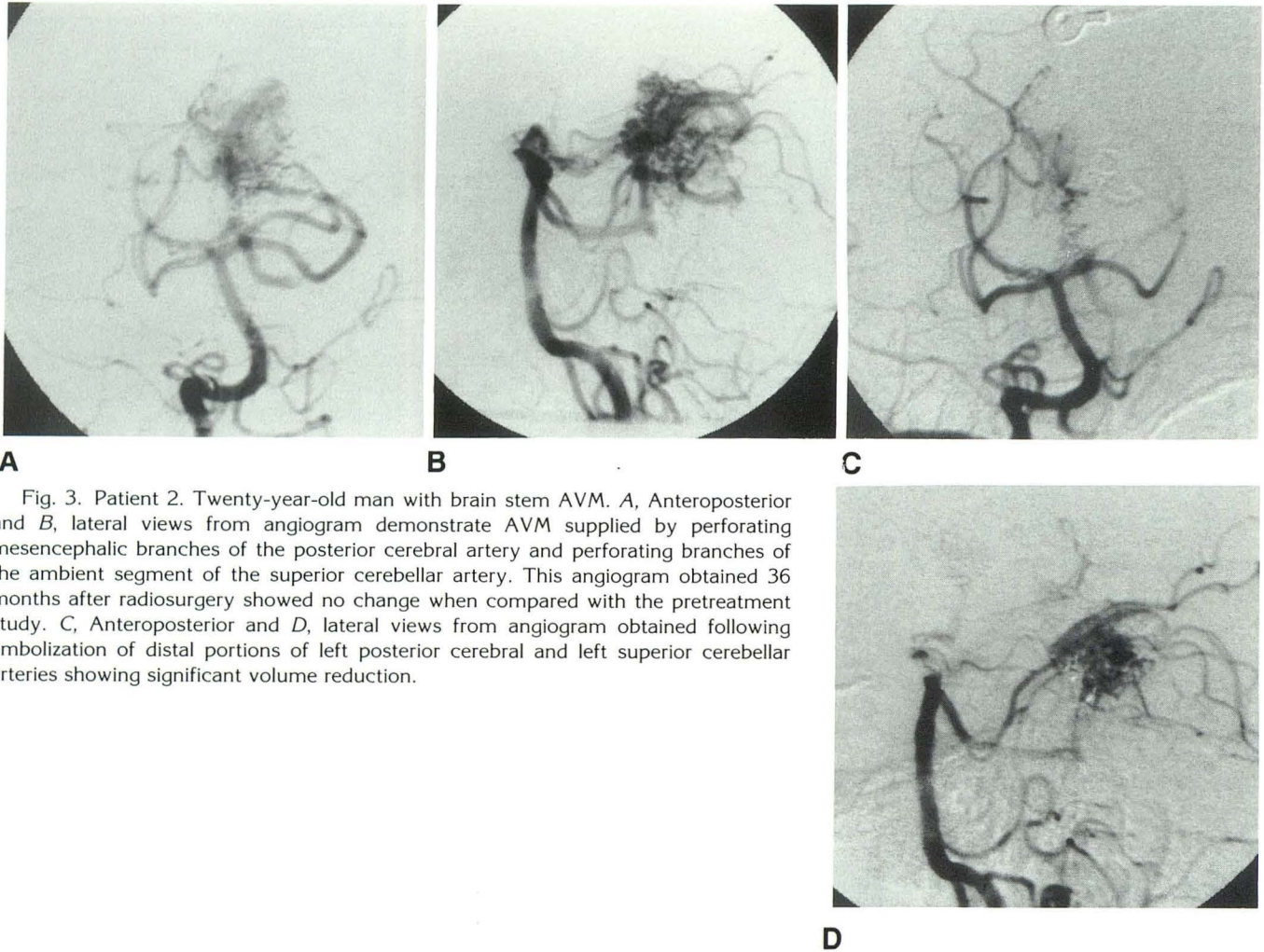


Fig. 3. Patient 2. Twenty-year-old man with brain stem AVM. *A*, Anteroposterior and *B*, lateral views from angiogram demonstrate AVM supplied by perforating mesencephalic branches of the posterior cerebral artery and perforating branches of the ambient segment of the superior cerebellar artery. This angiogram obtained 36 months after radiosurgery showed no change when compared with the pretreatment study. *C*, Anteroposterior and *D*, lateral views from angiogram obtained following embolization of distal portions of left posterior cerebral and left superior cerebellar arteries showing significant volume reduction.

ment and thrombosis, there may be a benefit in reducing the risk of hemorrhage with embolization. Of course, longer term follow-up and a larger series of patients will be needed to assess the benefits of embolization prior to radiosurgery.

There is a concern with embolization after radiosurgery that, with injury to the vessel, which can include fissuring of the walls and focal endothelial necrosis (18), there would be an increased risk of dissection during embolization. The asymptomatic focal carotid-artery dissection observed in this series was well outside of the region that received a significant radiation dose (19). On the other hand, vascular dissections have occurred during embolization in patients with cerebral AVMs who have not had prior radiosurgery. Furthermore, stenosis and occlusion of feeding vessels have been described previously with AVMs (20, 21) and histologic changes, which include a damaged intima, frayed elastic membrane, and medial muscle necrosis, have been

described in experimental high-flow states (22). Blood vessels such as this would likely be more prone to dissection.

In conclusion, we have shown that embolization can be used after radiosurgery to assist in the management of AVMs that have not responded well to initial treatment. There does not appear to be an increased risk following embolization in those patients previously treated with radiosurgery, although a larger series of patients will be needed to confirm this impression. Those AVMs that underwent surgical treatment benefited from staged embolization before operative excision, and embolization completely thrombosed one AVM. Significant size reduction was achieved in the two brain stem AVMs not amenable to surgical management. A benefit should be realized from reduction of the target volume prior to retreatment with radiation, but longer term follow-up will be needed to assess the results of radiosurgical treatment.

References

1. Pelz DM, Fox AJ, Vinuela F, Drake CC, Gerguson GG. Preoperative embolization of brain AVMs with isobutyl-2-cyanoacrylate. *AJNR* 1988;9:757-764
2. Vinuela F. Endovascular therapy of brain arteriovenous malformations. *Semin Interventional Radiol* 1987;4:269-280
3. Adelt D, Bruckmann H, Krenkel W, Hacke W, Zeumer H. Combined neuroradiological and neurosurgical treatment of intracerebral arteriovenous malformations. *J Neurol* 1988;235:355-358
4. Schumacher M, Horton JA. Treatment of cerebral arteriovenous malformations with PVA: results and analysis of complications. *Neuroradiology* 1991;33:101-105
5. Berthelsen B, Lofgren J, Svendsen P. Embolization of cerebral arteriovenous malformations with bucrylate. *Acta Radiol* 1990;31:13-21
6. Fox AJ, Pelz DM, Lee DH. Arteriovenous malformations of the brain: recent results of endovascular therapy. *Radiology* 1990;177:51-57
7. Spetzler RF, Martin NA, Carter P, et al. Surgical management of large AVM's by staged embolization and operative excision. *J Neurosurg* 1987;67:17-28
8. Marks MP, DeLaPaz RL, Fabrikant JI, et al. Intracranial vascular malformations: imaging of charged particle radiosurgery. I. Results of therapy. *Radiology* 1988;168:447-455
9. Steinberg GK, Fabrikant JI, Marks MP, et al. Stereotactic heavy-charged-particle Bragg-peak radiation for intracranial arteriovenous malformations. *N Engl J Med* 1990;323:96-101
10. Steiner L. Treatment of arteriovenous malformations by radiosurgery. In: Wilson CB, Stein BM, eds. *Intracranial arteriovenous malformations*. Baltimore: Williams & Wilkins, 1984:295-313
11. Betti OO, Munari C, Rosler R. Stereotactic radiosurgery with the linear accelerator: treatment of arteriovenous malformations. *Neurosurgery* 1989;24:311-321
12. Dawson RC, Tarr RW, Hecht ST, et al. Treatment of arteriovenous malformations of the brain with combined embolization and stereotactic radiosurgery: results after 1 and 2 years. *AJNR* 1990;11:857-864
13. Fabrikant JI, Lyman JT, Frankel KA. Heavy charged-particle Bragg peak radiosurgery for intracranial vascular disorders. *Radiat Res* 1985;104:S-244-S-258
14. Jungreis CA, Horton JA. Pressure changes in the arterial feeder to a cerebral AVM as a guide to monitoring therapeutic embolization. *AJNR* 1989;10:1057-1060
15. Marks MP, DeLaPaz RL, Fabrikant JI, et al. Intracranial vascular malformations: imaging of charged particle radiosurgery. II. Complications. *Radiology* 1988;168:457-462
16. Marks MP, Lane B, Steinberg GK, Chang PJ. Hemorrhage in intracerebral arteriovenous malformations: angiographic determinants. *Radiology* 1990;176:807-813
17. Marks MP, Lane B, Steinberg GK. Intranidus aneurysms in cerebral arteriovenous malformations: evaluation and endovascular treatment. *Radiology* 1992;183:355-360
18. Steiner L. Radiosurgery in cerebral arteriovenous malformations. In: Fein JM, Flamm ES, eds. *Cerebrovascular surgery*. New York: Springer-Verlag, 1985:1161-1215
19. Fabrikant JI, Levy RP, Steinberg GK, et al. Charged-particle radiosurgery for intracranial vascular malformations. *Neurosurg Clin Am* (in press)
20. Mawad ME, Hilal SK, Michelsen WJ, Stein B, Ganti SR. Occlusive vascular disease associated with cerebral arteriovenous malformations. *Neuroradiology* 1984;153:401-408
21. Marks MP, Lane B, Steinberg GK, Chang P. Vascular characteristics of intracerebral arteriovenous malformations in patients with clinical steal. *AJNR* 1991;12:489-496
22. Pile-Spellman JMD, Baker KF, Liszczak TM, et al. High-flow angiopathy: cerebral blood vessel changes in experimental chronic arteriovenous fistula. *AJNR* 1986;7:811-815

Please see the Commentary by Dawson on page 304 in this issue.