

Are your **MRI contrast agents** cost-effective?

Learn more about generic **Gadolinium-Based Contrast Agents**.



FRESENIUS  
KABI

caring for life

**AJNR**

**Treatment of a spontaneous carotid cavernous fistula using an electrodetachable microcoil.**

A Sadato, W Taki, S Nishi, K Yamashita, H Kikuchi and Y Ikada

*AJNR Am J Neuroradiol* 1993, 14 (2) 334-336

<http://www.ajnr.org/content/14/2/334>

This information is current as  
of April 17, 2024.

# Treatment of a Spontaneous Carotid Cavernous Fistula Using an Electrodetachable Microcoil

Akiyo Sadato,<sup>1,3</sup> Waro Taki,<sup>1</sup> Shogo Nishi,<sup>1</sup> Kohsuke Yamashita,<sup>1</sup> Haruhiko Kikuchi,<sup>1</sup> and Yoshito Ikada<sup>2</sup>

**Summary:** The authors detail their use of a modified version of an electrolysis coil currently manufactured in the United States. They connect a platinum wire to a stainless steel wire via a copper segment, and apply low voltage current to induce thrombosis while electrolysis of the copper effects separation of the platinum coil. Their technique shows potential for treatment of complicated carotid cavernous fistulas.

**Index terms:** Fistula, carotid-cavernous; Interventional instrumentation, coils; Cerebral angiography

Although the use of microcoils for treatment of the intracranial aneurysm and the carotid cavernous fistula (CCF) has become common, it is still unsatisfactory because of insufficient thrombogenesis and subsequent migration. Absence of retrievability also interferes with proper placement (1). Guglielmi et al have recently developed a detachable coil which may solve these problems (2, 3). This device consists of a platinum coil soldered to a stainless steel wire. Application of positive direct current through the wire electrolyzes a part of the stainless steel wire closest to the platinum coil and disconnects them in 4 to 12 minutes. At the same time, negatively charged blood cells are attracted to the positively charged platinum coil and a substantial amount of thrombus is formed. Having recognized the usefulness of the device, we concluded that it would develop into an essential treatment in selected cases. Although Guglielmi's detachable coil is already manufactured by Target Therapeutics, San Jose, CA, it is not now available in Japan and is not expected to be for the next several years. Therefore, we borrowed the innovative idea of the device and developed our own detachable coil (Fig. 1).

In our device, fine copper wire is used to connect a platinum coil to a stainless steel wire.

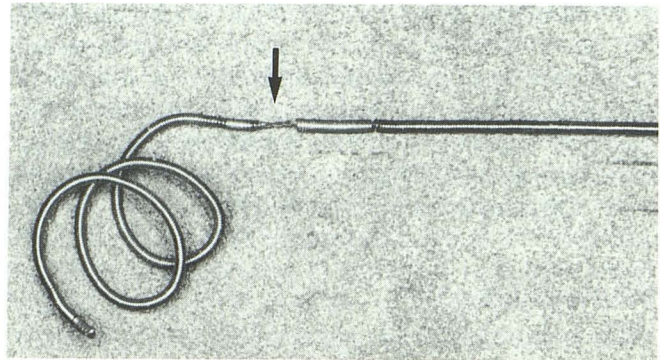


Fig. 1. Magnified view of the tip of an electrodetachable coil consisting of a platinum microcoil and stainless steel wire. The coil is connected to the stainless steel wire with a fine copper wire (arrow).

We have chosen copper for the electrolyzing part of the device because the copper wire is soft enough to keep the tip of the device flexible, and it has been commonly used for electrodes in direct electrothrombosis therapy and seems to be safe (4–8). By electrolyzing the copper wire, the platinum coil detaches in place with electrically formed thrombi on it. Although our device differs from Guglielmi's in this minor detail, the goal in terms of function is basically the same. We report the first clinical case treated by this device after several animal experiments.

## Case Report

A 50-year-old man experienced double vision after suffering left trochlear nerve palsy for 4 months; exophthalmus, chemosis, and left tinnitus were noted on admission in March 1991. Left external carotid angiography showed a spontaneous CCF supplied mainly from the left internal maxillary, middle meningeal, and accessory meningeal arteries. Both internal carotid arteries also supplied small

Received September 10, 1991; revision requested December 21; revision received February 24, 1992 and accepted May 18.

<sup>1</sup> Department of Neurosurgery, Kyoto University Medical School, Kyoto, Japan.

<sup>2</sup> Research Center for Biomedical Engineering, Kyoto University, Kyoto, Japan.

<sup>3</sup> Address reprint requests to Akiyo Sadato, MD, Department of Neurosurgery, Kyoto University Medical School, 54 Kawahara-cho Shogoin Sakyo-ku, Kyoto 606, Japan.



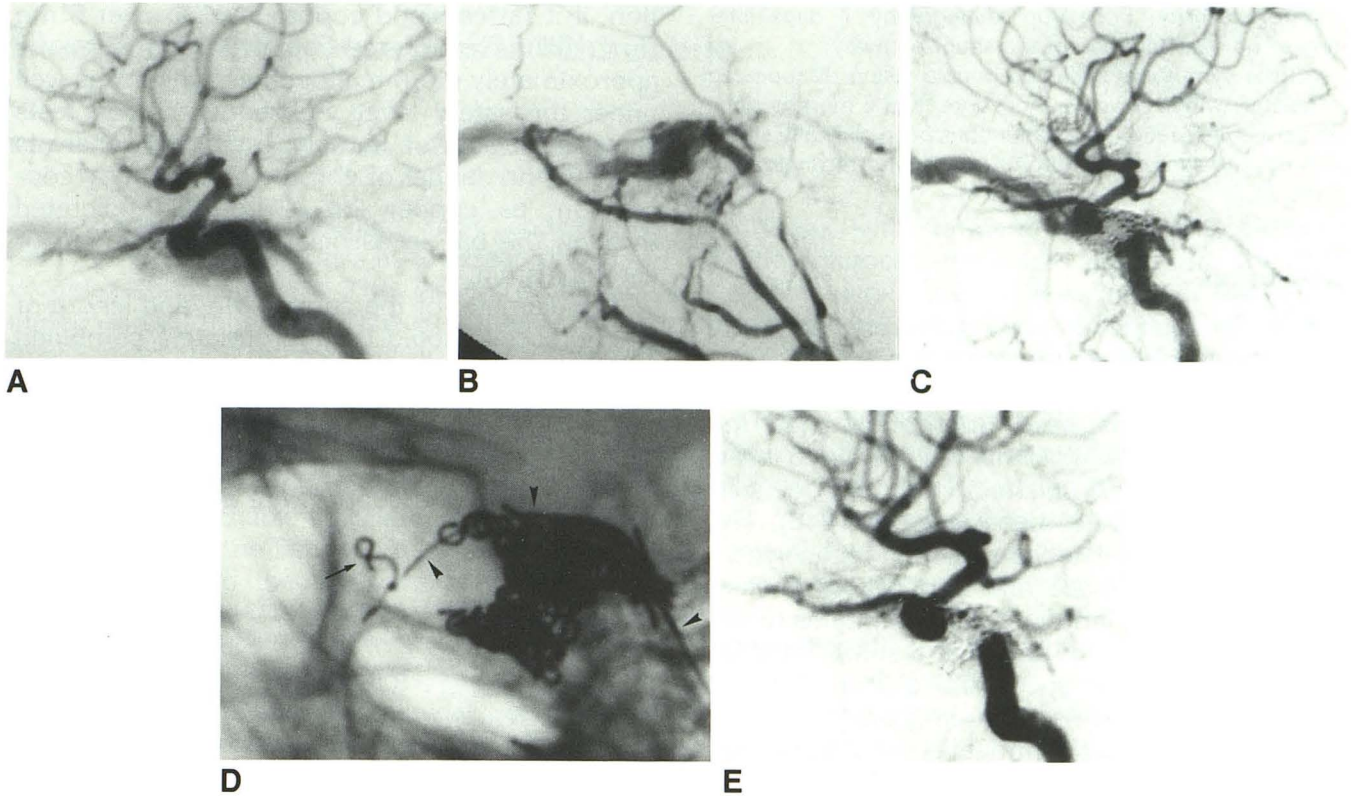


Fig. 2. Spontaneous CCF treated with electrodetachable microcoils.

A, Preoperative left internal carotid angiogram, lateral view. A CCF is shown.

B, Preoperative left external carotid angiogram, lateral view. The internal maxillary artery, the middle meningeal artery, and the accessory meningeal artery supplied the left CCF.

C, Left internal carotid angiogram after second, incomplete embolization, lateral view. Persistent early draining into the left superior ophthalmic vein.

D, Lateral skull radiograph taken during current application. An electrodetachable microcoil (arrow) placed into the left superior ophthalmic vein has not yet been detached from the stainless wire (arrowheads).

E, Left internal carotid angiogram after detaching the third coil, lateral view. No flow into the left superior ophthalmic vein is apparent.

branches to the left cavernous sinus. The fistula drained mostly into the left superior ophthalmic vein, and posteriorly into the left inferior petrosal sinus (Figs. 2A and 2B).

In the first attempt to treat that fistula, the left external carotid artery was embolized with gelatin sponge via a femoral route. Following this, the left cavernous sinus was embolized with 33 ordinary platinum microcoils through a 2.2-F catheter navigated up to the cavernous sinus via the left inferior petrosal sinus from a femoral vein. Although the embolization was incomplete at that time, progressive thrombosis was expected. Thirteen days later, however, follow-up angiography showed a persistent fistula and new feeding routes through the left ascending pharyngeal artery and retroauricular artery.

In the second attempt, the left internal maxillary, middle meningeal, ascending pharyngeal, and retroauricular arteries were embolized using ordinary microcoils. Following this step, about 80 microcoils were inserted into the cavernous sinus, again through the left inferior petrosal sinus. Although the shunt flow was considerably reduced by the end of these procedures, follow-up angiography performed

3 weeks later showed significant early draining flow into the left superior ophthalmic vein (Fig. 2C).

In the third treatment attempt, electrodetachable coils were utilized. The left internal jugular vein was punctured and a 2.2-F microcatheter was navigated up to the left superior ophthalmic vein. An electrodetachable coil was inserted into the superior ophthalmic vein through the microcatheter. We applied 2.0 mA positive direct current for 10 minutes and removed the detached guide wire. As angiography through the microcatheter showed little thrombus production at that time, we repeated the same procedure two more times. While the third electrodetachable coil was being implanted, the patient complained of a headache, and so the current was reduced to 1.0 mA, and then to as low as 0.6 mA. In total, we applied 2.0 mA for 18 minutes, 1.0 mA for 2 minutes, and 0.6 mA for 1 minute. After the third electrodetachable microcoil was detached, a left common carotid angiogram showed no shunt flow through the cavernous sinus and left superior ophthalmic vein (Figs. 2D and 2E). Finally, we inserted 15 ordinary platinum microcoils into the superior ophthalmic



vein for security. Follow-up angiography 7 days later showed no recanalization of the shunt pathway.

All the symptoms including double vision disappeared completely within 3 weeks. For more than 6 months since the third embolization, the patient has been clinically stable without any signs or symptoms suggesting recanalization of the CCF.

## Discussion

Based on the fact that blood cells are negatively charged, use of direct electrical current to thrombose CCFs, intracranial aneurysms, and vascular malformations has been attempted since the 1960s. Although craniotomy was needed to insert electrodes into a lesion, effective thrombogenesis using this method has been reported (4–8). The development of a detachable coil in recent years has made possible the first application of electrothrombosis via intravascular techniques (2, 3). Guglielmi et al recently reported results of animal experiments (2) and successful use in 15 cases of saccular aneurysms, including one CCF secondary to a ruptured intracavernous aneurysm (3).

Satisfactory thrombogenesis was demonstrated in our first clinical use of this coil in a spontaneous CCF that had remained incompletely embolized after the insertion of more than 100 conventional microcoils. It was cured by three electrodetachable coils. Placement of the detachable coils at the desired site was simple and easily controlled.

Concerning adverse side effects, there is the possibility of hemolytic anemia caused by acute copper poisoning, if the amount of electrolyzed copper is excessive. Normal blood copper level is 1–1.2 mg Cu/L; approximately 50% of the average dairy dietary intake of 2–5 mg of copper is absorbed into blood where most of it is bound to albumin (9). It has been said that hemolytic anemia may be caused by intravenous copper injec-

tion, if it raises blood copper level to over 6 mg Cu/L (10). Electrolyzed copper in this case was approximately 0.5 mg altogether, which was well under the safety level. Subsequent blood tests showed no sign of hemolytic anemia. There is probably no danger of chronic poisoning by copper ion, as copper ion is normally excreted through the bile in association with albumin or ceruloplasmin.

The diameter of the copper wire and length of platinum coil should be appropriately combined according to the type of lesion. The volume of electrically stimulated thrombi depends on the current, length of the platinum coil, and the time necessary for detachment, which is determined by the current and copper wire diameter.

## References

1. Halbach VV, Higashida RT, Barnwell SL, Dowd CF, Hieshima GB. Transarterial platinum coil embolization of carotid-cavernous fistulas. *AJNR* 1991;12:429–433
2. Guglielmi G, Vinuela F, Sepetka I, Macellari V. Electrothrombosis of saccular aneurysm via endovascular approach I. Electrochemical basis, technique, and experimental results. *J Neurosurg* 1991;75:1–7
3. Guglielmi G, Vinuela F, Dion J, Duckwiler G. Electrothrombosis of saccular aneurysm via endovascular approach II. Preliminary clinical experience. *J Neurosurg* 1991;75:8–14
4. Handa H, Yoneda S. Electrothrombosis for the treatment of cerebral vascular lesions. *Neurol Med Chir* 1978;18:795–802
5. Hosobuchi Y. Electrothrombosis of carotid-cavernous fistula. *J Neurosurg* 1975;42:76–85
6. Mullan S. Experience with surgical thrombosis of intracranial berry aneurysms and carotid cavernous fistulas. *J Neurosurg* 1974;41:657–670
7. Mullan S, Raimondi A, Dobben G, Vailati G, Hekmatpanah J. Electrically induced thrombosis in intracranial aneurysms. *J Neurosurg* 1965;22:539–547
8. Yoneda S, Matsuda M, Shimizu Y, Goto H, Handa H, Ogawa Y. Electrothrombosis of arteriovenous malformation. *Neurol Med Chir* 1977;17:19–28
9. Bearn A, Kunkel H. Localization of Cu<sup>64</sup> in serum fractions following oral administration: an alteration in Wilson's disease. *Proc Soc Exp Biol Med* 1954;85:44–48
10. Osterberg R. A critical review of copper in medicine. INCRE Research Report 1975, No. 234

Please see the Commentary by Viñuela et al on page 337 in this issue.