Are your MRI contrast agents cost-effective?
Learn more about generic Gadolinium-Based Contrast Agents.
FRESENIUS KABI
caring for life

AJNR

Spinal nerve enhancement with Gd-DTPA: MR correlation with the postoperative lumbosacral spine.

J R Jinkins, A G Osborn, D Garrett, Jr, S Hunt and J L Story

AJNR Am J Neuroradiol 1993, 14 (2) 383-394
http://www.ajnr.org/content/14/2/383

This information is current as of April 17, 2024.

Spinal Nerve Enhancement with Gd-DTPA: MR Correlation with the Postoperative Lumbosacral Spine

J. Randy Jinkins,[1,5] Anne G. Osborn,[2] David Garrett, Jr.,[3] Steve Hunt,[4] and Jim L. Story[3]

PURPOSE: To search for a probable source of the recurrent signs and symptoms associated with lumbosacral postsurgical syndrome on intravenous gadolinium-enhanced MR. **METHODS:** A retrospective study of 120 patients with recurrent symptomatology following lumbar disk surgery was carried out with spin-echo MR pre- and postenhancement with gadopentetate dimeglumine (0.1 mmol/kg). In addition, 10 asymptomatic subjects were evaluated at least 6 months postoperatively using the same imaging protocol. **RESULTS:** 21.6% of the symptomatic subjects (N = 26) had enhancement of one or more spinal nerve root. This enhancement was focal or multisegmental, and involved single or multiple nerve roots. The abnormal neural enhancement was associated with otherwise isolated epidural fibrosis in 88.5%, and with herniated nucleus pulposus in the remaining 11.5%. The overall clinical correlation of single root enhancement with a monoradiculopathy and multiroot enhancement with a polyradiculopathy was 95.7%. However, 21.7% of these same cases also showed additional nerve root enhancement that did not have an overt clinical correlation. All of these latter patients were imaged relatively early in the postoperative period (5 days to 8 months). The 10 patients in the asymptomatic group all manifested degrees of postoperative epidural scarring on MR, but no abnormal radicular enhancement or other associated pathology. **CONCLUSION:** In the chronic postoperative phase (more than 6 to 8 months), the presence of radicular enhancement on MR imaging in symptomatic individuals, and its absence in asymptomatic subjects, suggests that neural enhancement serves as a marker for active neural pathology that may in certain individuals be related temporally to the signs and symptoms associated with the lumbosacral postsurgical syndrome.

Index terms: Spine, magnetic resonance; Radiculitis; Contrast media, paramagnetic

AJNR 14:383–394, Mar/Apr 1993

Lumbosacral postsurgical syndrome consists of signs and symptoms occurring following operative treatment for disk disease. The literature has described in detail the two most important differential diagnoses in this syndrome *originating* in the postoperative period: 1) recurrent disk herniation, and 2) epidural scarring (1, 2). The clinical significance of recurrent disk herniation is obvious; however, the actual relationship of scarring to the clinical syndrome has never been elucidated. In fact, past computed tomography studies in postoperative asymptomatic subjects have shown that epidural fibrosis is present in equal or perhaps in even greater amounts in these individuals (3–5). Magnetic resonance (MR) with enhancement performed early in the postsurgical period (4–12 days) supports these observations (6). Contrast-enhanced MR scans performed up to 6 months after surgery in asymptomatic patients have shown a spectrum of findings including epidural fibrosis and nerve root enhancement (7). Changes responsible for failed therapy in the chronic postoperative phase include osseous foraminal or lateral recess stenosis, residual disk herniation, chronic adhesive arachnoiditis, and

Received July 30, 1991; revision requested August 16; revision received June 18, 1992 and accepted July 10.

Presented at the Annual Meeting of the American Society of Neuroradiology, Washington, DC, June 9–14, 1991.

Departments of [1] Radiology and [3] Neurosurgery, The University of Texas Health Science Center at San Antonio, San Antonio, TX 78284–7800.

[2] Department of Radiology, The University of Utah at Salt Lake City, Salt Lake City, UT 84108.

[4] Department of Radiology, Cottonwood Medical Center, Murray, UT 84115.

Address reprint requests to J. Randy Jinkins, MD, Director of Neuroradiology, The University of Texas Health Science Center at San Antonio, 7703 F Curl Drive, San Antonio, TX 78284–7800.

AJNR 14:383–394, Mar/Apr 1993 0195-6108/93/1402-0383
© American Society of Neuroradiology

finally "indeterminate" phenomena (eg, local vertebrogenic or remote musculoskeletal pathology). The purpose of this paper is to evaluate MR enhanced with intravenous (IV) gadopentetate dimeglumine (Gd-DTPA) one group of subjects with lumbosacral postsurgical syndrome, and to compare these findings with a second patient group without postoperative symptoms in an effort to search for abnormalities that might be associated with symptomatology.

Subjects and Methods

One hundred and twenty consecutive patients undergoing MR for the evaluation of persistent or recurrent signs (ie, pain, paresthesias) and symptoms (ie, weakness, reflex abnormalities) after lumbosacral spine surgery were evaluated retrospectively (symptomatic group). Patients ranged in age from 23 to 87 years old; the date of the most recent surgery prior to imaging ranged from 1 week to 9 years (Table 1).

T1-weighted (600/20/2, TR/TE/excitations), and T2-weighted (2000–2700/30–90/1) sagittal spin-echo imaging through the lumbosacral spine, and T1-weighted (600/20/2) oblique axial spin-echo imaging angled through the lower three lumbar intervertebral disks was performed. In addition, the T1-weighted (600/20/2) sagittal and axial spin-echo imaging was repeated immediately following the IV administration of Gd-DTPA (0.1 mmol/kg Magnevist). The thickness of the sections throughout was 5 mm, and the scan matrix was 256^2 or 256 × 192.

Scans were categorized into "normal" postoperative study (eg, evidence for laminectomy/laminotomy with minimal or no epidural enhancement and no additional visible abnormalities); isolated epidural fibrosis (eg, moderate to severe, focal or diffuse scarring, encasing the nerve root sheaths and/or thecal sac); herniated nucleus pulposus (either at the previously operated level or at a different vertebral interspace); extradural vertebral disease (eg, facet arthrosis and end plate osteophytosis with or without ligamentum flavum buckling, neural foraminal encroachment, central spinal or lateral recess stenosis); spinal nerve/nerve root enhancement (eg, enhancement of one or more neural radicles following IV Gd-DTPA administration), chronic adhesive arachnoiditis (eg, matting of intrathecal nerve roots, thickening of the dural sac, and adhesion of nerve roots to the thecal walls, with or without constriction of the thecal sac and enhancement); and miscellaneous lesions (eg, pseudomeningocele, conus region neoplasm).

Spinal nerve and nerve root enhancement (eg, an increase in signal on T1-weighted acquisitions of one or more neural radicles following IV Gd-DTPA administration) was determined by comparing the study cases to previously selected reference scans used as standard images. These showed focal (ie, single level) enhancement of a single root inside the thecal sac or root sleeve in association with epidural scar (Fig. 1) or disk herniation (Fig. 2), intrathecal single root enhancement extending over multiple segments (Fig. 3), intrathecal multiple root enhancement at a single or at multiple levels (Fig. 4), and extradural spinal nerve enhancement (Fig. 5).

A second group of subjects was composed of a prospective evaluation of 10 volunteer patients without signs or symptoms subsequent to surgery for lumbosacral disk disease (asymptomatic control group). The period at which these individuals were studied ranged from 6 months to 6 years after the operative procedure. With the approval of the Institutional Review Board, the MR examination carried out was identical to that outlined above for the symptomatic group.

Results

In the symptomatic group, the most common abnormality identified was moderate to severe epidural fibrosis, seen in 56 patients (46.7%). Anatomic changes limited to the surgical procedure enhancement (eg, laminotomy/laminectomy, minimal or no epidural enhancement) without other visible abnormalities were seen in 19 individuals (15.8%). Herniated nucleus pulposus was observed in 38 individuals (31.7%). Facet arthroses and degenerative osseous end plate spurring with varying degrees of neural foraminal narrowing, lateral recess encroachment, or generalized spinal stenosis were seen in 32 cases (26.7%).

Of the 120 patients in the symptomatic group, 26 (21.6%) had enhancement of one or more nerve roots following IV Gd-DTPA contrast administration. Of the 26 subjects with enhancing nerve roots, epidural fibrosis was associated in 88.5% of the total, and herniated nucleus pulposus in 11.5%. Enhancing roots were associated with isolated surgical change in 0% (N = 0), and with extradural osseous degenerative disease in 0% (N = 0).

The most commonly identified pattern of neural enhancement was isolated or single level focal enhancement of one nerve root, seen in 18 of the 26 patients (69.2%). Six patients had multiple roots enhancing at a single interspace (23.1%). Two patients had multilevel enhancement of a single root that extended over several interspaces, proximally and/or distally (7.7%). The earliest case of radicular enhancement was noted at 1 week after surgery and the latest at 9 years.

Sufficient clinical information for correlation of symptoms with enhancing nerve roots was available in 23 of the 26 patients. The three other patients were referred from remote sources and the clinical syndrome could not be reliably ascer-

TABLE 1: Summary of clinicoradiologic findings in 23 subjects with postoperative lumbosacral nerve root enhancement

Case No.	Location of Surgery: Side/Level/Site	Time Elapsed since Surgery	Current Clinical Syndrome	Site/Side/Level of Nerve Root Enhancement	Additional MR Findings	Clinical/MR Follow-Up
1	Left L4-L5, L5-S1 laminotomy, diskectomy L4-L5	2 weeks	Left posterior buttock, thigh pain	Multiple intrathecal root enhancement at L4-L5, L5-S1; left L5 root enhancement within root sheath	Epidural fibrosis: L4-L5, L5-S1	–
2	Bilateral decompression laminotomy, bilateral foraminotomy L4-L5; fusion L5-S1	13 months	Low back, left posterior thigh pain	Left L5 root enhancement within root sheath	Epidural fibrosis: L4-L5, L5-S1; left L5 root swelling	–
3	Right L4-L5, L5-S1 laminotomies, fusion L4-S1	18 months	Right posterior thigh/calf pain	Right L4-L5, L5-S1 root enhancement with root sheaths	Epidural/dural fibrosis: L4-L5, L5-S1	–
4	Multiple bilateral laminectomies, diskectomies L4-L5, L5-S1; fusion L4-S1	2 years	Low back pain; left antero and posterior leg pain	Left S1 root enhancement within root sheath	Epidural/dural fibrosis: L4-L5, L5-S1	–
5	Left L5 laminectomy, foraminotomy; fusion L5-S1	3 years	Left posterior leg pain	Left S1 root enhancement within root sheath	Epidural fibrosis: L5-S1	–
6	Left laminotomy, diskectomy L5-S1	14 months	Low back pain; left posterior calf and foot pain, and dysesthesias	Left S1 root enhancement within root sheath	Epidural fibrosis: L5-S1	–
7	Bilateral laminectomy, diskectomy L5-S1	2 years	Low back pain, left posterior leg pain	Left S1 root enhancement within root sheath	Epidural fibrosis: L5-S1	–
8	Right laminectomy, partial L5-S1 facetectomy; previous diskectomy at this level	5 years	Low back, buttock, posterior leg pain; numbness right foot, weakness right leg	Right S1 root enhancement within root sheath	Epidural fibrosis: L5-S1	Root enhancement unchanged since MR examination 2 years earlier
9	L4-L5, L5-S1 laminotomy, diskectomy	2½ years	Left buttock, left anterolateral thigh, left lateral foot, right foot pain	Left L5-S1 root enhancement within root sheath	Epidural fibrosis: L4-L5, L5-S1, left S1 root swelling	–
10	Right L5-S1 laminotomy, diskectomy	5 days	Right buttock, thigh, lateral foot pain, numbness right perineum; right leg weakness, bowel and bladder dysfunction	Multiple intrathecal root enhancement at L5-S1	Epidural fibrosis: L5-S1	Repeat MR at 10 weeks showed only right S1 root enhancement within root sheath; right lower extremity signs and symptoms unchanged

TABLE 1—Continued

Case No.	Location of Surgery: Side/Level/Site	Time Elapsed since Surgery	Current Clinical Syndrome	Site/Side/Level of Nerve Root Enhancement	Additional MR Findings	Clinical/MR Follow-Up
11	L4-L5 diskectomy, bilateral L5-S1 foraminotomies	5 months	Left buttock, posterior thigh, leg pain to ankle, groin pain	Bilateral intrathecal root enhancement at L5-S1	Epidural fibrosis: L4-L5, L5-S1	–
12	Bilateral L4-L5, L5-S1 laminectomies	5 years	Low back pain, bilateral hip and thigh pain	Bilateral intrathecal root enhancement at L4-L5	Epidural fibrosis: L4-L5, L5-S1	–
13	Right L5-S1 laminotomy, diskectomy	20 months	Right buttock, posterior thigh and lateral foot pain	Right S1 root enhancement within root sheath	Epidural fibrosis: L5-S1	–
14	Right L4-L5 laminotomy, diskectomy	14 months	Left leg and foot pain	Left L5 root enhancement within root sheath	Recurrent left paramedian L4-L5 herniated disk	–
15	Bilateral L4-L5 laminotomy, diskectomy	8 months	Low back pain, right leg pain	Multiple intrathecal enhancement at L4-L5	Epidural fibrosis: L4-L5	Repeat MR at 9 months demonstrated resolution of enhancement; subtotal resolution of signs and symptoms
16	Right L5-S1 laminectomy, diskectomy	4 months	Low back pain, right leg pain	Multiple intrathecal root enhancement at L5-S1; right S1 root enhancement within root sheath	Epidural fibrosis: L5-S1	–
17	L4-L5 laminectomy, diskectomy; fusion L4-S1	5 years	Low back pain, right posterior calf pain; left leg paresthesias	Left S1 root enhancement within root sheath	Left S1 fusion; epidural fibrosis: L4-L5, L5-S1	–
18	L4-L5, L5-S1 laminectomies, diskectomies	3 years	Left leg pain, bladder dysfunction	Left intrathecal root enhancement at L4-L5	Recurrent left L4-L5 herniated disk	–
19	L5-S1 laminectomy, diskectomy	9 years	Low back pain, dominant left hip, leg pain	Left S1 root enhancement within root sheath	Epidural fibrosis: L5-S1	–
20	Right L5-S1 laminectomy, diskectomy	2 months	Right posterior left pain	Right S1 root enhancement within root sheath; craniad extension of enhancement to conus	Epidural fibrosis: L5-S1	–
21	Bilateral L4-L5, L5-S1 laminotomies, diskectomies	10 weeks	Left buttock, thigh, and calf pain	Left L4-L5 root enhancement within root sheath	Epidural fibrosis: L4-L5, L5-S1	–

TABLE 1—Continued

Case No.	Location of Surgery: Side/Level/Site	Time Elapsed since Surgery	Current Clinical Syndrome	Site/Side/Level of Nerve Root Enhancement	Additional MR Findings	Clinical/MR Follow-Up
22	Bilateral L4-L5, L5-S1 laminectomies, diskectomies	4 years	Left leg pain	Left S1 root enhancement within root sheath	Left L3-L4 herniated disk	–
23	Bilateral L4-L5, L5-S1 laminectomies, diskectomies	5 years	Dominant left leg pain	Left S1 root enhancement within root sheath	Recurrent left L5-S1 herniated disk	–

Note.— – = not done or no change.

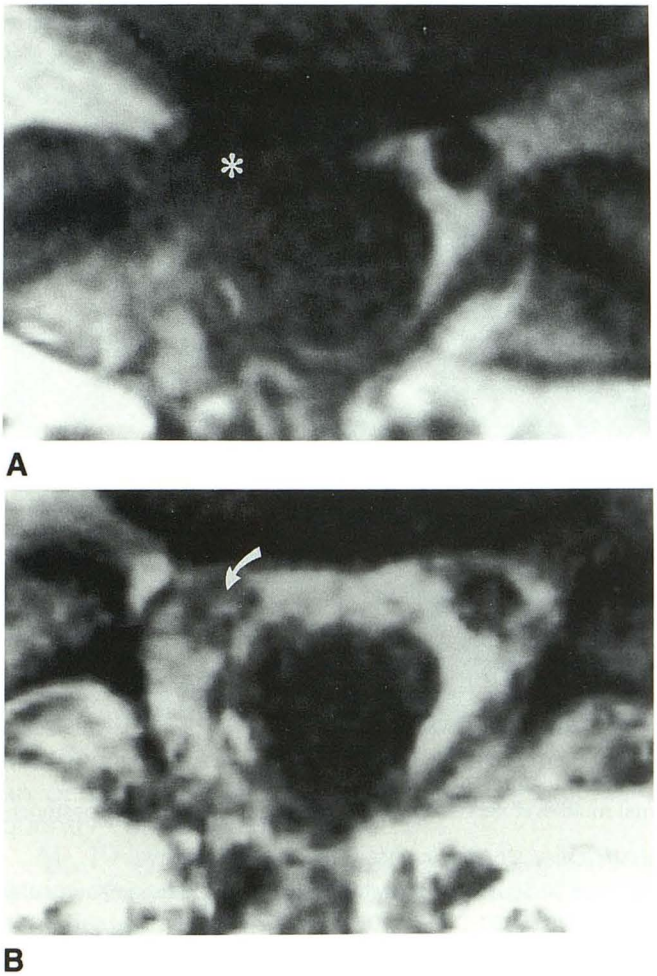

Fig. 1. Forty-eight-year-old man with right S1 radiculopathy: single focally enhancing nerve root associated with postoperative epidural fibrosis.

A, Precontrast T1-weighted (600/20) axial image illustrating the obliteration of the epidural fat on the right (*asterisk*).

B, Gd-DTPA-enhanced T1-weighted (600/20) axial image demonstrating perineural enhancement of the epidural scar, but also enhancement of the right S1 nerve root itself is identified compatible with radiculitis (*arrow*). Compare with normal left S1 nerve root and *A*.

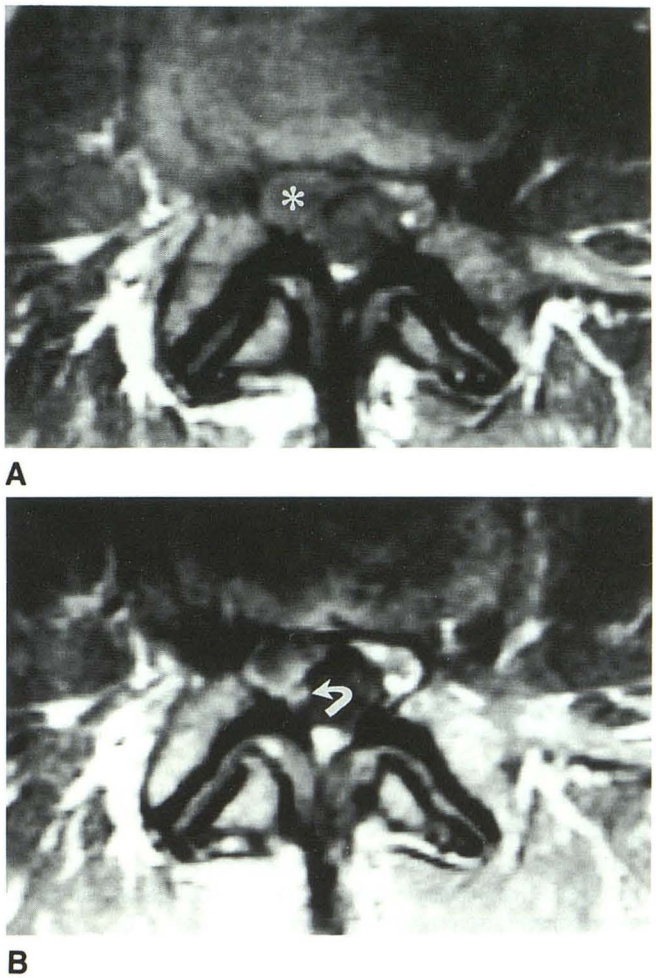

Fig. 2. Fifty-one-year-old man with right lower extremity radiculopathy: single focally enhancing nerve root associated with postoperative recurrent disk herniation.

A, Precontrast T1-weighted (600/20) axial image demonstrates a focal right-sided mass (*asterisk*).

B, Gd-DTPA-enhanced T1-weighted (600/20) image shows an intrathecally enhancing root (*arrow*) adjacent to the peripherally enhancing disk herniation. No intrathecal enhancement was identified extending craniad or caudad from this image.

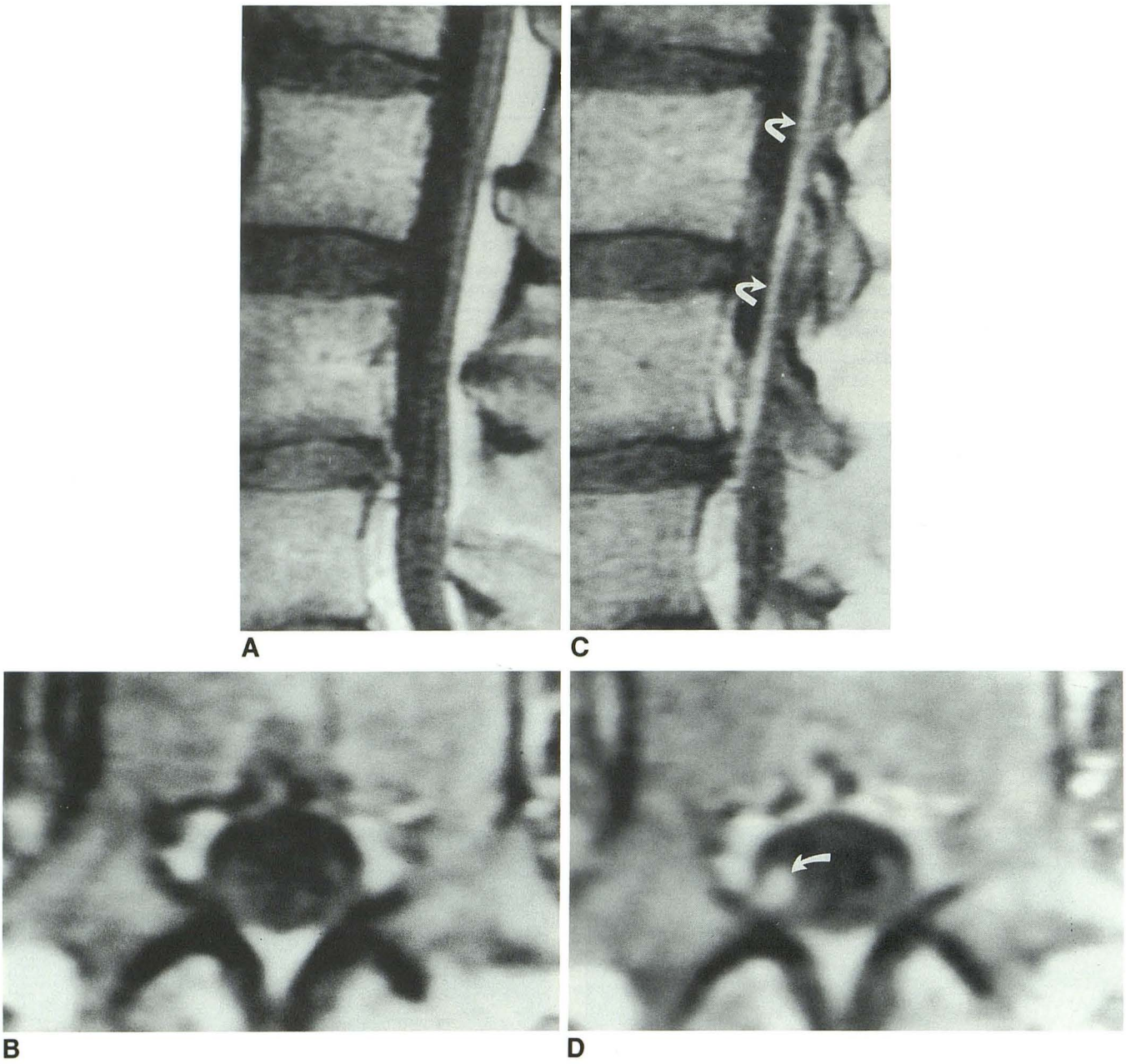

Fig. 3. Man with right lower extremity radiculopathy: single, proximal multilevel nerve root enhancement associated with postoperative epidural fibrosis.

A and *B*, Precontrast T1-weighted (600/20) sagittal and axial images revealing no distinct abnormality.

C and *D*, Gd-DTPA-enhanced T1-weighted (600/20) sagittal and axial images demonstrating extensive multisegment neural enhancement (*arrows*) (case courtesy of T. Burt, MD).

tained. Of the 23 who were reviewed, 20 manifested a clinical *monoradiculopathy* that correlated with the side and level of origin of the root enhancement on the MR examination in 19 cases. The clinical review of the remaining three cases of *polyradiculopathy* had good correlation with the MR evidence of multiple enhancing nerve roots in all three. The overall correlation of clinical radiculopathy with root enhancement thus was 95.7% (22 of 23 individuals). However, five of these same cases (21.7%) also showed additional nerve root enhancement that did *not* have an overt clinical correlation (cases 1, 10, 11, 15, and 16). All of these latter cases represented studies obtained relatively early in the postoperative period (5 days to 8 months). No case manifesting

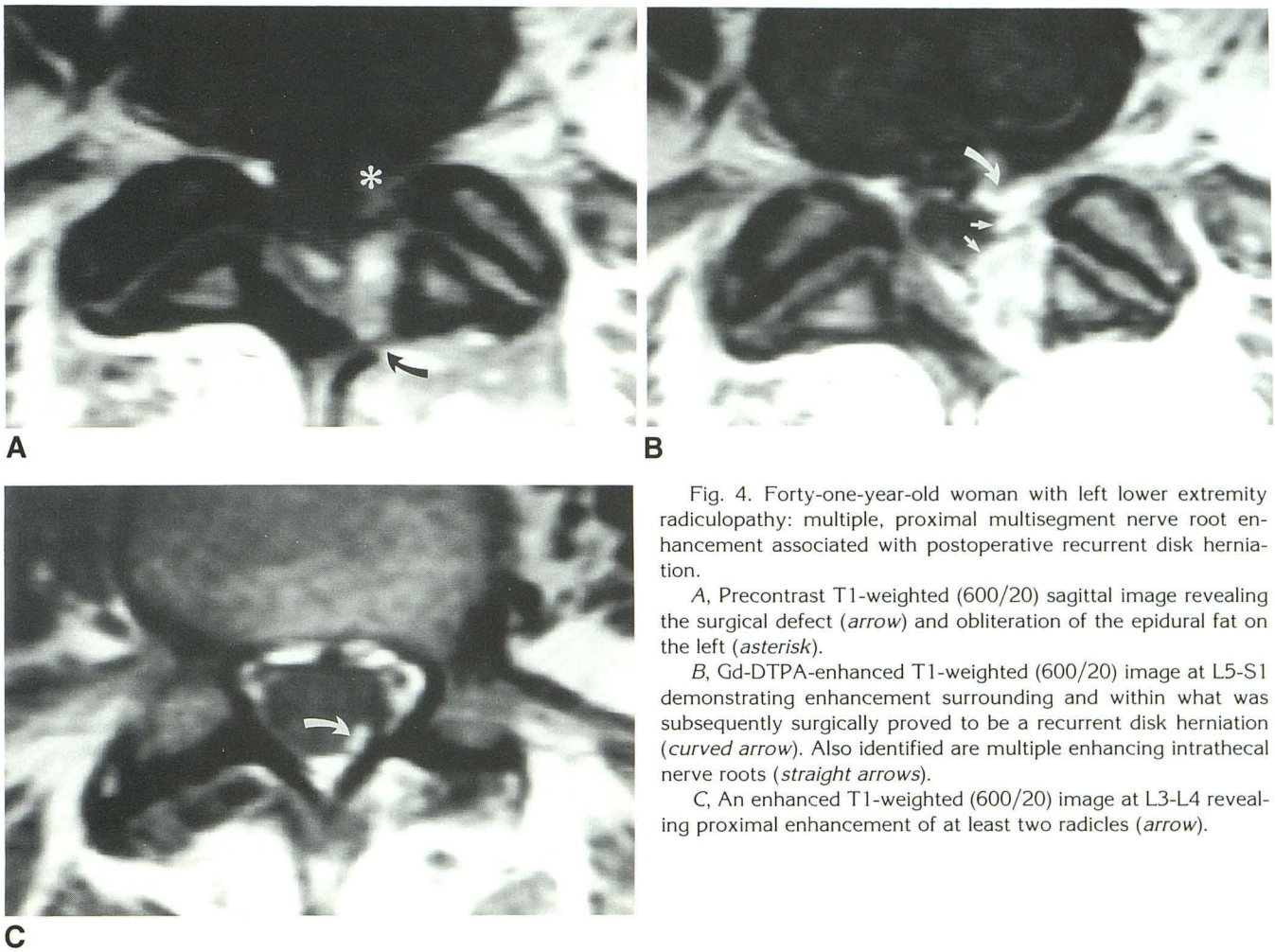

Fig. 4. Forty-one-year-old woman with left lower extremity radiculopathy: multiple, proximal multisegment nerve root enhancement associated with postoperative recurrent disk herniation.

A, Precontrast T1-weighted (600/20) sagittal image revealing the surgical defect (*arrow*) and obliteration of the epidural fat on the left (*asterisk*).

B, Gd-DTPA-enhanced T1-weighted (600/20) image at L5-S1 demonstrating enhancement surrounding and within what was subsequently surgically proved to be a recurrent disk herniation (*curved arrow*). Also identified are multiple enhancing intrathecal nerve roots (*straight arrows*).

C, An enhanced T1-weighted (600/20) image at L3-L4 revealing proximal enhancement of at least two radicles (*arrow*).

an enhancing nerve root on MR had a known past myelogram performed with oil-based contrast media.

The remaining abnormalities identified in the symptomatic group were chronic adhesive arachnoiditis (N = 2) and pseudomeningocele (N = 1). Postoperative MR study of one patient revealed an occult conus neurofibroma that was subsequently confirmed surgically.

All 10 patients in the asymptomatic control group demonstrated varying amounts of epidural scar tissue (Fig. 6). None, however, revealed any observable spinal nerve/root enhancement following IV Gd-DTPA administration. In addition, no recurrent/residual disk herniation or other structural spinal abnormality could be identified in the asymptomatic group.

Discussion

The lumbosacral postsurgical syndrome is composed of signs consisting of dysfunction and disability as well as symptoms comprising pain and paresthesia. A so-called failed back may be responsible for this constellation of findings. A true biomechanical failure of the spine in regard to disk disease may encompass: 1) primary disk herniation, and 2) recurrent disk herniation. Failure of some aspect of the treatment to cure the clinical syndrome, on the other hand, may be due to a wide variety of potential causes such as: 1) residual disk herniation, 2) spinal, meningeal, and/or neural inflammation, 3) epidural scar formation, 4) spinal/foraminal stenosis, and 5) remote or indeterminate phenomena that are unrelated to the spine itself (1, 2).

Most recurrent disk herniations are associated with variable amounts of epidural scar tissue. On immediate imaging following the IV administration of Gd-DTPA, the peripheral scar tissue will enhance variably, while the central, generally hypovascular extruded disk material in the majority of cases should not enhance in its entirety (6, 8,

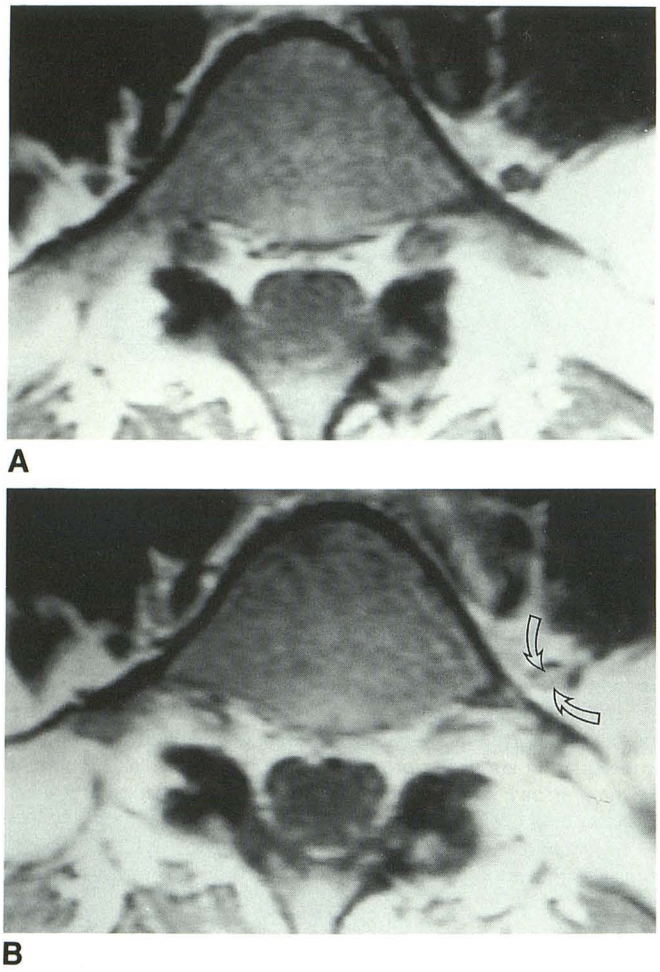

Fig. 5. Forty-year-old woman with left lower extremity radiculopathy: single, distal multisegment enhancing nerve associated with postoperative epidural fibrosis.

A, Precontrast T1-weighted (600/20) axial image shows no distinct abnormality. Mild epidural fibrosis was seen at the operative level (not shown).

B, Gd-DTPA-enhanced T1-weighted (600/20) axial image reveals intense enhancement of a left-sided descending extraforaminal lumbosacral nerve (*arrows*). Compare with opposite side and *A*.

9). False negatives (ie, totally or subtotally enhancing true disk herniations) in this setting are likely attributable to: 1) delaying the scan time beyond the immediate postinjection period, so that Gd-DTPA gradually "seeps" into the center of the disk thereby masking its presence; 2) a disk herniation that is sufficiently old that it is entirely permeated with the neovascularity accompanying the granulation tissue associated with disk extrusion; therefore, the extruded disk material generally enhances; or 3) actual rapid diffusion of contrast material into the loose connective tissue of the disk extrusion during the subacute phase after surgery (8, 9).

On the other hand, given the preceding stipulations, immediate complete enhancement of epidural tissues with IV Gd-DTPA, in the face of postoperative obliteration of epidural fat, usually indicates scarring (8, 9–11). This fibrosis may be plaque-like and/or mass-like in form, either of which may be indistinguishable from an actual disk herniation without the benefit of IV Gd-DTPA enhancement. Many of the cases in this series with otherwise unremarkable epidural fibrosis also demonstrated neural enhancement with IV Gd-DTPA-enhanced MR. The other association of nerve root enhancement was with disk herniation. Presumably, the latter circumstance was related to direct mechanical trauma which resulted in the observed neural enhancement on MR.

Some of the cases of multiple enhancing nerve roots may be due to a different phenomenon. Although unproved, these cases most probably represent instances of generalized low-grade aseptic inflammation. There were no clinical findings to suggest active infection in any of the individuals in this study, and no responsible agent could be identified.

It has been observed by others that asymptomatic neural enhancement on Gd-DTPA-enhanced MR may occur during the first 6 months following surgery, after which it resolves (7). Seven of the 26 cases of neural enhancement in the present series were observed relatively early in the postoperative period, within 8 months of the surgery. Importantly, five of the seven were the same five who demonstrated nerve root enhancement that did *not* correlate with clinical signs and symptoms. This represents clinically irrelevant early postoperative root enhancement (7). On the other hand, persistent enhancement beyond 6 to 8 months had a very high correlation (95.7%) with the presenting clinical syndrome in the current study.

Mild temporary pressure per se is of doubtful direct influence in the generation of symptoms in the chronic stages of neural compression. Although a sudden mechanical blow may induce transient paresthesias or even acute pain, such an insult, if minor, may not incite prolonged pain (12–14). However, a frank nerve crush or abnormal pressure brought to bear upon a nerve root *chronically* does cause pathophysiologic changes within the nerve that will in all probability result in extended pain and disability (15, 16).

In certain individuals, simple surgical removal of the disk herniation that was responsible for the

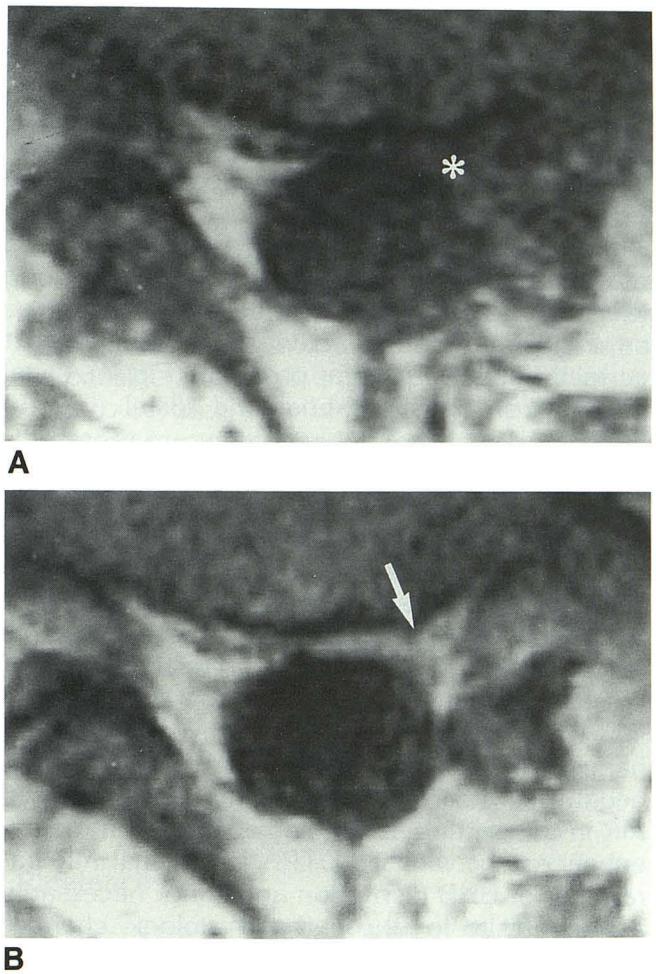

Fig. 6. Fifty-eight-year-old asymptomatic woman 6 months following successful disk surgery: isolated postoperative epidural fibrosis.

A, Precontrast T1-weighted (600/20) axial image showing obliteration of the epidural fat on the left (*asterisk*).

B, Gd-DTPA-enhanced T1-weighted (600/20) axial image demonstrating peripheral epidural enhancement (*arrow*) compatible with epidural fibrosis, but absence of detectable enhancement of intrathecal neural tissue.

initial insult may not halt the pathologic process. The enhancing nerve roots observed in this study that were not associated with disk herniations supported this hypothesis. The chronic pain that ensued may have its primary origin in continuous nerve root injury that preceded the operative procedure (ie, traumatic radiculitis). In other words, the pathophysiologic mechanism responsible for the observed enhancing nerve root may have transcended the disk surgery. The asymptomatic neural enhancement observed in the immediate postoperative period favored this contention (7). In this circumstance, the neural enhancement on MR in some cases was simply lagging behind the clinical recovery, but nevertheless represented an observable phenomenon of ongoing injury/repair.

In the majority of cases, abnormal nerve root enhancement was seen at the level of the operated disk and extended for a short distance caudally. The experimental correlation for this predominant distribution is found in studies of traumatized sciatic nerves in animal models. The pathologic vascular permeability of injured nerves increased both proximally and distally to the insult, although the increase tended to be significantly greater distally. This abnormal vascular permeability extended only for a relatively short distance, which was measured in centimeters (17, 18).

The epineurium and perineurium surrounding peripheral nerves in experimental animals contain no endothelial barrier to the passage of even large macromolecules from the bloodstream into the peripheral tissues (19–25). Ultrastructurally, both open junctions and fenestrae are present in the epineural and perineural vessels, thereby accounting for these findings. Nevertheless, these neural coverings are biomechanically quite strong, and structurally provide a measure of safety from mechanical injury (25). The proximal spinal roots, however, are somewhat different. Like the spinal cord, these roots are covered by arachnoid and pia, and the whole is bathed in cerebrospinal fluid (CSF). Thus, although surrounded loosely by dura and more closely by pia, the root does not have the advantage of an intimate, durable covering of perineurium, and may therefore be relatively more susceptible to external trauma (13, 26). In addition, the endothelial vessels traversing the nerve root itself are fundamentally different from those found in the epi- and perineurium of peripheral nerves. The vessles of the endoneurium constitute a true blood-nerve barrier (BNB) to the free exchange of water soluble nonelectrolytes, proteins, and some ions (24). However, this barrier is species-, individual-, and even nerve-specific (20).

Under normal conditions in humans, the degree of extravascular extravasation of intravascular substances (including radiographic contrast media) into spinal nerve roots is believed to be minor (19, 27, 28). In MR imaging, enhancement of spinal and cauda equina nerve roots following IV Gd-DTPA administration at 0.1 mmol/kg is not a normal occurrence (28). The distinction should be noted, on the other hand, that there is little or no BNB within the spinal dorsal root ganglia,

which explains their intense enhancement pattern after IV Gd-DTPA (18, 28). Anatomically, the dorsal ganglia are aligned longitudinally with the sacral roots, as opposed to transversely with dorsal roots elsewhere in the spine. A caveat to preceding observations concerning abnormal root enhancement in MR imaging is that, at and below the S1-S2 level, and within the lumbar neural foramina, any perceived neural enhancement may be due to physiologically enhancing dorsal ganglia. As dorsal root ganglion enhancement is inseparable visually from the remainder of the nerve root, this finding should not be misinterpreted.

With frank compression injury to spinal nerves and roots, however, this otherwise relatively intact BNB may break down. At surgery for disk herniation, affected nerve roots occasionally are noted to be swollen and hyperemic (29). Increased vascular permeability and accompanying vasodilatation presumably account partly for the abnormal neural enhancement identified on Gd-DTPA-enhanced MR in pathologic situations such as that observed in the cases in the present series (17, 18, 30, 31).

In addition to the direct trauma emanating from the initial disk herniation and subsequent surgery, other stimuli may be responsible for inducing epidural and perhaps primary or secondary neural inflammation. Byproducts of disk nutrition (ie, lactic acid) or otherwise normal substances ordinarily contained within the intact intervertebral disk (ie, glycoproteins) hypothetically may cause an inflammatory response following rupture of the disk into the epidural space (14, 32). Alternately, or in addition to this response to chemical irritation, an allergic/autoimmune reaction to disk material may play a part in the epidural pathologic process (14, 32). However, it seems unlikely that the spinal nerve, protected by the barrier formed by the dura, arachnoid, CSF, and pia, would be intimately affected in most cases by such epidural reactions (13). Therefore, while epidural fibrosis may be a direct manifestation of these processes, the pathology within the underlying nerve itself may not. Some experimental evidence seems to bear this out (33). Chronic compressive neural trauma/ischemia is believed to be the leading cause of the inflammation and secondary abnormal neurophysiologic change that may continue long after the initially offending influence (ie, disk herniation) has been removed (13, 16, 26, 34). Epidural fibrosis through CSF nutritional deprivation and a tethering of the root causing traction on the nerve during somatic movements may induce additional aberrant neuroelectrical potentials within the already inflamed, hypermechanosensitive axons (15, 35–37). However, actual mechanical circumferential constriction of the underlying nerve root could potentially be amplified by the perineural scar (38).

It has been proven that axon degeneration and regeneration actually contribute to and prolong the BNB breakdown and are believed to serve as an indicator of such activity (31, 39). Almost certainly, the cases of far proximal (Fig. 4), distal (Fig. 3), or both proximal and distal (Fig. 5) multisegmental root enhancement are representative of ongoing degenerative and regenerative phenomena within injured neural tissue.

In closing, final consideration should be given to those individuals in the symptomatic group who did not demonstrate either recurrent disk herniation or enhancing nerve roots or spinal nerves. One explanation for this is that some of these cases actually do have a low-grade neural injury but nevertheless do not reveal neural enhancement. Therefore, they may represent false negatives with regard to IV Gd-DTPA-enhanced MR in this setting. It should be stated that neural enhancement with Gd-DTPA is a visual MR parameter of BNB disruption and is not necessarily a prerequisite for the pathophysiologic changes linked with clinical signs and symptoms. BNB disruption and radicular pain are two fundamentally different pathophysiologic processes that may in certain situations be associated both temporally and spatially. By the same token, it may be assumed that the two may become dissociated in some circumstances (11). Nevertheless, the remote neural enhancement related to axonal degeneration/regeneration may be coupled to motor axon dysfunction and therefore clinical weakness and reflex dysfunction. However, the presence of neural enhancement with Gd-DTPA may also indicate a more severely injured nerve than would be true otherwise. Additional causes for symptoms in the sciatic distribution that are not intimately related to the spinal nerve root, and that might not therefore be visualized on a lumbosacral MR, include primary musculoskeletal pathology (ie, facet arthropathy, myofacial injury, etc) and peripheral sciatic nerve disease. Thus, a considerable etiologically indeterminate group still remains to be understood.

In summary, Gd-DTPA is an important adjunct to the MR evaluation of the postoperative lumbosacral spine with regard to the clarification of

the clinical, radiologic, physiologic, and prognostic aspects of the postsurgical syndrome. The three major areas of application are in the elucidation and differentiation of: 1) residual/recurrent disk herniation with or without associated scar formation, 2) isolated plaque-like or mass-like epidural fibrosis, and 3) spinal, leptomeningeal, and neural inflammation or neural degeneration of nonspecific etiology. The identification of enhancing nerves and/or nerve roots that correlate with clinical signs and symptoms may warrant the consideration of therapy specifically aimed at a neuroelectrical stabilization of the axon membrane. This may reduce the level of spontaneous pathologic ectopic neuroelectrical activity within the hypermechanosensitive nerve root that is believed to be partially responsible for the pathologic pain, paresthesias, and neuromuscular dysfunction associated with the postsurgical syndrome both in the presence and the absence of correlative anatomic spinal abnormalities.

Acknowledgment

We thank J. Murray for the manuscript preparation.

References

1. Burton CV, Kirkaldy-Willis WH, Yong-Hing K, Heithoff KB. Causes of failure of surgery on the lumbar spine. *Clin Orthop* 1981;157: 191–199
2. Byrd SE, Cohn ML, Biggers SL, Huntington CT, Locke GE, Charles MF. The radiographic evaluation of the symptomatic postoperative lumbar spine patient. *Spine* 1985;10:652–661
3. Braun IF, Lin JP, Benjamin MV, Kricheff II. Computed tomography of the asymptomatic postsurgical lumbar spine: Analysis of the physiologic scar. *AJNR* 1983;4:1213–1216
4. Montaldi S, Fankhauser H, Schnyder P, de Tribolet N. Computed tomography of the postoperative intervertebral disc and lumbar spinal canal: investigation of twenty-five patients after successful operation for lumbar disc herniation. *Neurosurgery* 1988;22:1014–1022
5. Cervellini P, Curri D, Volpin L, Bernardi L, Pinna V, Benedetti A. Computed tomography of epidural fibrosis after discectomy: a comparison between symptomatic and asymptomatic patients. *Neurosurgery* 1988;23:710–713
6. Roosen N, Kahn T, Messing M, Trappe RP, Moedder U, Lins E, Bock WJ. Gadolinium-DTPA-enhanced MRI of the asymptomatic postdiscectomy lumbar spine: early postoperative results. *Neuroradiology* 1991;33:99–100
7. Boden SD, Davis DO, Dina TS, et al. Contrast-enhanced MR imaging performed after successful lumbar disk surgery: prospective study. *Radiology* 1992;182:59–64
8. Hueftle MG, Modic MT, Ross JS, et al. Lumbar spine: postoperative MR imaging with Gd-DTPA. *Radiology* 1988;167:817–824
9. Bundschuh CV, Mittman B, Ladaga LE, Schinco FP. Correlation of patient symptoms, histology, and MR imaging characteristics of herniated nucleus pulposus specimens. *JMRI* 1991;1:182–183
10. Ross JS, Delamarter R, Hueftle MG, et al. Gadolinium-DTPA-enhanced MR imaging of the postoperative lumbar spine: time course and mechanism of enhancement. *AJNR* 1989;10:37–46
11. Ross JS, Masaryk TJ, Schrader M, Gentili A, Bohlman H, Modic MT. MR imaging of the postoperative lumbar spine: assessment with gadopentetate dimeglumine. *AJNR* 1990;11:771–776
12. Kelly M. Is pain due to pressure on nerves? *Neurology* 1946;6:32–38
13. Rydevik B, Brown MD, Lundborg G. Pathoanatomy and pathophysiology of nerve root compression. *Spine* 1984;9:7–15
14. Haughton VM, Nguyen CM, Ho K-C. Effect of experimental root sheath compression on dura. *Invest Radiol* 1989;24:204–205
15. Howe JF, Loeser JD, Calvin WH. Mechanosensitivity of dorsal root ganglia and chronically injured axons: a physiological basis for the radicular pain of nerve root compression. *Pain* 1977;3:25–41
16. Devor M, Rappaport HZ. Pain and the pathophysiology of damaged nerve. In: Fields HL, ed. *Pain syndromes in neurology.* Boston: Butterworths, 1990:47–83
17. Olsson Y. Studies on vascular permeability in peripheral nerves. I. Distribution of circulating fluorescent serum albumin in normal, crushed and sectioned rat sciatic nerve. *Acta Neuropathol (Berl)* 1966;7:1–15
18. Fukuhara N, Kumamoto T, Nakazawa Y, Tsubaki T. Blood-nerve barrier: effect of ligation of the peripheral nerve. *Exp Neurol* 1979;63:573–582
19. Olsson Y. Topographical differences in the vascular permeability of the peripheral nervous system. *Acta Neuropathol (Berl)* 1968;10: 26–33
20. Olsson Y. Studies on the vascular permeability in peripheral nerves: distribution of intravenously injected protein tracers in the peripheral nervous system of various species. *Acta Neuropathol (Berl)* 1971; 17:114–126
21. Miyoshi T, Kennedy WR, Yoon KS. Morphometric comparison of capillaries in muscle spindles, nerve, and muscle. *Arch Neurol* 1979;36:547–552
22. Michel ME, Shinowara NL, Rappaport SI. Presence of a blood-nerve barrier within blood vessels of frog sciatic nerve. *Brain Res* 1984;299:25–30
23. Malmgren LT, Olsson Y. Differences between the peripheral and the central nervous system in permeability to sodium fluorescein. *J Comp Neurol* 1980;191:103–117
24. Rechthand E, Smith QR, Rappaport SI. Transfer of nonelectrolytes from blood into peripheral nerve endoneurium. *Am J Physiol* 1987;252:H1175–H1182
25. Rechthand E, Rappaport SI. Regulation of the microenvironment of peripheral nerve: role of the blood-nerve barrier. *Proc Neurobiol* 1987;28:303–343
26. Olmarker K, Rydevik B, Holm S, Bagge U. Effects of experimental graded compression on blood flow in spinal nerve roots: a vital microscopic study on the porcine cauda equina. *J Orthop Res* 1989;7:817–823
27. Rydevik B, Nordborg C. Changes in nerve function and nerve fiber structure induced by acute, graded compression. *J Neurol Neurosurg Psychiatry* 1980;43:1070–1082
28. Breger RK, Williams AL, Daniels DL, et al. Contrast enhancement in spinal MR imaging. *AJNR* 1989;10:633–637
29. Green LN. Dexamethasone in the management of symptoms due to herniated lumbar disc. *J Neurol Neurosurg Psychiatry* 1975;38: 1211–1217
30. Rydevik B, Lundborg G. Permeability of intraneural microvessels and perineurium following acute, graded experimental nerve compression. *Scand J Plast Reconstr Surg* 1977;11:179–187
31. Mackinnon SE, Dellon AL, Hudson AR, Hunter DA. Chronic nerve compression: an experimental model in the rat. *Ann Plast Surg* 1984;13:112–120
32. Marshall LL, Trethewie ER, Curtain CC. Chemical radiculitis: a clinical, physiological and immunological study. *Clin Orthop Relat Res* 1977;129:61–67

33. Rydevik B, Brown MD, Ehira T, Nordborg C, Lundborg G. Effects of graded compression and nucleus pulposus on nerve tissue: an experimental study in rabbits. *Acta Orthop Scand* 1983;54:670–671
34. Rasminsky M. Ectopic generation of impulses in pathological nerve fibers. In: Jewett DL, McCarroll HR, eds. *Nerve repair and regeneration: its clinical and experimental basis.* St. Louis: Mosby, 1980: 178–185
35. Smyth MJ, Wright V. Sciatica and the intervertebral disc: an experimental study. *J Bone Joint Surg (Br)* 1958;40:1401–1418
36. Rydevik B, Holm S, Brown MD, Lundborg G. Nutrition of spinal nerve roots: the role of diffusion from the cerebrospinal fluid. *Trans Orthop Res Soc* 1984;9:276
37. Breig A, Marions O. Biomechanics of the lumbosacral nerve roots. *Acta Radiol* 1963;1:1141–1160
38. Ransford AO, Harries BJ. Localised arachnoiditis complicating lumbar disc lesions. *J Bone Joint Surg* 1972;54B:656–665
39. Sparrow JR, Kiernan JA. Endoneurial vascular permeability in degenerating and regenerating peripheral nerves.*Acta Neuropathol (Berl)* 1981;53:181–188
40. Weerasuriya A, Rapoport SI, Taylor RE. Perineurial permeability increases during Wallerian degeneration. *Brain Res* 1980;192: 581–585