

Are your **MRI contrast agents** cost-effective?

Learn more about generic **Gadolinium-Based Contrast Agents**.



FRESENIUS
KABI

caring for life

AJNR

Migration of luque rods through a laminectomy defect causing spinal cord compression.

D J Quint and G Salton

AJNR Am J Neuroradiol 1993, 14 (2) 395-398

<http://www.ajnr.org/content/14/2/395>

This information is current as
of April 17, 2024.

Migration of Luque Rods through a Laminectomy Defect Causing Spinal Cord Compression

Douglas J. Quint¹ and Greg Salton¹

Summary: Internal fixation of traumatic spinal injuries has been associated with spinal canal stenosis, spinal cord compression, and nerve root impingement. We present a case of spinal cord/cauda equina compression due to migration of intact, anchored thoracolumbar Luque rods into the spinal canal through a laminectomy defect, leading to neurologic complications 10 years after the original operation.

Index terms: Spine, surgery; Spinal cord, compression; Cauda equina, compression

Internal fixation (instrumentation) of the spinal column is performed to correct scoliosis and/or kyphosis, and also for stabilization of vertebral fractures, spondylolisthesis, tumors, and after posterior laminectomies. While both sublaminar hooks and wires and broken rods have been associated with spinal canal stenosis and/or spinal root compression, we present a case of spinal cord/cauda equina compression due to migration of intact, appropriately anchored Luque rods into the spinal canal through a laminectomy defect, leading to neurologic complications 10 years after the original operation.

Case Report

In 1981, a 26-year-old man suffered an L1 vertebral body compression fracture-dislocation in association with multiple other injuries in a motor vehicle accident in which he was an unrestrained passenger. He lost most of the motor and sensory function in his left leg and some of the motor function in his right leg. Emergent decompressive surgery performed at that time revealed a traumatic dural laceration with associated transection of approximately 40% of the cauda equina nerve roots (majority on the left side), with the remaining roots appearing intact but severely traumatized. No definite conus medullaris abnormalities were seen. Decompression with posterior laminectomy at the L1 level was performed. Stabilization of the spine was achieved via posterior spinal fusion with Luque rod placement and sublaminar wiring from T9 to L3 (Figs. 1A and

1B). Over the next several months the patient regained most of his right leg motor function. His left leg paralysis persisted, but eventually he was able to walk with a left leg brace and a crutch.

Over the next 9 years, the patient was followed regularly in the orthopedic department. During this time, thoracolumbar kyphosis centered at the L1 level was noted, but was not considered significant as it was not associated with new symptoms. However, over a 3-week period in March 1991, the patient began experiencing increasing difficulty walking associated with frequent falling episodes. He also reported progressive right leg and lower back pain. A neurologic examination revealed right dorsiflexor, hallucis longus, and hip flexor weakness, and patchy decreased sensation to pinprick in the right lower extremity up to the L1 level. Right foot proprioception was poor. Sacral sensation was markedly decreased on the right side. Fasciculations were noted in the right quadriceps and anterior tibial muscle groups. These findings were suggestive of multiple nerve root (cauda equina) and/or spinal cord (conus medullaris) compression. Lateral flexion-extension radiographs revealed a 50° kyphosis centered at the L1 level. Review of serial lateral radiographs (Figs. 1B–1D) demonstrated a progressive retrolisthesis at the T12 level associated with a kyphosis that increased from 25° to 50° over 10 years.

A thoracolumbar myelogram and a postmyelogram computed tomography (CT) (Figs. 1D and 1E) revealed a severe compression fracture of L1, a moderate compression fracture of T12, a retrolisthesis at the T12/L1 level, and two intact thoracolumbar Luque rods with associated intact wires. A complete posterior extradural block to the caudal flow of contrast at the T12/L1 level was seen. Postmyelogram CT (Fig. 1E) revealed severe anteroposterior narrowing of the spinal canal with thecal sac compression at the L1 level due to the Luque rods within the posterior aspect of the spinal canal superimposed on the retrolisthesis at this level. Surgery confirmed that the Luque instrumentation had entered the spinal canal through the laminectomy defect as the patient's kyphosis had progressed. The Luque rods and sublaminar wires were removed, the posterior bony fusion mass freed, and, at a second operation performed 1 month later, an anterior

Received March 17, 1992; revision requested May 12; revision received June 10 and accepted June 15.

¹ Department of Radiology, BID530H, Neuroradiology, Box 30, University of Michigan Hospitals, 1500 East Medical Center Drive, Ann Arbor, MI 48109-0030. Address reprint requests to Douglas J. Quint.

AJNR 14:395–398, Mar/Apr 1993 0195-6108/93/1402-0395 © American Society of Neuroradiology

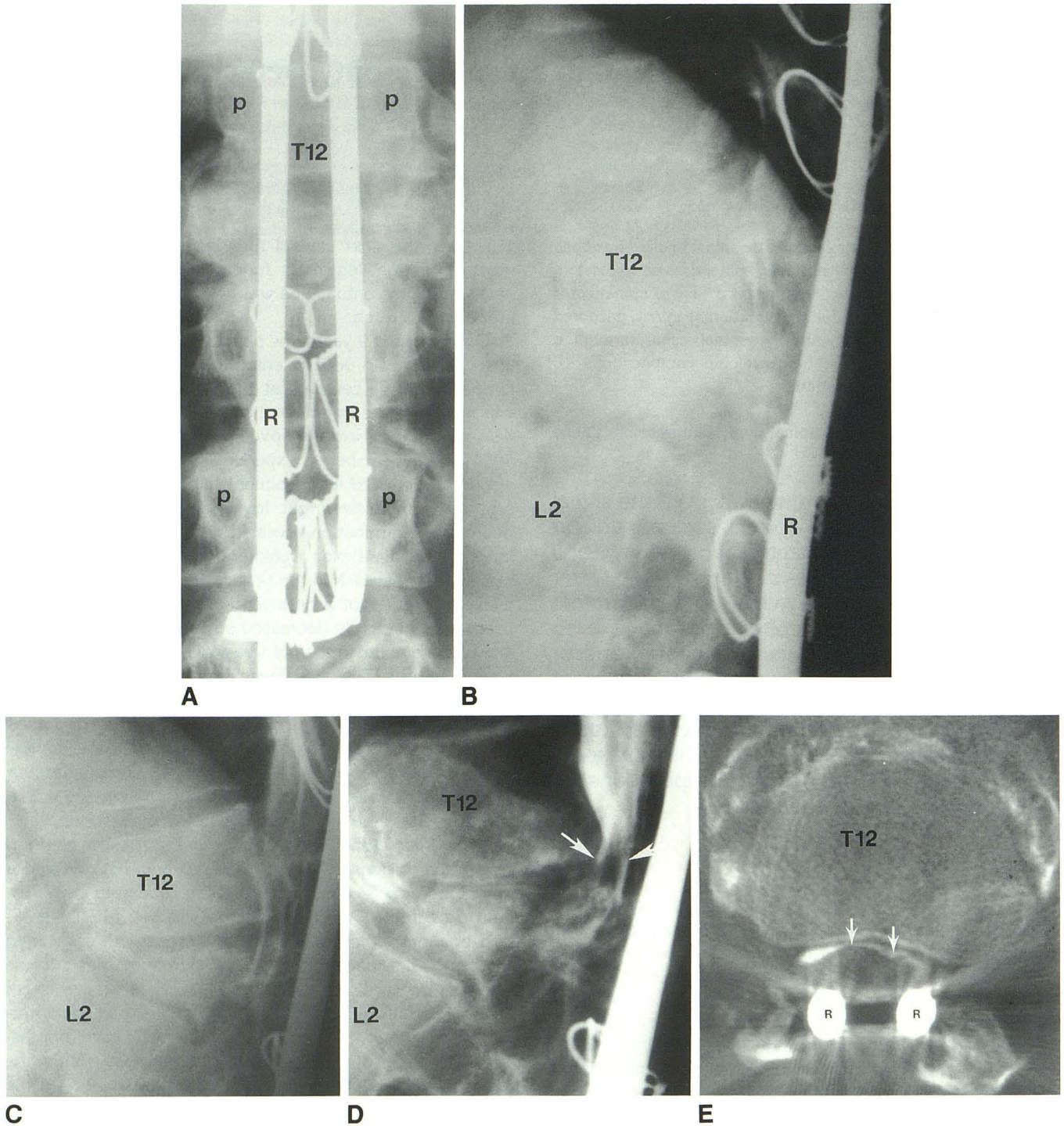


Fig. 1. Twenty-six-year-old man 10 years after traumatic L1 compression fracture treated by L1 laminectomy and bony posterior spinal fusion with Luque rod instrumentation. Immediate postoperative anteroposterior radiograph of the spine (A) demonstrates two Luque rods that are appropriately anchored, but are located in a more medial than usual position (medial to the pedicles) such that they appear to overlie the laminectomy defect. Kyphosis (as measured from the superior end plate of T11 to the inferior end plate of L2) centered at the L1 level progressed from 22° in 1982 (B) to 40° in 1985 (C) to 50° in 1990. Progressive retrolisthesis of T12 is also noted. Myelogram (D) with postmyelogram CT (E) in March 1991 redemonstrates the 50° kyphosis and shows migration of the Luque rods into the spinal cord canal through the laminectomy defect causing a posterior extradural myelographic block and thecal sac compression. (L2 = L2 vertebral body; P = pedicle; R = Luque rod; T12-T12 vertebral body; arrows = compressed thecal sac.)

spinal fusion with anterior plate placement (Zielke instrumentation) from T11 to L2 was performed.

Postoperatively, the patient experienced some reduction in the pain and dysesthesias in his right leg, with some residual numbness in his right foot. While he has continued to experience thoracolumbar back pain, a repeat CT scan 5 months later demonstrated the spinal canal to still be widely patent.

Discussion

A wide variety of procedures and hardware can be used for internal fixation of the spine in cases of scoliosis, kyphosis, and vertebral fractures. For example, fracture-dislocations are often stabilized using distractive forces (Harrington or Jacob rods and hooks or other "locking hook" spinal rods), and scoliosis can be treated with distractive forces (Harrington rods), compressive forces (Zielke or Dwyer instrumentation), or predominantly lateral forces (sublaminar or intraspinous wiring combined with supporting rods (Luque rods) or interpeduncular plates and screws). The choice of instrumentation in these patients is often one of surgeon preference, but also depends on the degree of scoliosis and/or kyphosis, whether an anterior or posterior approach to the spine is planned, and which spinal region is being treated.

While internal fixation devices provide many therapeutic benefits, neurologic complications of such instrumentation can occur years after surgery. Complications of internal fixation of the spine that can lead to compromise of spinal canal structures include: 1) fixation rod and/or wire breakage with either direct impingement on the thecal sac by these broken pieces of hardware or compression of the thecal sac secondary to progressive kyphosis in the region of the failed instrumentation, 2) impingement on the thecal sac by intact rod hooks or wires, 3) pseudoarthrosis with associated fixation rod failure, and 4) degenerative spondylostenosis at the level of posterior spinal fusion and rod placement (1-3).

In patients treated with spinal fixation instrumentation for stabilization of vertebral fractures, laminectomies have often been performed to provide spinal cord decompression. However, several authors have suggested that laminectomy is rarely indicated, and should be performed only in cases of spinal stenosis due to spondylosis with resultant ligamentum flavum hypertrophy and/or osteophyte formation in the region of the posterior elements (4). In our patient, the laminectomy resulted in the posterior defect through which, over time, as the patient's kyphosis pro-

gressed, the Luque rods migrated into the spinal canal, ultimately causing compression of the thecal sac. While the Luque rods appear to have initially been positioned too medially directly over the laminectomy (Fig. 1A), predisposing them to anterior migration, the rod migration obviously would not have occurred had the posterior elements been intact.

Spinal instrumentation is often used in the clinical setting of vertebral fractures for stabilization of the spine, permitting early patient mobilization. Willén (5) studied spinal morphology by CT both before and after Harrington rod implantation in patients with unstable thoracolumbar fractures, and noted that while the width of the spinal canal is significantly increased after hardware installation, the midsagittal diameter and cross-sectional area of the spinal canal were decreased by an average of 26% after surgery. Thus, in the treatment of fractures with Harrington instrumentation, one must be aware that bone fragments may compress the region of the thecal sac despite good overall spinal alignment (6). Verbiest (7) reported that midsagittal diameters of 10 mm or less may lead to compression of the cauda equina, despite an overall normal spinal canal cross-sectional area. Therefore, even slight degenerative changes in patients whose vertebral fractures have been stabilized by internal fixation may lead to spinal compromise (7).

Neurologic complications associated with wire breakage in spines treated with internal fixation have been reported (8), as dural indentation by the broken wires has been shown. Frank breakage of rods is also not uncommon. There have been multiple reports (9, 10) of neurologic complications secondary to direct Harrington hook impingement on the thecal sac, with and without associated dural tears. These patients present days to years after operation, with neurologic symptoms ranging from parasthesias and pain to weakness and incontinence.

In conclusion, there are several known complications of the various types of spinal internal fixation devices that can result in neurologic findings years after spinal instrumentation. However, there is to our knowledge no report of neurologic symptoms secondary to compression of spinal canal structures due to the migration of intact, appropriately anchored instrumentation rods into the spinal canal with resultant thecal sac compression. This complication could not have occurred had the posterior vertebral elements been intact. This case stresses the importance of

reserving the procedure of laminectomy for those cases in which it is truly indicated, and of careful review of serial lateral spine radiographs to identify changes (eg, progressive kyphosis, retrolisthesis) that may only become evident over a long period of time. In patients who have undergone laminectomy with Luque rod instrumentation, any progressive kyphotic deformity of the spine, even if asymptomatic, should be further evaluated. As was the case in this patient, myelography with postmyelogram CT is the imaging exam of choice for demonstration of impingement on the spinal canal by instrumentation, as spinal hardware, while often magnetic resonance compatible, results in local artifacts on magnetic resonance scans that will obscure regions of interest.

References

1. Eismont FJ, Simeone FA. Bone overgrowth (hypertrophy) as a cause of later paraparesis after scoliosis fusion: a case report. *J Bone Joint Surg (Am)* 1981;63-A:1016-1019
2. Quencer RM, Murtagh FR, Post JD, Rosomoff HL, Stokes NA. Postoperative bony stenosis of the lumbar spinal canal: evaluation of 164 symptomatic patients with axial radiography. *AJR* 1978;1059-1064
3. Kornberg M, Harndon WA, and Rehtine GR. Lumbar nerve root compression at the site of Hook insertion: late complications of Harrington rod instrumentation for scoliosis. *Spine* 1985;10:853-855
4. Meyer PR, Cotler HB. Traumatic spine injuries in spine fusion. In: Cotler JM, Cotler HB, eds. *Spinal fusion: science and technique*. New York: Springer-Verlag, 1990
5. Willén J, Lindhal S, Irstam L, et al. Unstable thoracolumbar fractures: a study by CT and conventional roentgenology of the reduction effect of Harrington instrumentation. *Spine* 1984;9:214-219
6. Quencer RM, Montalvo BM, Eismont FJ, Green BA. Intraoperative spinal sonography in thoracic and lumbar fractures: evaluation of Harrington rod instrumentation. *AJR* 1985;145:343-349
7. Verbiest H. The significance and principles of computerized axial tomography in idiopathic developmental stenosis of the bony lumbar vertebral canal. *Spine* 1979;4:368-378
8. Bernard TN, Johnston CE, Roberts JM, et al. Late complications due to wire breakage in segmental spinal instrumentation. *J Bone Joint Surg (Am)* 1983;65-A:1339-1345
9. Bowen JR, Ferrer J. Spinal stenosis caused by a Harrington hook in neuromuscular disease: a case report. *Clin Orthop* 1983;180:179-181
10. Rossier AB, Cochran TP. The treatment of spinal fractures with Harrington compression rods and segmental sublaminar Wiring: A dangerous combination. *Spine* 1984;9:798-799