

The **next generation** GBCA
from Guerbet is here

Explore new possibilities >

Guerbet | 

© Guerbet 2024 GUOB220151-A

AJNR

Pseudoaneurysm of the internal carotid artery: complication of deep neck space infection.

J Krysl, L Noël de Tilly and D Armstrong

AJNR Am J Neuroradiol 1993, 14 (3) 696-698

<http://www.ajnr.org/content/14/3/696>

This information is current as
of March 20, 2024.

Pseudoaneurysm of the Internal Carotid Artery: Complication of Deep Neck Space Infection

J. Krysl,¹ L. Noël de Tilly,² and D. Armstrong³

Summary: The authors describe a patient with a pseudoaneurysm of the internal carotid artery secondary to cervical adenitis.

Index terms: Aneurysm, arteriovenous; Neck, infection; Pediatric neuroradiology

Complication of neck space infections has become much less common in the antibiotic era (1). Vascular complications of such infections are rare, but their recognition remains imperative to ensuring adequate and prompt treatment. We present a case report of a patient with a pseudoaneurysm of the internal carotid artery secondary to cervical adenitis.

Case Report

The patient, a 3-year-old girl, presented with a right neck mass and soreness of 2 weeks duration. A diagnosis of cervical adenitis was made and the child was treated with intravenous antibiotics. Clinical improvement with partial resolution of the mass followed and the patient was discharged from hospital. While at home on oral antibiotics, the child developed minimal hematemesis and returned to the hospital where a fluctuant, tender right neck mass was again noted. She was irritable and febrile and had a leukocytosis. Treatment with intravenous antibiotics was instituted for cervical adenitis. In hospital, the child improved and the mass again substantially resolved; the patient was discharged on oral antibiotics. Two days later, the hematemesis and right neck mass recurred. In light of the recurrent episodes of bleeding, the child was referred to a tertiary-care pediatric hospital.

Upon admission of the patient to the referral hospital, a right-sided, nonfluctuant neck mass approximately 3 cm in size with induration was noted in the region of the deep cervical nodes. No bruit was heard. There was no coagulopathy and the hemoglobin remained stable.

Computed tomography (CT) demonstrated a large irregular hypodense collection in the right parapharyngeal space

at the level of the second to sixth cervical vertebrae. The mass displaced the pharyngeal constrictors medially and anteriorly. Marked distortion of the airway was also noted. Intense enhancement in the central portion of the collection was seen (Fig. 1). As a result, the diagnosis of cervical adenitis complicated by a pseudoaneurysm of the internal carotid artery was considered and the child underwent carotid angiography.

The carotid angiogram demonstrated a 5 to 6-cm aneurysmal collection just distal to the origin of the right internal carotid artery (Fig. 2). Turbulent flow was present and contrast persisted in the area of the dilatation beyond the arterial phase of the angiogram. Study of the left internal carotid artery demonstrated the presence of crossover flow with filling of the right anterior and middle cerebral arteries.

A diagnosis of pseudoaneurysm of the right internal carotid artery was made and the child taken to the operating room. The right common carotid artery was identified, was noted to have an edematous and inflamed adventitia, and was then ligated proximal to its bifurcation. Further blunt dissection released pus from the soft tissues. Bacterial cultures grew *Streptococcus anginosus* (an α -hemolytic streptococcus) as well as mixed respiratory anaerobic flora.

Follow-up CT done 1 week postoperatively demonstrated a persistent irregular, hypodense collection that had reduced in size since the preoperative scan. The right common carotid artery was thrombosed above the ligation to its bifurcation.

With continued antibiotic therapy the child recovered. The neck mass resolved and there was no further hemoptysis. The child was discharged home without neurologic deficit.

Discussion

Cervical adenitis is a common disease of childhood. Etiologic agents include a variety of bacteria, viruses, and other unusual pathogens. Bilateral cervical adenitis is most often viral; unilateral cervical lymphadenitis is most often bacterial. *Staphylococcus aureus*, group A streptococci,

Received June 2, 1992; accepted after revision September 3.

¹ Department of Radiologic Sciences, Sunnybrook Health Sciences Centre, 2075 Bayview Avenue, Toronto, Ontario, Canada, M4N 3M5.

² Department of Radiology, St. Michael's Hospital, 30 Bond Street, Toronto, Ontario, Canada, M5B 1W8.

³ Department of Paediatric Neuroradiology, Hospital for Sick Children, 555 University Avenue, Toronto, Ontario, Canada, M5G 1X8. Address reprint requests to Dr D. Armstrong.

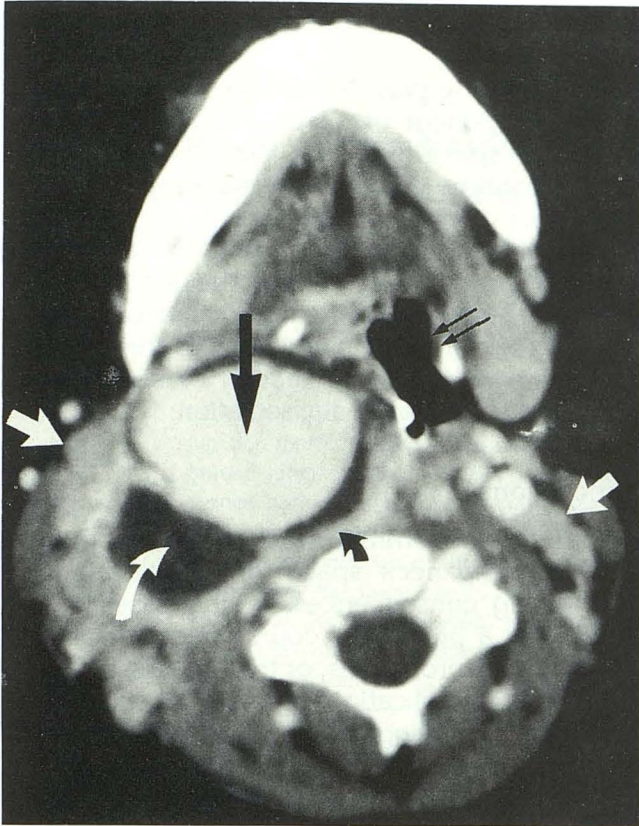


Fig. 1. Enhanced CT scan of the neck. There is a large right parapharyngeal space mass characterized by a thin, uniform, enhancing rim (*curved black arrow*), a central area of necrosis (*straight black arrow*), and low attenuation material filling the intervening space (*curved white arrow*). The internal jugular vein and internal carotid artery are not clearly identified. There is narrowing of the airway (*thin black arrows*) secondary to the mass effect from the process and bilateral cervical adenopathy is present (*straight white arrows*).

and *Haemophilus influenza* are the more common pathogenic bacteria (1).

The incidence of complications of deep neck space infections has dramatically decreased with the institution of antibiotic therapy (2, 3). These include airway compromise and vascular complications, including septic thrombophlebitis of the jugular vein and carotid artery pseudoaneurysms. Neurologic sequelae have also been described, including Horner syndrome and cranial nerve palsies. Trismus caused by pterygoid muscle spasm may also occur (2-5).

The complications of deep neck space infections are all related to the regional anatomic structures. The fascial compartments of the neck do not provide anatomic barriers per se and hence infection can spread from one compartment to another (1). Such spread can then lead to involvement of the parapharyngeal space, potentially

jeopardizing vascular channels (the jugular vein and carotid system) as well as neural pathways (cranial nerves 9 to 12 and the sympathetic plexus) (1, 5).

The incidence of internal carotid artery aneurysm and hemorrhage has been documented in the otolaryngology and radiology literature (6, 7). The recognition of complicated cervical lymphadenitis (as well as other complicated deep neck space infections) is paramount for the prompt evaluation and treatment of these patients. In their review of hemorrhage caused by pharyngeal and peritonsillar abscesses, Salinger and Pearlman demonstrated the need for prompt therapy with ligation of a major vessel (6). Of the group that did not undergo ligation, only 36 of 154

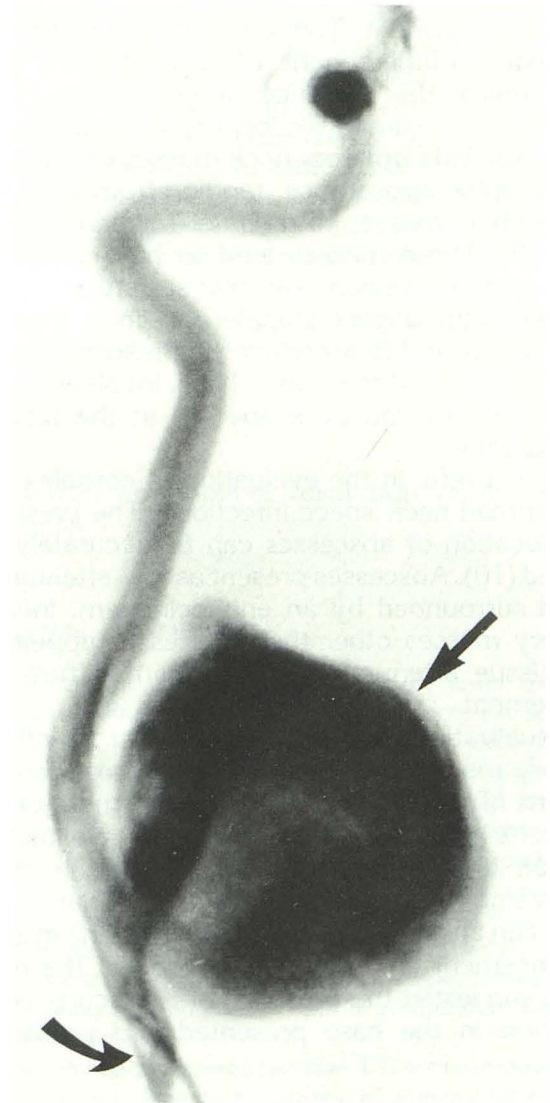


Fig. 2. Selective right internal carotid angiogram, frontal projection. There is a large pseudoaneurysm (*straight arrow*) at the origin of the internal carotid artery (*curved arrow*).

patients (23%) survived whereas of the 72 patients who underwent ligation of a major artery 47 survived (65%) (6).

Several clinical findings have been reported by Alexander et al (2) to accompany vascular (arterial) complications of deep neck space infections. These included recurrent small hemorrhages (which may be from the ear, the nose, or the throat) (8); protracted clinical course (usually greater than 7 to 14 days); and presentation with shock. Also, at the time of surgery, hematoma in the surrounding tissues may be found (2). In her review of the subject in 1990, Stevens included cranial neuropathies and Horner syndrome as well as trismus as potential indicators of vascular complications of infections (8).

Imaging of these patients plays a major role in their management. The use of plain radiographs is usually of little benefit. Ultrasound of the neck may reveal the presence of lymphadenopathy and define the anatomic location and relations of the mass. Inflammatory neck masses vary in their sonographic appearance, ranging from relatively hypoechoic masses to areas of mixed echogenicity (9). These masses tend to have increased through transmission. Vascular structures can be imaged with duplex Doppler or color Doppler flow ultrasound to ascertain the presence of flow within or around the mass. Thus, involvement of major vessels can be suspected at the time of sonography.

CT is useful in the evaluation of complex and widespread neck space infections. The presence and location of abscesses can be accurately assessed (10). Abscesses present as low-attenuation areas surrounded by an enhancing rim. Inflammatory masses other than abscesses appear as soft-tissue attenuation masses with diffuse enhancement.

Visualization of structures adjacent to inflammatory masses permits the diagnosis of complications of cervical infections. Involvement of the adjacent bony structures with osteomyelitis, extension into other compartments of the neck, involvement of the airway, and vascular structures can all be visualized by CT (10). The intense enhancement of the central portion of the neck mass suggested the presence of a vascular complication in the case presented and prompted

further evaluation with angiography and subsequent surgery.

Angiography plays a key role in the diagnosis and management of vascular complications of deep neck space infections. Vascular involvement can be confirmed and the vessel involved identified. Most commonly, the internal carotid artery is involved, although the common carotid and external carotid artery can also be affected (6). In addition, cerebral angiography will allow evaluation of the collateral circulation in the circle of Willis, as well as the detection of septic aneurysms in the intracranial circulation.

Conclusions

Although uncommon, the vascular complications of deep neck space infections can have devastating consequences. In the cases of patients with a protracted course, recurrent bleeding, cranial neuropathies, or trismus, the presence of vascular complications must be considered and appropriate imaging carried out to allow the localization of the infection and to ascertain the status of the vessels in the neck. Prompt diagnosis and treatment of these patients is necessary to prevent significant hemorrhagic complications.

References

1. Odell PF. Infections of the fascial spaces of the neck. *J Otolaryngol* 1990;19:201-205
2. Alexander DW, Leonard JR, Trail ML. Vascular complications of deep neck abscess: a report of four cases. *Laryngoscope* 1968;78:361-370
3. Eneroth CM, Tham R. Pseudoaneurysm of the internal carotid artery: a warning of septic erosion. *Acta Otolaryngol* 1971;72:445-450
4. Metson BF. Hemorrhage of the internal carotid artery secondary to deep neck abscess. *Ann Otol Rhinol Laryngol* 1956;65:218-224
5. Blum DJ, McCaffrey TV. Septic necrosis of the internal carotid artery: a complication of peritonsillar abscess. *Otolaryngol Head Neck Surg* 1983;91:114-118
6. Salinger S, Pearlman SJ. Hemorrhage from pharyngeal and peritonsillar abscesses. *Arch Otolaryngol* 1933;18:464-509
7. Wells RG, Sty JR. Cervical lymphadenitis complicated by mycotic carotid artery aneurysm. *Pediatr Radiol* 1991;21:402-403
8. Stevens HE. Vascular complications of neck space infection: case report and literature review. *J Otolaryngol* 1990;19:206-210
9. Kraus R, Han BK, Babcock DS, Oestreich AE. Sonography of neck masses in children. *AJR: Am J Roentgenol* 1986;146:609-613
10. Nyberg DA, Brooke Jeffrey R, Brant-Zawadzki M, Federle M, Dillon W. Computed tomography of cervical infections. *J Comput Assist Tomogr* 1985;9:288-296