

Are your **MRI contrast agents** cost-effective?

Learn more about generic **Gadolinium-Based Contrast Agents**.



FRESENIUS  
KABI

caring for life

**AJNR**

**Kallmann syndrome: MR findings.**

J R Knorr, R L Ragland, R S Brown and N Gelber

*AJNR Am J Neuroradiol* 1993, 14 (4) 845-851

<http://www.ajnr.org/content/14/4/845>

This information is current as  
of April 17, 2024.

# Kallmann Syndrome: MR Findings

John R. Knorr,<sup>1</sup> Ronald L. Ragland,<sup>1</sup> Rosalind S. Brown,<sup>2</sup> and Nicholas Gelber<sup>1</sup>

**PURPOSE:** To evaluate patients with known hypogonadotropic hypogonadism, some with known anosmia, for defective rhinocephalon development that resulted in olfactory tract abnormalities, an affliction known as Kallmann syndrome. **METHODS:** Six patients who clinically had hypogonadotropic hypogonadism were examined by MR. Thin coronal images of the inferior frontal region were used to determine presence or absence of olfactory tract and to evaluate the olfactory sulci. **RESULTS:** Olfactory tracts were not seen in three of the six cases; two of which had hypoplastic olfactory sulci. **CONCLUSIONS:** T1-weighted MR examination of the inferior frontal region in the coronal plane can help determine whether a patient with hypogonadotropic hypogonadism, with or without clinically evident anosmia, is afflicted with Kallmann syndrome.

**Index terms:** Kallmann syndrome; Nervous system, disease; Olfactory lobe; Brain, magnetic resonance; Brain, growth and development

AJNR 14:845-851, Jul/Aug 1993

Kallman syndrome is a form of congenital hypogonadotropic hypogonadism with accompanying hyposomia or anosmia (1). Its reported incidence is on the order of 1 in 10,000 men and 1 in 50,000 women (2). This disease is believed to be due to defective rhinocephalon development, which results in hypoplasia or absence of olfactory tract development (3). We used magnetic resonance (MR) imaging to visualize the olfactory tracts and to evaluate the olfactory sulci in patients with this abnormality.

## Materials and Methods

We examined six patients who appeared clinically to have hypogonadotropic hypogonadism and anosmia, and had a family history of Kallmann syndrome. The standard examination included sagittal T1-weighted and axial double-echo T2-weighted images (for example, conventional spin-echo [CSE] 400/11 (repetition time/echo time) and 2500/30 and 80, respectively). However, an additional sequence was performed on each patient to evaluate the

olfactory sulcus region further and to determine the presence of the olfactory tract. Three-millimeter section thickness with T1-weighted technique (for example CSE 800/12) images were obtained through the frontal lobe region (see Fig. 1). Scans were performed on a 1.5-T system. The images were evaluated by two neuroradiologists for the appearance of the olfactory sulci as well as visualization of the olfactory tracts (see Fig. 1). The coronal plane was chosen for evaluation because the structures of interest are well seen in this plane, and volume averaging, even with 3-mm section thickness, could not obscure them. As the authors were unaware of a standard of depth for the olfactory sulci, olfactory sulcus depth was compared with that of other sulci visualized in the same patient.

## Results

The clinical and radiologic findings are displayed in Table 1.

### Case 1

The patient presented at age 16 years with short stature and delayed puberty. He was the product of a difficult delivery and clinically had severe neonatal asphyxia. He also had severe hydrops and hyperbilirubinemia, presumed to be due to Rh incompatibility, requiring three exchange transfusions. As a child, he had delayed milestones, such as not walking or talking until 2 years of age, although it was not immediately clear whether this was related to his neonatal illnesses.

---

Received Aug. 12, 1992; revision requested Sept. 17; final revision received Jan. 19, 1993 and accepted Jan. 26.

Departments of Radiology<sup>1</sup> and Pediatric Endocrinology,<sup>2</sup> University of Massachusetts Medical Center, Worcester, MA 01655.

Address reprint requests to: John R. Knorr, D.O., Department of Radiology, University of Massachusetts Medical Center, 55 Lake Avenue North, Worcester, MA 01655

AJNR 14:845-851, July/Aug 1993 0195-6108/93/1404-0845

© American Society of Neuroradiology



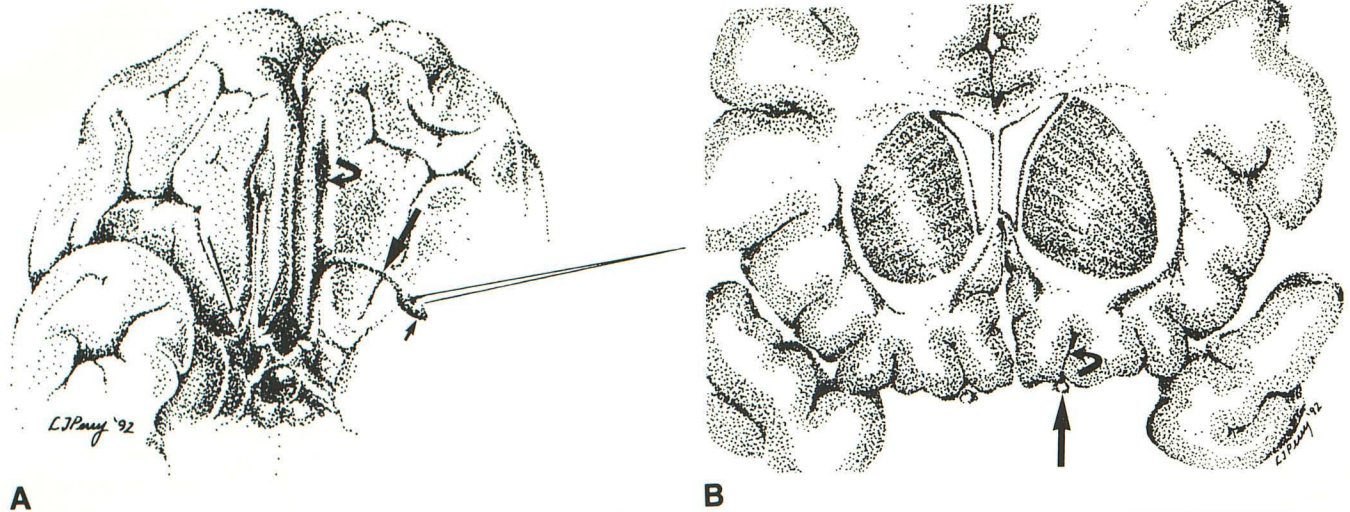
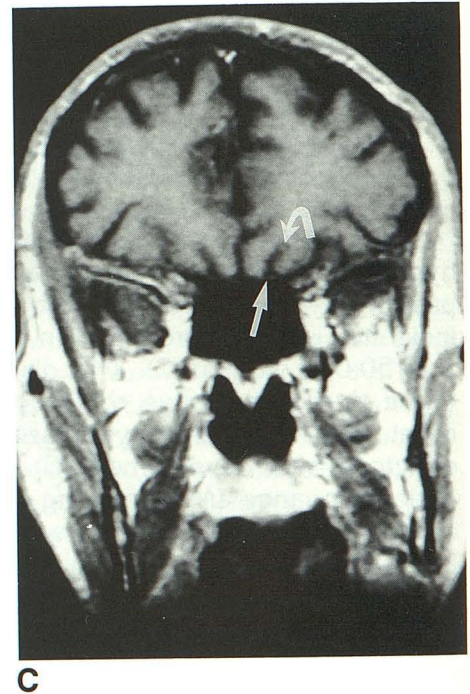


Fig. 1. A, Anatomic drawing of external view of the inferior frontal region.

B, Anatomic drawing of coronal section.

C, Normal coronal T1-weighted (SE 800/12) MR image.

The left olfactory bulb has been retracted in the drawing (A, *small arrow*). The olfactory tract (*large arrow*) is seen on each image. The medial olfactory stria (*curved arrow*) and lateral olfactory stria (*long arrow*) are seen in A.



On presentation, his height was below the fifth percentile, and weight was between the tenth and twenty-fifth percentiles. His penis was small, and his scrotum undervirilized. He remained cryptorchid, although small testes (5 mm) were thought palpable in the inguinal canals. He was unable to perceive the odor of peppermint or lemon oil.

The patient was placed on monthly testosterone and synthetic thyroid hormone therapy and achieved full puberty after 4 years.

An MR examination of the brain was tailored to the inferior frontal lobes (Fig. 2). Hypoplastic and small olfactory sulci were noted. The olfactory tracts and bulbs were not seen. The pituitary gland was normal.

#### Case 2

The patient presented at 18 years of age with short stature and delayed puberty. His family history was notable for a maternal grandmother who had anosmia, which she thought due to chronic "sore throat." A maternal great uncle never developed puberty and had no children. A maternal aunt had a son with retardation, hypogonadism, anosmia, and an undefined renal affliction. Another maternal aunt bore a son with cryptorchism, hypogonadism, and mental retardation.

The patient's height and weight were below the fifth percentile for his age. His penis was



TABLE 1: Radiographic and clinical findings

	Case 1	Case 2	Case 3	Case 4	Case 5	Case 6
Radiographic findings						
Visualization of olfactory tracts	No	Yes	Yes	No	Yes	No
Appearance of olfactory sulci	Hypoplastic	Indistinct	Severely hypoplastic	Hypoplastic	Hypoplastic	Normal
Appearance of pituitary	Normal	Normal	Normal	Normal	Normal	Normal
Clinical findings						
Cryptorchid	Yes	Yes	No	Left	No	No
Penis	Prepubertal <sup>a</sup>	Prepubertal <sup>a</sup>	Microphallus	Small	Normal	Prepubertal <sup>a</sup>

<sup>a</sup> Past expected age of puberty.

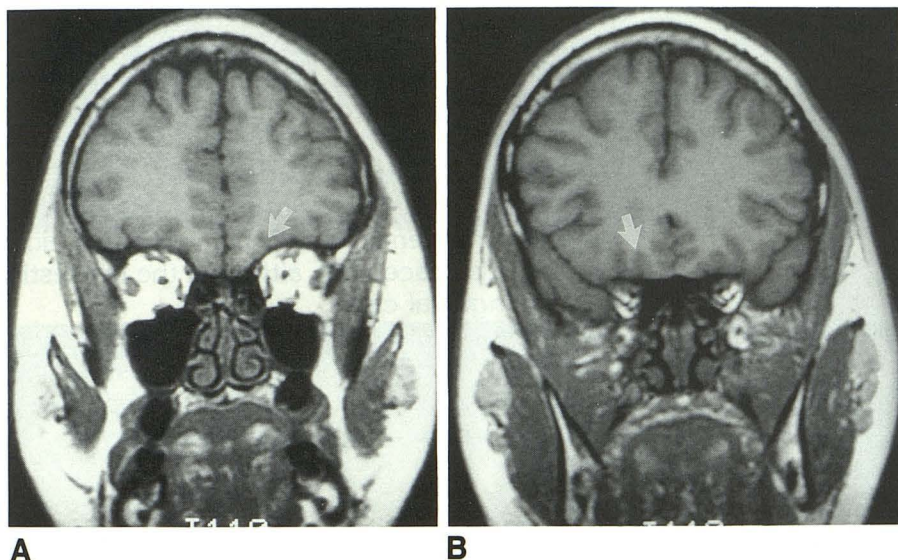


Fig. 2. Coronal T1-weighted (SE 500/11) MR images (A and B) of patient 1 demonstrate hypoplastic and small olfactory sulci (arrows). The olfactory tracts and bulbs are not seen. The pituitary gland (not shown) was of normal size and configuration.

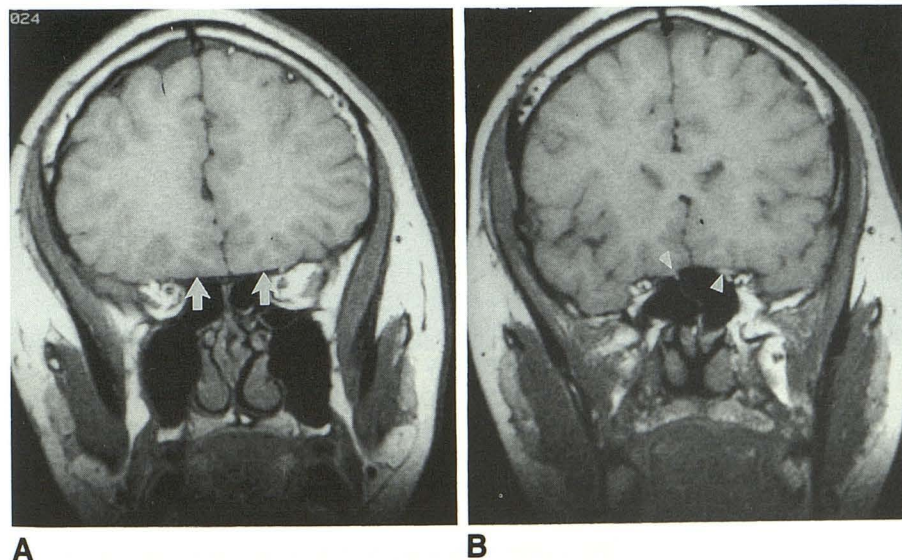


Fig. 3. Coronal T1-weighted (SE 600/20) MR (A) of patient 2 demonstrated small and indistinct olfactory sulci, smaller than in a healthy patient of this age (arrows). In B, the olfactory tracts were visible (arrowheads). Incidental note was made of a choroidal fissure arachnoid cyst. The pituitary gland was normal in appearance (not shown).

prepubertal but normal, and the testes were prepubescent and within the inguinal canal.

Laboratory testing revealed depression of testosterone, luteinizing hormone, follicle-stimulat-

ing hormone, total thyroxine, and free thyroxine index.

An MR examination (Fig. 3) demonstrated small and indistinct olfactory sulci; however, ol-



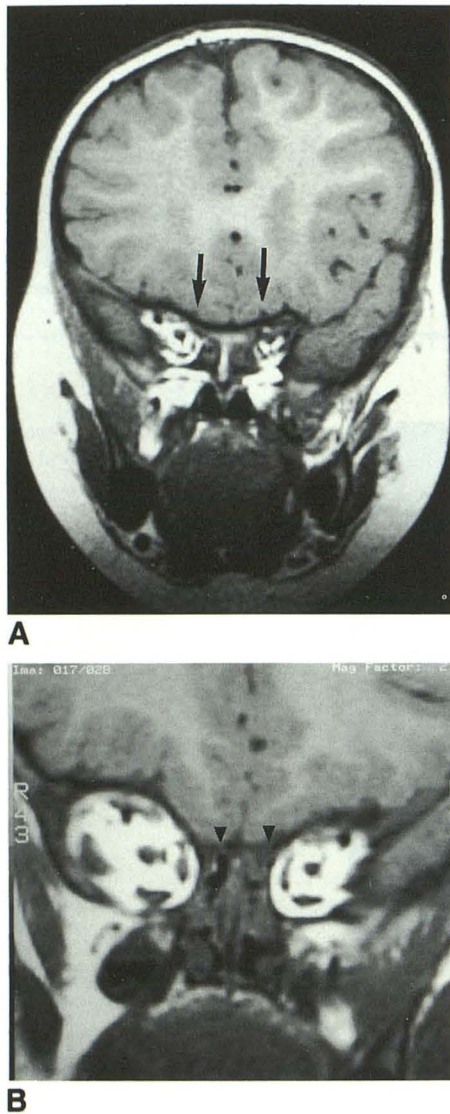


Fig. 4. Coronal T1-weighted (SE 500/12) MR examination (A) of patient 3 showed small olfactory sulci, which suggest hypoplasia (arrows). In B, the olfactory tracts were visualized on coronal images (arrowheads).

factory tracts were visible. Incidental note was made of a choroid fissure arachnoid cyst. The pituitary gland was normal.

### Case 3

A 17-month-old boy was referred for microphallus, ichthyosis, and low thyroxine. The family history was positive for hypogonadism in male family members.

Early in life, the patient appeared healthy, aside from dry skin and microphallus. A mild developmental delay was noted at the time of presentation.

Physical exam showed body length at the twenty-fifth percentile, weight at the ninetieth percentile, and head circumference below the fifth percentile. The penis was small, and testes in the scrotum were noted. Laboratory analysis failed to demonstrate abnormalities.

An MR examination showed only a suggestion of olfactory sulci (Fig. 4A) and evidence of hypoplasia of the sulcus and cortex. The olfactory tracts were visualized on coronal images (Fig. 4B).

### Case 4

The patient, a 16-month-old boy, was referred for developmental delay and known family history of developmental delay and hypogonadism.

On exam, the patient was within the tenth percentile in body length, within the twenty-fifth percentile in weight, and below the fifth percentile in head circumference. The penis was small, and the right testis descended, although the left testis was in the inguinal canal.

The patient was examined by MR (Fig. 5) and the olfactory sulcus appeared hypoplastic. The olfactory tracts were not visualized. The pituitary gland was normal.

### Case 5

The patient presented at 2 weeks of age with dry skin and hypospadias. He had a family history of Kallmann syndrome. Physical examination demonstrated a normally active baby with good feeding activity and good energy. His length, weight, and head circumference were within the fiftieth percentile for age. Both testes were descended, and the phallus appeared normal for age. The patient's neurologic examination was normal for his age, although sense of smell could not be adequately tested.

An MR examination at age 5 weeks demonstrated olfactory sulci smaller and less developed than other nearby sulci (Fig. 6). Small structures inferior to the frontal lobe were noted and believed to be the olfactory tracts.

### Case 6

The patient presented at age 16 years because of lack of puberty and thinning of his hair. Examination revealed prepubertal genitalia and hypothalamic hypogonadotropic laboratory results. The patient was noted on testing to have anosmia.



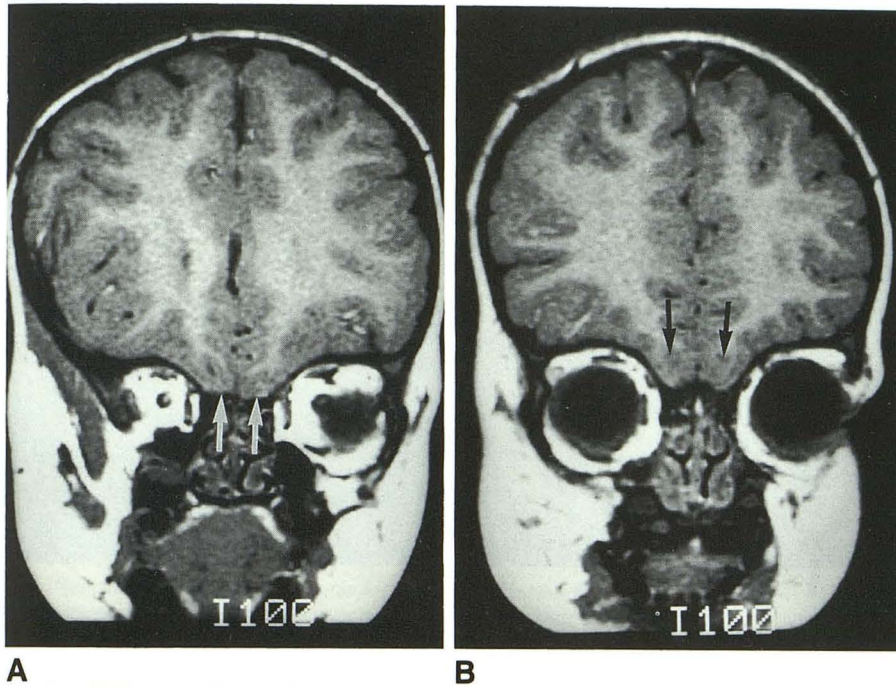


Fig. 5. T1-weighted (SE 800/12) coronal MR (A and B) of patient 4 demonstrates hypoplastic olfactory sulci (arrows). The olfactory tracts were not visualized.

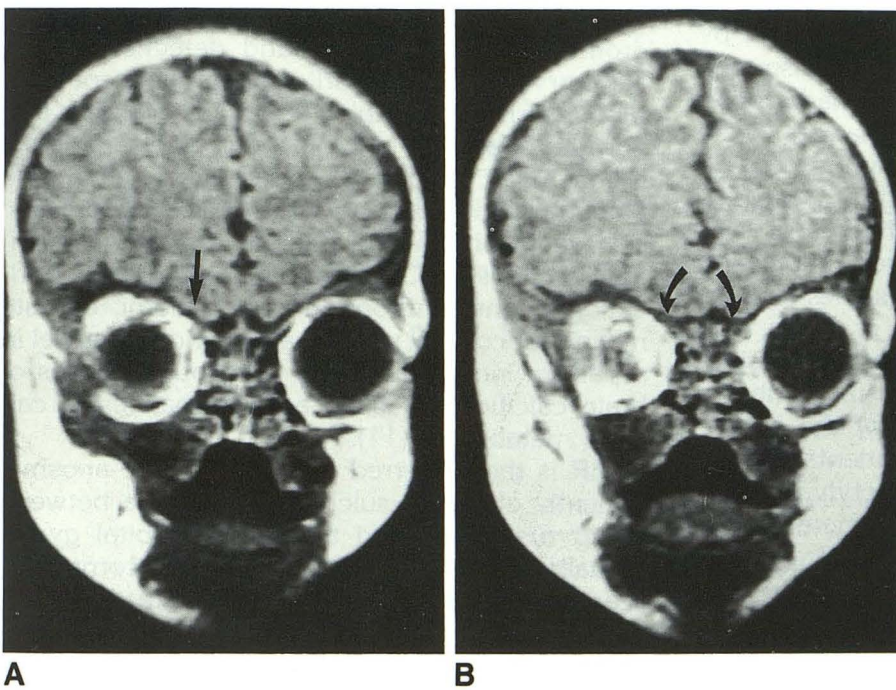


Fig. 6. T1-weighted (SE 500/11) images (A) of patient 5 at 5 weeks of age obtained in a coronal plane of the inferior frontal lobe demonstrated only small olfactory sulci, seemingly smaller and less developed than other nearby sulci (arrows). In B, small structures inferior to the frontal lobe were noted and are believed to be the olfactory tracts (curved arrows).

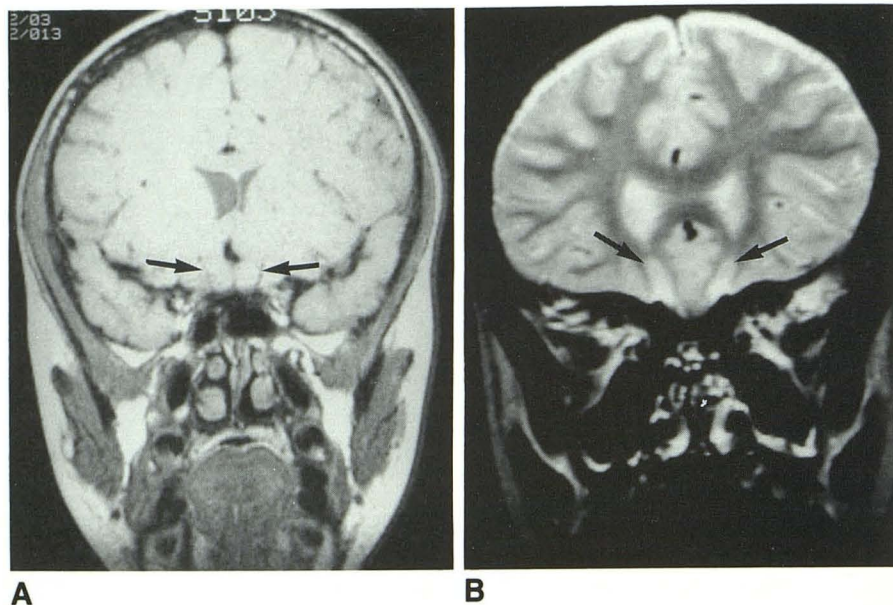
An MR examination was performed with axial, coronal, and sagittal images showing a Chiari I malformation with some compression and crowding at the foramen magnum. The pituitary gland was normal. The olfactory sulci (Fig. 7) had a normal appearance; however, the olfactory tracts were not visualized.

Hypoplasia or near absence of the sulcus was found in five of our six cases. Nonvisualization of

the olfactory tracts occurred in three of our six cases, two of which had hypoplastic olfactory sulci. The MR examination in case 6 contained coronal T2-weighted images that allowed adequate visualization of the olfactory sulci, and on proton density did not demonstrate the presence of olfactory tracts. The windowing of the image in Figure 7B was high in contrast to accentuate the olfactory sulci.



Fig. 7. A, Coronal T1-weighted (SE 800/25) and B, coronal T2-weighted (SE 2000/80) MR images of patient 6 show normal olfactory sulci (arrows). However, the olfactory tracts were not visualized.



## Discussion

The disease characterized by hypogonadotropic hypogonadism was described in 1944 by Kallmann (1), whose patient's hypogonadism was caused by decreased secretion of gonadotropin-releasing hormone. Histologic changes were noted postmortem in the hypothalamus.

Although not a constant finding, other anomalies have been reported with Kallmann syndrome, including diaphragmatic eventration, cleft palate, and cardiovascular abnormalities such as atrial septal defect, mitral valve prolapse, and right-sided aortic arch (4). Cryptorchidism, osteopenia, neurosensory hearing loss, facial abnormalities, and shortened frenulum of the tongue have been reported (5). Some patients have a high palate, clinodactyly, camptodactyly, and one or more abnormally short or long metacarpals, often a short fourth metacarpal. Renal agenesis has been closely correlated (6). Defective red-green color vision and deafness have been reported (7). Obesity is often seen in Kallmann syndrome and has been theorized as hypothalamic in origin (7).

Cryptorchidism is a common finding and is believed to be due to decreased placental gonadotropin or low fetal plasma gonadotropin concentrations (8). At birth patients usually have prepubescent levels of gonadotropins, which remain at this level past the usual age of puberty.

Kallmann noted familial clustering of cases (1). A human leukocyte antigen association has also been presented (9). Autosomal inheritance for X-linked inheritance has been theorized (4). Turner

et al reported cryptorchidism in a family with Kallmann syndrome (8).

Neuroradiologic findings in Kallmann syndrome have centered around detection of the olfactory sulcus. An earlier pneumoencephalography series by Liebich et al (7) did not find normal olfactory sulci in four such patients. Klingsmuller et al (10) found no sulci in one patient, rudimentary sulci in two, and hypoplastic sulci in the remaining patient. Reported associated findings on CT have been extensive calcification of the lentiform nuclei, thalami, dentate nuclei, subcortical white matter, and red nuclei in a pattern indistinguishable from other causes of brain calcification, such as disturbances in calcium metabolism (11).

MR is the preferred way to evaluate anosmic patients' olfactory sulci (12), which lie between the gyrus rectus and the medial orbital gyrus. Visualization of the olfactory tracts, commonly seen on MR examination just beneath the olfactory sulcus, is also important in Kallmann syndrome. The olfactory tracts connect anteriorly with the olfactory bulbs and posteriorly with the anterior olfactory nucleus and the olfactory stria (see Fig. 1A) and trigone, which are continuous with the gray matter of the prepiriform cortex, anterior perforated substance, and precommissural septal areas (13).

## Conclusion

MR examination, especially with high-resolution T1-weighted imaging in the coronal plane, can aid in evaluation of the olfactory sulci and,



in normal patients, visualization of the olfactory tracts. Hypoplasia of the olfactory sulci or non-visualization of the olfactory tracts along with the clinical findings of hypogonadotropic hypogonadism, anosmia, or heredity (family history of Kallmann syndrome) is consistent with the presence of Kallmann syndrome.

### Acknowledgments

Anatomic illustrations by Laura Perry, MD. Special thanks for manuscript preparation to Kathy Delongchamp.

### References

1. Kallmann FJ, Schoenfeld WA, Barrera SE. The genetic aspects of primary eunuchoidism. *Am J Ment Defic* 1944;48:203-210
2. Jones JR, Kemmann E. Olfacto-genital dysplasia in the female. *Obstet Gynecol Ann* 1976;5:443-445
3. Maestre de San Juan A. Teratologia: falta total de los nervios olfactorios con anosmia en un individuo en quien existia un atrofia congenita de los testiculos y miembro viril. *El Siglo Med* 1856;3:211-221
4. Moorman JR, Crain B, Osborne D. Kallmann's syndrome with associated cardiovascular and intracranial abnormalities. *Am J Med* 1984;77:369-372
5. Kovacs K, Sheehan HL. Pituitary changes in Kallmann's syndrome: a histologic immunocytologic, ultrastructural and immunoelectron microscopic study. *Fertil Steril* 1982;37:83-89
6. Bardin CW, Ross GT, Rifkind AB, Cargille CM, Lipsette MB. Studies of the pituitary-leydig cell assessing young men with hypogonadotropic hypogonadism and hyposmia. Comparison with normal men, prepuberal boys and hypopituitary parents. *J Clin Invest* 1969;48:2046
7. Lieblich JM, Rogol AD, White BJ, Rosen SW. Syndrome of anosmia with hypogonadotropic hypogonadism in (Kallmann's syndrome). Clinical and laboratory studies in 23 cases. *Am J Med* 1982;73:506-519
8. Turner RC, Bobrow M, Bobrow LG, et al. Cryptorchidism in a family member with Kallmann's syndrome. *Proc R Soc Med* 1974;67:33-35
9. Rogol AD, et al. HLA compatible paternity in two "fertile eunuchs" with congenital hypogonadotropic hypogonadism and anosmia (the Kallmann's syndrome). *J Clin Endocrinol Metab* 1980;38:275
10. Klingsmuller D, Dewes W, Krahe Th, Brecht G, Shweikert H. Magnetic resonance imaging of the brain in patient's with anosmia and hypothalamic hypogonadism (Kallmann's syndrome). *J Clin Endocrinol Metab* 1987;62:581-584
11. Malat J, Virapongse C. Brain calcification in Kallmann's syndrome. Computed tomographic appearance. *Pediatr Neurosci* 1985-1986;12:257-259
12. Von Dewes W, Krahe Th, Klingmuller D, Harder Th. MR tomographie beim Kallman syndrom. *Fortschr Rontgenstr* 1987;147:400-402
13. Williams PL, Warwick R (eds). *Gray's anatomy*. 36th ed. Philadelphia: WB Saunders, 1986;994-995

Please see the Commentary by Bick and Ballabio on page 852 in this issue.