AJNR

A technique for core biopsies of head and neck masses.

S K Mukherji, D Turetsky, R P Tart and A A Mancuso

AJNR Am J Neuroradiol 1994, 15 (3) 518-520
http://www.ajnr.org/content/15/3/518

A Technique for Core Biopsies of Head and Neck Masses

Suresh K. Mukherji, David Turetsky, Roger P. Tart, and Anthony A. Mancuso

Summary: A technique for performing core biopsies of indeterminate masses of the extracranial head and neck is described. Four patients with suspicious masses of the extracranial head and neck underwent coaxial core biopsies through an 18-gauge Hawkins-Akins blunt tip needle. Three of the four patients had diagnostically adequate samples. There were no neurologic or vascular complications.

Index terms: interventional neuroradiology, experimental; Interventional instrumentation, needles; Biopsies, technique

Core biopsies have gained popularity because of their ability to achieve a larger sample size, resulting in a higher diagnostic yield than fine-needle biopsy. This technique has most often been applied to abdominal and breast lesions (1). However, it has not been commonly applied to deep seated head and neck lesions because of the possibility, given the intricate anatomy of this region, of hemorragic or neurologic complications.

We have used a technique for performing core biopsies of deep-seated head and neck lesions via a coaxial system using a Hawkins-Akins blunt needle. It has proved safe in our initial experience (Fig 1) (2). This report will describe our technique and briefly summarize our clinical results.

Materials and Methods

All biopsies were performed with a cytotechnologist in attendance. A region of interest was determined with contrast-enhanced computed tomography (CT) (Fig 2A). The internal carotid artery and branches of the external carotid artery including the internal maxillary artery were identified and their relationship to the suspicious mass determined. The skin site was prepared and draped in sterile fashion. The superficial and deep area overlying the biopsy site was anesthesized with 1% xylocaine. For deep lesions, the patient was sedated with intravenous Midazolam (Versed) with the dose dependent on age, weight, and pain tolerance. All deep biopsies requiring intravenous sedation were performed with a nurse in attendance and with continuous monitoring of blood pressure, oxygen saturation, and electrocardiogram. A small skin incision was made to allow easy passage of the needle through dermal elements.

Eighteen-gauge Hawkins-Akins blunt needle (Cook Inc., Bloomington, Ind) with a blunt trocar in place was advanced to the proximal edge of the mass under CT guidance (Fig 2B). The trocar was removed and initial biopsies were performed coaxially though the Hawkins-Akins needle using a 20-gauge or 22-gauge Chiba cutting needle (Manon Medical Products, Northbrook, Ill). Core biopsy was then performed coaxially through the Hawkins-Akins blunt needle by advancing the tip of an automated 20-gauge core-biopsy needle (Manon Medical Products) to the tip of the blunt needle. Biopsy was then performed using an automated biopsy gun (Manon Medical Products) with a 2-cm throw. Postbiopsy scans were performed through the region of interest in all cases. Outpatients were monitored and observed for 4 hours after the procedures. The procedure is graphically summarized in Figure 3.

Results

Four patients underwent CT-guided core biopsies using the previously described coaxial system over the past year. Our results and clinical follow-up are summarized in Table 1. We obtained sufficient tissue samples in three of the four patients. There were no hemorrhagic or neurologic complications in any of our patients.

Discussion

CT-guided biopsies of head and neck lesions in the skull base and masticator spaces are usually performed with fine-needle aspiration because of possible risks to major vessels (carotid

Received November 16, 1992; accepted March 10, 1993.

From the Department of Radiology, University of Florida College of Medicine, Shands Teaching Hospital, Box 100374, JHMHC, Gainesville, FL 32610-0291. Address reprint requests to Dr Mukherji.

AJNR 15:518–520, Mar 1994 0195-6108/94/1503-0518 © American Society of Neuroradiology

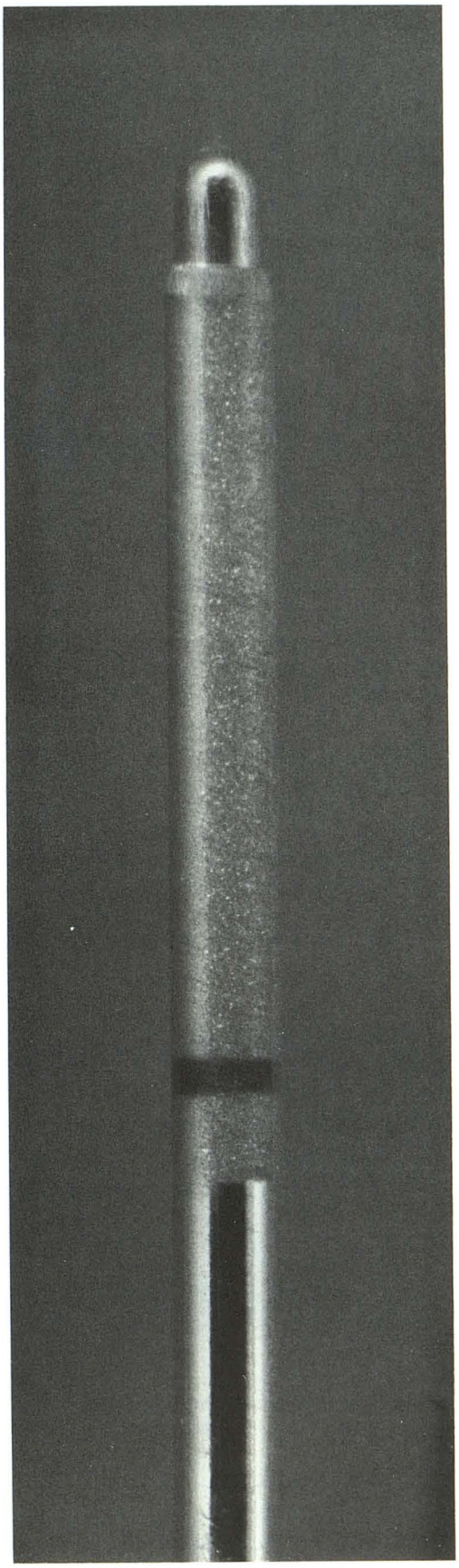

artery, jugular vein, maxillary artery) and nerves (facial and various lower cranial nerves). The placement of the blunt needle to the edge of the target allows purchase of the lesion without injury to adjacent vessels or nerves. The throw of the cutting needle can be planned to traverse the target only along a path that will avoid injury to adjacent and deeper neurovascular structures.

Our results suggest that a coaxial system using the Hawkins-Akins blunt needle can allow safe and diagnostically adequate sampling of lesions with 20-gauge cutting needles and automated 20-gauge core-biopsy needles. There were no neurologic or vascular complications in our series.

Three of the four patients had adequate tissue for diagnosis. The single patient (no. 2) whose sample was inadequate was treated for osteradionecrosis and is currently tumor-free 1 year after biopsy. The patient who underwent core biopsy of the nasopharynx (no. 4) had undergone an intraoperative transmucosal biopsy of this region which was negative 10 days before the percutaneous approach. In this case, core biopsy provided definitive proof of recurrent tumor. This patient was treated with radiation therapy and is currently tumor-free.

In our series, we have not encountered any significant resistance advancing the blunt-tip needle for deep-seated lesions of the nasopharynx. This includes biopsies that would have traversed such structures as the spenomandibular ligament (Fig 2B).

Our results are preliminary but indicate that this technique is a promising one for performing safe core biopsies of deep-seated masses near the skull base or those involving the masticator or parapharyngeal spaces. A larger series of cases would be necessary before the safety of this technique can be adequately determined.

References

1. Dronkers DJ. Stereotactic core biopsy of breast lesions. *Radiology* 1992;183:631–634
2. Akins WE, Hawkins IF, Mlandich C, Tupler R, Siragua RJ, Pry R. The blunt needle: A new percutaneous access device. *AJR Am J Roentgenol* 152:181–182

Fig. 1. Tip of the Hawkins-Akins 18-gauge blunt needle with blunt trocar in place.

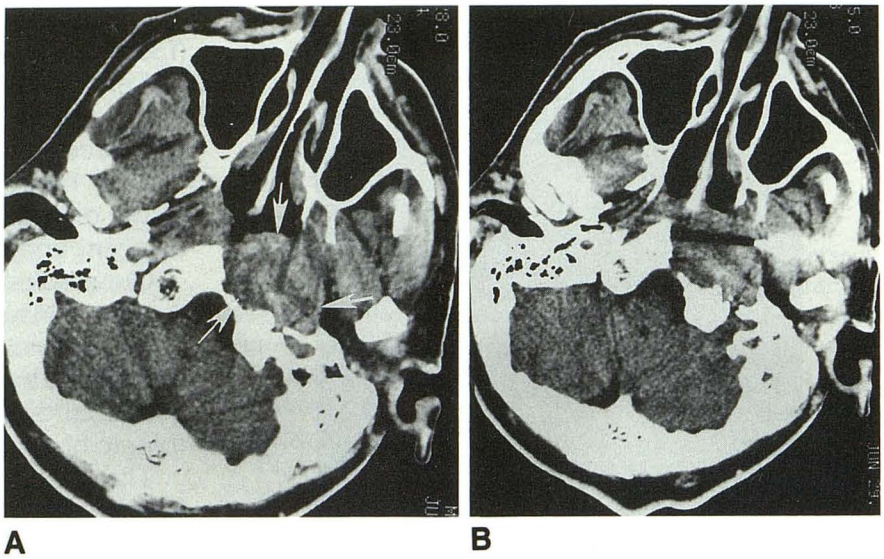

Fig. 2. CT of the nasopharynx. *A*, Axial image demonstrates a suspicious mass in the left nasopharynx (*arrows*) with obscuration of the adjacent fat planes. *B*, The tip of the Hawkins-Akins needle has been advanced to the edge of the mass in question and deep to the maxillary artery. The course of the needle was directed toward the clivus and away from the expected course of large branches of the external carotid artery and cranial nerves. Biopsy result was positive for recurrent squamous cell carcinoma.

TABLE 1: Summary of core biopsy results

Patient	Date	Reason for Biopsy	Location	Biopsy Results	Complications	Clinical Follow-Up
1	6/23/92	Neural foraminal mass	C3-4 neural foramina	No tumor cells	None	No evidence of tumor
2	11/27/91	? Recurrent tumor	Masticator space	Fibrovascular tissue	None	No evidence of recurrence
3	7/1/92	? Recurrent tumor	Tongue base	Atypical epithelial cells	None	Surgical resection Recurrent SCC
4	6/29/92	? Recurrent tumor	Nasopharynx	Poorly differentiated SCC	None	Radiation therapy

Note.—SCC indicates squamous cell carcinoma.

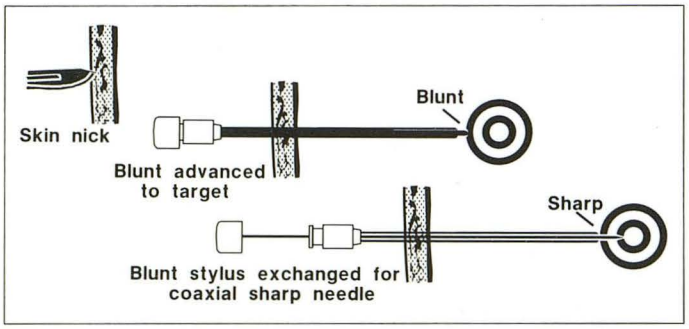

Fig. 3. Schematic representation of coaxial biopsy procedure using Hawkins-Akins blunt needle (courtesy of Irwin F. Hawkins, MD).