

Are your **MRI contrast agents** cost-effective?  
Learn more about generic **Gadolinium-Based Contrast Agents**.



**AJNR**

**Giant Rathke cleft cyst.**

J R Meyer, D J Quint, P E McKeever, M Boland and D A Ross

*AJNR Am J Neuroradiol* 1994, 15 (3) 533-536

<http://www.ajnr.org/content/15/3/533>

This information is current as  
of April 19, 2024.

---

## Giant Rathke Cleft Cyst

Joel R. Meyer, Douglas J. Quint, Paul E. McKeever, Michael Boland, and Donald A. Ross

**Summary:** The preoperative diagnosis for an unusual skull base lesion was chordoma. The combination of imaging, pathologic, and surgical findings suggests the diagnosis of Rathke cyst.

**Index terms:** Sella turcica, cysts; Sella turcica, computed tomography; Sella turcica, magnetic resonance; Skull, base

Rathke cysts are congenital, usually sellar and/or suprasellar lesions that are rarely symptomatic and often go undetected during life. They can be found incidentally in as many as 33% of autopsies (1, 2). With computed tomography (CT) and magnetic resonance (MR), these lesions are now more commonly diagnosed preoperatively or discovered incidentally (3). Although imaging features may be helpful in differentiating these lesions from other well-circumscribed intrasellar/suprasellar processes, including craniopharyngiomas, arachnoid cysts, epidermoid cysts, mucoceles, abscesses, and pituitary adenomas, radiologic findings can be nonspecific, necessitating cyst-wall biopsy to attempt to obtain a more definitive diagnosis. We report an unusual case of a giant Rathke cyst with extensive involvement of the skull base, for which the preoperative diagnosis was chordoma.

### Case Report

A 45-year-old woman presented with neck pain. Her neurologic examination was normal. Cervical spine radiographs demonstrated no abnormalities of the cervical spine; however, a destructive lesion of the skull base was incidentally noted on these films. MR (Figs 1A–1D) demonstrated a well-defined lesion centered in the clivus with extension to involve the sphenoid sinus, right posterior ethmoid air cells, orbital roofs (left greater than right), and prepontine cistern. The lesion demonstrated somewhat inhomogeneous low signal intensity (slightly greater than cerebrospinal fluid) on T1-weighted (short-repetition-time, short-echo-time) images and increased signal intensity (slightly greater

than cerebrospinal fluid) on T2-weighted (long-repetition-time, long-echo-time) images. There was no enhancement of any portion of the lesion after the intravenous administration of gadopentetate dimeglumine. The adenohypophysis was considered at the lower limits of normal in size. The posterior pituitary gland and infundibulum as well as the remainder of the brain were normal. CT scan of the skull base (Figs 1E and 1F) demonstrated a well-circumscribed homogeneous (ie, no calcified matrix) low-attenuation lesion in a distribution similar to that seen on the MR scan. The bone margins of the lesion were smooth and well defined. The bone involvement by the mass was better delineated on the CT scan than on the MR scan.

The patient underwent a bifrontal craniotomy with bilateral supraorbital osteotomy permitting a subfrontal, extradural approach to the lesion. There was no evidence for an aggressive neoplasm. A large cystic lesion involving the posterior ethmoid air cells, both orbits, and the basisphenoid region was identified. The cyst contained clear yellow fluid with numerous yellow and white crystals layering dependently within the cyst. The cyst was aspirated, and the lining of the cyst was biopsied. After aspiration of the cyst contents, the medial aspect of the cavernous sinuses, Dorello canals, and the dura-covered hypoglossal canals could clearly be seen bilaterally. The intraoperative frozen section histologic evaluation was considered most consistent with squamous and cuboidal epithelium, suggesting a benign lesion. Fascia lata, fat, and vascularized pericranium were used to reconstruct the floor of the anterior cranial fossa. On the permanent histologic sections (Fig 1G), squamous and cuboidal epithelium and underlying subepithelial connective tissue, infiltrated by lymphocytes and occasional neutrophils, were identified. The combination of imaging, surgical, and histologic findings led to a final diagnosis of a Rathke cyst.

### Discussion

Rathke cysts are classically believed to arise from failure of obliteration of the lumen of Rathke pouch, which develops as a rostral outpouching of the primitive oral cavity during the third or

---

Received June 9, 1992; accepted pending revision August 12; revision received January 4, 1993.

From the Departments of Radiology (J.R.M., D.J.Q.) and Pathology (P.E.M.), and Section of Neurosurgery, Department of Surgery (M.B., D.A.R.), University of Michigan Hospitals, Ann Arbor.

Address reprint requests to Joel R. Meyer, MD, Department of Radiology-Neuroradiology, Northwestern Memorial Hospital, Olson Pavilion, Suite 3535, 710 North Fairbanks Ct, Chicago, IL 60611.

AJNR 15:533–536, Mar 1994 0195-6108/94/1503-0533 © American Society of Neuroradiology



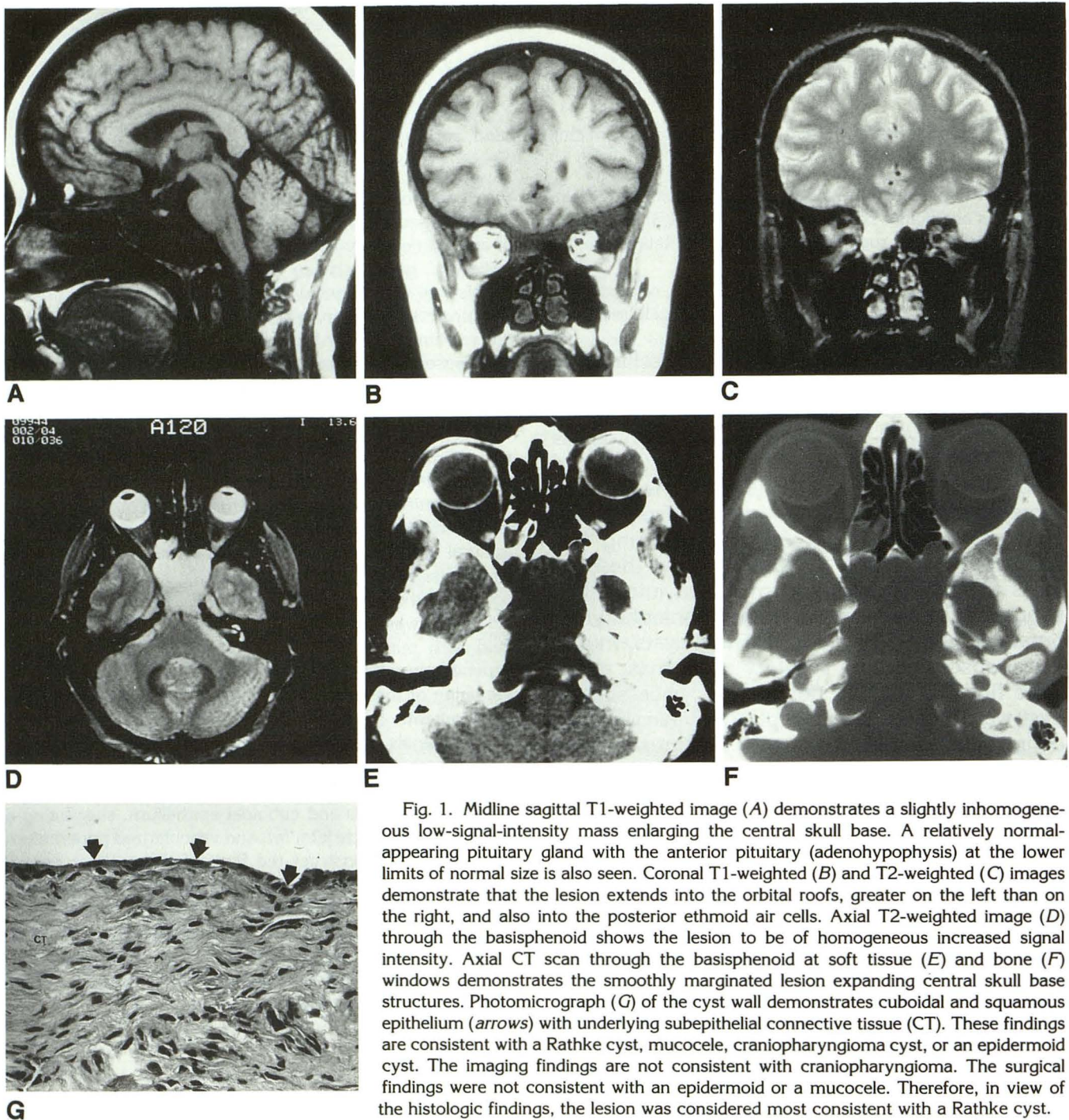


Fig. 1. Midline sagittal T1-weighted image (A) demonstrates a slightly inhomogeneous low-signal-intensity mass enlarging the central skull base. A relatively normal-appearing pituitary gland with the anterior pituitary (adenohypophysis) at the lower limits of normal size is also seen. Coronal T1-weighted (B) and T2-weighted (C) images demonstrate that the lesion extends into the orbital roofs, greater on the left than on the right, and also into the posterior ethmoid air cells. Axial T2-weighted image (D) through the basisphenoid shows the lesion to be of homogeneous increased signal intensity. Axial CT scan through the basisphenoid at soft tissue (E) and bone (F) windows demonstrates the smoothly margined lesion expanding central skull base structures. Photomicrograph (G) of the cyst wall demonstrates cuboidal and squamous epithelium (arrows) with underlying subepithelial connective tissue (CT). These findings are consistent with a Rathke cyst, mucocoele, craniopharyngioma cyst, or an epidermoid cyst. The imaging findings are not consistent with craniopharyngioma. The surgical findings were not consistent with an epidermoid or a mucocoele. Therefore, in view of the histologic findings, the lesion was considered most consistent with a Rathke cyst.

fourth week of gestation (4–6). Alternatively, other investigators have suggested that Rathke cysts originate directly from neuroepithelial tissue (7–9) or by reverse metaplasia of anterior pituitary cells (10). It also has been proposed that they represent the simplest lesions in a spectrum of

epithelial lesions of common origin, which arise from squamous cell rests of the craniopharyngeal duct, including craniopharyngiomas and epidermoid cysts (9, 11, 12).

In a recent review of 43 surgically proved Rathke cysts by Ross et al (2), six of the lesions



were discovered incidentally; 37 patients had clinical symptoms including headache, amenorrhea/galactorrhea, visual field deficits, hypopituitarism, and diabetes insipidus. Of the 30 patients with either preoperative CT or MR, lesions were either intrasellar (14), suprasellar (9), or a combination of intrasellar and suprasellar (7). None of the lesions involved the skull base, as seen in our patient.

A Rathke cyst presenting with extensive involvement of the skull base and without intrasellar or suprasellar involvement is distinctly unusual. This occurrence would tend to support the theory that Rathke cysts may arise from epithelial rests of the craniopharyngeal duct (9, 11, 12). In our patient, as the majority of the sphenoid bone and the basiocciput were replaced by this large lesion, it is impossible to determine where the lesion arose. However, the dural sleeves of visualized cranial nerves were well formed, suggesting that the extensive bone loss was acquired over time, not caused by congenital failure of the bone to form. We cannot explain why this process remained confined to the skull base without involving intracranial contents. However, the borderline small size of the adenohypophysis (Fig 1A) may be secondarily related to this process, because most Rathke cysts do effect the intrasellar compartment.

The differential diagnostic considerations based on the CT scan in our patient included chordoma as well as more benign lesions such as epidermoid cyst, meningocele (congenital or posttraumatic), cystic craniopharyngioma, and mucocele arising from the sphenoid sinus, because the margins of the process were smooth, suggesting a long-standing lesion. Less likely considerations included more malignant processes such as multiple myeloma, chondrosarcoma, lymphoma, and metastatic disease.

The lack of a history of trauma, other inflammatory changes, and the absence of a communication between the intracranial contents and the skull-base lesion in addition to the overall benign appearance of the lesion narrowed the differential diagnosis. MR was more specific than CT, demonstrating some inhomogeneity to the lesion and possibly a cystic nature to the lesion, with prolongation of T1 and T2 relaxation times. However, because solid neoplasms usually also demonstrate similar prolongation of T1 and T2 relaxation times, the differential diagnosis could be narrowed only to congenital cyst (Rathke cleft

cyst), epidermoid, and cystic craniopharyngioma (with an atypical mucocele considered a less likely possibility) after the MR imaging was completed. MR diffusion imaging might have been helpful to differentiate noninvasively between the cystic possibilities (Rathke cyst and cystic craniopharyngioma) and more solid epidermoid or mucocele, because all four of these entities can demonstrate the imaging characteristics seen in this patient (13, 14).

The histologic findings from the cyst-wall biopsy performed at surgery revealed relatively nonspecific cuboidal and squamous epithelium consistent with the lining of a mucocele, epidermoid cyst, cystic craniopharyngioma, or Rathke cleft cyst. Immunoperoxidase stains showed very weak focal reactivity for S-100 protein (reported positive in some Rathke cysts [15]) and none for glial fibrillary acidic protein. Mucin stain was negative. This staining profile was considered nondiagnostic. However, the MR findings of a lesion with no abnormal enhancement after gadolinium administration, either of the lesion wall or of a solid tissue nidus, makes the diagnosis of a Rathke cyst much more likely than a craniopharyngioma (16). Similarly, because epidermoids are usually filled with waxy material representing keratinous debris (15, 17), the surgical finding of a fluid-filled lesion is not consistent with an epidermoid. The surgical findings were also considered inconsistent with those expected for a mucocele. Therefore, although the histologic findings alone cannot be considered diagnostic of a Rathke cleft cyst, when considered in conjunction with the imaging and surgical findings, a congenital Rathke cleft cyst becomes the best diagnosis.

In our patient, treatment options included transphenoidal or transcranial drainage of the lesion, with biopsy of the cyst wall. A transphenoidal approach, although technically simpler, was considered less desirable because of the size and extent of this lesion. It was considered unlikely that a transphenoidal approach would permit drainage of the entire lesion. Such incomplete drainage of the cyst would increase the risk of secondarily infecting the lesion. Using a transcranial approach, it is possible to see down the clivus as far as C-2 in some instances (18). In our patient, it allowed surgical exposure of the majority of the lesion with anticipation of resection of a tumor. The correct intraoperative diagnosis of a Rathke cyst was extremely important in this



case, because the patient was spared extensive skull-base surgery.

## References

1. Bayoumi ML. Rathke's cleft and its cysts. *Edinb Med J* 1948;55:745-749
2. Ross DA, Norman D, Wilson CB. Radiologic characteristics and results of surgical management of Rathke's cysts in 43 patients. *Neurosurgery* 1992;30:173-179
3. Wagle VG, Nelson D, Rossi A, Uphoff D. Magnetic resonance imaging of a symptomatic Rathke's cleft cyst. Report of a case. *Neurosurgery* 1989;24:276-278
4. Barrow DL, Spector RH, Takei Y, Tindall GT. Symptomatic Rathke's cleft cysts located entirely in the suprasellar region: review of diagnosis, management, and pathogenesis. *Neurosurgery* 1985;16:766-772
5. Fager CA, Carter H. Intrasellar epithelial cysts. *J Neurosurg* 1966;24:77-81
6. Yoshida J, Kobayashi T, Kageyama N, Kanzaki M. Symptomatic Rathke's cleft cyst. Morphological study with light and electron microscopy and tissue culture. *J Neurosurg* 1977;47:451-458
7. Concha S, Hamilton BPM, Millan JC, Mcqueen JD. Symptomatic Rathke's cleft cyst with amyloid stroma. *J Neurol Neurosurg Psychiatry* 1975;38:782-786
8. Diengdoh JV, Scott T. Electron microscopical study of a Rathke's cleft cyst. *Acta Neuropathol (Berl)* 1983;60:14-18
9. Steinberg GK, Koenig GH, Golden JB. Symptomatic Rathke's cleft cysts: report of two cases. *J Neurosurg* 1982;56:290-295
10. Naiken VS, Tellem M, Meranze DR. Pituitary cyst of Rathke's cleft origin with hypopituitarism. *J Neurosurg* 1961;18:703-706
11. Eisenberg HM, Weiner RL. Benign pituitary cysts. In: Wilkins RH, Rengachary SS (eds). *Neurosurgery*. New York: McGraw-Hill, 1985:932-934
12. Matsushima T, Fukui M, Fuji K, Kinoshita K, Yamakawa Y. Epithelial cells in symptomatic Rathke's cleft cysts. A light and electron microscopic study. *Surg Neurol* 1988;30:197-203
13. Tsuruda JS, Clew WM, Moseley ME, Norman D. Diffusion-weighted MR imaging of the brain: value of differentiating between extra-axial cysts and epidermoid tumors. *AJNR Am J Neuroradiol* 1990;11:925-931
14. Tampien D, Melanson D, Ethier R. MR imaging of epidermoid cysts. *AJNR Am J Neuroradiol* 1989;10:351-356
15. McKeever PE, Sima AAF, Blaivas M. Neoplasms of the sellar region. In: Lloyd RV (ed). *Surgical pathology of the pituitary gland. Major problems in pathology series*. Philadelphia: Saunders, 1993:141-210
16. Kucharczyk W, Montanera WJ. The sella and parasellar region. In: Atlas SW (ed). *Magnetic resonance imaging of the brain and spine*. New York: Raven, 1991:625-667
17. Gao P, Osborn AG, Smirniotopoulos JG, Harris CP. Radiologic-pathologic correlation: epidermoid tumor of the cerebellopontine angle. *AJNR Am J Neuroradiol* 1992;13:863-872
18. Sekhar LN, Nanda A, Sen CN, Snyderman CN, Janecka IP. The extended frontal approach to tumors of the anterior, middle and posterior skull base. *J Neurosurg* 1992;76:198-206