AJNR

The posterior condylar canal.

L E Ginsberg

AJNR Am J Neuroradiol 1994, 15 (5) 969-972
http://www.ajnr.org/content/15/5/969

The Posterior Condylar Canal

Lawrence E. Ginsberg

PURPOSE: To assess the prevalence and appearance of the posterior condylar canal using high-resolution CT. **METHODS:** One hundred twenty-three high-resolution temporal bone CT examinations were retrospectively reviewed for the presence or absence of the posterior condylar canal. Thirty-four gross skulls were also examined. **RESULTS:** The posterior condylar canal was identified on CT bilaterally in 31% of the final study group and unilaterally in 50%. On gross specimens, this structure was identified in 55.9% bilaterally and 17.6% unilaterally. The posterior condylar canal, when present, is readily identifiable in a predictable location. The imaging appearance of this structure is dependent on its relationship to the angle of scanning. **CONCLUSION:** The posterior condylar canal is among the largest emissary foramina in the human skull. Recognition of this structure and its role as an alternative source of venous drainage from the brain will help avoid misinterpretation during CT examination.

Index terms: Skull, anatomy; Skull, computed tomography; Cerebral blood flow

AJNR Am J Neuroradiol 15:969–972, May 1994

Emissary veins exist in the skull as an escape mechanism, an alternative route of egress for venous blood (1–4). When the normal routes of venous drainage are patent, the role of emissary veins is limited. However, should venous outflow be compromised (ie, jugular thrombosis), these accessory conduits become an important alternative pathway for venous drainage of the brain. Emissary channels include the sphenoid emissary vein (via the foramen of Vesalius), the mastoid emissary vein, the occipital emissary vein, foramen ovale emissary sinuses, and the posterior condyloid vein. Recently described emissary foramina include the inferior and lateral rotundal canals (5). The posterior condylar vein exits the skull through the posterior condylar (or condyloid) canal, which is a communication between the jugular foramen and the condylar fossa, situated just posterior to the occipital condyles on either side of the foramen magnum (4) (Fig 1). This canal allows for venous anastomosis between the jugular bulb and the suboccipital venous plexus (1–4).

The purpose of this report was to study the anatomy and imaging appearance of the posterior condyloid canal. Recognition of this common canal is useful for understanding alternative pathways of venous flow and avoiding confusion during interpretation of magnetic resonance and computed tomography (CT) examinations. Misinterpretation of the posterior condyloid canal has led to surgical intervention for presumed glomus jugulare tumor (4).

Subjects and Methods

Selected at random, high-resolution unenhanced CT scans of the temporal bone were retrospectively examined in 116 patients to assess the presence or absence of the posterior condylar canal. Studies were acquired using 1.5-mm contiguous sections in an axial plane parallel to the infraorbitomeatal line. All scans were performed on a GE 9800 scanner (GE Medical Systems, Milwaukee, Wis) and reconstructed on bone algorithm, with zooming of each side separately to a 9.6-cm field of view. Although the protocol was designed principally to detect temporal bone disorders, the jugular foramen and foramen magnum were well visualized in all cases. These 116 patients demonstrated no evidence of vascular, neoplastic, or destructive disease in the region of the foramen magnum or jugular foramen that would have distorted normal anatomy. In

Received May 4, 1993; accepted for publication July 26.

From the Department of Radiology, Bowman Gray School of Medicine, Winston-Salem, NC.

Address correspondence and reprint requests to: Lawrence E. Ginsberg, MD, Department of Radiology, Bowman Gray School of Medicine, Medical Center Boulevard, Winston-Salem, NC 27157–1088.

AJNR 15:969–972, May 1994 0195-6108/94/1505–0969

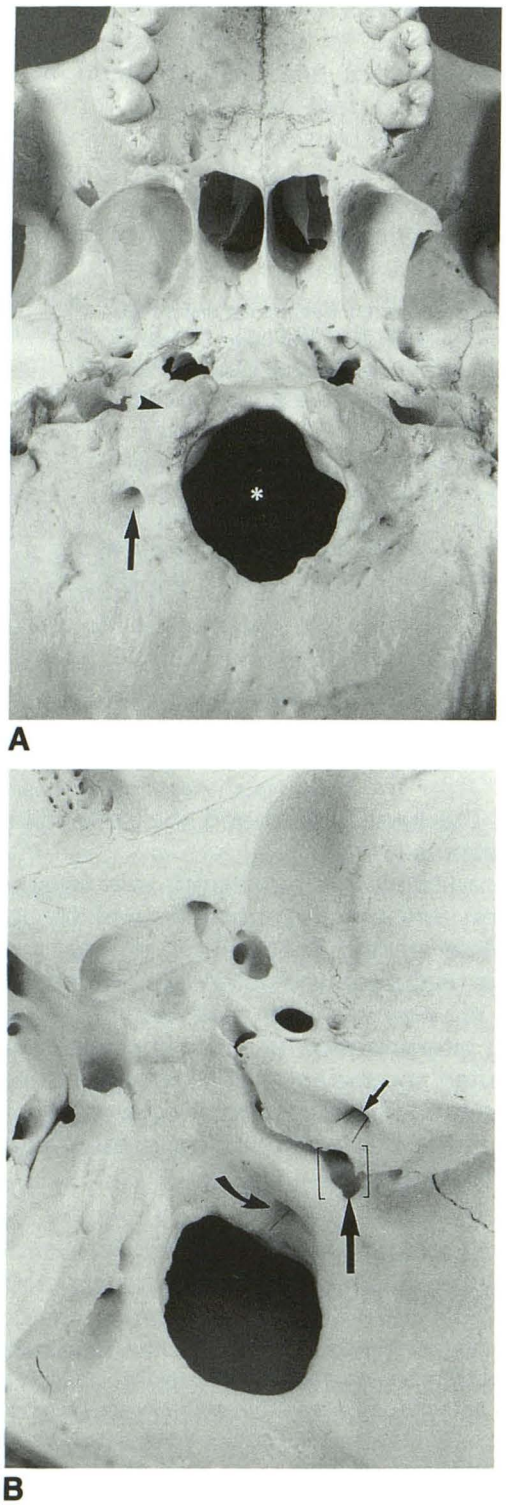

Fig. 1. Photographs of gross skull specimen.

A, Exocranial view from below. The right posterior condylar canal is prominent (*arrow*), situated just posterior to occipital condyle (*arrowhead*) and just lateral to the foramen magnum (*asterisk*).

B, Endocranial view from above and slightly to the left. The posterior condylar canal (*large arrow*) can be seen extending inferiorly from the floor of the jugular foramen (*brackets*). Wires can be seen emerging from the internal auditory canal (*small arrow*) and hypoglossal canal (*curved arrow*).

addition, 34 gross skulls were physically examined for the unilateral or bilateral presence or absence of the posterior condylar canal.

Results

The posterior condylar canal was identified on CT examinations in 94 (81%) of our patients; 36 (31%) bilaterally and 58 (50%) unilaterally. Of the unilateral cases, 25 were right sided and 33 were left sided (21.6% and 28.4% of all cases, respectively). On examination of gross skulls, the posterior condylar canal was identified bilaterally in 19 (55.9%) and unilaterally in six (17.6%). The unilateral posterior condylar canals were evenly distributed between left and right. Thus, the posterior condylar canal was completely undetectable in only 20% of cases by CT and 26.5% of cases by gross inspection.

Discussion

The posterior condylar canal forms a communication between the jugular foramen and the condylar fossa just posterior to the occipital condyles (1,2,4). It transmits an emissary vein which allows anastomosis of the jugular bulb or sigmoid sinus to the suboccipital venous plexus (1–4).

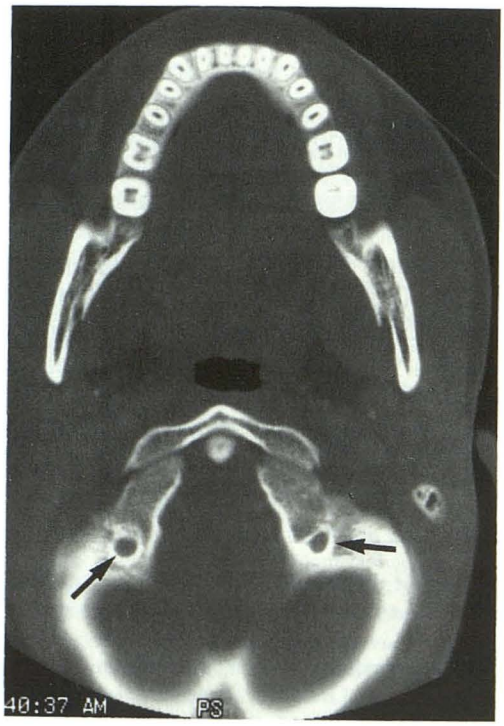

Fig. 2. Bilateral posterior condylar canals appearing as simple foramen (*arrows*).

According to Boyd (6), the posterior condylar canal is the largest of the emissary foramina; in his examination of 1500 skulls it was present, at least unilaterally, in 77%. We observed the presence of this structure, at least unilaterally, in 81% of our CT examinations and 74% of our skulls.

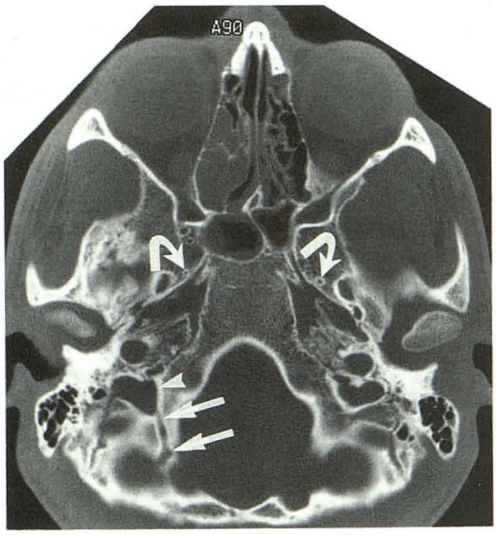

Fig. 3. Right-sided posterior condylar canal appearing more canallike. The posterior condylar canal (*long arrows*) can be seen extending posteriorly from the jugular foramen (*arrowhead*). Note the presence of the foramen of Vesalius bilaterally (*curved arrows*).

The posterior condylar canal, when present, is generally quite apparent just posterior and inferior to the jugular foramen (Figs 2 and 3). A reported right-sided predominance of the posterior condylar canal (7) was not borne out by our data. When unilateral, the posterior condylar canal was more commonly left sided (28.4%) than right sided (21.6%). The posterior condylar canal tends to have a meandering course; therefore, its appearance is variable and may depend on its position relative to a particular CT cut. If caught in cross-section, only a round foramenlike hole may be seen (Fig 2). If imaged more tangentially, a longer, more canallike structure is observed (Fig 3). Either configuration or both may be seen in a given patient. During the venous phase of a cerebral arteriogram, the posterior condylar vein may occasionally be observed (3) (Fig 4). In the healthy patient, the value of recognizing the posterior condylar canal is in appreciating its anatomic role and not misinterpreting it as pathologic. We have noted occasionally that on contrast-enhanced magnetic resonance imaging, prominent posterior condylar canals may enhance strikingly and could be misinterpreted as a neuroma (Fig 5). Of course, any destructive lesion of the jugular fossa could extend to involve the posterior condylar canal.

The posterior condylar canal may have some clinical relevance. First, in a patient with promi-

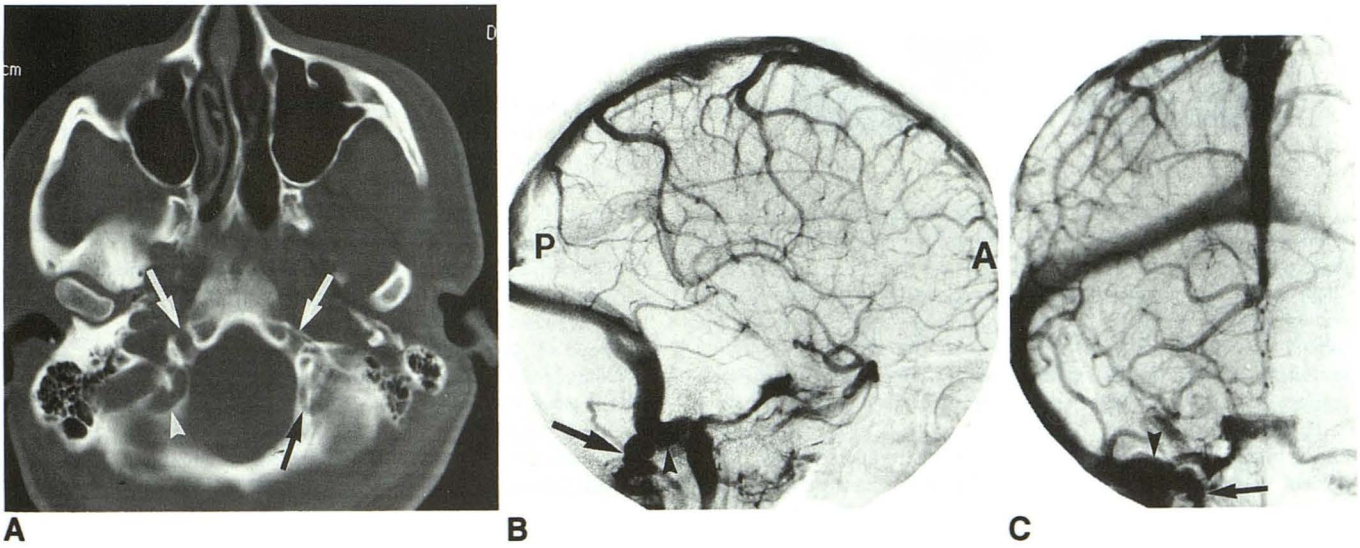

Fig. 4. Prominent right-sided posterior condylar canal with angiographic demonstration of the posterior condylar vein.

A, Axial CT shows a large right-sided posterior condylar canal (*arrowhead*). A smaller left-sided posterior condylar canal can be seen (*black arrow*). Note the hypoglossal canals bilaterally (*white arrows*).

B, Carotid angiogram, venous phase, lateral view. A indicates anterior; P, posterior. The posterior condylar vein (*arrow*) can be seen extending posteroinferiorly from jugular fossa (*arrowhead*).

C, Carotid angiogram, venous phase, anteroposterior view. Right-sided posterior condylar canal (*arrow*) can be seen extending inferiorly and medially from jugular fossa (*arrowhead*).

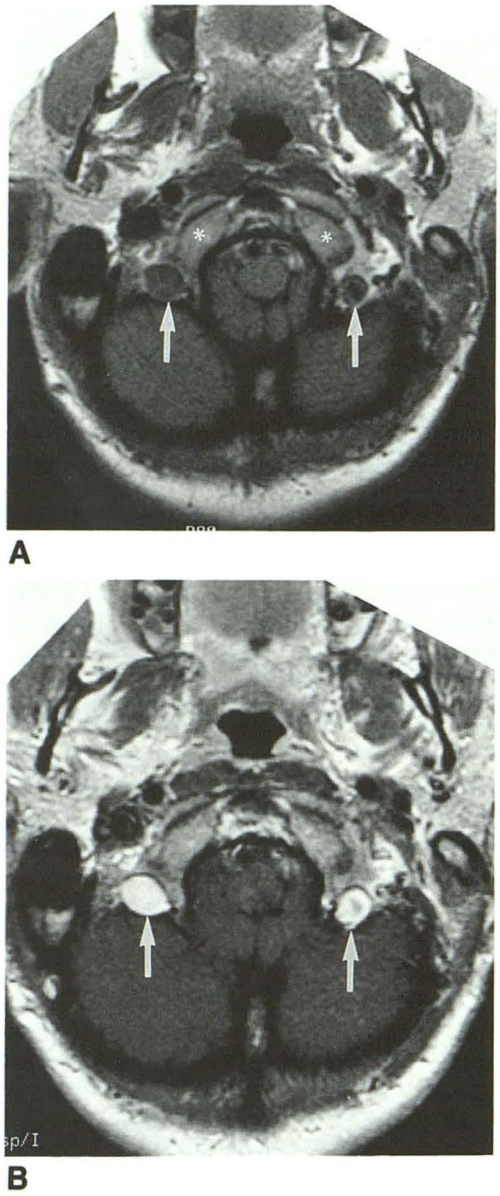

Fig. 5. Prominent bilateral posterior condylar canal in a 45-year-old woman with bright contrast enhancement on magnetic resonance.

A, Axial T1-weighted (400/17) magnetic resonance image shows bilateral posterior condylar canal as round soft-tissue intensity structures (*arrows*) posterior to the occipital condyles (*asterisks*). There is low signal intensity, suggesting flow within the left posterior condylar canal.

B, Postcontrast axial T1-weighted (400/17) magnetic resonance image shows bright enhancement bilaterally (*arrows*). This patient was asymptomatic in this region; the rest of her exam findings were normal.

nent posterior condylar canals, the resulting venous anastomoses may allow for alternative venous drainage and, therefore, the theoretical possibility of a false-positive Queckenstedt's test, suggesting spinal block (2). Secondly, the posterior condylar canal/vein and other emissary channels may allow for venous escape of blood in the event of unilateral or bilateral jugular venous obstruction. It is possible that in the event of a high-flow state or vascular malformation, the posterior condylar canal could become enlarged. This has been reported for the foramen of Vesalius (8).

Conclusion

The posterior condylar canal is one of the larger emissary channels in the skull. It is present, at least unilaterally, in up to 80% of patients and is readily identifiable on CT examinations. It should not be misinterpreted as abnormal. Recognition of the posterior condylar canal and other variant emissary foramina, such as the foramen of Vesalius or the mastoid emissary foramen, allows a deeper appreciation of the alternative routes of venous drainage from the brain.

Acknowledgments

I thank Miriam Vernon and Nancy Ragland for their assistance in the preparation of this manuscript.

References

1. Williams PL, Warwick R, Dyson M, Bannister LH, eds. *Gray's anatomy*, 37th ed. New York: Churchill Livingstone, 1989:286–287
2. Coin CG, Malkasian DR. Foramen magnum. In: Newton TH, Potts DG, eds. *Radiology of the skull and brain: the skull.* Vol 1, Book 1. St. Louis: Mosby, 1971:275–286
3. Hacker H. Normal supratentorial veins and dural sinuses. In: Newton TH, Potts DG, eds. *Radiology of the skull and brain: the skull.* Vol 2, Book 3. St. Louis: Mosby, 1971:1851–1877
4. Haas LL. The posterior condylar fossa, foramen and canal, and the jugular foramen. *Radiology* 1957;69:546–552
5. Ginsberg LE. Skull-base foramina of the middle cranial fossa: reassessment of normal variation with high resolution CT. *AJNR Am J Neuroradiol* 1994;15:283–291
6. Boyd GI. The emissary foramina of the cranium in man and the anthropoids. *J Anat* 1930;65:108–121
7. Schelling F. Die emissarien des menschlichen schädels. *Anat Anz* 1978;143:340–382
8. Lanzieri CF, Duchesneau PM, Rosenbloom SA, Smith AS, Rosenbaum AE. The significance of asymmetry of the foramen of Vesalius. *AJNR Am J Neuroradiol* 1988;9:1201–1204