

Are your **MRI contrast agents** cost-effective?

Learn more about generic **Gadolinium-Based Contrast Agents**.



FRESENIUS
KABI

caring for life

AJNR

Delineation of gliomas with various doses of MR contrast material.

W T Yuh, H D Nguyen, E T Tali, N A Mayr, D J Fisher, S W Atlas, M C Carvlin, B P Drayer, S R Pollei and V M Runge

AJNR Am J Neuroradiol 1994, 15 (5) 983-989

<http://www.ajnr.org/content/15/5/983>

This information is current as of April 18, 2024.

Delineation of Gliomas with Various Doses of MR Contrast Material

William T. C. Yuh, Hoang D. Nguyen, E. Turgut Tali, Nina A. Mayr, David J. Fisher, Scott W. Atlas, Mark C. Carvlin, Burton P. Drayer, Steven R. Pollei, Val M. Runge, and Gordon K. Sze

PURPOSE: To examine the effects of different gadolinium doses on the delineation of gliomas, particularly the demonstration of abnormal enhancement on T1-weighted images extending beyond the zone of apparent signal abnormality on corresponding T2-weighted images. **METHODS:** During phase II clinical trials of gadoteridol, 23 patients with pathologically proved gliomas were studied by MR with various doses of gadoteridol, ranging from 0.05 to 0.3 mmol/kg. **RESULTS:** All of the gliomas were readily detected by T2-weighted images. Twelve of 23 patients demonstrated enhancement on T1-weighted images extending beyond the zone of apparent signal abnormality demonstrated on T2-weighted images. These findings were seen in none of the six patients (0%) studied at 0.05 mmol/kg, one of five patients (20%) studied at 0.1 mmol/kg, four of five patients (80%) studied at 0.2 mmol/kg, and seven of seven patients (100%) studied at 0.3 mmol/kg. **CONCLUSIONS:** The detection of symptomatic gliomas does not require a contrast agent because they are generally large and readily demonstrated on T2-weighted images. However, the area of postcontrast enhancement of gliomas seems to be greater with higher doses of contrast agent. The cause of the abnormal enhancement extending beyond the zone of apparent signal abnormality on T2-weighted images seen in this limited study is unknown and probably represents tumor infiltration. The frequency of detection of such findings appears to be proportional to the dose of contrast material used.

Index terms: Glioma; Contrast media, paramagnetic; Magnetic resonance, tissue characterization; Brain, magnetic resonance

AJNR Am J Neuroradiol 15:983-989, May 1994

Histologically, gliomas as a group demonstrate heterogeneity and variability in extent, geometry, and peripheral infiltrating margins (1). On contrast-enhanced computed tomographic examinations, gliomas typically show areas of enhance-

ment surrounded by vasogenic edema (2-5). Similarly, on magnetic resonance (MR) imaging with a 0.1 mmol/kg dose of contrast material, tumor enhancement tends to be localized within the zone of apparent signal abnormality demonstrated on T2-weighted images (zone of T2-weighted abnormality) (2,6-9). It is well known that gliomas can be found in the areas where the brain parenchyma shows normal radiologic findings. Stereotactic biopsy or postmortem correlation of gliomas has proved that computed tomography with an iodinate agent or MR with a standard dose (0.1 mmol/kg) of gadopentetate dimeglumine (Magnevist, Berlex Laboratories, Wayne, NJ) may fail to delineate the extent of involvement (3,4,10-13). Although some gliomas occasionally show no enhancement, other radiographic abnormalities, such as tumor heterogeneity, hemorrhage, border definition, cysts, necrosis, and mass effect, may suggest high-grade glioma. It should also be said that, conversely,

Received March 10, 1993; accepted pending revision May 7; revision received August 12.

This study was supported in part by grants from Squibb Diagnostic to all of the participating institutions.

From the Department of Radiology, University of Iowa College of Medicine (W.T.C.Y., H.D.N., E.T.T., N.A.M., D.J.F.), Iowa City; the Hospital of the University of Pennsylvania (S.W.A.), Philadelphia; Squibb Diagnostics (M.C.C.), Princeton; Barrow Neurologic Institute (B.P.D.), Phoenix, Ariz; the Center for Diagnostic Imaging (S.R.P.), St. Louis Park, Minn; the University of Kentucky Medical Center (V.M.R.), Lexington; and the Yale Medical Center (G.K.S.), New Haven, Conn.

Address reprint requests to William T. C. Yuh, MD, MSEE, Department of Radiology, University of Iowa Hospitals and Clinics, 200 Hawkins Dr, Iowa City, IA 52242.

AJNR 15:983-989, May 1994 0195-6108/94/1505-0983

© American Society of Neuroradiology

some very low-grade gliomas (such as pilocytic astrocytoma) enhance deeply. The purpose of this study was to investigate whether the dose of MR contrast agent has an effect on the enhancement of gliomas, specifically on the demonstration of extension of abnormal enhancement beyond the zone of T2-weighted abnormality. It is important to define the tumor by imaging because doing so may affect management decisions, such as whether to extend the surgical margins or place radiation ports to cover all of the tumor.

Materials and Methods

We retrospectively reviewed the MR scans of 80 patients with possible intracranial tumors evaluated during the multicenter phase II clinical trial of the MR contrast agent gadoteridol (ProHance, Squibb Diagnostics, Princeton, NJ), gadolinium 1,4,7-tris(carboxymethyl)-10-(2¹-hydroxypropyl)-1,4,7,10-tetraazacyclododecane. Fifteen patients had metastases, and 65 had other intracranial lesions. Forty-two of the 65 patients were excluded because the lesions were not gliomas (they were acoustic neurinomas, meningiomas, pituitary adenomas, and others) or because of postsurgical studies, lack of enhancement after contrast material administration, or no definite diagnosis. Thus, 23 patients with pathologically confirmed gliomas and MR examinations demonstrating enhancement constituted the study population.

All examinations followed strict protocol approved by the Federal Drug Administration and the Human Subject Committee. Of the 23 patients with gliomas, six received 0.05 mmol/kg gadoteridol, five received 0.1 mmol/kg, five received 0.2 mmol/kg, and seven received 0.3 mmol/kg. Imaging protocol included precontrast axial T1-weighted (600–750/20–30/1–2 [repetition time/echo time/excitations]), T2-weighted (2000–3000/90–100/1–2), and proton density-weighted (2000–3000/30–35/1–2) images using 0.5-T Vista (Picker International, Highland Heights, Ohio), 1.5-T (Signa, GE Medical Systems, Milwaukee, Wis), and 1-T or 1.5-T (Magnetom, Siemens, Erlangen, Germany) superconductive scanners. Section thickness ranged from 5 mm with a 50% gap on the 1.5 T scan to 10 mm without a gap. Additional pulse sequence or image planes were not required, but were frequently available. After intravenous contrast administration, T1-weighted images (same parameters including position as those of precontrast images) were obtained immediately and after a delay of 15 to 30, 30 to 45, and 45 to 60 minutes. The postcontrast images that demonstrated the greatest areas of enhancement were used for the study.

T2-weighted and contrast-enhanced T1-weighted MR studies of each patient were reviewed independently by four radiologists (E.T.T., F.G., H.D.N., and W.T.C.Y.). The patient's clinical findings and the doses of contrast agent used were unknown to the reviewers. The size of the lesion was manually traced and recorded on the T2-weighted

images and contrast-enhanced studies independently. The extent of involvement demonstrated by T2-weighted images in each lesion was then compared with that demonstrated by contrast-enhanced T1-weighted images. To increase the confidence of interpretation, because of the variation in image quality and availability of image planes among the studies, we considered abnormal enhancement to extend beyond the zone of T2-weighted abnormality when extension of abnormal enhancement exceeded at least 10 mm beyond the zone of T2-weighted abnormality, and all four reviewers came to the same conclusion. Additionally, the histopathologic grades of the tumors were reviewed to determine whether there was any relationship between the tumor grade and the detection of enhancement beyond the areas of abnormality on T2-weighted imaging.

Results

No adverse effects were observed in any of the 80 patients with doses up to 0.3 mmol/kg gadoteridol. Extensive laboratory blood chemistry tests revealed no abnormality related to the injection of gadoteridol, as previously reported (14). All patients had a detectable lesion on T2-weighted images before the injection of the contrast agent. The abnormalities (including vasogenic edema) demonstrated on T2-weighted images were larger than the area with abnormal contrast enhancement in all lesions. The center of abnormal enhancement was always located within the zone of T2-weighted abnormality. However, in 12 of the 23 patients with gliomas, subtle but definite enhancement extended beyond the zone of T2-weighted abnormality at the periphery of the tumor, whereas 11 showed the area with abnormal enhancement to be located entirely within the boundaries of the zone of T2-weighted abnormality (Fig 1, 2, and 3). None of the six patients (0%) receiving 0.05 mmol/kg gadoteridol, one of five patients (20%) receiving 0.1 mmol/kg, four of five patients (80%) receiving 0.2 mmol/kg, and seven of seven patients (100%) receiving 0.3 mmol/kg showed one portion of the periphery with abnormal enhancement at least 1 cm beyond the zone of T2-weighted abnormality. These 12 lesions that extended beyond the T2-weighted image boundaries included eight glioblastomas multiforme, three astrocytomas, and one ganglioglioma. Maximum enhancement after injection usually occurred at 30 minutes (immediately for one patient, at 15 minutes for two, at 30 minutes for nine, and at 45 minutes for one). The only glioma that showed maximum enhancement on the immediate image was studied with a higher dose (0.3 mmol/kg). Although

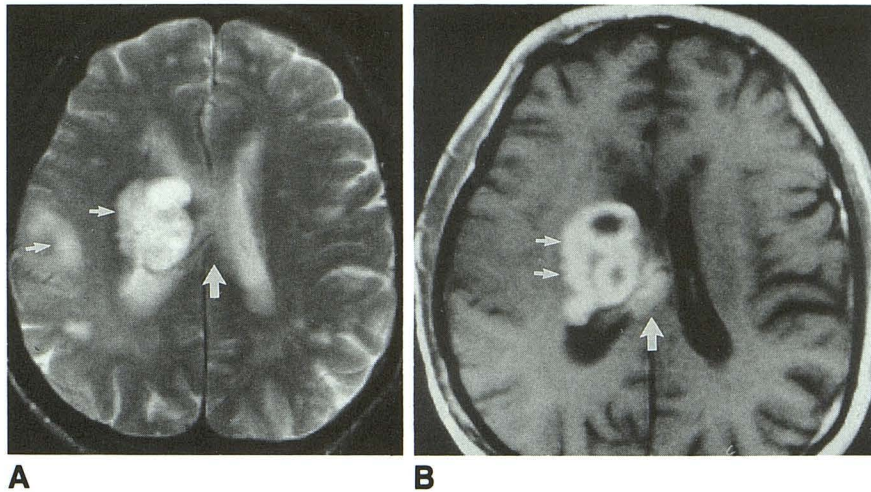


Fig. 1. A, Axial T2-weighted image (2500/80/1) shows abnormal signal in the parietal lobe (arrow) and corona radiata (arrow) of the right hemisphere. No signal abnormality is noted in the region of the corpus callosum (large arrow).

B, Postcontrast T1-weighted image obtained immediately after intravenous injection of 0.1 mmol/kg gadoteridol shows abnormal enhancement extending into the regions of normal signal intensity including the corpus callosum (large arrow) and possibly the corona radiata (small arrows). The parietal region with abnormal signal intensity noted in A shows no evidence of enhancement.

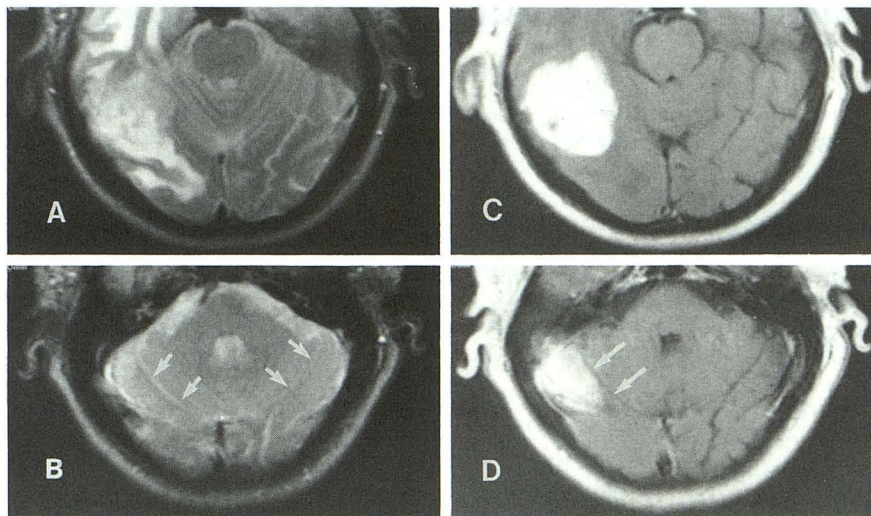


Fig. 2. Axial T2-weighted images (2500/100/1) from cranial (A) to caudal (B) show abnormal signal change in the right temporo-parietal region. In retrospect, there is very slight hyperintensity in the right occipital region (arrows) relative to the left.

C, D, Postcontrast T1-weighted images (C, D) corresponding to A and B, obtained immediately after intravenous injection of 0.2 mmol/kg gadoteridol, show areas with abnormal enhancement in the right occipital lobe (arrows) without associated T2 signal changes.

lesions showed increased signal intensity on delayed images (30 minutes), there was no increase in frequency, by delayed imaging, in the detection of abnormal enhancement beyond the zone of T2-weighted abnormality regardless of the dose used. There was no consistent relationship between the detection of abnormal enhancement beyond areas of T2 signal changes and tumor grade. The histology of this series was dominated by glioblastoma multiforme, which when studied with high-dose gadoteridol showed enhancement beyond areas of T2 signal changes. However, enhancement beyond the areas of T2 signal abnormality were also observed in lower grade gliomas (astrocytoma and ganglioglioma) studied with both high and standard doses.

Discussion

MR is the imaging modality of choice in the evaluation of central nervous system (CNS) tu-

mors. A drawback of the noncontrast MR imaging is the inability to differentiate peritumor vasogenic edema from the tumor based on T1- and T2-weighted images (2,6-9). Although T2-weighted imaging is sensitive to pathologic changes in water content in the brain parenchyma, the subtle differences in the signal intensity of the tumor and vasogenic edema cannot be differentiated reliably using standard pulse sequences. However, with the application of standard-dose contrast agent (0.1 mmol/kg gadopentetate dimeglumine), tumor, particularly metastatic, can be better differentiated from peritumor edema (2,6-9,15). Like ours, these studies using the dose of 0.1 mmol/kg have shown that the lesion size detected by T2-weighted images (lesion plus vasogenic edema) is typically larger than the area with abnormal enhancement, and the area of abnormal enhancement is usually

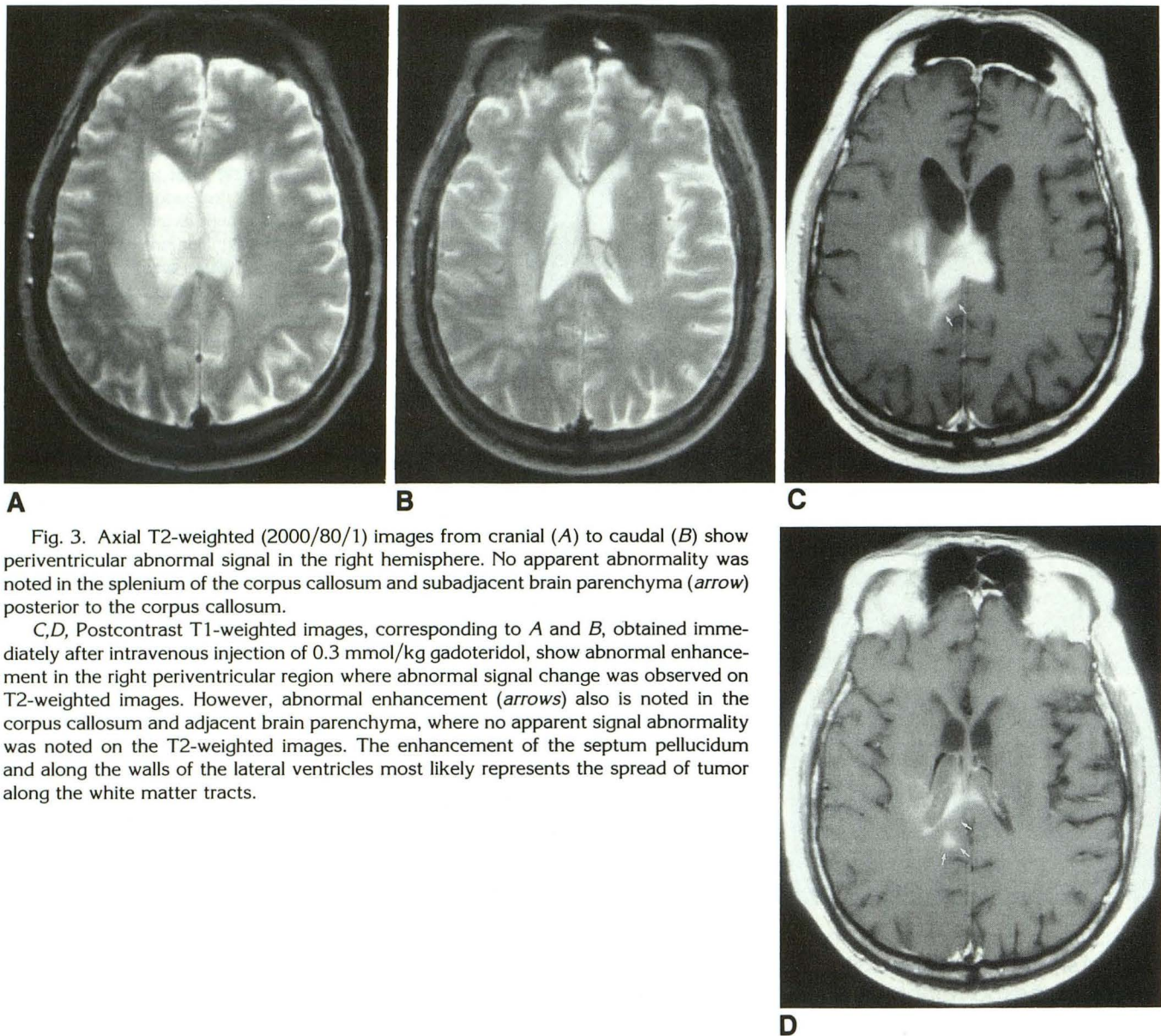


Fig. 3. Axial T2-weighted (2000/80/1) images from cranial (A) to caudal (B) show periventricular abnormal signal in the right hemisphere. No apparent abnormality was noted in the splenium of the corpus callosum and subadjacent brain parenchyma (arrow) posterior to the corpus callosum.

C, D, Postcontrast T1-weighted images, corresponding to A and B, obtained immediately after intravenous injection of 0.3 mmol/kg gadoteridol, show abnormal enhancement in the right periventricular region where abnormal signal change was observed on T2-weighted images. However, abnormal enhancement (arrows) also is noted in the corpus callosum and adjacent brain parenchyma, where no apparent signal abnormality was noted on the T2-weighted images. The enhancement of the septum pellucidum and along the walls of the lateral ventricles most likely represents the spread of tumor along the white matter tracts.

located within the zone of T2-weighted abnormality.

Recent studies, however, have shown that both computed tomography and MR studies without or with conventional contrast agents and standard doses (0.1 mmol/kg) may not always be able to delineate the true extent of involvement of primary CNS tumors, particularly gliomas (3,4,10-13). These studies showed that some gliomas may infiltrate beyond the margins of vasogenic edema and enhancement on contrast-enhanced computed tomographic images and the zone of T2-weighted abnormality on MR images. Using stereotactic biopsies, Greene et al (10), Kelly et

al (11), and Earnest et al (3) found malignant astrocytomas outside the zone of T2-weighted abnormality. Kelly et al (11) also reported grade II and III astrocytomas in half of the specimens obtained outside the zone of T2-weighted abnormality. In a study correlating postmortem MR imaging and neuropathologic findings of glioblastoma multiforme, Johnson et al (12) showed that tumor cells without edema were infiltrating 3 to 5 cm beyond the abnormality demonstrated on T2-weighted images. This finding was generally thought to be related to the infiltrative, rather than expansive, growth of some gliomas that may not exhibit associated vasogenic edema.

Local growth and spread of primary CNS tumors are dependent on the cell type, location, and surrounding brain structures. Russell and Rubinstein (1) demonstrated that the local spread of ependymomas, pineocytomas, and choroid plexus papillomas is by expansion rather than infiltration, except in the malignant counterparts. Oligodendrogliomas, astrocytomas, cerebellar astrocytomas, cerebral neuroblastomas, and glioblastomas may be well circumscribed grossly, but exhibit various degrees of infiltration microscopically, although this zone of proliferation is frequently narrow. Cerebral and brain stem astrocytomas as well as gliomas of the anterior optic pathway typically exhibit diffuse infiltrative growth (1). Matsukado et al (16) showed that 25% of primary gliomas do not form a definite mass or destruct preexisting tissues. Without a definite tumor mass, sufficient tumor density per voxel, vasogenic edema, and contrast enhancement from the infiltrating tumor, the exact border of the tumor may be difficult to demonstrate by standard-dose MR examinations.

Although it is known that the signal intensity (and lesion conspicuity) of CNS lesions increases proportionately with the dose of MR contrast agent (17,18), it is commonly accepted that the standard dose (0.1 mmol/kg) is adequate for evaluating brain lesions. In our study, gliomas evaluated with higher doses of contrast did show a higher frequency of abnormal enhancement beyond the zone of T2-weighted abnormality. It is possible that the tumor located beyond the zone of T2-weighted abnormality in the studies reported by Greene et al (10), Kelley et al (11), Johnson et al (12), and Earnest et al (3) may be better delineated using higher doses of contrast agent, as seen in our study. This is probably related to the improved lesion signal or lesion contrast by the higher dose of contrast agent. Those areas of tumor involvement not demonstrated by T2-weighted and/or standard-dose contrast MR images may have a better chance of being detected by a higher dose of contrast material.

The cause of tumor enhancement without associated vasogenic edema is unknown. Although it has been shown that the use of a contrast agent can detect a breakdown in the blood-brain barrier, even without the associated vasogenic edema, particularly in small lesions in the cortical and subcortical region (19,20), it is generally thought that the development of vasogenic edema and contrast enhancement are coexistent and related

to the breakdown of the blood-brain barrier, which allows contrast agents as well as water, protein, and other substances to penetrate the extracellular space (3). Theoretically, if there is a break in the blood-brain barrier, water molecules, which are small, should be able to escape from the intravascular space into the brain interstitium much more easily than much larger-sized contrast molecules such as gadopentetate dimeglumine or gadoteridol. This may explain why the extent of vasogenic edema is usually larger than the area of contrast enhancement.

Our finding of greater enhancement in areas without abnormal T2 signal changes in large gliomas located in both the peripheral and deep white matter using higher contrast doses is different from the typical findings of CNS tumors and is difficult to explain without using animal models. Our results, however, cannot be explained fully by the frank disruption of the blood-brain barrier alone, in which excess water should leak out more easily into the brain interstitium than contrast agent, especially in the deep white matter (20). The difference in the enhancement pattern between gliomas (without signal abnormality on T2-weighted images) and other tumors (with significant amount of edema), such as metastases, requires further investigation. We speculate that this phenomenon may be related in part to the difference in the degree of integrity of the blood-brain barrier within various portions of the glioma (1,21) and between gliomas, as well as to metastasis and the inflammatory reaction of the surrounding brain tissue (22).

Although the degree of enhancement generally is proportional to the degree of anaplastic elements in gliomas (3,21), occasionally high-grade gliomas show little or no enhancement (5,21), whereas some low-grade gliomas show intense enhancement (3). In addition, more anaplastic elements or poorly differentiated cells are usually found in the center of high-grade gliomas, whereas their peripheries contain better differentiated cells (1,21). Therefore, it is possible that the degree of blood-brain barrier breakdown in various gliomas and even in different portions of the same glioma may not always be the same. The peripheral portion of the glioma may have a more intact blood-brain barrier with better differentiated cells than the central portion. The degree of leakage of contrast agent, therefore, may be less in the periphery and may require a higher dose of contrast agent to be appreciated (1,5).

In addition, the growth of brain tumors relies on the development of a new blood supply (neovasculature) to satisfy the nutrient requirement. The development of neovasculature within brain parenchyma is dependent on angiogenesis factors from the original tumoral cells, primary or metastatic (1). The neovasculature of brain metastases with primary sites outside the CNS, such as breast, lung, or colon, is likely to be a "non-CNS" vessel that does not have a highly selective barrier like the blood-brain barrier. Therefore, brain metastases more likely will demonstrate intense enhancement within the zone of T2-weighted abnormality because of the near-complete absence of the blood-brain barrier. Conversely, angiogenesis factors from primary CNS tumors such as gliomas are likely to give rise to neovasculature of neural origin that may exhibit some properties of the blood-brain barrier. Therefore, in the primary tumor, we can speculate that the blood-brain barrier may be intact, partially intact, or completely disrupted. The degree of leakage of contrast material into the extracellular space in gliomas may not always be the same and possibly less than that in metastatic non-CNS tumors.

The lesser degree of inflammatory reaction associated with gliomas than with metastasis also affects the pattern of contrast enhancement. CNS metastases are heterogeneous in relation to the brain parenchyma and usually have rapid growth within a short period of time. Therefore, they tend to induce a greater amount of inflammatory reaction, which results in the breakdown of the blood-brain barrier and vasogenic edema (22). Gliomas usually grow slowly over a long period of time and infiltrate a long distance without inducing a significant inflammatory reaction or vasogenic edema (1,16).

In our study, the area of enhancement beyond the zone of T2-weighted abnormality was greater in high-dose examinations than in standard- and low-dose examinations. The mechanism for enhancement beyond the zone of T2-weighted abnormality in gliomas with high doses of contrast agent is not known, although a previous study showed that the accumulation of contrast material is dependent on the concentration of contrast agent used (18) and the imaging time after contrast administration (7,23) in addition to the breakdown of the blood-brain barrier with an intact vascular supply to the tumor. It is clear that the observation that we made in this study cannot be fully explained by the breach in the blood-brain barrier alone. Rather, it may also be

related to local blood pooling in the intravascular space, retention of contrast agents by neoplastic cells, or passage of contrast into the extravascular space caused by the fenestrated neocapillaries. Although all gliomas studied with high-dose examination showed enhancement extended beyond the zone of T2-weighted abnormality, we do not believe that these findings will always be observed in a large series, because some high-grade gliomas may have completely intact blood-brain barrier and, therefore, will not show enhancement even with a higher dose. Similarly, despite a greater area of enhancement, it may not always be possible to outline the extent of involvement, because the MR examination, even with the high dose, has its limited resolution and cannot detect microscopic tumors.

In conclusion, our study with a small number of patients showed that the abnormal enhancement beyond the zone of T2-weighted abnormality is seen more frequently with high-dose examinations. The underlying pathophysiology of our findings remains unclear, although we speculate that the increased contrast pooling of higher doses of contrast agent in the intravascular space of the glioma with a partially intact blood-brain barrier may be the explanation for abnormal enhancement without associated T2-weighted signal abnormality.

References

1. Russell DS, Rubinstein LJ. *Pathology of tumors of the nervous system*, 5th ed. Baltimore: Williams & Wilkins, 1989:1-500.
2. Mihara F, Hirakata R, Hasuo K, et al. Gd-DTPA administered MR imaging of intracranial mass lesions: a comparison with CT and precontrast MR. *Radiat Med* 1989;7:227-235
3. Earnest F, Kelly PJ, Scheithauer BW, et al. Cerebral astrocytomas: histopathologic correlation of MR and CT contrast enhancement with stereotactic biopsy. *Radiology* 1988;166:823-827
4. Burger PC, Heinz ER, Shibata T, Kleihues P. Topographic anatomy and CT correlations in the untreated glioblastomas multiforme. *J Neurosurg* 1988;68:698-704
5. Butler AR, Horll SC, Kricheff II, Shannon MB, Budzilovich GN. Computed tomography in astrocytomas. *Radiology* 1978;129:433-439
6. Carr DH. The use of proton relaxation enhancers in magnetic resonance imaging. *Magn Reson Imaging* 1985;1985:17-25
7. Schorner W, Kazner E, Laniado M, Sprung C, Felix R. Magnetic resonance tomography of intracranial tumors: initial experience with the use of the contrast medium gadolinium-DTPA. *Neurosurg Rev* 1984;7:303-312
8. Graif M, Steiner RE. Contrast-enhanced magnetic resonance imaging of tumors of the central nervous system: a clinical review. *Br J Radiol* 1986;59:865-873
9. Agnoli AL, Jungmann D, Lochner B. Magnetic resonance imaging of brain tumors: application of gadolinium-DTPA and comparison to computed tomography. *Neurosurg Rev* 1987;10:25-29

10. Greene GM, Hitchon PW, Schelper RL, Yuh W, Dyste GN. Diagnostic yield in CT-guided stereotactic biopsy of gliomas. *J Neurosurg* 1989;71:494-497
11. Kelly PJ, Dumas-Duport C, Kispert DB, Kall BA, Scheithauer BW, Illig JJ. Imaging-based stereotactic serial biopsies in untreated intracranial glial neoplasms. *J Neurosurg* 1987;66:865-874
12. Johnson PC, Hunt SJ, Drayer BP. Human cerebral gliomas: correlation of postmortem MR imaging and neuropathologic findings. *Radiology* 1989;170:211-217
13. Lilja A, Bergstrom K, Spannare B, Olsson Y. Reliability of computed tomography in assessing histopathological features of malignant supratentorial gliomas. *J Comput Assist Tomogr* 1981;5:625-636
14. Runge VM, Bradley WG, Brant-Zawdzki MN, et al. Clinical safety and efficacy of gadoteridol: a study in 411 patients with suspected intracranial and spinal disease. *Radiology* 1991;181:701-709
15. Felix R, Schorner W, Laniado M, et al. Brain tumors: MR imaging with gadolinium-DTPA. *Radiology* 1985;156:681-688
16. Matsukado Y, MacCarty CS, Kernohan JW. The growth of glioblastoma multiforme (astrocytomas, grades 3 and 4) in neurological practice. *J Neurosurg* 1961;18:636-644
17. Niendorf HP, Laniado M, Semmler W, Schorner W, Felix R. Dose administration of gadolinium-DTPA in MR imaging of intracranial tumors. *AJNR Am J Neuroradiol* 1987;8:803-815
18. Yuh WTC, Fisher DJ, Engelken JD, et al. MR evaluation of CNS tumors: dose comparison study with gadopentetate dimeglumine and gadoteritol. *Radiology* 1991;180:485-491
19. Runge VM, Clanton JA, Price AC, et al. The use of Gd-DTPA as a perfusion agent and marker of blood-brain barrier disruption. *Magn Reson Imag* 1985;3:43-55
20. Healy ME, Hesselink JR, Press GA, Middleton MS. Increased detection of intracranial metastases with intravenous Gd-DTPA. *Radiology* 1987;165:619-624
21. Castillo M, Scatliff JH, Bouldin TW, Suzuki K. Radiologic-pathologic correlation: intracranial astrocytoma. *AJNR Am J Neuroradiol* 1992;13:1609-1616
22. Morioka T, Baba T, Black KL, Steit WJ. Inflammatory cell infiltrates vary in experimental primary and metastatic brain tumors. *Neurosurgery* 1992;30:891-896
23. Yuh WTC, Engelken JD, Muhonen MG, Mayr NA, Fisher DJ, Ehrhardt JC. Experience with high-dose gadolinium MR imaging in the evaluation of brain metastases. *AJNR Am J Neuroradiol* 1992;13:335-345