

Are your **MRI contrast agents** cost-effective?

Learn more about generic **Gadolinium-Based Contrast Agents**.



FRESENIUS
KABI

caring for life

AJNR

Death after cerebral angiography: an unusual cause.

W R Smoker and A J Kuta

AJNR Am J Neuroradiol 1994, 15 (6) 1192-1193

<http://www.ajnr.org/content/15/6/1192.citation>

This information is current as
of April 20, 2024.

LETTERS

Intracranial Aneurysm Not Seen on Conventional Angiography

I wish to comment on the recently published case report by Curnes et al, "MR Angiographic Demonstration of an Intracranial Aneurysm Not Seen on Conventional Angiography" (1). The detection and failure to detect the source of spontaneous subarachnoid hemorrhage, with particular reference to ruptured aneurysm, were well discussed in the commentary to that article by Heinz (2). He made the statement that he "has no good explanation why the conventional angiogram was negative, but the magnetic resonance angiogram (MRA) was positive," and Curnes et al stated that "we can only speculate on the reason the initial angiogram did not show the aneurysm." Having inspected only the available, published illustrations and not the original films, I probably should not be so brash as to suggest that I know why. Nevertheless, I do believe that I know the reason(s). Reinforced by the agreement of several local colleagues, I am emboldened to write this letter.

As is frequently the case when an aneurysm is "missed" on the initial cerebral angiography, the lumen of the aneurysm may be relatively small and difficult to project clear of adjacent, often tortuous vessels. This probably played a role in the present case.

Although subtracted images are a great aid in cerebral angiography, there occasionally may be certain pitfalls in their interpretation, which may be caused by technical factors. For example, it may be difficult to see an aneurysm, ulceration, or stenosis through a dense column of contrast material on a subtracted image, including digital subtraction angiography. Conventional, unsubtracted images on occasion actually may demonstrate such abnormalities to better advantage. This almost certainly is part of the explanation for the failure to see any evidence of the aneurysm in their Figure 1B. In Figure 1D, an extra dense collection of contrast material is seen at or adjacent to the junction between the anterior communicating artery and the right anterior cerebral artery, but admittedly it is impossible to differentiate the possible presence of an aneurysm from vessel tortuosity on the basis of that projection alone.

However, as the authors pointed out, Figure 1A shows a focal clot in the anterior interhemispheric fissure, which is extremely strong evidence that there almost certainly must be an aneurysm in the anterior communicating artery region. Indeed, I believe that Figure 1C does show an aneurysm in exactly the same location where it subsequently was demonstrated on MRA and repeat conventional angiography. At the very least, its presence at the junction between the anterior communicating artery and the right anterior cerebral artery should be strongly suspected, based on the appearance of Figure 1C. Contrast material in this area is seen in a larger area than can be accounted for on the basis of diameter size of any adjacent

artery. If this appearance were caused by tortuosity of vessels, either such vessel tortuosity would be apparent, or superimposition of two segments of the same artery or two different arteries would produce an *increased*, approximate doubling of contrast density, which is not the case. Projection of an artery on end likewise would produce a markedly increased contrast density, entirely different from the uniform, single vessel and/or lumen of aneurysm density shown in the pertinent area. Increased (*addition of*) contrast density caused by superimposition of vessels or a vessel seen on end is illustrated well in Figure 1C on the *left*, at or near the junction of the *left* anterior cerebral and anterior communicating arteries.

Admittedly, the angiographic image of *left* common carotid angiography reproduced in Figure 1C does not demonstrate this area to optimal advantage, in my opinion. Although contrast material is demonstrated as very opaque material in the left internal carotid artery and middle cerebral artery branches, the subtraction technique used for that projection does not demonstrate as dense contrast material in the anterior communicating artery region. Use of the same projection with injection of the *right* internal or common carotid artery probably would have resulted in better contrast visualization of this area, especially of the *right* anterior cerebral artery and its junction with the anterior communicating artery, as was essentially done (and achieved) for the repeat conventional angiography illustrated in Figure 3B. The repeat right carotid angiography showing the aneurysm in Figure 3B admittedly was done with a slightly different projection, but the projection used in Figure 1C probably would have worked equally well.

Although difficult to determine on the basis of only the MRA reproduced in Figure 2, I wonder whether *some* of the appearance that may have been attributed to the aneurysm actually may represent vessel superimposition or the anterior cerebral artery projected on end at the base of the aneurysm (note high signal intensity area). This could contribute to an *apparent* but *false* "better" demonstration of the aneurysm. In fairness to the authors, I realize that other, unpublished MRA projections might clarify this possibility. Nevertheless, a generally acknowledged problem in diagnosing small cerebral aneurysms, especially by means of MRA, is their differentiation from arterial tortuosity. The technical improvements with MRA have been rapid and enormously impressive, but the spatial resolution of MRA still does not equal that readily obtainable with conventional cerebral angiography of high technical quality.

When an aneurysm is not identified by cerebral angiography, it has been my experience that a combination of several factors often is responsible. I believe that the case report by Curnes et al is a published illustration of such an occurrence. However, albeit difficult to appreciate on the published images, as discussed above, I believe that this

case is *not* primarily an example of the initial conventional cerebral angiography failing to demonstrate or "detect" the aneurysm. Rather, I think that it is an example of *not* having used optimally the conventional angiographic technique(s) at our disposal. Most of all, I regard it as an excellent example of failing to make the correct angiographic observation(s) and interpretation. I challenge the authors to review carefully their original examination and obtain different subtraction images for more optimal demonstration of the anterior communicating artery region, which I suspect may well demonstrate the presence of the aneurysm more clearly than shown in Figure 1C.

I am pleased that MRA contributed to proper care of the patient in this case. I also am pleased that the authors had the foresight to use MRA, which apparently was needed by them (or at least was *useful* to them) in this case. However, I feel that conventional cerebral angiography took a "bum rap" by publication of this case, as I believe has happened also in other communications (for example, at the last American Society of Neuroradiology meeting in Vancouver) comparing excellent-quality MRA with suboptimally performed and interpreted conventional cerebral angiography.

Trygve O. Gabrielsen
 Department of Radiology
 University of Michigan Medical Center
 Ann Arbor

References

1. Curnes JT, Shogry ME, Clark DC, Elsner HJ. MR angiographic demonstration of an intracranial aneurysm not seen on conventional angiography. *AJNR Am J Neuroradiol* 1993;14:971-973
2. Heinz ER. Commentary: aneurysms and MR angiography. *AJNR Am J Neuroradiol* 1993;14:974-977

Reply

We would like to thank Dr. Gabrielsen for his careful review of our paper. His somewhat strident tone gives us new insight into the University of Michigan mascot, the wolverine.

Aside from arguing about the specific images from our case report, Dr Gabrielsen apparently rejects even the

possibility that an aneurysm might be seen at MRA but not at conventional cerebral angiography. This seems to be a rather extreme position.

We agree that unsubtracted images are often helpful in finding the aneurysm. In this case they were not (Fig 1). As requested, an unsubtracted view of one of our original illustrations is presented here (Fig 1A), along with the base view (Fig 1B) from a right common carotid artery injection at the time of the first angiogram. It does give us the opportunity to make the point that the workup of subarachnoid hemorrhage should be primarily done with cut-film, not digital, technique, to allow the examination of *both* subtracted and unsubtracted images.

To address the question of overlapping vessels, we reprocessed the MRA using a General Electric Windows work station with MRAngio software (version 1.1.7). This program not only allows one to isolate a specific circulation (ie, right internal carotid artery), but one may then rotate the remaining vessels in an infinite variety of angles to choose the best view. Figure 2 shows the aneurysm at the junction of the anterior communicating artery with the right anterior cerebral artery after electronic removal of the posterior circulation and most of the left anterior circulation, proving that no overlying vessels caused the density. The presence of a neck on the aneurysm proves that it is not a superimposition of tortuous vessels. Real-time rotation of the isolated circulation readily confirms the site of the aneurysm and can provide the surgeon with helpful three-dimensional visualization of the approach before craniotomy.

It was no surprise to us that an anterior communicating artery aneurysm was eventually found; that was the working hypothesis from the time the interhemispheric clot was discovered on computed tomography (CT). However, we could not convince ourselves that an aneurysm was present on the first study. A *double density* is not sufficient proof to commit a patient to an exploratory craniotomy.

Demonstration of anterior communicating aneurysms is often difficult. A recent article from New York University Medical Center described four cases in which the surgeons successfully operated on patients with anterior communicating artery aneurysms despite negative arteriography, basing their approach solely on the presence of interhemispheric fissure clot (1). Although we have no experience with this form of management, the article is a timely

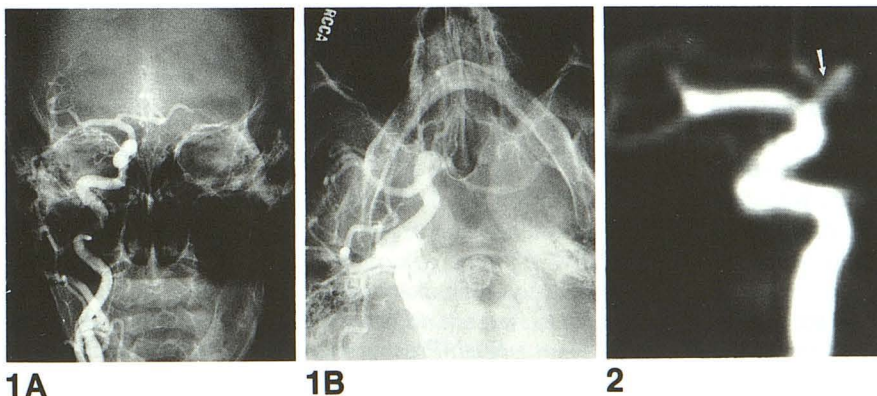


Fig. 1. A, Anteroposterior right common carotid artery with left cross-compression fails to reveal an anterior communicating artery aneurysm.

B, Right common carotid artery injection, base view. No aneurysm is seen.

Fig. 2. Three-dimensional phase-contrast MRA of the right anterior circulation, and both anterior cerebral arteries, left anterior oblique projection. The aneurysm neck is marked with an arrow.

statement that even in the *best* neuroradiologic centers, it can be impossible to demonstrate some aneurysms acutely. Our hypothesis remains that either clot, alterations in cerebral perfusion pressure, or both prevented the visualization of the aneurysm on the first study.

We suspect that Dr Gabrielsen is concerned that we, and others, are cleverly building a coffin into which we plan eventual interment of conventional cerebral angiography. This is not the case. We continue to recommend high-resolution, cut-film angiography in the workup of subarachnoid hemorrhage, with repeat angiography at 1 week in negative cases. However, we also predict that a large number of neuroradiologists will continue to find it irresistible to test the limits of MRA for aneurysms, be it for screening, flow dynamics in giant aneurysms, evaluating vasospasm, or in negative angiography of subarachnoid hemorrhage. We will continue to practice high-quality cerebral angiography and MRA, and use each to their best advantage.

John T. Curnes
Mark E. C. Shogry
David C. Clark
Greensboro Radiology Associates
Henry J. Elsner
Guilford Neurosurgical Associates
Greensboro, NC

Reference

1. Jafar JJ, Weiner HL. Surgery for angiographically occult cerebral aneurysms. *J Neurosurg* 1993;79:674-679

Death after Cerebral Angiography: An Unusual Cause

We recently had an unfortunate fatality after cerebral angiography. A 56-year-old woman had a subarachnoid hemorrhage for which she underwent emergency angiography and aneurysm clipping of a left middle cerebral artery genu aneurysm. Angiography was performed via a single-wall arterial puncture with a 5-F catheter. She had a moderate-size right groin hematoma which was stable. Her postoperative course was complicated by a left lower lobe pneumonia successfully treated with antibiotics. Nine days after aneurysm clipping she underwent repeat cerebral angiography as part of the Tirilazad study protocol. Because of the right groin hematoma, repeat angiography was performed via a double-wall puncture, left femoral artery approach with a 5-F catheter.

Thirty minutes after the patient's return to her room from the second angiogram, she became acutely hypotensive, necessitating emergency intubation and intravenous pressor therapy. Acute myocardial infarction was suspected, but cardiac evaluation was entirely normal. The diagnosis of intraabdominal hemorrhage was also considered, but the patient denied any discomfort or pain, and the abdomen was nondistended and normal to palpation.

She continued to deteriorate, required multiple transfusions during the ensuing 14 hours to maintain a falling hematocrit, the reasons for which remained obscure at the time, and finally had fatal cardiopulmonary arrest, resistant to all resuscitative measures, including open-heart massage.

Autopsy revealed extensive retroperitoneal and intraperitoneal hemorrhage and a 5-cm patent dissection and luminal tear of the right common femoral artery. Death was attributed to exsanguination via the dissected right common femoral artery.

Our opinion is that the dissected right common femoral artery, when under normal pressure, presented no major complication, aside from a persisting hematoma. However, when subjected to 20 minutes of markedly elevated blood flow during compression of the left femoral artery after the second angiogram, the luminal tear became enlarged, allowing increased blood flow, ultimately leading to the patient's death.

Wendy R.K. Smoker
A. John Kuta
Department of Radiology
Medical College of Virginia
Richmond

Reply

The aforementioned case both in timing and in clinical sequence typifies a postangiography puncture pseudoaneurysm with subsequent rupture. The patient had a "moderate size" right groin hematoma, which in all likelihood concealed a pseudoaneurysm. Most of these will occlude with time or at least become palpable once the adjacent hematoma resolves. In this case, however, the patient was unlikely to complain of right groin pain or undergo duplex sonography to evaluate the right groin for pseudoaneurysm. Unfortunately, she probably did have a local increase in blood pressure in her right lower extremity arterial system after the repeat angiogram from the contralateral side. This was probably enough to prompt rupture of the pseudoaneurysm into the adjacent tissues, retroperitoneum, and intraperitoneum, findings of which would be indistinguishable from the descriptions described at autopsy.

In an article evaluating patients treated surgically for postangiography pseudoaneurysms, a mean time from angiography to rupture was 2.8 days (with a range of 1 to 6), and multiple regression analysis demonstrated that risk factors for rupture included increased patient age, presence of peripheral vascular disease, and abnormal liver function tests (1).

Michael C. Brunner
Terence A. S. Matalon
Department of Diagnostic Radiology
Rush-Presbyterian-St. Luke's Medical Center
Chicago, Ill

Reference

1. Graham AN, et al. Risk of rupture of post angiographic femoral false aneurysm. *Br J Surg* 1992;79:1022-1025

An Algorithm for Imaging and Treatment of Patients with Back Pain

We formed a multidisciplinary task force to create recommendations to facilitate the workup and treatment of patients with back pain. The task force consisted of physicians from Ambulatory Care, Anesthesiology, Neurology, Neuroradiology, Neurosurgery, Orthopedics, the Pain Program, and Rehabilitation Medicine. The recommendations were incorporated into an algorithm. Patients without a defined neurologic deficit are spared MR because their treatment will be conservative regardless of the imaging findings. We consider MR the imaging modality of choice and perform CT only when there is a contraindication to MR. The algorithm was implemented by discussion with the clinical services and by the neuroradiologist, who returned nonconforming imaging consultation requests with a letter of explanation and a copy of the algorithm.

During the first 4 months of implementation about 20% of requests were received with stated history clearly outside the guidelines of the algorithm. After reevaluation 20% to 30% of these had clinical information added, which prompted performance of the examination. By the last 4 months of the first year of implementation, the number of nonconforming requests had diminished to 5% with only 1% ultimately canceled. The number of requests received in total did not change markedly during the year.

Many factors, including economics, rapid introduction of technology, and data showing high levels of inappropriate care, are pressuring the development of practice guidelines (1). Although these ideally would be based on results of outcomes research, such data are generally not yet available. A federal agency is conducting many such studies, through patient outcomes research teams; one is on back pain (Agency for Health Care Policy and Research, 18-12 Parklawn Bldg, Rockville, MD 20857). It was started in September 1989 and is expected to finish in August 1994. In the meantime, we have formulated and implemented an algorithm based on clinical consensus.

Consensus methods are being used increasingly to solve problems in medicine and health and were reviewed by Fink and associates (2). Our consensus group was not as formally structured as the types they defined but did parallel several of their recommendations. Consensus participants were selected as representative of their profession and had the power to implement the findings.

Fink and coworkers also note that the impact of consensus studies can be improved through careful dissemination of the findings. Initial implementation was done mainly at the level of the neuroradiologist reviewing imaging requests. This led to confusion on the part of clinicians who were unaware of the algorithm. This was resolved by discussions at clinical conferences. Clinicians also noted

that patients themselves often demand imaging studies, pointing out the need for patient-education materials. The central position of the neuroradiologist in the clinical neurosciences team seemed to be helpful in terms of facilitating clinician education.

We have used similar consensus methods to create an algorithm for patients suspected of having spinal metastases.

The final effect of our algorithm is not clearly defined by a permanent change in numbers of scans requested or performed. There has been a marked change in the clinical information provided with requests. We believe that there has been an element of increased selectivity on the part of clinicians in ordering scans, but mainly more careful inclusion of history to assure that requested scans are indicated. Our study suggests that applying algorithms developed by consensus studies, for determining the necessity of medical diagnostic procedures, will not necessarily result in reduced health-care expenditures.

Craig N. Linden

Department of Radiology

Maria Alfonso

Section of Pain Management and Rehabilitative Services

Department of Internal Medicine

University of South Florida

College of Medicine

Tampa

References

1. Brook RH. Practice guidelines and practicing medicine: are they compatible? *JAMA* 1989;262:3027-3030
2. Fink A, Kosecoff J, Chassin M, Brook RH. Consensus methods: characteristics and guidelines for use. *Am J Public Health* 1984;74:979-983

MR of Cerebral Aspergillosis: Different Patterns in the Same Patient

We read with great interest the paper of Cox et al (1) on MR and histopathologic correlation of cerebral aspergillosis in an immunosuppressed patient. CT showed a large low-attenuation lesion with mass effect and surrounding edema and a hyperdense rim at the periphery of the lesion without contrast enhancement. MR demonstrated a low-signal-intensity rim on proton density- and T2-weighted images.

We encountered a case of intracranial multifocal aspergillosis caused by hematogenous spread from the lungs in an immunosuppressed patient (chronic myelocytic leukemia and bone marrow transplantation) which healed with stereotactic surgical aspiration and aggressive antifungal therapy (Amphotericin B and Itraconazole). There were no important neurologic sequelae. In our case one of the lesions (left parietooccipital) on unenhanced CT (Fig 3) and long-repetition-time MR (Fig 4A) was similar to Cox et al's

case, but there was contrast enhancement (Fig 4B) of the inner part of the peripheral rim. This contrast enhancement may be caused by granuloma formation as previously reported (2-4), indicating ability of the host defense mechanisms to encapsulate the fungus.

However, cases in which MR was described there was no low-signal peripheral rim of the granulomas (3, 4), and these lesions presented as did the right temporooccipital lesion of our patient (Fig 4) (ie, intermediate-signal lesions within surrounding high-signal edema on proton density- and T2-weighted images and low-signal lesions on T1-weighted images with heterogeneous contrast enhancement). In Gupta et al's case (2) there was a low-signal peripheral rim on long-repetition-time MR images attributed to a pial vascular rim.

In Cox et al's case this peripheral rim related to a dense population of hyphal elements and blood breakdown products (maybe deoxyhemoglobin) in a lesion imaged 1 day after the onset of neurologic symptoms. Histologically the center of the lesion consisted of areas of coagulative fungal necrosis.

Cox et al refer to an MR study of invasive pulmonary aspergillosis. In this study (5) the lesions had a targetlike appearance where the center represented coagulative fungal necrosis and the peripheral rim of high signal intensity on T1- and T2-weighted images corresponded to subacute hemorrhage (in 5- to 15-day-old lesions). This peripheral rim enhanced after administration of gadopentetate dimeglumine and peripheral concentric inflammation associated

with hyperemia was supposed to account for this enhancement.

In our case this peripheral rim appeared after several weeks of evolution. There was at the beginning a hypodense lesion with faint contrast enhancement on CT, consistent with an early infarction (Fig 5) caused by initial vascular occlusion by fungal hyphae. Several weeks later a granuloma appeared with a hyperdense enhancing peripheral rim on the CT scan. The MR scan was done 1 month after stereotactic aspiration of the left parietooccipital lesion. This aspiration of 15 ml of purulent material showed on microscopic examination the characteristic septate branching hyphae in coagulative fungal necrosis.

Therefore, the low signal of the peripheral rim on T2-weighted images could be related to the presence of blood breakdown products (hemosiderin of chronic hemorrhage) caused by hemorrhagic surgical aspiration, but because the hyperdense rim was already present on CT scans before surgery (Figure 3) these blood breakdown products also could originate from spontaneous hemorrhage of the aspergillus lesion.

As in Cox et al's case the center of the lesion in our case probably represented coagulative fungal necrosis, because it was present in the center of the cavity at the time of stereotactic aspiration. In Cox et al's case, despite the similar CT and MR appearance, there was no enhancement after iodinated intravenous contrast administration, probably because of the short delay (1 day) between the scan and the onset of symptoms.

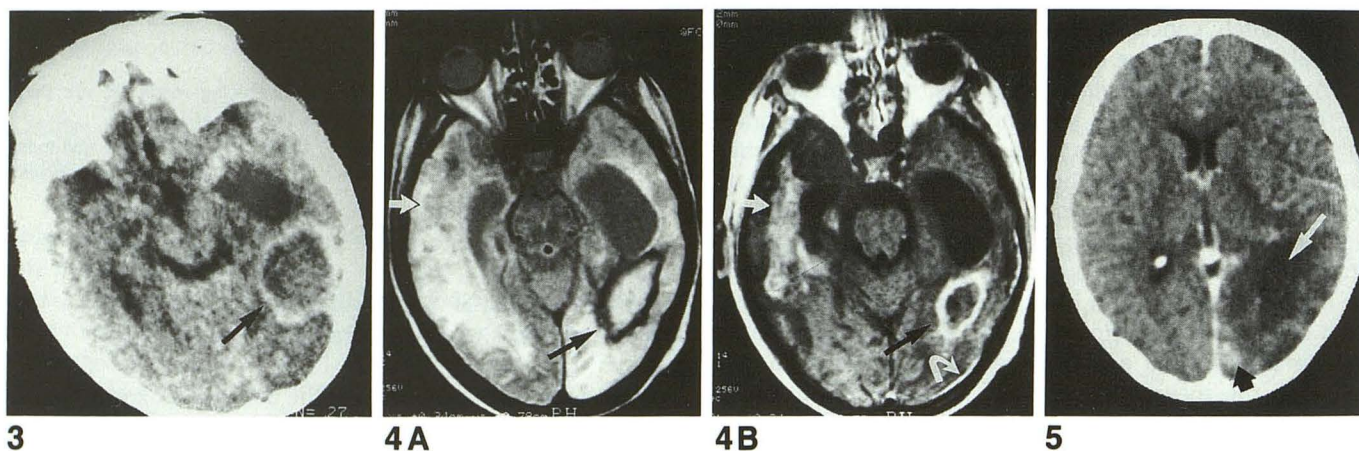


Fig. 3. Nonenhanced CT scan obtained 1 month before stereotactic aspiration. Low-density lesion with hyperdense peripheral rim (arrow) in the left parietooccipital region (the right temporooccipital lesion is not visible on this section).

Fig. 4. MR scan (0.5-T machine) 1 month after stereotactic aspiration.

A, Proton-density image (1940/40 [repetition time/echo time]). The left lesion has a high-signal center with a low-signal peripheral rim (arrow) and high-signal surrounding edema. The right lesion (arrow) has an intermediate-signal intensity within edema.

B, Postcontrast T1-weighted image (500/20). There is enhancement of the inner part of the peripheral rim (black arrow) in the left lesion and heterogeneous enhancement of the right lesion (white arrow). There is also focal meningeal enhancement on the left (curved white arrow).

Fig. 5. First CT scan (enhanced) after the onset of neurologic symptoms. A low-density lesion (white arrow) is seen in the left parietooccipital region with mass effect on the left trigone and faint enhancement (black arrow), consistent with early infarction.

Thus cerebral aspergillosis may present different patterns depending on the lesion's age and the immunologic status of the patient: early infarction presenting as a hypodense lesion with faint or no enhancement. It could be associated with a peripheral rim of high attenuation on CT and of low signal intensity on T2-weighted MR images, when the infarction is hemorrhagic. When the host defense system is able to encapsulate the fungus, there is granuloma formation. Granulomas present as enhancing lesions with or without peripheral rims of low signal intensity on T2-weighted MR images.

Yves Miaux
Ali Guermazi
Pierre Bourrier
Department of Radiology
Beatrice Singer
Sarah Leder
Department of Hematology
Hôpital Saint-Louis
Paris, France

References

1. Cox J, Murtagh FR, Wilfong A, Brenner J. Cerebral aspergillosis: MR Imaging and histopathologic correlation. *AJNR Am J Neurocardiol* 1992;13:1489-1492
2. Gupta R, Singh AK, Bishnu P, et al. Intracranial aspergillus granuloma simulating meningioma on MR Imaging. *J Comput Assist Tomogr* 1990;14:467-469
3. Wilms G, Lammens M, Dom R, et al. MR imaging of intracranial aspergilloma extending from the sphenoid sinus in an immunocompromised patient with multiple myeloma. *J Belge Radiol* 1992;75:29-32
4. Mikhael MA, Rushovich AM, Ciric I. Magnetic resonance imaging of cerebral aspergillosis. *Comput Radiol* 1985;9:85-89
5. Herold CJ, Kramer J, Sertl K, et al. Invasive pulmonary aspergillosis: evaluation with MR Imaging. *Radiology* 1989;173:717-721

Reply

We read with great interest the communication from Drs Miaux et al regarding a single immunosuppressed

patient with multiple aspergillus lesions caused by haematogenous spread from the lungs. It is certainly gratifying to see another extremely well documented case of cerebral aspergillosis with pathologic correlation. It is through such well-correlated comparisons of pathology and radiology that imaging science continues to advance.

Exactly as in our reported case, some of the most important features of the imaged abscesses included extreme signal decreases on MR T2-weighted images. We felt that the mycoses in which the hyphal forms predominate tend to form patterns consistent with vascular occlusion and secondary abscess formation and that decreased signal was a prominent feature in the MR imaging thereof. The decreased signal might have been caused by the accretion of metallic elements such as manganese and magnesium. On the other hand, it could just have easily been caused by coagulative necrosis with hemorrhagic change in all the various forms of hemorrhage that relate to decreased signal on the T2-weighted images.

We found that in our case, however, there was no hemorrhage in the center of the lesion, and we concluded that the centers of the aspergillus lesions were believed to represent coagulative fungal necrosis, and the periphery of the lesions corresponded to subacute hemorrhage or hemorrhagic infarction. This seems to be the same conclusion reached by Miaux et al, and we would agree with the authors' contention that cerebral aspergillosis may present with different patterns, depending on the age of the infective lesions and the immunologic state of the patient. If the patient has enough functioning host defenses and is able to encapsulate the fungus, there is granuloma formation with enhancement on contrast-enhanced MR; if, as in our patient, the host-defense system is so disordered that no encapsulation can occur, then coagulative necrosis, depicted by hemorrhagic change and accretion of manganese and magnesium, is the predominant form.

F. Reed Murtagh
Joe Cox
University Diagnostic Institute
Tampa, Fla