

Are your MRI contrast agents cost-effective?

Learn more about generic Gadolinium-Based Contrast Agents.



**FRESENIUS
KABI**

caring for life

AJNR

**Devascularization of craniofacial tumors by
percutaneous tumor puncture.**

A Casasco, D Herbreteau, E Houdart, B George, P Tran Ba Huy,
D Deffresne and J J Merland

AJNR Am J Neuroradiol 1994, 15 (7) 1233-1239

<http://www.ajnr.org/content/15/7/1233>

This information is current as
of April 23, 2024.

Devascularization of Craniofacial Tumors by Percutaneous Tumor Puncture

A. Casasco, D. Herbreteau, E. Houdart, B. George, P. Tran Ba Huy, D. Deffresne, and J. J. Merland

PURPOSE: To present and evaluate a devascularization technique for hypervascular tumors of the head and neck by direct tumor puncture. **METHODS:** Tumor puncture was performed percutaneously or via natural orifices (nose and mouth). In one case, an intrasellar tumor was embolized via a transseptosphenoidal surgical approach. The embolization material used was NBCA, lipiodol, and tungsten in the majority of tumors (14 out of 17) and alcohol for 3 metastases of the calvarium. We used this technique to embolize 10 nasopharyngeal fibromas, 4 tumors of the calvarium (3 metastases and 1 hemangiopericytoma), 1 intrasellar hemangiopericytoma, and 2 glomus tumors. Reflux of blood was obtained in every case after direct puncture of the tumor. Direct injection of contrast agent into the tumor revealed local parenchymography followed by local and regional venous drainage without extravasation. **RESULTS:** Total devascularization was obtained in 14 cases, and devascularization greater than 90% was obtained in 3 cases. Thirteen tumors were totally resected without requiring blood transfusion. During surgery, the limits of the exsanguinated tumor were very well defined in every case by the black staining induced by tungsten. Of the 4 tumors embolized but not operated on (3 metastases and 1 glomus tumor), 2 metastases needed retreatment after 6 and 8 months of remission, respectively. The other metastasis is still in remission after 3 months, and the volume of the glomus tumor decreased by 80% remains unchanged after 8 months. **CONCLUSION:** This technique was initially used to devascularize tumors with difficult or dangerous intravascular access, but in view of the hemodynamic and surgical results obtained, we believe that the indications for this technique can be extended to hypervascular tumors accessible to conventional embolization.

Index terms: Head, neoplasms; Neck, neoplasms; Interventional neuroradiology, experimental

AJNR Am J Neuroradiol 15:1233-1239, Aug 1994

The value of preoperative embolization of hypervascular tumors is well established. This technique has been extensively developed by various teams during the last 15 years (1-9). The objective of these embolizations is to devascularize the tumor by the catheterization and embolization of each artery supplying the tumors. Unfortunately, these objectives are not always achieved. Most hypervascular head and neck tumors are supplied by branches of the

external carotid artery, which are easily accessible to highly selective embolization with a low risk. However, once the tumor has invaded the base of the skull, branches of the internal carotid artery and/or vertebral artery are also frequently involved. Embolization of these branches often can be performed by experienced operators but is nevertheless more complicated and potentially more dangerous than embolization of branches of the external carotid artery (5, 10). The same applies to pial participation in the blood supply of certain meningiomas, hemangiopericytomas, and hemangioblastomas (11). It is not unusual to observe hypervascular tumors that have bled, requiring emergency ligation of the external carotid artery and its branches, thus preventing a conventional intravascular approach (12). All of these hemodynamic factors mean that only a few

Received July 1, 1993; accepted after revision January 20, 1994.

From the Departments of Interventional Neuroradiology (A.C., D.H. E.H. J.J.M.), Neurosurgery (B.G.), and Ear, Nose, and Throat (P.T.B.H., D.D.), Hôpital Lariboisière, Paris, France.

Address reprint requests to Alfredo Casasco, MD, Associate Professor, Section de Neuroradiologie Interventionnelle, Hôpital Lariboisière, 2 rue A. Paré, 75010 Paris, France.

AJNR 15:1233-1239, Aug 1994 0195-6108/94/1507-1233

© American Society of Neuroradiology

Presentation of tumors and results of direct puncture

Case	Histopathology	Skull Base Extension	Vascularization			Devascular- ization	Embolic Material	Total Removal	Recurrence	Follow-up, mo
			Internal Carotid Artery	External Carotid Artery	Vertebral Artery					
1	Nasopharyngeal angiofibromas	+	+	+	—	>90%	NBCA	+	—	18
2	Nasopharyngeal angiofibromas	+	+	+	—	100%	NBCA	+	—	18
3	Nasopharyngeal angiofibromas	+	+	+	—	100%	NBCA	+	—	17
4	Nasopharyngeal angiofibromas	+	+	+	—	100%	NBCA	+	—	16
5	Metastasis	—	+	+	—	100%	Alcohol	No removal	+	20
6	Hemangiopericitoma	—	+	+	—	100%	NBCA	+	—	16
7	Nasopharyngeal angiofibromas	+	+	+	—	100%	NBCA	+	—	15
8	Nasopharyngeal angiofibromas	+	+	+	—	100%	NBCA	+	—	15
9	Glomus tumor	+	—	+	+	>90%	NBCA	+	—	14
10	Metastasis	—	+	+	—	100%	Alcohol	No removal	+	14
11	Nasopharyngeal angiofibromas	+	+	+	+	100%	NBCA	+	—	14
12	Glomus tumor	+	—	+	+	100%	NBCA	No removal	—	8
13	Nasopharyngeal angiofibromas	—	+	+	—	100%	NBCA	+	—	7
14	Nasopharyngeal angiofibromas	—	+	+	—	100%	NBCA	+	—	7
15	Metastasis	—	+	+	—	100%	Alcohol	No removal	—	6
16	Nasopharyngeal angiofibromas	+	+	+	—	100%	NBCA	+	—	6
17	Hemangiopericitoma	+	+	+	—	>90%	NBCA	+	—	3

very experienced interventional neuroradiology teams are able to overcome all of these problems and embolize successfully tumors arising in or extending to the base of the skull. It was therefore necessary to simplify this embolization technique to make it accessible to all interventional neuroradiology teams. Based on the principle of embolization of vertebral bone tumors by direct percutaneous puncture (13), we have developed, since 1992, a devascularization technique for head and neck tumors by direct tumor puncture and injection of NBCA or alcohol into the tumor capillary bed. This technique facilitates access to the tumor and decreases the risk of certain embolizations.

Materials and Methods

Since July 1992, we have embolized 10 nasopharyngeal angiofibromas, 3 metastases of the calvarium (thyroid cancer), 2 hemangiopericytomas (involving the calvarium and the sellar region), and 2 glomus tumors (see Table).

All patients were investigated by conventional radiology, computed tomography (CT), and/or magnetic resonance with intravenous injection of iodine and/or gadolinium. Diagnostic angiography was performed in every case with exploration of the internal and external carotid and vertebral arteries and, in some cases, the cervical branches of the subclavian artery. With the exception of

three metastases and one glomus tumor, all of the other tumors were operated on and submitted to histologic examination.

Informed consent was obtained before subjecting patients to the new therapeutic mode.

Topographic Data

Most of the nasopharyngeal fibromas (8 out of 10) invaded the base of the skull (see Fig 2). The 3 metastases of the calvarium were osteolytic and invaded the dura mater. A frontal hemangiopericytoma had eroded bone and was present underneath the skin (see Fig 3), whereas the other intrasellar hemangiopericytoma involved the cavernous sinus and left temporal fossa. The glomus tumors were situated in the carotid and jugular bodies with extension toward the base of the skull.

Angiographic Findings (Table)

All of the nasopharyngeal fibromas were supplied by the internal maxillary artery and, to a lesser degree, by the ascending pharyngeal artery. Internal carotid participation was detected in every case, either via its mandibular branch or via the inferolateral trunk (see Fig 2). Four patients underwent ligation of the external carotid arteries and/or their branches, and one patient underwent proximal ligation of the internal and external carotid arteries. The three metastases were supplied by the external carotid artery and pial branches of the internal carotid artery. The two hemangiopericytomas were supplied by meningeal

branches of the external carotid and internal carotid arteries (intracavernous and ophthalmic) (see Fig 3). The glomus tumors were supplied by the external carotid and vertebral arteries.

Devascularization Technique

All patients received corticosteroids (100 mg/d of hydrocortisone) 24 hours before treatment of the tumor. Treatment was performed under general anesthesia. All patients were treated in a digital subtraction angiography room with high-definition two-dimensional fluoroscopic control. Transfemoral carotid and/or vertebral artery catheterizations were performed to obtain postdevascularization films.

Tumor Puncture

The nasopharyngeal fibromas were treated via a transnasal approach in six cases (see Fig 2), a right precondylar approach in two cases, and a transvestibular (transbuccal) approach in two cases. Tumors of the calvarium and glomus tumors were treated by direct percutaneous puncture. The intrasellar hemangiopericytoma was punctured via a transseptosphenoidal surgical approach immediately before surgery. Superficial subcutaneous tumors were punctured with 19-gauge epicranial needles, and deeper tumors were punctured with standard 18-gauge lumbar puncture needles (Terumo, Japan) or Chiba 20-gauge needles. In the case of a long needle track through a region containing vital neurovascular structures (precondylar for example), we performed a single puncture with a 16-gauge Teflon sheath needle (Johnson & Johnson, Elizabeth, NJ), which was left in place and used as an introducer for the needles used for subsequent embolization. Progression of the needle was monitored by 2-D fluoroscopy. When the needle was correctly located, reflux of blood at the needle hub was obtained. After this verification, contrast agent was injected into the tumor, revealing the local tumor parenchymography, draining to regional veins without extravasation. This appearance seems to be a common denominator of all hypervascular tumors regardless of their histologic characteristics (Fig 1). Usually with a single puncture each needle was positioned in the tumor, but if there was no reflux of blood the needle had to be repositioned.

Embolization

For the metastases that were not operated on the embolization agent used was alcohol; a mixture of NBCA, lipiodol, and tungsten powder was used for the preoperative embolizations. The alcohol can be mixed with tungsten or tantalum powder for visualization of the embolization agent. NBCA and lipiodol were mixed in equal proportions. The injection was performed with a 3-mL syringe under fluoroscopic control. Several injections were necessary to devascularize the various tumor compartments (5 to 10 injections with a mean of 7). The emboli-

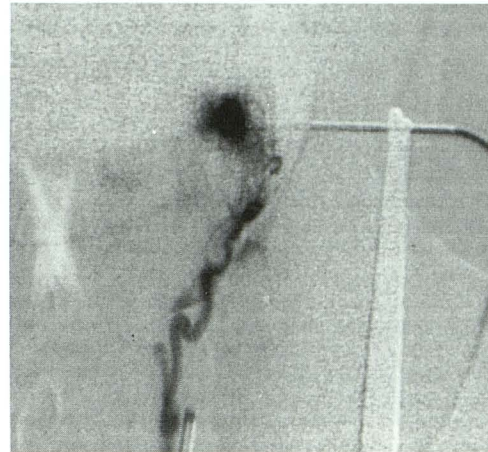


Fig 1. Angiographic findings during intratumoral injection of contrast material. Anteroposterior view, direct puncture of a left glomus tumor, shows local tumor parenchymography followed by local venous drainage, without extravasation.

zation agent must be injected slowly to avoid tumor effraction and to occupy progressively the entire tumor capillary bed. If the needle became obstructed, it was removed with a rotating movement to detach it. Another needle was inserted, and further injections were performed until the entire tumor blood supply was eliminated, which was accomplished with 10 to 30 mL of the mixture, depending on the total size of the lesion.

Intraarterial angiography must be performed during embolization to evaluate the results of treatment. A CT scan is performed after treatment to assess the distribution of the embolization agent precisely (Figs 2 and 3).

Surgery

All tumors were operated on 24 to 48 hours after embolization, except the metastases and one glomus tumor. All of the operated tumors were submitted to histologic examination.

Results

Angiographic Results

Total tumor devascularization was obtained in 14 cases, and devascularization greater than 90% of the initial tumor volume was obtained in 3 cases.

Part of the tumor venous drainage also can be embolized in the course of direct tumor injections, and certain arterial feeders can be embolized in a retrograde fashion, especially during the last injections; this occurred in eight cases (Fig 3).

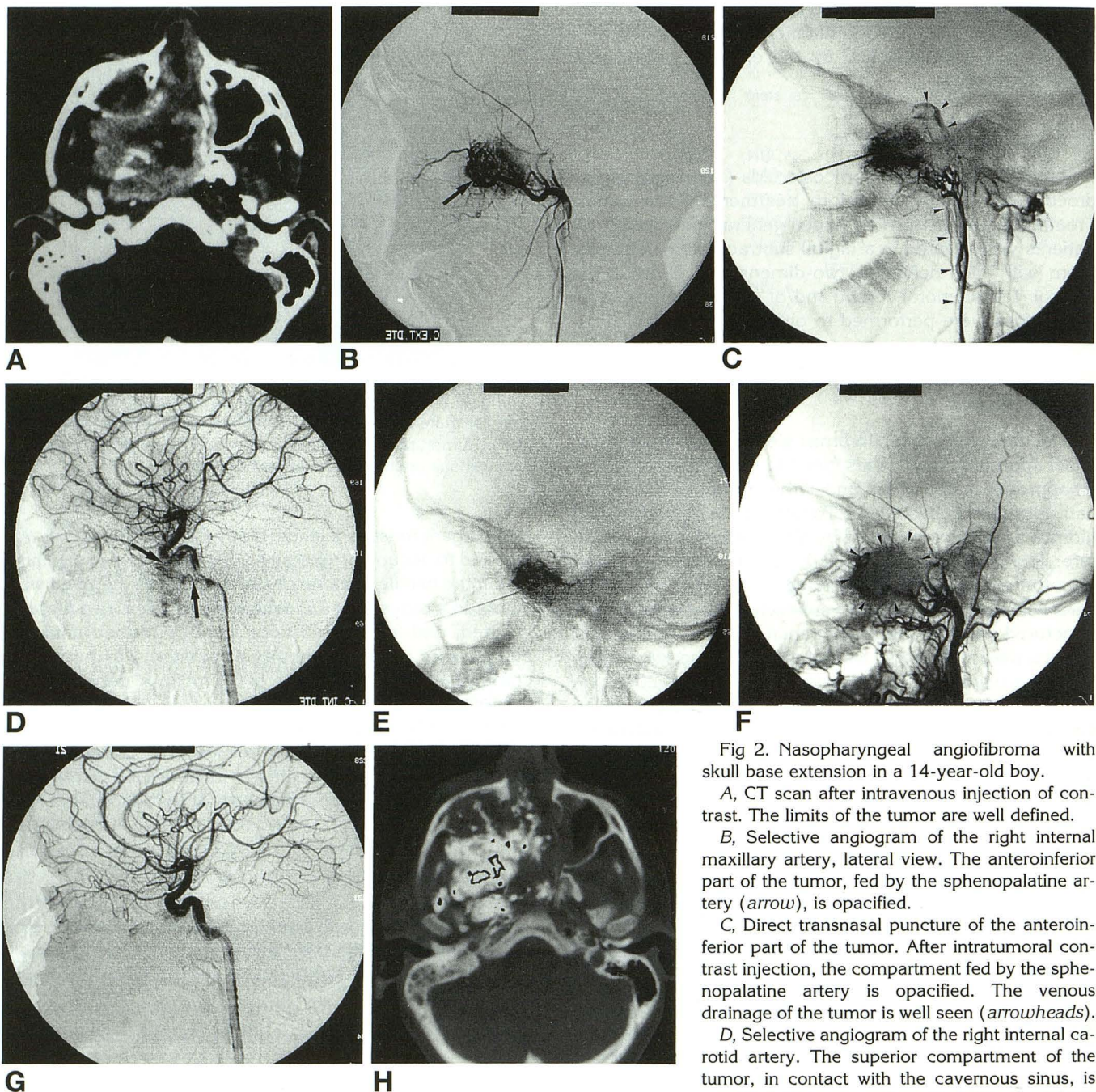


Fig 2. Nasopharyngeal angiofibroma with skull base extension in a 14-year-old boy.

A, CT scan after intravenous injection of contrast. The limits of the tumor are well defined.

B, Selective angiogram of the right internal maxillary artery, lateral view. The anteroinferior part of the tumor, fed by the sphenopalatine artery (arrow), is opacified.

C, Direct transnasal puncture of the anteroinferior part of the tumor. After intratumoral contrast injection, the compartment fed by the sphenopalatine artery is opacified. The venous drainage of the tumor is well seen (arrowheads).

D, Selective angiogram of the right internal carotid artery. The superior compartment of the tumor, in contact with the cavernous sinus, is opacified. This compartment is fed by the infero-

lateral trunk and the mandibular artery (arrows).

E, Transnasal puncture and contrast media injection of the internal carotid artery territory. Early injection.

F, Postembolization angiogram of the external carotid artery. The NBCA cast is well seen (arrowheads).

G, Postembolization angiogram of the internal carotid artery. The tumor devascularization is satisfactory in the territory of the internal carotid artery.

H, Postembolization CT scan. The intratumoral distribution of the NBCA-lipiodol-tungsten mixture is well seen.

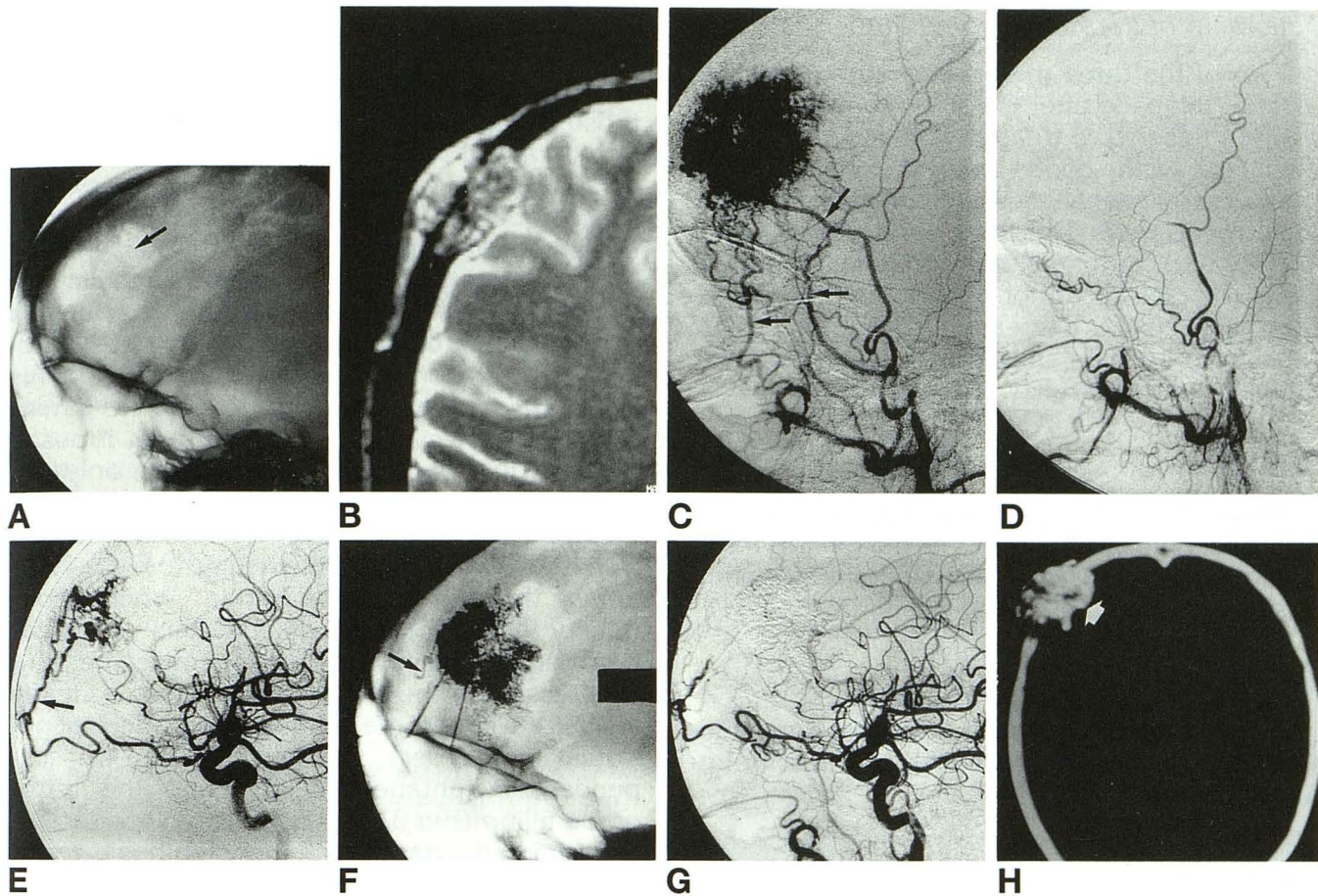


Fig 3. Forty-three-year-old woman. Pulsating palpable tumor of the calvarium.

A, The plain x-ray film of the skull shows frontal osteolysis (arrow).

B, Magnetic resonance examination: extradural tumor with local mass effect and subcutaneous extension through the bone lysis.

C, External carotid angiogram: hypervascular tumor fed by the middle meningeal artery, the superficial temporal artery, and anterior deep temporal artery (arrows).

D, External carotid angiogram after superselective embolization of all afferent pedicles. The tumor seems to be well devascularized.

E, Internal carotid artery angiogram: important tumor remnant, fed by a meningeal branch of the ophthalmic artery (arrow). A direct puncture of the tumor, followed by an embolization procedure, was performed.

F, Postembolization x-ray film. The tumor NBCA mixture cast is well seen. Retrograde embolization of the meningeal branch of the ophthalmic artery is also seen (arrow).

G, Postembolization angiogram of the common carotid artery: total devascularization of the tumor.

H, Postembolization CT scan: intratumoral NBCA cast (arrow).

Surgical Results

All of the tumors operated on were totally resected. None of the patients required blood transfusion. The limits of the tumors were easily identified by the black staining caused by tungsten, which facilitated complete excision.

A good plane of cleavage was obtained in every case because of the tumor retraction induced by devascularization. In the case of the nasopharyngeal angiofibromas, the tumor was cut with scissors and was even excised whole in six cases. In the last five operations, the surgical

fields were reduced while maintaining good control of the tumor margins.

Histology

The various surgical specimens submitted to histologic examination confirmed the nature of the various tumors operated on and showed that almost all of the tumor capillary beds were occupied by embolization agent mixed with tungsten powder. Areas of necrosis within the tumors were also identified.

Follow-up of the Nonoperated Tumors

Two of the three metastases embolized with alcohol relapsed after 6 and 8 months, respectively. These were treated with second alcohol injections with good tumoral remission, although the patients eventually died without any local recurrence. The third case of metastasis was treated 3 months ago and is still in remission. The glomus tumor not operated on embolized with NBCA decreased in size by 80% in relation to its initial volume and remains stable after 8 months of follow-up.

Side Effects

Postembolization pain was the only side effect observed in the cases of nasopharyngeal fibroma. This pain was relieved by minor analgesics and corticosteroids.

Complications

One patient with a glomus jugular tumor developed Horner syndrome lasting 1 month before full recovery.

Discussion

Preoperative embolization of hypervascular tumors is a very useful technique, because it reduces the tumor blood supply and decreases intraoperative bleeding (6, 14, 15). Until now, this embolization, performed via a conventional intravascular approach, was the only method of ensuring effective preoperative devascularization. However, these devascularizations are rarely complete, because embolization of the various arterial pedicles does not always eliminate the tumor capillary bed. This is not important when all of the pedicles supplying the tumor are embolized, but when only some of the pedicles are treated, the tumor blood supply can be restored via the untreated pedicles. This problem is particularly serious when nonembolized pedicles supply zones of the tumor that are more difficult to treat surgically (cavernous sinus, left temporal fossa, and cerebral cortex). Certain tumors such as nasopharyngeal fibromas have lower risk of recurrence when the tumors are excised as single pieces (en bloc resection), but this is very difficult to perform when devascularization is not complete. Using our direct tumor puncture embolization technique, total tumor devascularization is easier to

achieve, and the parts of the tumor supplied by branches of the internal carotid or vertebral artery can be devascularized just as easily as those parts vascularized by branches of the external carotid artery (Figs 2 and 3).

Early in our experience, we used this technique to devascularize only tumors with difficult or dangerous intravascular access, but in view of the hemodynamic and surgical results obtained, we believe that the indications for this technique can be extended to tumors easily accessible to conventional embolization. This technique is easy to perform and carries a minimal risk. However, good-quality and, if possible, 2-D fluoroscopy is required. The only potential risk is reflux of NBCA into the internal carotid or vertebral artery via feeders derived from these arteries and filled in retrograde fashion at the end of embolization. When good-quality fluoroscopy is available, this complication can be easily avoided, because the slow progression of the embolization agent is clearly visualized. When the embolization agent penetrates into feeders, the injection can be suspended, instantaneously stopping the retrograde filling (Fig 3).

Staining the tumor with tungsten has the major advantage for the surgeon of easily distinguishing between healthy tissues and the tumor. Since we have used this technique, no residual tumor has been detected on postoperative magnetic resonance or CT, and for the moment, no recurrences have been observed with a mean follow-up of 12 months. In view of the efficacy of devascularization and the effect obtained on metastases and a nonoperated glomus tumor, this technique possibly could be considered sole treatment for certain inoperable tumors or for the treatment of very elderly or debilitated patients.

The injection of embolization material into a tumor in a conscious patient is extremely painful, which we believe is a response to tumor ischemia. Therefore, we perform this procedure under general anesthesia. Horner syndrome occurred in the case of a very large glomus tumor probably involving the cervical sympathetic nervous system, which accounts for the immediate deficit and its regression 1 month later when the initial volume of the tumor was reduced.

No increased mass effect was observed after embolization with NBCA, but alcohol injection can induce an increase in volume during the

first 24 hours because of edema around the lesion, probably of vasogenic origin. This suggests that NBCA injection possibly could be performed by intracranial stereotactic techniques for inoperable tumors or tumors inaccessible to surgery.

In conclusion, we believe that this technique, used in combination with surgery, is relatively simple, inexpensive, and accessible to most interventional neuroradiology teams. Its efficacy simplifies the surgical procedure and consequently facilitates complete tumor excision while decreasing the surgical risk and the risk of recurrence.

This embolization technique would seem to be effective as a palliative treatment or as the sole treatment for certain tumors, but a longer follow-up is necessary to confirm its long-term efficacy.

References

1. Djindjian R, Merland JJ. *Superselective Arteriography of the External Carotid Artery*. Berlin: Springer-Verlag, 1978
2. Moret J, Roulleau J, Poncet E, Vignaud J. Intérêt de l'artériographie thérapeutique dans le traitement des glomus tympano-jugulaires. *Ann Otolaryngol* 1977;94:491-498
3. Lasjaunias P. Nasopharyngeal angiofibromas: hazards of embolization. *Radiology* 1980;136:119-123
4. Berenstein A, Kricheff I. Microembolization techniques of vascular occlusion: radiologic, pathologic, and clinical correlation. *AJNR Am J Neuroradiol* 1981;2:261-267
5. Valavanis A. Preoperative embolization of the head and neck: indications, patients, selection, goals, and precautions. *AJNR Am J Neuroradiol* 1986;7:943-952
6. Halbach V, Hieshima G, Higashida T, David C. Endovascular therapy of head and neck tumors. In: Vinuela F, et al, eds. *Interventional Neuroradiology: Endovascular Therapy of the Central Nervous System*. New York: Raven Press, 1992:17-28
7. Davis KR, Debrun GM. Embolization of juvenile nasopharyngeal angiofibromas. *Semin Intervent Radiol* 1987;4:309-320
8. Davis KR. Embolization of epistaxis and juvenile nasopharyngeal angiofibromas. *AJNR Am J Neuroradiol* 1986;5:953-962
9. Roberson GH, Price AC, Davis JM, Gulati A. Therapeutic embolization of juvenile angiofibroma. *AJNR Am J Neuroradiol* 1979;133:657-663
10. Lasjaunias P, Berenstein A. In: *Surgical Neuroangiography: Endovascular Treatment of Craniofacial Lesions*. New York: Springer-Verlag 1987:101-126
11. Casasco A, Mani J, Alachkar F, Notari F, Theron J. L'oedème pérítumoral dans les méningiomes intracrâniens: corrélation angiographique et tomodesitométrie. *Neurochirurgie* 1986;32:296-303
12. Riche MC, Hadjean E, Tricot JF, Merland JJ. Le risque de la ligature de la carotide externe dans le traitement des angiodysplasies cervico-faciales. *Ann Otolaryngol Chir Cervicofac* 198;97:3-13
13. Deramond H, Debuische C, Pruvo JP. La vertébroplastie feuillets de radiologie. 1990;30:262-268
14. Garcia Cervigon E, Rufenacht D, Thurel C, Reizine D, Tran Ba Huy P, Merland JJ. Pre-operative embolization of nasopharyngeal angiofibromas: report of 58 cases. *Neuroradiology* 1988;30:556-560
15. Riche MC, Cophignon J, Thurel C, et al. Embolization of the cavernous and petrous segments of the internal carotid artery in severe basilar skull and petrous bone lesions. *J Neuroradiol* 1981;8:301-315