

Are your **MRI contrast agents** cost-effective?

Learn more about generic **Gadolinium-Based Contrast Agents**.



FRESENIUS
KABI

caring for life

AJNR

Normal values of cerebrovascular reserve capacity after stimulation with acetazolamide measured by xenon 133 single-photon emission CT.

G Leinsinger, A Piegras, K Einhüpl, P Schmiedek and C M Kirsch

This information is current as of April 19, 2024.

AJNR Am J Neuroradiol 1994, 15 (7) 1327-1332
<http://www.ajnr.org/content/15/7/1327>

Normal Values of Cerebrovascular Reserve Capacity after Stimulation with Acetazolamide Measured by Xenon133 Single-Photon Emission CT

Gerda Leinsinger, Axel Piepgras, Karl Einhüpl, Peter Schmiedek, and Carl Martin Kirsch

PURPOSE: To determine whether a standardized stimulation challenge with acetazolamide will be helpful for assessing the vasodilatory capacity in patients with obstructive cerebrovascular disease. **METHODS:** To establish normative data of the cerebrovascular reserve capacity, a group of 41 control patients was investigated. The regional cerebral blood flow was measured quantitatively before and after stimulation with acetazolamide using the xenon 133 inhalation method and dynamic single-photon emission CT. **RESULTS:** A significant increase of regional cerebral blood flow was found after administration of 1 g of acetazolamide. By doubling the dose no significant further increase was measured. We found no correlation of either baseline or stimulated flow values with age. However, a linear dependence between the stimulated flow values and their respective baseline values was observed. **CONCLUSION:** The standardized challenge with acetazolamide seems to be a reliable method to determine cerebrovascular reserve capacity quantitatively.

Index terms: Cerebral blood flow; Brain, effects of drugs on; Brain, radionuclide studies; Single-photon emission computed tomography (SPECT); Xenon

AJNR Am J Neuroradiol 15:1327-1332, Aug 1994

The increasing effect of acetazolamide (Diamox) on cerebral blood flow was reported in 1959 by Posner and Plum (1). Their findings have been reproduced with various techniques for the measurement of cerebral blood flow. The exact underlying mechanism is still unclear; the most favored theory is one of an increase of partial pressure of carbon dioxide within the brain tissue through carbonic anhydrase inhibition followed by a decrease of cerebral extracellular fluid pH that acts as a strong vasodilator (2, 3). Acetazolamide-activated regional cerebral blood flow measurements are used to study a variety of disorders (4, 5). A standardized combination of regional cerebral blood flow measurements and acetazolamide was reported

by Vorstrup et al (6) to assess the vasodilatory capacity of the arterial collaterals distal to a carotid artery occlusion. This test was based on a comparison of regional cerebral blood flow at rest and after stimulation with acetazolamide and allows assessment of the cerebrovascular reserve capacity. This parameter is particularly useful in determining the hemodynamic effect of obstructive cerebrovascular disease before revascularizing procedures.

For a meaningful interpretation of the results obtained with the acetazolamide test and to improve its diagnostic accuracy, sufficient normative data are needed. Reports on the use of the acetazolamide test in control subjects have been conducted in rather small populations (7-10). In this study we give a summary of our experience with a large group of control subjects.

Patients and Methods

Forty-one patients participated in this study. There were 33 men and 8 women, mean age 45 ± 13 years (range, 19 to 77 years). Cerebrovascular disease was excluded by history and neurologic examination, including

Received March 9, 1993; accepted pending revision May 28; revision received October 26.

From the Departments of Nuclear Medicine (G.L., C.M.K.), Neurosurgery (A.P., P.S.), and Neurology (K.E.), University of Munich.

Address reprint requests to Dr Gerda Leinsinger, Institut für Radiologische Diagnostik, Klinikum Innenstadt, Pettenkoferstrasse 8, 80336 Munich, Germany.

AJNR 15:1327-1332, Aug 1994 0195-6108/94/1507-1327

© American Society of Neuroradiology

Regional cerebral blood flow (mL/100 g per minute) before and after intravenous injection of 1 g of acetazolamide in 41 healthy control subjects

Region	Before Injection		After Injection		Increase	
	Mean \pm SD	Range	Mean \pm SD	Range	Mean \pm SD	Range
Anterior cerebral artery	57 \pm 10	40-78	68 \pm 9	49-92	12 \pm 5	1-24
Right middle cerebral artery	64 \pm 11	45-87	81 \pm 10	62-103	17 \pm 11	9-29
Left middle cerebral artery	66 \pm 11	46-90	82 \pm 9	60-101	16 \pm 6	4-29
Posterior cerebral artery	63 \pm 10	43-89	81 \pm 9	59-101	19 \pm 6	5-31

extracranial ultrasonographic examination. Further exclusion criteria were a history of diabetes mellitus, arterial hypertension, or ischemic heart disease. There were 23 smokers, and 3 participants had quit smoking more than 2 years before.

For measurement of regional cerebral blood flow the xenon 133 inhalation technique and dynamic single-photon emission computed tomography (Tomomatic 64, Medimatic, Copenhagen, Denmark) was used. This method has been described in detail previously (11, 12). Quantitative data on flow values (milliliters per 100 g per minute) were obtained from three transaxial sections, each 2 cm in thickness, which corresponded to planes 2, 6, and 10 cm above the canthomeatal line. Standardized regions of interest were used for evaluation as proposed by Rootwelt et al (13) representing the perfusion territories of the anterior cerebral, middle cerebral, and posterior cerebral arteries. This study is focused on the middle cerebral artery territory because of clinical relevance. For the determination of the mean flow values of the middle cerebral artery territory, the second section was evaluated.

According to the study protocol, regional cerebral blood flow was measured under resting conditions. Thirty minutes later 1 g of acetazolamide was given intravenously. This resulted in a dosage of greater than 10 mg/kg body weight with a mean of 13.4 ± 2.1 mg/kg. The regional

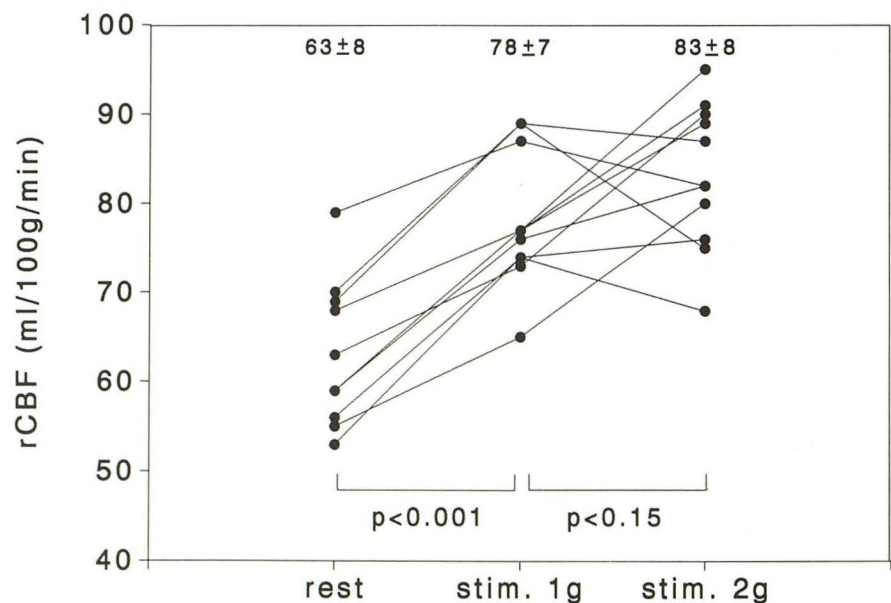
cerebral blood flow measurement was repeated 15 minutes after the administration of the drug representing the approximate time of maximal response of regional cerebral blood flow (14). At the end of each regional cerebral blood flow study, arterial blood gases were sampled, and hematocrit and blood pressure were measured. Flow values were not corrected for individual partial pressure of carbon dioxide values. No serious side effects were seen that could be attributed to the drug. Transient headache which did not require any treatment was experienced by some participants. Some also noted an altered sense of taste or reversible perioral numbness.

Statistical evaluation of the mean flow values before and after acetazolamide was performed using the paired *t* test. Significant changes were assumed for $P < .05$.

Results

In all cases a significant increase of regional cerebral blood flow ($P < .001$) was noted after administration of 1 g of acetazolamide. The mean flow values of the respective cerebral arteries as represented in section 2 of the study are shown in the Table. There were no significant differences between the right and left hemi-

Fig 1. Dose response of regional cerebral blood flow (rCBF) in the middle cerebral artery territory after 1 and 2 g of acetazolamide in 11 control subjects.



sphere. Mean blood pressure was unchanged after the administration of acetazolamide. The mean value of the arterial partial pressure of carbon dioxide was 36.2 ± 2.8 mm Hg before and 35.9 ± 3.1 mm Hg after acetazolamide. The mean hematocrit value was $42 \pm 5\%$ before and did not change after 1 g of acetazolamide.

For further evaluation of the dose response of acetazolamide on regional cerebral blood flow, 11 subjects underwent an additional study 24 hours after administration of 2 g of acetazolamide. A comparison of the flow increase within the middle cerebral artery territory is shown in Figure 1. After administration of 1 g of acetazolamide, a significant increase was found in all subjects ($P < .001$). By doubling the dose of acetazolamide, further changes in regional cerebral blood flow were not significant ($P < .15$).

To study possible age dependence of the acetazolamide response on regional cerebral blood flow, the flow increase within the middle cerebral artery territory after 1 g of the drug was investigated with regard to the individual age of the subjects (Fig 2). Flow values were found not to correlate with age either for the baseline study ($r = -.1$) or after stimulation with acetazolamide ($r = -.1$).

In addition, stimulated flow values were compared with their respective baseline values (Fig 3). A linear dependence was found; it can be expressed in the following equation:

$$r\text{CBF}_{\text{stim}} = 0.75r\text{CBF}_{\text{rest}} + 32.6\text{ml}/100\text{g per min}; r = .87.$$

The 95% tolerance limits for this regression show the upper and lower limits of the stimulated flow values.

Therefore, persons with low baseline flow values reached lower values after stimulation with acetazolamide than subjects exhibiting high baseline flow values. The increase in regional cerebral blood flow, however, was more pronounced in subjects with low baseline flow values.

To allow a more sensitive evaluation of the cerebrovascular reserve capacity of patients with cerebrovascular disease this dependence of baseline and stimulated flow was further elaborated, resulting in a different graphic representation (Fig 4). Here the flow increase after acetazolamide (reserve capacity, $\text{CVRC} = r\text{CBF}_{\text{stim}} - r\text{CBF}_{\text{rest}}$) is shown with its corre-

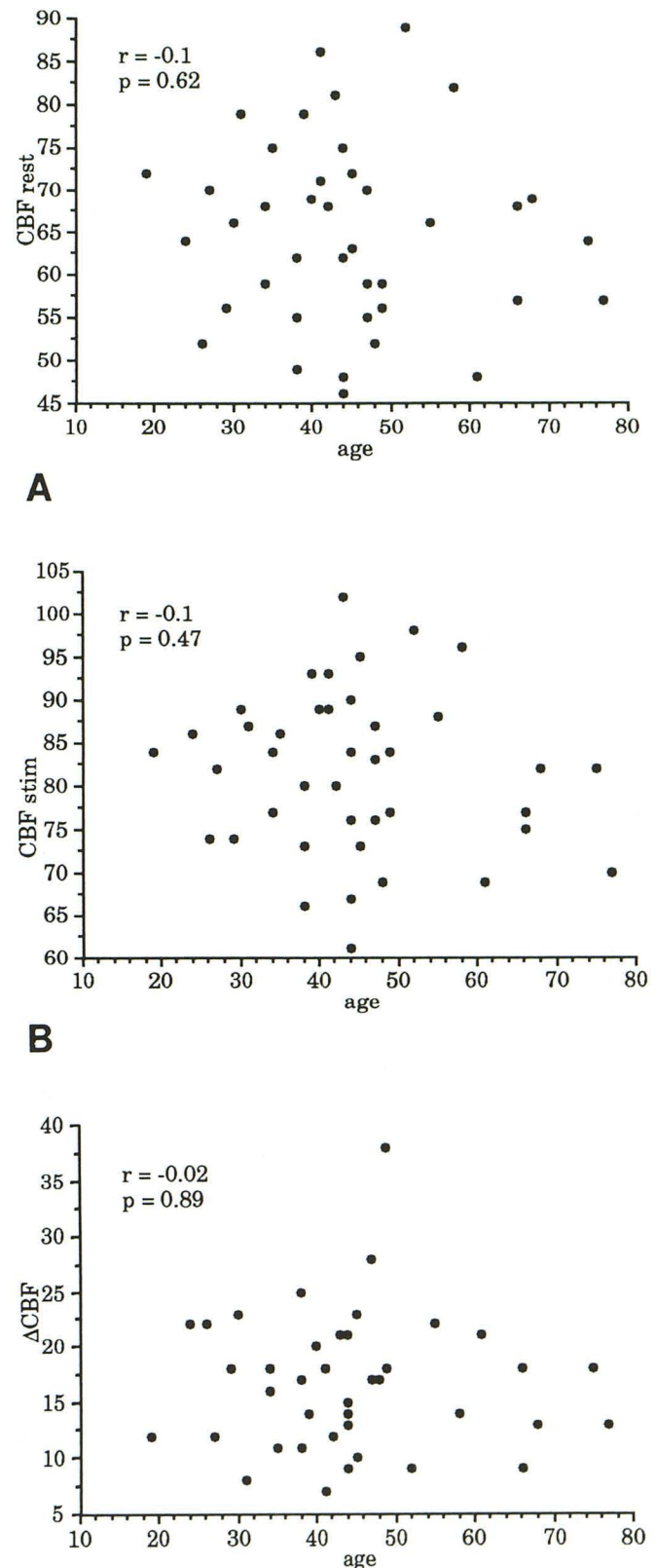
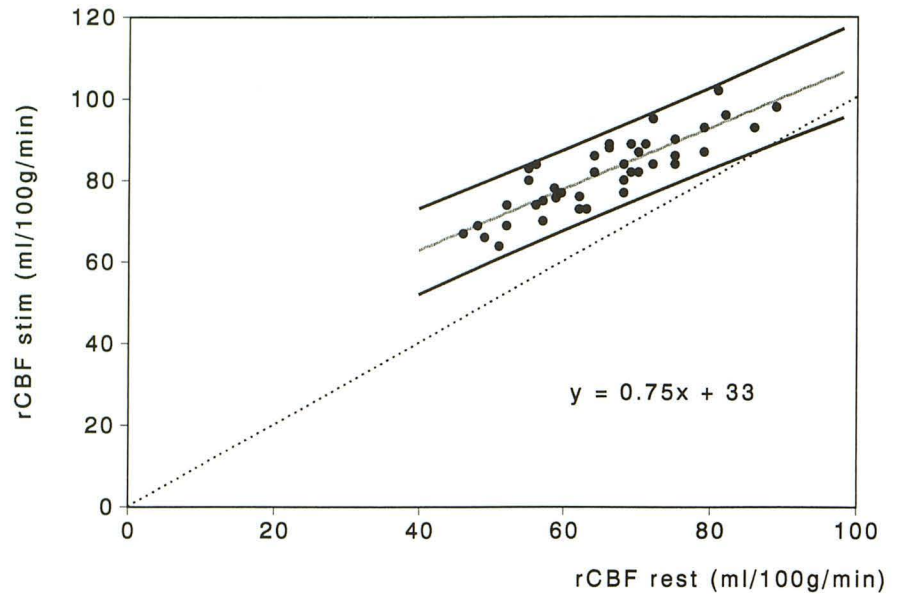


Fig 2. Age dependence of the baseline flow (A), stimulated flow (B), and cerebral blood flow (CBF) (C) values in the middle cerebral artery territory.

Fig 3. Stimulated flow values in comparison with the respective baseline values in 41 control subjects.



sponding dependence on the resting flow values. Flow values below the lower tolerance limit represent a decreased cerebrovascular reserve capacity.

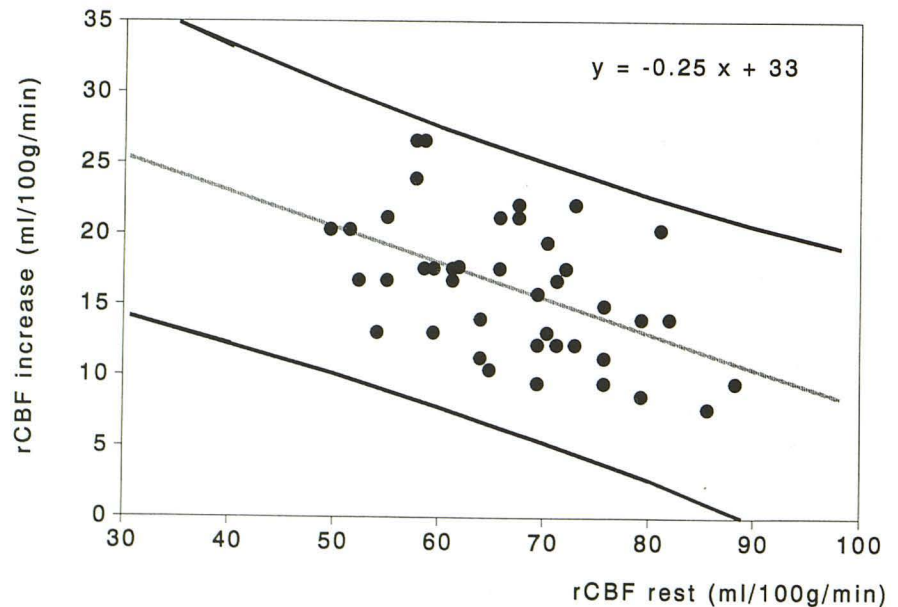
Discussion

For determination of the functional impact of obstructive cerebrovascular disease the measurement of cerebrovascular reserve capacity was shown to be a suitable parameter (3, 15, 16). The pathophysiologic basis for a decreased cerebrovascular reserve capacity is a chronic dilatation of distal resistance vessels with a di-

minished autoregulatory response to counteract hypotensive situations. By administration of acetazolamide using a dosage of more than 10 mg/kg body weight the carbonic anhydrase was blocked, resulting in an almost maximal increase of regional cerebral blood flow with regard to this mechanism. Contrary to what is reported with other stimulation tests like carbon dioxide inhalation, we observed no systemic reactions concerning blood pressure or arterial carbon dioxide tension using acetazolamide.

The xenon 133 inhalation method was used for noninvasive and quantitative determination of regional cerebral blood flow. Although this

Fig 4. Tolerance limits of cerebrovascular reserve capacity in terms of regional cerebral blood flow (rCBF).



method provides only limited spatial resolution (section thickness, 2 cm; resolution within the section, 1.7 cm full width at half-maximum), the dynamic acquisition mode allows the quantitative evaluation of absolute flow values with respect to the anterior cerebral, middle cerebral, and posterior cerebral artery territories. Unlike those methods that present only the static distribution images of a perfusion tracer such as technetium 99 m hexamethyl-propyleneamine oxime, the quantitative approach allows the determination of cerebrovascular reserve capacity in terms of mL/100 g per minute separately over each hemisphere. This is important in patients with bilateral cerebrovascular occlusive disease. Especially in the follow-up after revascularizing procedures, only the quantitative

measurements of cerebrovascular reserve capacity could reveal significant changes.

With respect to the clinical demands the mean flow values over the anterior cerebral, middle cerebral, and posterior cerebral artery territories were assessed by regions of interest (Fig 5). According to the studies of Rezai et al (17) the sizes of these regions were suitable for reliable calculation of flow values up to a maximum of 100 mL/100 g per minute. Higher flow values would be underestimated. In our study the flow values of the middle cerebral artery territory ranged after stimulation from 60 to 103 mL/100 g per minute.

Previous studies documented only a slight decrease of regional cerebral blood flow at rest and a decrease with age after stimulation (10,

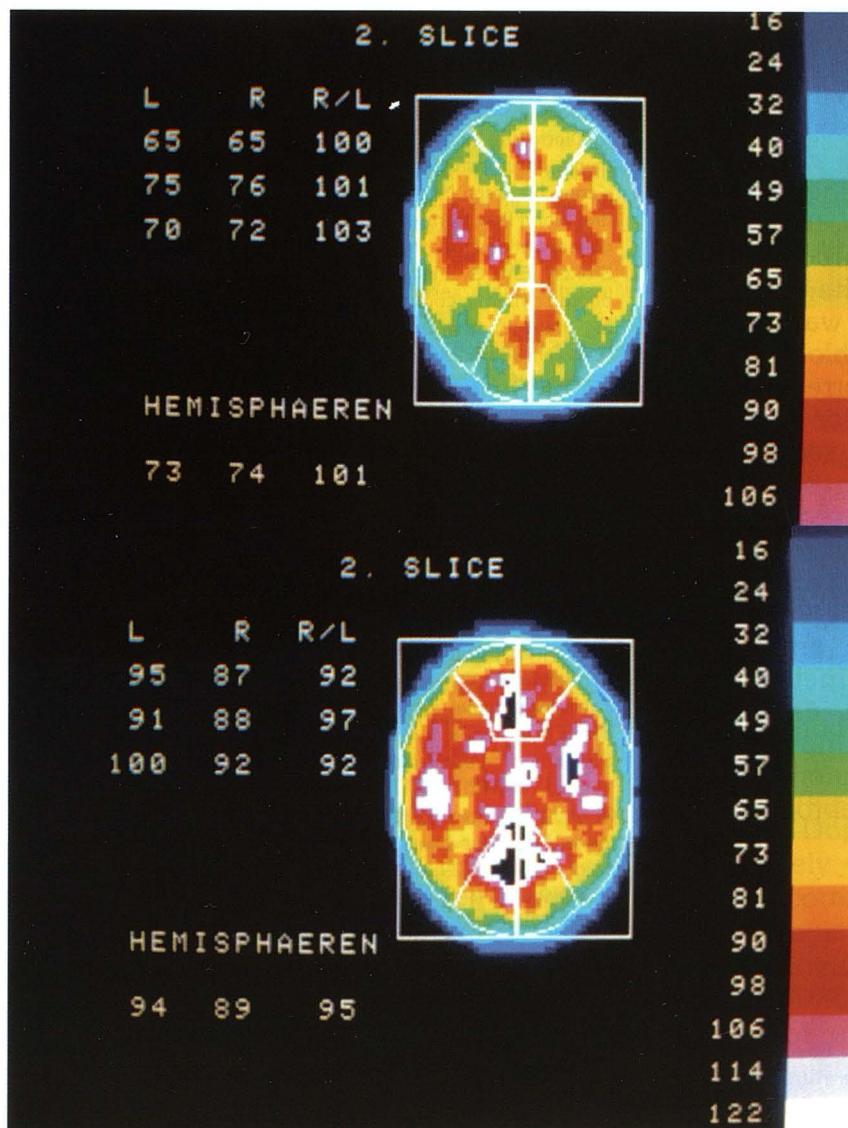


Fig 5. Color-coded flow maps of a control subject before (*top*) and after (*bottom*) stimulation with 1 g of acetazolamide. The sections were subdivided by standardized regions of interest into territories representing the perfusion areas of the anterior cerebral, middle cerebral, and posterior cerebral artery. The mean flow values over these regions of interest were assessed in terms of milliliters per 100 g per minute and are presented to the *left* of each image. *Hemisphaeren* refers to values for an entire hemisphere.

18). From our data, no significant age dependence of baseline or stimulated flow values could be demonstrated. Furthermore, our data suggested individual differences of cerebral perfusion capacities, showing that subjects with low baseline flow values reach lower flow values after stimulation than subjects presenting high baseline values.

The increase of regional cerebral blood flow, however, was more pronounced in persons with low baseline flow values. In some cases extremely high stimulated flow values might have been underestimated by the xenon 133 inhalation method. A further explanation could be the effect of different dilatation of cerebral arterioles before stimulation. Bogsrud et al (9) could not observe this tendency in a group of 12 healthy volunteers. Using comparable methods, the baseline flow values of the middle cerebral artery territory in his group ranged from 46 to 71 mL/100 g per minute (mean increase, 15.4 ± 5 mL/100 g per minute), representing a smaller range of flow values than were seen in the present study. Concerning the wide range of individual baseline and stimulated regional cerebral blood flow values in our series, the influence of arterial partial pressure of carbon dioxide may be related. Therefore, the arterial partial pressure of carbon dioxide was measured with each regional cerebral blood flow study. However in our series, the correction of regional cerebral blood flow values for individual partial pressure of carbon dioxide values did not decrease the standard deviation of mean flow values. Therefore, no further correction for individual partial pressure of carbon dioxide values was performed.

In conclusion, the acetazolamide test using xenon 133 dynamic single-photon emission computed tomography is a reliable method to determine cerebrovascular reserve capacity quantitatively. These normative data may serve as a basis for a meaningful interpretation of the results obtained in patients with cerebrovascular disease.

References

1. Posner JB, Plum F. The toxic effects of carbon dioxide and acetazolamide in hepatic encephalopathy. *J Clin Invest* 1960;39:1246-1258
2. Bickler PE, Litt L, Banville DL, Severinghaus JW. Effects of acetazolamide on cerebral acid-base balance. *J Appl Physiol* 1988; 422-427
3. Vorstrup S, Jensen KE, Thomsen C, Henriksen O, Lassen NA, Paulson OB. Neuronal pH regulation: constant normal intracellular pH is maintained in brain during low extracellular pH induced by acetazolamide— ^{31}P NMR study. *J Cereb Blood Flow Metab* 1989; 9:417-421
4. Batjer HH, Devous MD, Meyer YJ, Purdy PD, Samson DS. Cerebrovascular hemodynamics in arteriovenous malformation complicated by normal perfusion pressure breakthrough. *Neurosurgery* 1988;22:503-509
5. Shinoda J, Kimura T, Funakoshi T, Araki Y, Imao Y. Acetazolamide reactivity on cerebral blood flow in patients with subarachnoid haemorrhage. *Acta Neurochir (Wien)* 1991;109:102-108
6. Vorstrup S, Boysen G, Brun B, Engell HC. Evaluation of the regional cerebral vasodilatory capacity before carotid endarterectomy by the acetazolamide test. *Neurol Res* 1987;9:10-18
7. Bonte FJ, Devous MD, Reisch JS. The effect of acetazolamide on regional cerebral blood flow in human subjects as measured by single-photon emission computed tomography. *Invest Radiol* 1988;23:564-568
8. Sorteberg W, Lindegaard K-F, Rootwelt K, et al. Effect of acetazolamide on cerebral artery blood velocity and regional cerebral blood flow in normal subjects. *Acta Neurochir (Wien)* 1989;97: 139-145
9. Bogsrud TV, Rootwelt K, Russel D, Nyberg-Hansen R. Acetazolamide effect on cerebellar blood flow in crossed cerebral-cerebellar diaschisis. *Stroke* 1990;21:52-55
10. Sullivan HG, Kingsbury TB, Morgan ME, et al. The rCBF response to Diamox in normal subjects and cerebrovascular disease patients. *J Neurosurg* 1987;67:525-534
11. Kanno I, Lassen NA. Two methods for calculating regional cerebral blood flow from emission computed tomography of inert gas concentrations. *J Comput Assist Tomogr* 1979;3:71-76
12. Stokely EM, Sveinsdottir E, Lassen NA, Rommer P. A single photon dynamic computer assisted tomograph (DCAT) for imaging brain function in multiple cross sections. *J Comput Assist Tomogr* 1980;4:230-240
13. Rootwelt K, Dybevoild S, Nyberg-Hansen R, Russel D. Measurement of cerebral blood flow with ^{133}Xe inhalation and dynamic single photon emission computer tomography. Normal values. *Scand J Clin Lab Invest* 1986;46:97-105
14. Hauge A, Nicolaysen G, Thorensen M. Acute effects of acetazolamide on cerebral blood flow in man. *Acta Physiol Scand* 1983; 117:233-239
15. Leinsinger G, Schmiedek P, Kreisig T, Einhäupl K, Bauer W, Moser E. ^{133}Xe -DSPECT. Bedeutung der zerebrovaskulären Reservekapazität für Diagnostik und Therapie der chronischen zerebralen Ischämie. *Nucl Med* 1988;27:127-134
16. Schmiedek P, Piepgras A, Leinsinger G, Einhäupl K, Kirsch CM. Extra-intracranial bypass surgery in patients with hemodynamic cerebral ischemia. In: Schmiedek P, Einhäupl K, Kirsch CM, eds. *Stimulated cerebral blood flow*. Berlin and New York: Springer Verlag, 1992;257-262
17. Rezaei K, Kirchner PT, Armstrong C, Ehrhardt JC. Validation studies for brain blood flow assessment by radioxenon tomography. *J Nucl Med* 1988;29:348-355
18. Shirahata N, Henriksen L, Vorstrup S, et al. Regional cerebral blood flow assessed by ^{133}Xe inhalation tomography: normal values. *J Comput Assist Tomogr* 1985;9:861-866