

Are your **MRI contrast agents** cost-effective?

Learn more about generic **Gadolinium-Based Contrast Agents**.



FRESENIUS
KABI

caring for life

AJNR

**CT and MR of
3-hydroxy-3-methylglutaryl-coenzyme A lyase
deficiency.**

K Gordon, M Riding, P Camfield, H Bawden, M Ludman and P Bagnell

This information is current as
of April 23, 2024.

AJNR Am J Neuroradiol 1994, 15 (8) 1474-1476
<http://www.ajnr.org/content/15/8/1474>

CT and MR of 3-Hydroxy-3-Methylglutaryl-Coenzyme A Lyase Deficiency

Kevin Gordon, Michael Riding, Peter Camfield, Harry Bawden, Mark Ludman, and Philip Bagnell

Summary: Siblings with 3-hydroxy-3-methylglutaryl-coenzyme A lyase deficiency were evaluated with CT and MR. Both imaging studies demonstrated a leukodystrophy with preferential involvement of the deeper arcuate fibers.

Index terms: Brain, computed tomography; Brain, magnetic resonance; Brain, metabolism; Degenerative brain disease; Pediatric neuroradiology

3-Hydroxy-3-methylglutaryl-coenzyme A lyase deficiency (HMG-CoA lyase, EC 4.1.3.4, McKusick 24645[1]) is an inborn error of leucine catabolism. The clinical and biochemical features of this enzyme deficiency recently have been reviewed (2). Our two patients, previously reported by Gibson et al, (3), were evaluated by magnetic resonance (MR) and computed tomography (CT). We demonstrate both CT and MR findings of a leukodystrophy with preferential involvement of the arcuate fibers. These findings may be unique for this metabolic disease.

Case Reports

Case 1

A 16-year-old boy experienced repeated episodes of metabolic acidosis, hypoglycemia, lethargy, respiratory distress, vomiting, and coma since age 5 months. The frequency of these metabolic crises has declined with increasing age. Hepatomegaly was absent. Hepatic enzymes were normal, and ketonuria was absent. Urinary organic acids that were elevated included 3-hydroxyisovaleric acid, 3-methylglutaconic acid, and 3-methylglutaric acid. A diagnosis of HMG-CoA lyase deficiency was confirmed in lymphocyte and cultured fibroblast enzymatic assays.

During investigation for a potential seizure disorder, a CT scan was obtained, followed up with MR imaging. Two

electroencephalograms were normal. Neuropsychological testing (Wechsler Intelligence Scale for Children, Revised) demonstrated a full-scale IQ of 89 but also suggested deficits consistent with an intercortical processing defect.

The CT scan (Fig 1A) demonstrated patchy areas of reduction in white matter density without atrophy. These changes preferentially involved the deeper arcuate fibers, and therefore the delineation between gray matter and white matter was accentuated especially in the frontal and occipital areas.

The MR study (1.5 T) (Fig 1B) revealed multiple areas of increased signal intensity on T2-weighted images in the white matter bilaterally. The areas of increased signal intensity were widely distributed and multifocal but were more coalescent and more prevalent within the deep arcuate fibers. Periventricular white matter was relatively spared as was the brain stem and cerebellum.

Case 2

A 9½-year-old girl, sister of the boy in case 1, presented with a similar history but with onset at 4 months and with metabolic crises less frequent. Hepatomegaly was present. Hepatic enzymes were normal, and ketonuria was rare. Urinary and serum organic acids were elevated in a pattern similar to that of her brother. A diagnosis of HMG-CoA lyase was confirmed.

She had a similar series of investigations, which included CT and MR. Electroencephalograms demonstrated rhythmical delta over posterior head regions consistent with white matter disease. Neuropsychological testing (Wechsler Intelligence Scale for Children, Revised) demonstrated a full-scale IQ of 91 but without any clear difficulties in intercortical processing.

Her CT and MR scans (Figs 2A and 2B) demonstrated similar findings to those of her brother but of lesser magnitude. On the T2-weighted images the areas of increased signal were multifocal within the more superficial subcortical areas of the parietal and occipital lobes.

Received March 12, 1993; accepted after revision August 9, 1993.

From the Departments of Pediatrics (K.G., P.C., M.L.) and Radiology (M.R.), Dalhousie University, Halifax, Nova Scotia; the Department of Neuropsychology (H.B.), IWK Children's Hospital, Halifax, Nova Scotia; and the Department of Pediatrics (P.B.), East Tennessee State University, Johnson City.

Address reprint requests to Kevin Gordon, MD, MS, IWK Children's Hospital, 5850 University Ave, Box 3070, Halifax, Nova Scotia, Canada, B3J 3G9.

AJNR 15:1474-1476, Sep 1994 0195-6108/94/1508-1474 © American Society of Neuroradiology

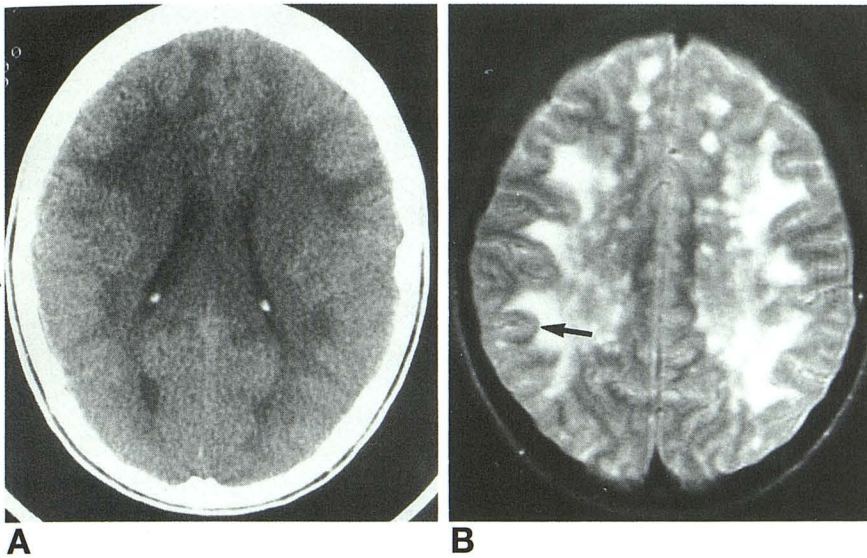


Fig 1. Case 1. A, Axial CT scan. B, Axial T2-weighted MR image (2100/80/2 [repetition time/echo time/excitations]). Preferential involvement of the deep arcuate fibers is indicated by the arrow.

Discussion

Patients with HMG-CoA lyase deficiency present in infancy with severe hypoglycemia without ketosis, metabolic acidosis, hepatomegaly, vomiting, lethargy or coma, and apnea. The presentation may be life threatening, and it often resembles that of Reye syndrome. 3-Hydroxy-3-methylglutaric, 3-methyl-glutacnic, 3-methylglutaric, and 3-hydroxyisovaleric acids, all compounds on the leucine catabolic pathway, are elevated in urine. Long-term management concentrates on avoiding hypoglycemia and long fasts. Use of a high-carbohydrate, low-protein diet has been advocated (2) with sufficient leucine to ensure appropriate growth.

The CT and MR findings we describe are remarkable because of the distribution of the lesions involving the deeper arcuate fibers. Leucodystrophies may be patchy or diffuse but tend to spare the arcuate fibers. In a review of CT and MR imaging of the brain in Canavan disease, Brismar et al (4) presented a single case in which the white matter changes were maximal in the deeper arcuate fibers with sparing of the more superficial fibers. This suggests that the radiologic differential diagnosis of a white matter disease that preferentially involves these deep cortex-cortex connections would include Canavan disease. Clinically Canavan disease, with its neurodegenerative course, macroceph-

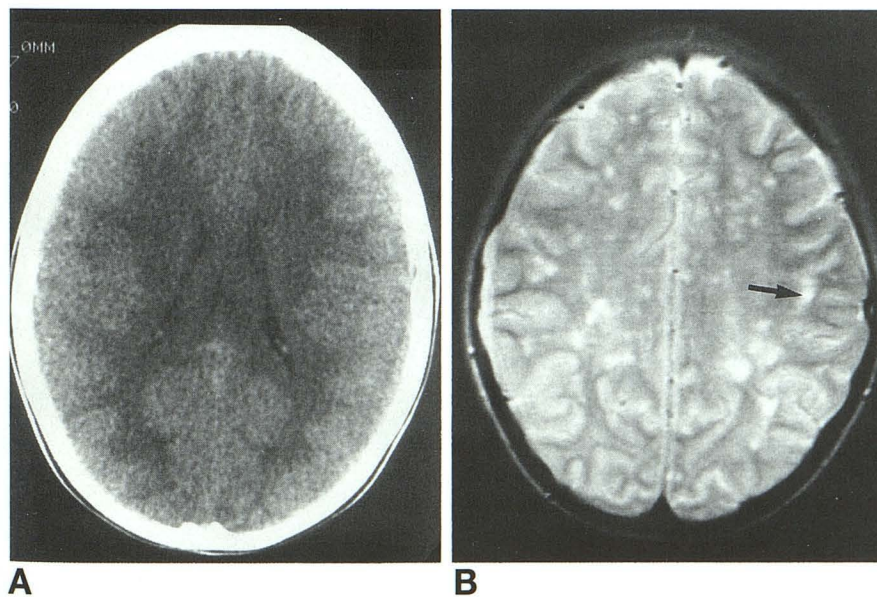


Fig 2. Case 2. A, Axial CT scan. B, Axial T2-weighted MR image (2100/80/2). Preferential involvement of the deep arcuate fibers is indicated by the arrow.

aly, and blindness, would not likely be confused with HMG-CoA lyase deficiency. These imaging findings have not been described with either hypoglycemia or acidosis, both of which may be associated with the metabolic crises of this disease.

The CT findings are different from those in previously reported cases of HMG-CoA lyase deficiency. One child has demonstrated macrocephaly, progressive dilatation of the ventricles, and widespread hypodensity of the white matter with cystic alterations (5, 6). Another child revealed asymmetry of the lateral ventricles with compression of the left ventricle (7). In a recent case series from Saudi Arabia (8), three patients underwent CT. Two patients had minor or questionable atrophy and questionable white matter findings, whereas another patient had marked atrophy but no white matter changes.

This report also included the MR appearance of HMG-CoA lyase deficiency demonstrated white matter changes in the subcortical white matter, with a tendency to involve preferentially the frontal lobes, adjacent to the frontal horns (8).

Why our patients' MR findings differ from those of Ozand et al (8) is not clear. The Saudi Arabian patients, in general, have a clinical presentation that differs from others reported with the disease. Their patients tended to have been born of consanguineous marriages and to have had early onset of symptoms (within 72 hours of life) with infrequent metabolic crises. Ozand et al proposed that their patients may have a different form of this disease than do North American patients. This genetic heterogeneity may account for differences in the imaging findings of HMG-CoA lyase deficiency, with perhaps distinct North American and Saudi Arabian (early onset) mutations.

In the above-described patient of Zoghbi et al (7), a brain biopsy showed no abnormalities in the cerebral cortex, but there was reactive gliosis, spongiosis, and increased astrocytic glycogen content of the white matter.

In our patients, both MR and CT demonstrate the same findings; however, they are more ap-

parent with MR. This suggests that MR is more sensitive for this disease.

Both our patients demonstrate clinical correlates of the MR alterations. Our first has neuropsychological findings, suggesting an alteration in intracortical processing. The second patient has persistent delta on electroencephalograms, suggesting white matter disease. Furthermore, the less prominent radiologic findings in patient 2 may be related to her youth, earlier age at diagnosis, and hence earlier dietary intervention, less frequent metabolic crises, or heterogeneity within this condition.

A recent commentary (9) has highlighted the important role of neuroimaging in the diagnosis of metabolic diseases. HMG-CoA lyase deficiency is a fascinating disease, and its propensity for involvement of the deep arcuate fibers as demonstrated by CT and MR in our patients may correlate with the unusual neuropsychological and electroencephalographic findings.

References

1. McKusick VA. *Mendelian Inheritance in Man: Catalogs of Autosomal Dominant, Autosomal Recessive, and X-linked Phenotypes*. 9th ed. Baltimore: John Hopkins University Press, 1990
2. Gibson KM, Breuer J, Nyhan WL. 3-Hydroxy-3-methylglutaryl-coenzyme A lyase deficiency: review of 18 reported patients. *Eur J Pediatr* 1988a;148:180-186
3. Gibson KM, Breuer J, Kaiser K, et al. 3-Hydroxy-3-methylglutaryl-CoA lyase deficiency: report of five new patients. *J Inher Metab Dis* 1988b;11:76-87
4. Brismar J, Brismar G, Gascon G, Ozand P. Canavan disease: CT and MR imaging of the brain. *AJNR Am J Neuroradiol* 1990;11:805-810
5. Lisson G, Leupold D, Bechinger D, Wallesch C. CT findings in a case of deficiency of 3-hydroxy-3-methylglutaryl-CoA lyase. *Neuroradiology* 1981;21:99-101
6. Leupold D, Bojasch M, Jakobs C. 3-Hydroxy-3-methylglutaryl-CoA lyase deficiency in an infant with macrocephaly and mild metabolic acidosis. *Eur J Pediatr* 1982;138:73-76
7. Zoghbi HY, Spence JE, Beaudet AL, O'Brein WE, Goodman CJ, Gibson KM. Atypical presentation and neuropathologic studies in 3-hydroxy-3-methylglutaryl-CoA lyase deficiency. *Ann Neurol* 1986;20:367-369
8. Ozand PT, Al Aqeel A, Gascon G, Brismar J, Thomas E, Gleispach H. 3-Hydroxy-3-methylglutaryl-coenzyme A (HMG-CoA) lyase deficiency in Saudi Arabia. *J Inher Metab Dis* 1991;14:174-188
9. Naidu S, Moser H. Value of neuroimaging in metabolic disease affecting the CNS. *AJNR Am J Neuroradiol* 1991;12:413-416