

Are your MRI contrast agents cost-effective?

Learn more about generic Gadolinium-Based Contrast Agents.



**FRESENIUS
KABI**

caring for life

AJNR

Prevalence of MR evidence of diffuse axonal injury in patients with mild head injury and normal head CT findings.

R L Mittl, R I Grossman, J F Hiehle, R W Hurst, D R Kauder, T A Gennarelli and G W Alburger

This information is current as
of April 9, 2024.

AJNR Am J Neuroradiol 1994, 15 (8) 1583-1589
<http://www.ajnr.org/content/15/8/1583>

Prevalence of MR Evidence of Diffuse Axonal Injury in Patients with Mild Head Injury and Normal Head CT Findings

Robert L. Mittl, Jr, Robert I. Grossman, John F. Hiehle, Jr, Robert W. Hurst, Donald R. Kauder, Thomas A. Gennarelli, and George W. Alburger

PURPOSE: To assess the prevalence of MR evidence for diffuse axonal injury at 1.5 T in patients with normal head CT findings after mild head injury. **METHODS:** Twenty consecutive patients with mild head injury (Glasgow Coma Scale, 13 to 15; no subsequent deterioration, loss of consciousness < 20 minutes) and normal head CT findings were examined with MR at 1.5 T. Pulse sequences included a conventional T2-weighted spin-echo sequence (2500–3000/30,80/1[repetition time/echo time/excitations]) and a T2*-weighted gradient-echo sequence (750/40/2, 10° flip angle). Each sequence was read independently by two blinded readers. **RESULTS:** The readers agreed that abnormalities compatible with diffuse axonal injury were present in the white matter of 6 (30%) of 20 patients (95% confidence interval, 12% to 54%). Both readers agreed that foci of high signal intensity were present on the T2-weighted spin-echo sequence in 3 (15%) of the 20 cases (95% confidence interval, 3% to 38%) and that foci of hypointensity compatible with hemorrhagic shear injury were present on the T2*-weighted sequence in 4 (20%) of the 20 patients (95% confidence interval, 6% to 44%). Both types of abnormality were noted by the readers in one patient. **CONCLUSIONS:** MR shows evidence of diffuse axonal injury in some patients with normal head CT findings after mild head injury. These lesions may represent the pathologic substrate underlying the postconcussion syndrome that occurs in many patients with moderate to severe head injury.

Index terms: Head, injuries; Brain, injuries; Brain, magnetic resonance; Nerve cells

AJNR Am J Neuroradiol 15:1583–1589, Sep 1994

Head trauma is a major public health problem in the United States. The yearly incidence of closed head injury in the United States has been estimated at 130 to 150 per 100 000 persons (1, 2). As many as 75% of head-injured patients are classified as having "mild head injury," that is, brief loss of consciousness and good neurologic status without subsequent deterioration. Mild head injury is not without morbidity, however: one third to one half of patients develop a postconcussion syndrome. This syndrome is

characterized by subjective complaints including difficulty concentrating, memory problems, headache, or disequilibrium, and is associated with deficits in information processing on neuropsychological testing (3–6).

Diffuse axonal injury, also known as white matter shearing injury, has been demonstrated neuropathologically in patients with moderate to severe head injury and is widely believed to account for the decreased consciousness and cognitive deficits that are frequent sequelae in these patients in the absence of space-occupying lesions (7–22). Previous studies of computed tomography (CT) and magnetic resonance (MR) imaging of the brain after moderate to severe head injury have commonly shown parenchymal abnormalities compatible with diffuse axonal injury, namely, small focal white matter hemorrhages on CT (23–26) and high-intensity white matter foci on long-repetition-time MR images (27–31). At 1.5 T, hypointense foci in white matter on long-repetition-time/

Received July 1, 1993; accepted after revision January 5, 1994.

Presented at the Annual Meeting of the American Society of Neuroradiology, Vancouver, May 1993.

Departments of Radiology (R.L.M., R.I.G., J.F.H., R.W.H.), Trauma (D.R.K.), and Neurosurgery (T.A.G., G.W.A), Hospital of the University of Pennsylvania, Philadelphia.

Address reprint requests to Robert I. Grossman, MD, Department of Radiology, Hospital of the University of Pennsylvania, 3400 Spruce St, Philadelphia, PA 19104.

AJNR 15:1583–1589, Sep 1994 0195-6108/94/1508–1583

© American Society of Neuroradiology

echo-time spin-echo or gradient-echo images presumably representing foci of hemorrhagic diffuse axonal injury have been reported (32, 33).

The prevalence of MR abnormalities in mildly head-injured patients is unclear from the literature. Although prior studies of MR in head trauma have included mildly head-injured patients (34–37), the frequency of MR abnormalities, if they are found at all, is difficult to determine from these nonhomogeneous groups of patients. Also, almost all prior studies of head-injured patients have been performed at low or intermediate field strength, not at 1.5 T, and did not include gradient-echo imaging. The improved sensitivity of high-field MR systems for the susceptibility effects found in acute and chronic hemorrhage over low and intermediate field systems has been well documented (38, 39). At 1.5 T the improved sensitivity of gradient-echo imaging over spin-echo imaging for susceptibility effects has also been demonstrated (33).

We prospectively evaluated patients with mild head injury and normal head CT findings to determine the frequency of abnormalities on MR at 1.5 T in these patients. Conventional spin-echo and T2*-weighted gradient-echo images were compared to determine which technique was more sensitive.

Subjects and Methods

Twenty subjects were prospectively evaluated after admission for closed head injury to the neurosurgical or trauma services at our medical center; the subjects met the following criteria for mild head injury: (a) brief loss of consciousness less than 20 minutes; (b) initial Glasgow Coma Score of 13 to 15 without subsequent deterioration (40); (c) age less than or equal to 50 years; and (d) head CT findings interpreted by a neuroradiologist as normal. The mean age of the 20 study patients was 30.6 years (range 17 to 50 years). None had a history of diabetes, hypertension, or other chronic medical problems. Ten patients were injured in motor vehicle accidents, nine by assaults, and one in a fall.

Head CT was performed using a third generation CT system. MR was performed using a 1.5 T system. The CT examinations were performed promptly after patients presented to the emergency room, usually within 4 hours of injury. The MR studies were performed within 24 hours of injury in 10 patients, within 48 hours in 3, within 72 hours in 1, and within 96 hours in 3. The other patients underwent MR imaging at 5, 6, and 25 days after injury. Pulse sequences included a short-repetition-time/echo-time

sagittal localizer (500/16/1 [repetition time/echo time/excitations]), an axial long-repetition-time/echo-time spin-echo sequence (2500–3000/30,80/1), and an axial gradient-echo acquisition (750/40/2, 10° flip angle). The gradient-echo sequence used has previously been shown to be more sensitive than spin-echo imaging in detecting hemorrhagic lesions because it is more sensitive to susceptibility effects of blood products (33).

Two blinded neuroradiologists independently evaluated the MR images and were asked to note all foci of abnormal signal intensity in the brain. Spin-echo and gradient-echo images were presented separately to each reader in random order. The readers recorded the signal intensity, size, and location (cortical, gray matter-white matter junction, deep white matter, corpus callosum, deep gray matter, brain stem, cerebellum) of each lesion identified.

Confidence intervals were calculated using the exact binomial method (41) (cases in which the readers disagreed regarding the presence or absence of abnormality were considered normal). Interobserver variation was assessed with κ , in which the degree of agreement was defined by the scale of Landis and Koch (42): less than 0, poor; 0 to 0.20, slight; 0.21 to 0.40, fair; 0.41 to 0.60, moderate; 0.61 to 0.80 substantial; and 0.81 to 1.0, almost perfect.

Results

On T2-weighted spin-echo MR images in patients with normal head CT scans after mild head injury, both readers agreed that foci of high signal intensity were present in the white matter in 3 (15%) of 20 patients (95% confidence interval, 3% to 38%). One of these cases is illustrated in Figure 1. Although high-signal-intensity foci are nonspecific, they could be foci of shear injury in these young patients. The readers also agreed that a separate 2-mm hypointense focus was present in one of these three patients, compatible with a small site of hemorrhage. One of the two readers identified a 2-mm hypointense focus in another patient. All three cases concordant for high signal intensity occurred in patients who lost consciousness after assaults. The number, size, and location of high-intensity lesions in the concordant cases are summarized in Table 1. All lesions were located either at the gray matter-white matter junction or in the deep white matter. None were located in the corpus callosum or brain stem. Both readers interpreted the white matter as normal in 13 patients, but they disagreed regarding the presence of foci of increased signal intensity in 4 patients. The κ for interobserver agree-

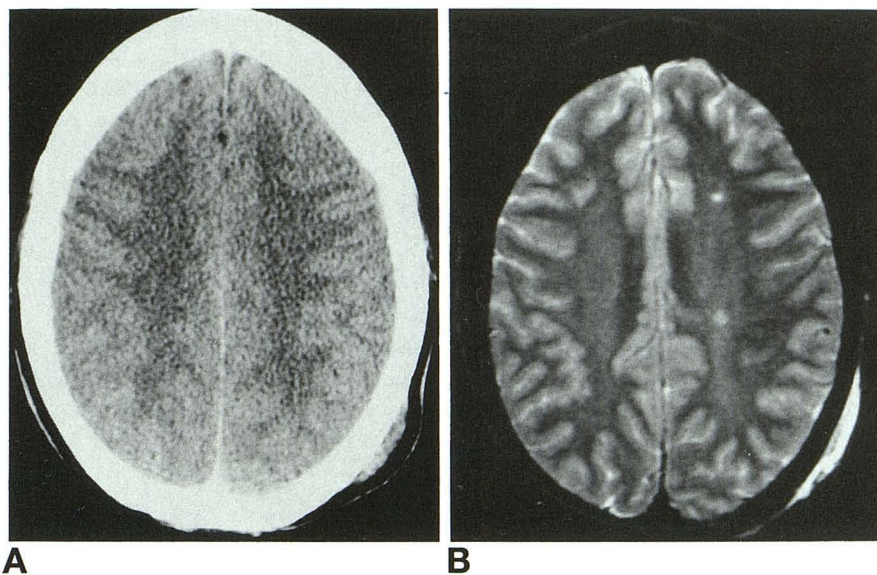


Fig 1. A, There is no evidence of abnormality on head CT of a 20-year-old woman after mild head injury caused by an assault.

B, T2-weighted spin-echo MR images obtained within 24 hours of injury in the same patient at the same level demonstrate foci of high signal intensity in the white matter compatible with nonhemorrhagic diffuse axonal injury.

ment regarding the presence of white matter high-signal-intensity foci on this pulse sequence was 0.57, indicating moderate interobserver agreement.

On gradient-echo T2*-weighted MR images, both readers agreed that foci of hypointensity were present in white matter of 4 (20%) of the 20 patients (95% confidence interval, 6% to 44%). Almost all of these foci were located immediately below the cortex and presumably represented small foci of hemorrhagic shear

injury. Figure 2 illustrates one of these cases at a level in which spin-echo imaging was normal but T2*-weighted gradient-echo imaging demonstrated abnormal hypointensity. Two of the patients had lost consciousness after motor vehicle accidents, and two after assaults. The number, size, and location of the lesions in concordant cases are listed in Table 1. None were located in the corpus callosum or brain stem. Both readers interpreted the white matter as normal in 12 cases, but they dis-

TABLE 1: Number, location, and size of foci of abnormal signal intensity for cases in which both readers agreed abnormality was present on MR images at 1.5 T in patients after mild head injury with normal head CT findings

Case	Number of Lesions	
	Reader 1	Reader 2
High-intensity foci on T2-weighted spin-echo images		
1	2 [DWM (3), DWM (3)]	2 [DWM (3), DWM (3)]
2	2 [GW (3), GW (3)]	1 [GW (3)]
3	2 [GW (6), GW (2)]	1 [GW (4)]
Low-intensity foci on T2*-weighted gradient-echo images		
2	1 [GW (5)]	1 [GW (3)]
4	2 [GW (10), GW (6)]	2 [GW (16), GW (3)]
6	3 [GW (3), GW (3), GW (3)]	1 [GW (3)]
7	5 [DWM (3), GW (3), GW (3), GW (3), GW (3)]	7 [all GW (1, 2, 2, 2, 2, 3, 4)]

Note.—Data in brackets represent location (size in millimeters). GW indicates gray matter–white matter junction; DWM, deep white matter (centrum semiovale, corona radiata).

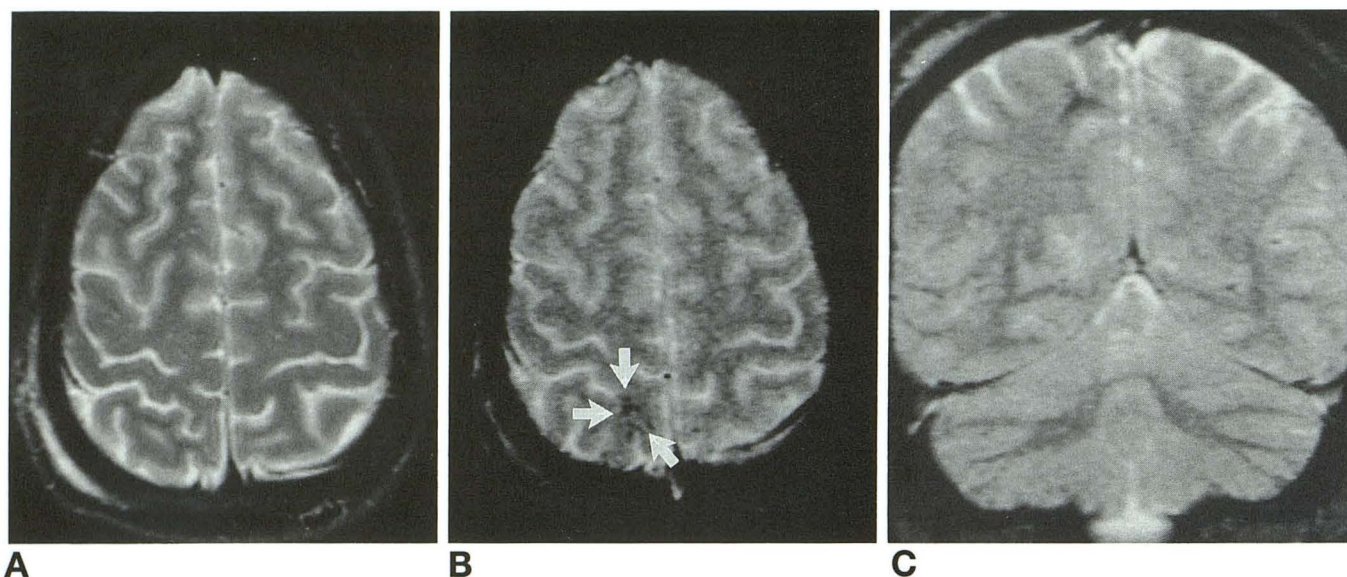


Fig 2. A, There is no evidence of abnormal high or low signal intensity on T2-weighted spin-echo MR of the brain of a 20-year-old man obtained within 24 hours after mild head injury caused by an automobile accident. Head CT (not shown) was also normal.

B, Axial T2*-weighted gradient-echo imaging in the same patient at the same level reveals evidence of abnormal hypointensity at the gray matter-white matter junction in the right occipital region compatible with hemorrhagic diffuse axonal injury (*white arrows*).

C, Coronal T2*-weighted images confirm the subcortical location of the hypointense focus.

agreed regarding the presence of hypointense foci in 4 cases. The κ for interobserver agreement regarding the presence of white matter low-signal-intensity foci on this pulse sequence was 0.52, indicating moderate interobserver agreement.

Table 2 compares the readers' interpretations of the T2-weighted spin-echo and T2*-weighted gradient-echo images. In 30% of the cases (95% confidence interval, 12% to 54%) the readers agreed that an abnormality compatible with diffuse axonal injury was present, represented by either high signal intensity on the spin-echo or low intensity on the gradient-echo images. In three of the four cases for

which both readers agreed that hypointense foci were present on T2*-weighted gradient-echo images, the readers disagreed on the interpretation of the T2-weighted spin-echo images with only one reader identifying abnormal signal intensity on these images. In these three cases the spin-echo abnormalities were in different sites from the gradient-echo abnormalities.

In one case without white matter abnormality the readers agreed that a lesion isolated to the cerebral cortex was present. They noted an approximately 1.5-cm focus in the right frontal cortex that was hypointense on T2-weighted spin-echo and gradient-echo images compati-

TABLE 2: Comparison of blinded reader interpretations of T2-weighted spin-echo and T2*-weighted gradient-echo images for white matter abnormalities on MR at 1.5 T, after mild head injury and normal head CT findings

		T2*-Weighted Gradient-Echo Images		
		Both readers interpreted as normal	One reader interpreted as normal, one reader as abnormal	Both readers interpreted as abnormal
T2-weighted spin-echo images	Both readers interpreted as normal	11	2	
	One reader interpreted as normal, one reader interpreted as abnormal	1		3
	Both readers interpreted as abnormal		2	1

Note.—Total studies = 20.

ble with an acute hemorrhagic cortical contusion not identified on a CT performed the previous day.

Discussion

Our data indicate that MR abnormalities compatible with diffuse axonal injury occur in approximately 30% of cases with mild head injury and normal head CT findings. These changes indicate that a pathologic process occurs in some mildly head-injured patients that is not detected by CT but is revealed by MR. This pathologic substrate potentially plays a role in the postconcussion syndrome, a constellation of subjective complaints associated with objective deficits on neuropsychological testing which occurs in up to one half of patients after mild head injury.

The neuropathologic and radiologic changes of diffuse axonal injury have been extensively described in moderately to severely head-injured patients. Pathologic changes demonstrated include axonal retraction balls, microglial proliferation, and demyelination with or without associated hemorrhage (7–22). These abnormalities are manifested on MR at low and intermediate field strengths as high-signal-intensity foci on long-repetition-time/echo-time spin-echo pulse sequences (27–31). A few studies of severely head-injured patients have indicated that lesions with signal intensities compatible with hemorrhage can occasionally be found on spin-echo images, especially at 1.5 T (32, 33), and that T2*-weighted gradient-echo imaging demonstrates more hemorrhagic foci than does spin-echo imaging (33).

Although most patients meeting criteria for mild head injury (Glasgow Coma Score 13 to 15; no deterioration, brief loss of consciousness) are not examined pathologically, there are experimental animal data (43, 44) indicating that pathologic changes characteristic of diffuse axonal injury occur after mild head injury. Several MR studies have included mildly head-injured patients, but the imaging characteristics of this subgroup are difficult to determine from the heterogeneous populations of patients reported (34–37). Almost all prior studies that included patients with mild head injury were performed at low field strength, and many appear to have included at least some patients with abnormalities on CT.

This study shows that there are lesions compatible with hemorrhagic and nonhemorrhagic diffuse axonal injury revealed in mildly head-injured patients on MR at 1.5 T but not shown by CT. This confirms previous studies of moderate to severe head injury showing that MR is more sensitive than CT for nonhemorrhagic diffuse axonal injury (27–33), and shows that hemorrhagic diffuse axonal injury may be missed by CT alone.

The lesions in mildly head-injured patients were not as widely distributed as in moderate to severe head injury, occurring solely in subcortical white matter. No lesions were located in the corpus callosum or brain stem, common locations in more severely injured patients (31, 45). Most were located at the gray matter–white matter junction, but some were located in deep white matter. These two sites of shear injury have been described previously in radiologic studies of moderate to severe head injury (25, 28, 31). Our cases demonstrated a relatively low number of lesions per positive case, even with the use of sensitive pulse sequences. The distribution and low number of lesions in our cases may relate to the less severe disturbance of consciousness that characterizes mild head injury relative to more severe forms.

Although the sequelae of mild head injury are not usually devastating, the disability that occurs in these patients should not be considered trivial. Important subjective and objective cognitive deficits occur in these patients leading to significant disability (3–6). The focal changes we demonstrated on MR may represent the pathologic substrate that underlies this postconcussion syndrome. Despite objective findings on neuropsychological testing, however, it is not uncommon to construe patients' complaints after mild head injury as merely a hysterical reaction to the traumatic event, or perhaps being related to secondary gain (5). Our data support the contention that the postconcussion syndrome, at least in some patients, has a pathologic substrate.

Our data also demonstrate the importance of selecting appropriate MR techniques for evaluating mildly head-injured patients. Conventional T2-weighted spin-echo and T2*-weighted gradient-echo pulse sequences seem to be complementary in evaluating these cases, reflecting the fact that shearing injuries in the white matter may be hemorrhagic or nonhemorrhagic. Although high-signal-intensity foci in

white matter on T2-weighted spin-echo images are nonspecific, they are suggestive of nonhemorrhagic diffuse axonal injury in the acutely head-injured patient. This is especially true in young patients without chronic medical conditions, such as those examined in our study, in whom these findings are uncommon. Demonstration of hemorrhagic foci (manifested as foci of hypointensity on T2-weighted spin-echo images) is more specific for diffuse axonal injury, but our blinded readers noted this on spin-echo images in only one patient in our study. On T2*-weighted gradient-echo imaging, however, the readers identified four cases in which hypointense foci compatible with hemorrhagic diffuse axonal injury were present. The improved sensitivity of gradient-echo imaging is attributable to its greater sensitivity to susceptibility effects produced by inhomogeneity of the static magnetic field associated with paramagnetic blood products. The dephasing of proton spins produced by these local field inhomogeneities are refocused to a degree in spin-echo imaging but not in gradient-echo imaging (33).

A limitation of this study is the lack of correlation with neuropsychological findings. Although we have shown that 30% of patients demonstrate MR abnormalities after mild head injury, additional work is needed to determine whether this subgroup of patients corresponds to the subgroup with subjective and/or objective neuropsychological findings after trauma. Longitudinal studies correlating neuropsychological recovery with severity of initial imaging abnormalities and evolution of imaging changes are also needed.

Our data also demonstrate the need for assessment of the interobserver variation in readings of spin-echo and gradient-echo images when evaluating lesions that are millimeters in size. Interpretation of both sequences is confounded by potential pitfalls: on long-repetition-time spin-echo images pathologic high-signal-intensity foci must be distinguished from perivascular spaces, and on T2*-weighted gradient-echo images pathologic hypointensity must be distinguished from artifactual hypointensity. Our analysis took this into account and dismissed those patients in whom the readers disagreed. Theoretically, therefore, our data may minimize the number of patients in whom changes occur after injury.

In summary, our results reveal MR changes compatible with nonhemorrhagic and hemor-

rhagic diffuse axonal injury after mild head injury which are not shown by CT. These changes may represent the pathologic substrate that underlies the postconcussion syndrome found in many mildly head-injured patients. Other studies have demonstrated that MR is more sensitive than CT for detecting parenchymal injuries such as diffuse axonal injury and contusions after moderate and severe head trauma (27-33), and this study extends those observations to the mildly head-injured patient. The greater sensitivity of MR than CT makes it a better indicator of the presence and extent of injury and thus potentially a better predictor of outcome. These points, as well as mildly head-injured patients being a stable group of patients with good neurologic status, should be considered in developing imaging strategies. MR may be justifiable as the sole study in selected patients with brief loss of consciousness and excellent neurologic status. Although some investigators have proposed that CT should provide the basis for updated classification schemes of head injury for use in research and clinical settings (46, 47), this study indicates that MR should play a major role in any classification scheme of head injury, especially in mildly head-injured patients.

References

1. Kraus JF, Nourjah P. The epidemiology of mild uncomplicated brain injury. *J Trauma* 1988;28:1637-1643
2. Kraus JF, Black MA, Hessol N, et al. The incidence of acute brain injury and serious impairment in a defined population. *Am J Epidemiol* 1984;119:186-201
3. Levin HS, Mattis S, Ruff RM, et al. Neurobehavioral outcome following minor head injury: a three-center study. *J Neurosurg* 1987;66:234-243
4. Hugenholtz H, Stuss DT, Stethem BA, Richard MT. How long does it take to recover from mild concussion? *Neurosurgery* 1988;22:853-858
5. Evans RW. The postconcussion syndrome and the sequelae of mild head injury. *Neurol Clin* 1992;10:815-847
6. Capruso DX, Levin HS. Cognitive impairment following closed head injury. *Neurol Clin* 1992;10:879-893
7. Rand CW, Courville CB. Histologic changes in the brain in cases of fatal injury to the head. *Arch Neurol Psychiatry* 1934;31
8. Strich SJ. Shearing of nerve fibers as a cause of brain damage due to head injury. *Lancet* 1961;2:443-448
9. Oppenheimer DR. Microscopic lesions in the brain following head injury. *J Neurol Neurosurg Psychiatry* 1968;31:299-306
10. Nevin NC. Neuropathologic changes in the white matter following head injury. *J Neuropathol Exp Neurol* 1967;26:77-84
11. Peerless SJ, Rewcastle NB. Shear injuries of the brain. *Can Med Assoc J* 1967;96:577-582
12. Tomlinson BE. Brain-stem injuries of the brain. *J Clin Pathol* 1970;23:154-165

13. Adams JH, Mitchell DE, Graham DI, Doyle D. Diffuse brain damage of immediate impact type. *Brain* 1977;100:489-502
14. Adams JH, Graham DI, Gennarelli TA. Neuropathology of acceleration-induced head injury in the subhuman primate. In: Grossman RG, Gildenberg PL, eds. *Head Injury: Basic and Clinical Aspects*. New York: Raven, 1982:141-150
15. Adams JH, Graham DI, Murray LS, Scott G. Diffuse axonal injury due to nonmissile head injury in humans: an analysis of 45 cases. *Ann Neurol* 1982;12:557-563
16. Gennarelli TA, Adams JH, Graham DI. Acceleration induced head injury in the Minkey, I: the model, its mechanical and physiological correlates. *Acta Neuropathol (Berl)* 1981;Suppl VII:23-25
17. Gennarelli TA, Thibault LE, Adams JH, Graham DI, Thompson CJ, Marcincin RP. Diffuse axonal injury and traumatic coma in the primate. *Ann Neurol* 1982;12:564-574
18. Gennarelli TA, Thibault LE, Adams TA, Graham DI, Thompson CJ, Marcincin RP. Diffuse axonal injury and traumatic coma in the primate. In: Dacey RG, ed. *Trauma of the Central Nervous System*. New York: Raven, 1985:169-193
19. Maxwell WL, Irvine A, Adams JH, Graham DI, Gennarelli TA. Response of cerebral microvasculature to brain injury. *J Pathol* 1988;155:327-335
20. Maxwell WL, Kansagra AM, Graham DI, Adams JH, Gennarelli TA. Freeze-fracture studies of reactive myelinated nerve fibres after diffuse axonal injury. *Acta Neuropathol (Berl)* 1988;76:395-406
21. Blumbergs PC, Jones NR, North JB. Diffuse axonal injury in head trauma. *J Neurol Neurosurg Psychiatry* 1989;52:838-841
22. Bullock R, Maxwell WL, Graham DI, Teasdale GN, Adams JH. Glial swelling following human cerebral contusion: an ultrastructural study. *J Neuro Neurosurg Psychiatry* 1991;54:427-434
23. Zimmerman RA, Bilaniuk LT, Gennarelli T. Computed tomography of shearing injuries of the cerebral white matter. *Radiology* 1978;127:393-396
24. Wilberger JE, Rothfus WE, Tabas J, Goldberg AL, Deeb ZL. Acute tissue tear hemorrhages of the brain: computed tomography and clinicopathological correlations. *Neurosurgery* 1990;27:208-213
25. Levi L, Guilburd JN, Lemberger A, Soustiel JF, Feinsod M. Diffuse axonal injury: analysis of 100 patients with radiological signs. *Neurosurgery* 1990;27:419-432
26. Kido DK, Cox C, Hamill RW, Rothenberg BM, Woolf PD. Traumatic brain injuries: predictive usefulness of CT. *Radiology* 1992;182:777-781
27. Levin HS, Kalisky Z, Handel SF, et al. Magnetic resonance imaging in relation to the sequelae and rehabilitation of diffuse closed head injury; preliminary findings. *Semin Neurology* 1985;5:221-232
28. Wilberger JE, Deeb Z, Rothfus W. Magnetic resonance imaging in cases of severe head injury. *Neurosurgery* 1987;20:571-576
29. Hesselink JR, Dowd CF, Healy ME, Hajek P, Baker LL, Luerssen TG. MR imaging of brain contusions: a comparative study with CT. *AJNR Am J Neuroradiol* 1988;9:269-278
30. Gentry LR, Godersky GC, Thompson B, Dunn VD. Prospective comparative study of intermediate-field MR and CT in the evaluation of closed head trauma. *AJNR Am J Neuroradiol* 1988;150:673-682
31. Gentry LR, Godersky JC, Thompson B. MR imaging of head trauma: review of the distribution of radiopathologic features of traumatic lesions. *AJNR Am J Neuroradiol* 1988;150:663-672
32. Zimmerman RA, Bilaniuk LT, Hackney DB, Golberg HI, Grossman RI. Head injury: early results of comparing CT and high-field MR. *AJNR Am J Neuroradiol* 1986;7:757-764
33. Atlas SW, Mark AS, Grossman RI, Gomori JM. Intracranial hemorrhage: gradient-echo MR imaging at 1.5T. Comparison with spin echo imaging and clinical applications. *Radiology* 1988;168:803-807
34. Snow RB, Zimmerman RD, Gandy SE, Deck MDF. Comparison of magnetic resonance imaging and computed tomography in the evaluation of head injury. *Neurosurgery* 1986;18:45-52
35. Levin HS, Amparo E, Eisenberg HM, et al. Magnetic resonance imaging and computerized tomography in relation to neurobehavioral sequelae of mild and moderate head injuries. *J Neurosurg* 1987;66:706-713
36. Yokota H, Kurokawa A, Otsuka T, Kobayashi S, Nakazawa S. Significance of magnetic resonance imaging in acute head injury. *J Trauma* 1991;31:351-357
37. Doezeema D, Espinosa MC, King JN, Orrison WW, Tandberg D. Magnetic resonance imaging in minor head injury. *Ann Emerg Med* 1991;20:449
38. Gomori JM, Grossman RI, Goldberg HI, Zimmerman RA, Bilaniuk LT. Intracranial hematomas: imaging by high-field MR. *Radiology* 1985;157:87-93
39. Gillis P, Koenig SH. Transverse relaxation of solvent protons induced by magnetized spheres: application to ferritin, erythrocytes and magnetite. *Magn Reson Med* 1987;5:323-345
40. Teasdale G, Jennett B. Assessment of coma and impaired consciousness. *Lancet* 1974;2:81-83
41. Beyer WH ed. *CRC Standard Probability and Statistics: Tables and Formulae*. Boston: CRC Press, 1991:151.
42. Landis JR, Koch GG. The measurement of observer agreement for categorical data. *Biometrics* 1977;33:159-174
43. Povlishock JT, Becker DP, Cheng CLY, Voughn GW. Axonal change in minor head injury. *J Neuropathol Exper Neurol* 1983;42:225-242
44. Jane JA, Steward O, Gennarelli T. Axonal degeneration induced by experimental noninvasive minor head injury. *J Neurosurg* 1985;62:96-100
45. Gentry LR, Godersky JC, Thompson BH. Traumatic brain stem injury: MR imaging. *Radiology* 1989;171:177-187
46. Marshall LF, Marshall SB, Klauber MR, et al. A new classification of head injury based on computed tomography. *J Neurosurg* 1991;75(suppl):S14-S20
47. Marshall LF, Marshall SB, Klauber MR, et al. The diagnosis of head injury requires a classification based on computed axial tomography. *J Neurotrauma* 1992;9 Suppl 1:S287-292