

Are your **MRI contrast agents** cost-effective?

Learn more about generic **Gadolinium-Based Contrast Agents**.



FRESENIUS
KABI

caring for life

AJNR

In vitro evaluation of papaverine hydrochloride incompatibilities: a simulation of intraarterial infusion for cerebral vasospasm.

J M Mathis, A J DeNardo, L Thibault, M E Jensen, J Savory and J E Dion

This information is current as of April 20, 2024.

AJNR Am J Neuroradiol 1994, 15 (9) 1665-1670
<http://www.ajnr.org/content/15/9/1665>

In Vitro Evaluation of Papaverine Hydrochloride Incompatibilities: A Simulation of Intraarterial Infusion for Cerebral Vasospasm

John M. Mathis, Andrew J. DeNardo, Lucie Thibault, Mary E. Jensen, John Savory, and Jacques E. Dion

PURPOSE: To elucidate, in light of reports of complications associated with intraarterial infusion of papaverine hydrochloride, the known propensity of papaverine hydrochloride to form precipitate in combination with other solutions or pharmaceuticals. **METHODS:** Initially simulating a situation experienced during an intraarterial papaverine infusion for cerebral vasospasm, we mixed various concentrations of papaverine with serum, nonheparinized and heparinized saline, and nonionic contrast material. **RESULTS:** Papaverine in concentrations of 0.3% (300 mg/100 mL of normal saline) or greater formed a precipitate when mixed with human serum (blood). The precipitate crystals were 50 to 100 μm in size and could be returned to solution simply by the addition of more serum. **CONCLUSION:** Crystal emboli are a possible transient cause of complications experienced during treatment of vasospasm with its attendant altered flow dynamics.

Index terms: Drugs, intraarterial injection; iatrogenic disease or disorders; Interventional neuroradiology, complications of; Subarachnoid space, hemorrhage; Vasospasm

AJNR Am J Neuroradiol 15:1665-1670, Oct 1994

Papaverine hydrochloride is a member of the benzylisquinoline group of alkaloids, which may be prepared synthetically or obtained from opium (1). The most characteristic clinical effect of papaverine is smooth muscle relaxation in the vascular system, as well as in the bronchial musculature and gastrointestinal, biliary, and urinary tracts. For more than 2 decades it has been used intraarterially in the peripheral vascular system to increase perfusion or to reverse vasospasm. More recently, intraarterial papaverine has been used in cerebral vessels to counteract clinical vasospasm after subarachnoid hemorrhage (2, 3). The effects on vasospasm in the cerebral circulation, although not permanent, are nevertheless encouraging and suggest that papaverine may be a useful thera-

peutic option. However, reports also have included complications associated with papaverine infusion (2, 4, 5). Papaverine has long been known to be potentially unstable in solution, forming a precipitate in various mixtures. This report describes the conditions and results under which papaverine is found to be unstable while simulating a clinical infusion for cerebral vasospasm.

Materials and Methods

To simulate a situation commonly experienced during intraarterial papaverine infusion for cerebral vasospasm, we assumed a typical patient with a 5-L intravascular volume and a recent diagnostic angiogram using 100 mL of nonionic radiographic contrast material (300 mg/mL of iohexol [Winthrop, New York, NY]). Additionally, heparinized saline (4000 to 6000 U/L) is commonly used as a flush solution. Heparin is often administered intravenously in quantities of 3000 to 5000 U when microcatheters are used. The papaverine is usually infused with normal saline in a 0.3% (300 mg/100 mL) of normal saline concentration.

These parameters established the following physiologic test situation: (a) 37°C temperature, 5000 mL extravascular volume; (b) 0.3% papaverine concentration in normal saline; (c) 4 U of heparin/mL saline (flush); (d) 0.5 U of heparin/mL (in vivo heparin concentration assuming a 5000-U bolus); and (e) 0.02 mL of 300 mg/mL nonionic

Received October 29, 1993; accepted for publication February 7, 1994.

From the Division of Neuroradiology, Endovascular Therapy Section (J.M.M., A.J.D., M.E.J., J.E.D.), and the Division of Clinical Chemistry and Biochemistry (J.S.), University of Virginia Health Sciences Center, Charlottesville; and Target Therapeutics, Fremont, Calif (L.T.).

Address reprint requests to John M. Mathis, MD, MS, Division of Neuroradiology, Box 170, University of Virginia Health Sciences Center, Charlottesville, VA 22908.

AJNR 15:1665-1670, Oct 1994 0195-6108/94/1509-1665

© American Society of Neuroradiology

contrast per milliliter in vivo (100 mL contrast for diagnostic angiogram). The above-mentioned concentrations of papaverine, heparinized saline, and radiographic contrast served only as initial guides to probable physiologic concentrations of common substances likely to be mixed (along with blood) during an actual infusion. Concentrations were varied on either side of these starting points, typically by a factor of 10.

Spectrophotometric analysis of each mixture (at 37°C) was obtained using a Beckman DU-7 Spectrophotometer (Beckman Instruments, Irvine, Calif). An ultraviolet and visible light absorption spectrum was obtained on each sample after standardization. The spectrum ranged from 225 to 700 nm.

The stability of papaverine in solution was also evaluated with respect to change in pH. Papaverine solutions of 3%, 0.3%, and 0.03% (with and without preservative) were buffered with sodium hydroxide, which is used as a buffer in papaverine preparation. A Beckman Phi 44 pH meter was used to monitor pH. Precipitate formation was detected visually and spectrophotometrically.

Precipitates obtained in serum and during pH adjustments were examined with light microscopy for crystal shape and size.

Results

Measurements of papaverine hydrochloride with chlorobutanol preservative (Lilly, Indianapolis, Ind), 30 mg/mL (3.0%), demonstrated an acidic mixture with a pH of 3.3. Slowly buffering this preparation with small aliquots of sodium hydroxide consistently produced a fine white precipitate above a pH of 5.3. This situation also held true for papaverine hydrochloride without chlorobutanol preservative (Frosst, Kirkland, Quebec, Canada). Papaverine at 0.3% (300 mg/100 mL of normal saline) concentration also precipitated between 5.3 and 5.4 pH. However, when diluted to 0.03% (30 mg/100 mL of normal saline), there was no precipitate formation, indicating that the stability of papaverine in solution is concentration as well as pH dependent (Table).

Precipitate formation was also found to be concentration dependent when papaverine was mixed with heparinized saline and serum (Table). A precipitate is formed when 3.0% (30 mg/mL) papaverine is mixed with heparinized saline between 2000 and 10 000 U/L (Fig 1). This concentration of papaverine, although common for peripheral infusion, is not used intracranially. Papaverine is typically mixed at a concentration of 300 mg/100 mL of normal saline (0.3%) for cerebral infusion. A papaverine concentration of 0.3% or less revealed no detectable precipitate when mixed with heparinized saline solutions (Fig 2).

In nonheparinized human serum, papaverine forms a white precipitate when used in 3.0% and 0.3% concentrations (Fig 3). Initially, small quantities of papaverine added to serum will form a layer of precipitate that can be redissolved when the solution is agitated. Continued addition of papaverine eventually will develop a permanent precipitate; this quantity was found to be 0.6 mL of 0.3% papaverine per milliliter of serum (Fig 4). When this point is reached, additional serum combined during agitation will redissolve the papaverine precipitate. The reversibility of precipitate formation is the same with or without chlorobutanol preservative.

We tested papaverine at various concentrations in normal saline, 300 mg/mL of iohexol, 300 mg/mL of iopamidol (Squibb, New Brunswick, NJ), and 320 mg/mL of ioversol (Mallinckrodt, St. Louis, Mo) without evidence of precipitate (Fig 5).

Papaverine precipitate microscopically has a variable crystalline configuration (Fig 6) with crystal sizes ranging from 50 to 100 μ m.

Discussion

Papaverine was originally derived from crude opium but has no apparent narcotic properties.

Papaverine incompatibilities

Papaverine, %	Serum	Heparin	Contrast	Saline	pH 4	pH 5	pH 6
3.0 (W)	+	+	-	-	+	+	+
0.3 (W)	+	-	-	-	-	+	+
0.03 (W)	-	-	-	-	-	-	-
3.0 (WO)	+	+	-	-	-	+	+
0.3 (WO)	+	-	-	-	-	+	+
0.03 (WO)	-	-	-	-	-	-	-

Note.—Heparin is 2000 to 10 000 U/L of normal saline; contrast, 300 mg/mL of iohexol, 320 mg/mL of ioversol, and 300 mg/mL of iopamidol; and saline, 0.9% sodium chloride (normal saline). W indicates with chlorobutanol; WO, without chlorobutanol; +, precipitate; and -, no precipitate.

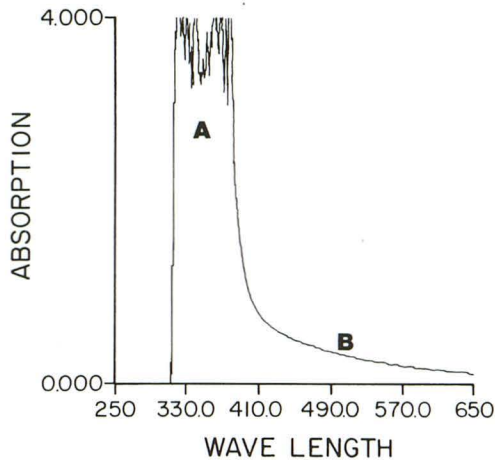


Fig 1. Spectrophotometric analysis of 3.0% papaverine combined with heparinized saline (5000 U/L). A precipitate was visible and represented by the portion of the spectrum labeled B (the portion labeled A represents papaverine).

It is a potent smooth muscle relaxant that produces generalized arteriolar dilatation and smooth muscle relaxation (6). The mechanism of action is not known, but may be related to elevated levels of intracellular cyclic adenosine monophosphate and secondary to inhibition of phosphodiesterase (7). Metabolism is largely hepatic, and 90% of circulating papaverine is protein bound (1). The half-life is estimated to be between 1 and 2 hours (8).

Recommended uses of papaverine are diverse and include treatment of ventricular arrhythmias (historical) and vasospasm associated with coronary occlusion and infarction (9). It also has been used for peripheral vascular

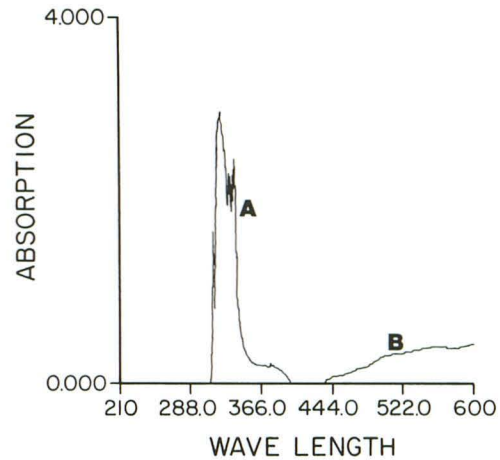


Fig 3. Spectrophotometric analysis of 0.3% papaverine combined with serum. Peak A represents papaverine and peak B the precipitate.

disease, both diffuse and focal (10). The drug has been shown to increase cerebral blood flow in patients with cerebrovascular disease (11, 12). However, papaverine, like other vasodilators, can decrease flow to ischemic areas when used shortly after ischemic stroke (13, 14). Papaverine has recently been used intraarterially in the cerebral vasculature for vasospasm after subarachnoid hemorrhage (2, 3, 15, 16). When used early after the onset of clinical vasospasm, it often has a beneficial effect, with associated vasodilation and improved regional perfusion. The response of vasospasm to papaverine after subarachnoid hemorrhage may be transient, with vasodilation diminishing from 12 to 24 hours. Also, work in animals suggests

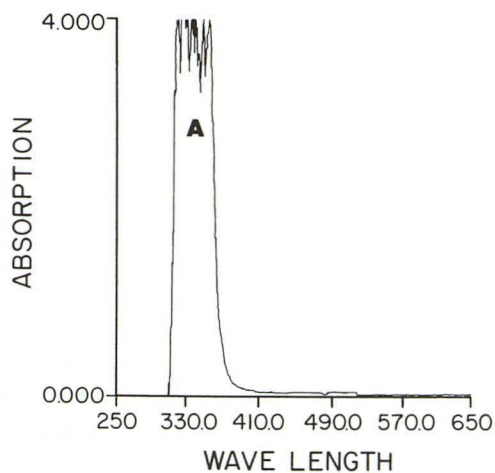


Fig 2. Heparinized saline (5000 U/L) mixed with 0.3% papaverine produced no precipitate (the portion of the spectrum marked A again represents papaverine).

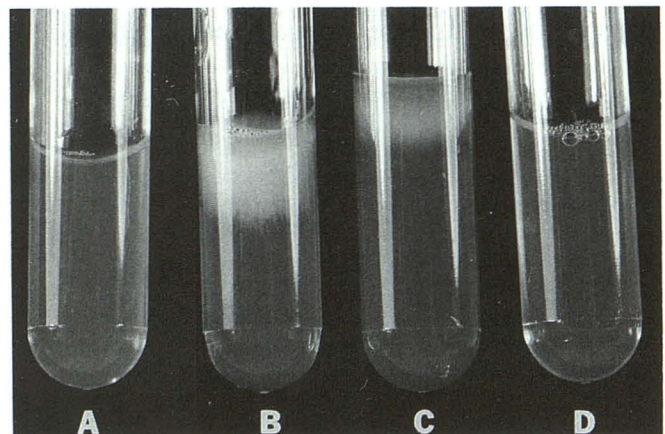


Fig 4. A, Serum; B, serum plus 3.0% papaverine; C, serum plus 0.3% papaverine; D, serum plus 0.3% papaverine after agitation. Precipitate originally formed in tube D returns to solution with agitation.

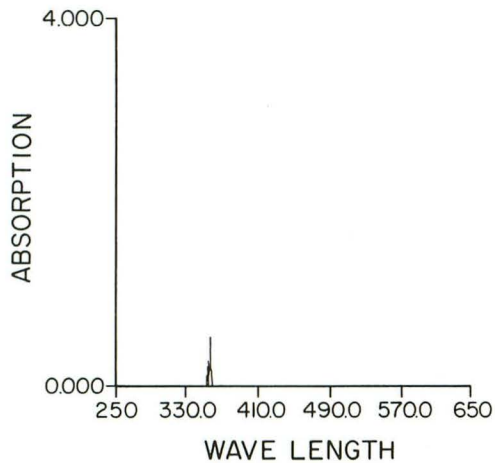


Fig 5. Iohexol (300 mg/mL) combined with 3.0% papaverine. Absorption peak caused by papaverine. No precipitate.

that vasospasm becomes progressively refractory to papaverine infusion 48 hours or more after its onset (17, 18). This is believed to be related to irreversible structural changes in the endothelium, smooth muscle cell layer, and adventitia that occur several days after subarachnoid hemorrhage (19–21).

Known complications include hypotension and tachycardia. Ectopic rhythms of ventricular origin may be produced when an arteriovenous conduction abnormality exists. Sedation has been reported as a side effect in humans, and progressive central nervous system depression is noted in animals at high dose levels (1). There is an anecdotal report of coma after an intramuscular injection (22). Also, vessel occlusion was noted in an upper extremity after intraarterial use of papaverine combined with radiographic contrast material (23). Complications in the central nervous system after intraar-




Fig 6. Light photomicrograph of a precipitate crystal that has a maximum dimension of 100 μ m.

terial injections for vasospasm have been described and include transient hemiparesis (2), cranial nerve deficits, and reversible brain stem depression (4). The cause of these complications is not yet known. Thus far, all adverse effects from intraarterial papaverine used for cerebral vasospasm have been transient. They are, however, distressing to the health care team and, when not recognized and appropriately treated, potentially life threatening (ie, brain stem depression with respiratory arrest).

Complications that result during infusion for cerebral vasospasm occur in situations of altered flow dynamics and during infusions near small perforators. As yet, it has not been determined whether complications result from: (a) primary toxic or neurodepressive effects, or (b) secondary embolic or ischemic effects associated with precipitate formation. Indeed, both potentially could be produced or accentuated by the low flow state created with vasospasm. Direct neurodepressive effects have been suggested (5). Incompatibilities with radiographic contrast (most notably Hexabrix) resulting in precipitate formation have been described on several occasions (24–29), as well as instability in solutions with pH above 5.0 (30). Intrathecal injection of a 3% concentration of papaverine also resulted in precipitate formation.

This *in vitro* investigation attempted to simulate concentrations of materials that potentially could be combined with papaverine during an infusion for cerebral vasospasm. The results indicate that papaverine solutions of 0.3% or higher concentration have the propensity to form precipitate when mixed with serum (Fig 7). This would be accentuated by a low flow state, as found in vasospasm, in which any dilutional effect would be minimized. Concentration-dependent precipitate formation could be reduced or prevented by using more dilute solutions of papaverine or by slowing the infusion rate (as evidenced by papaverine's being redissolved with the addition of serum and/or agitation [Fig 4]). Papaverine did not form precipitate with heparinized saline when diluted to 0.3% (300 mg/100 mL of normal saline (Table)). Compatibility with nonionic contrast (iohexol, iopamidol, and ioversol) was also demonstrated. No difference in compatibility was noted between papaverine with or without chlorobutanol preservative.

Papaverine hydrochloride has proved, in this and other evaluations, to be potentially unstable

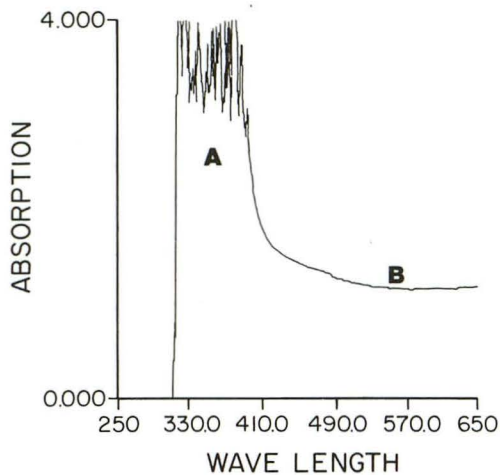


Fig 7. Spectrophotometric analysis of 3.0% papaverine buffered to a pH of 5.3; area B of the absorption curve indicates the precipitate.

in solution at certain concentrations mixed with serum, ionic contrast material, or heparinized saline, or when buffered above a pH of 5.0 (Table). This instability is, in all situations, concentration dependent. Precipitate crystals are 50 to 100 μm in size and have very irregular, angular shapes (Fig 6). Once formed, papaverine crystals easily could create significant emboli distally with expected ischemic symptoms. Ischemic symptoms might be transient because of resuspension of precipitate over time. These problems are diminished by dilutions that decrease the papaverine concentration to less than 0.3% before infusion and a slower papaverine infusion rate. When a diagnostic angiogram reveals severely restricted flow or the need to infuse near perforating vessels, a decreased papaverine concentration or protracted infusion time should be considered. It is hoped that this would decrease the chance of embolic and ischemic complications associated with precipitate formation and minimize possible direct neurodepressant effects.

Conclusions

Complications have been reported with intraarterial infusion of papaverine for cerebral vasospasm. This study confirms the potential for papaverine to precipitate and form emboli in low-flow situations. Although it is not yet possible to determine whether the complications result from a direct (neurodepressant) or secondary (embolic or ischemic) effect, appropriate attention to the papaverine concentration and

infusion rate may be helpful in decreasing side effects.

Acknowledgments

We thank Joyce Henderson for secretarial assistance, Jan Houchens for technical assistance, and Carol Newcomb for copy editing in the preparation of this manuscript.

References

1. Papaverine Hydrochloride. In: *Physicians' Desk Reference*. Montvale, NJ: Medical Economics Data, 1993;47:1290-1291
2. Kassell NF, Helm G, Simmons N, Phillips CD, Cail WS. Treatment of cerebral vasospasm with intra-arterial papaverine. *J Neurosurg* 1992;77:848-852
3. KaKu Y, YoneKawa Y, Tsurahara T, KazeKawa K. Supraselective intra-arterial infusion of papaverine for the treatment of cerebral vasospasm after subarachnoid hemorrhage. *J Neurosurg* 1992;77:842-847
4. Mathis JM, De Nardo A, Jensen ME, Scott J, Dion JE. Transient neurologic events associated with intraarterial papaverine infusion for subarachnoid hemorrhage-induced vasospasm. *AJNR Am J Neuroradiol* 1994;15:1671-1674
5. Barr JD, Mathis JM, Horton JA. Transient severe brain stem depression during intraarterial papaverine infusion for cerebral vasospasm. *AJNR Am J Neuroradiol* 1994;15:719-723
6. Cook P, James I. Cerebral vasodilators. *N Engl J Med* 1981;305:1508-1513
7. Poch G, KuKovetz WR. Papaverine-induced inhibition of phosphodiesterase activity in various mammalian tissues. *Life Sci* 1971;10:133-144
8. Arnold JD, Baldrige J, Riley B, Brody G. Papaverine hydrochloride: the evaluation of two new dosage forms. *Int J Clin Pharmacol* 1977;15:230-233
9. Martindale W. *The Extra Pharmacopoeia*. 27th ed. London: Pharmaceutical Press, 1977
10. Boley SJ, Siegelman SS. Experimental and clinical nonocclusive mesenteric ischemia. In: Hilal SK, ed. *Small Vessel Angiography*. St. Louis: CV Mosby, 1973:438-453
11. Meyer JS, Gotoh F, Gilroy J, Nara N. Improvements in brain oxygenation and clinical improvement in patients with strokes treated with papaverine hydrochloride. *JAMA* 1965;194:957-961
12. McHenry LC, Jaffe ME, Kawamura J, Goldberg HI. Effects of papaverine on regional blood flow in focal vascular disease of the brain. *N Engl J Med* 1970;282:1167-1170
13. Olesen J, Paulson OB. The effect of intra-arterial papaverine on the regional cerebral blood flow in patients with stroke or intracranial tumor. *Stroke* 1971;8:148-159
14. Capon A, De Rood M, Verbist A, Frushling J. Action of vasodilators on regional cerebral blood flow in subacute or chronic cerebral ischemia. *Stroke* 1977;8:25-29
15. Marks MP, Steinberg GK, Lane B. Intra-arterial papaverine for the treatment of vasospasm. *AJNR Am J Neuroradiol* 1993;14:822-826
16. Livingston K, Hopkins LN. Intra-arterial papaverine as an adjunct to transluminal angioplasty for vasospasm induced by subarachnoid hemorrhage. *AJNR Am J Neuroradiol* 1993;14:346-347
17. Vorkapic P, Bevan RD, Bevan JA. Pharmacologic irreversible narrowing in chronic cerebrovasospasm in rabbits is associated with functional damage. *Stroke* 1990;21:1478-1484

18. Varsos VG, Liszczak T, Han OH, et al. Delayed cerebral vasospasm is not reversible by aminophylline, nifedipine, or papaverine in a two hemorrhage canine model. *J Neurosurg* 1983;58:11-17
19. Duff TA, Scott G, Feilbach JA. Ultrastructural evidence of arterial denervation following experimental subarachnoid hemorrhage. *J Neurosurg* 1986;64:292-297
20. Hughes JT, Schianchi PM. Cerebral artery spasm: a historical study at necropsy of the blood vessels in cases of subarachnoid hemorrhage. *J Neurosurg* 1978;48:515-525
21. Liszczak TM, Varsos VT, Black PM, Kistler JP, Zarvas NT. Cerebral arterial constriction after experimental subarachnoid hemorrhage is associated with blood components within the arterial wall. *J Neurosurg* 1983;58:18-26
22. Ilan Y, Gemer O. Papaverine-induced coma. *Eur J Clin Pharmacol* 1988;33:651
23. Pallan TM, Wulkan IA, Abadir AR, Flores L, Chandhry MR, Gintautas J. Incompatibility of Isovue 370 and papaverine in peripheral arteriography. *Radiology* 1993;87:257-259
24. Shah SJ, Gerlock AJ. Incompatibility of hexabrix and papaverine in peripheral arteriography. *Radiology* 1987;162:619-620
25. McGill JE, Rysavy JA, Frick MD. Experimental investigations of hexabrix-papaverine interaction. *Radiology* 1988;166:577-578
26. Pilla TJ, Beshany SE, Shields JB. Incompatibility of hexabrix and papaverine. *AJR Am J Roentgenol* 1986;146:1300-1301
27. Delcour C. Incompatibility of hexabrix and papaverine (letter). *AJR Am J Roentgenol* 1986;147:1096
28. Irving HD, Barbridge BE. Incompatibility of contrast agents with intravascular medications. *Radiology* 1989;173:91-92
29. Seidmon EJ, Samaha AM. The pH analysis of papaverine-phentolamine and prostaglandin E1 for pharmacologic erection. *J Urol* 1989;141:1458-1459
30. Ogata M, Marshall BM, Loughheed WM. Observations on the effects of intrathecal papaverine in experimental vasospasm. *J Neurosurg* 1973;38:20-25