

Are your **MRI contrast agents** cost-effective?

Learn more about generic **Gadolinium-Based Contrast Agents**.



FRESENIUS
KABI

caring for life

AJNR

Hemangioma of the mandibular condyle and ramus.

A M DelBalso, J B Banyas and L M Wild

AJNR Am J Neuroradiol 1994, 15 (9) 1703-1705

<http://www.ajnr.org/content/15/9/1703.citation>

This information is current as
of April 20, 2024.

Hemangioma of the Mandibular Condyle and Ramus

Angelo M. DelBalso, Jeffrey B. Banyas, and Linda M. Wild

Summary: We report the panoramic zonographic, computed tomographic, and pathologic findings of an intraosseous hemangioma involving the condyle and proximal ramus.

Index terms: Hemangioma; Mandible; Temporomandibular joint, computed tomography

Intraosseous hemangiomas are benign tumors occurring most often in the skull and vertebrae. Rarely, these lesions can present in the maxilla and mandible. We found in the literature a case of an intraosseous hemangioma involving the mandibular condyle (1). We wish to report the panoramic zonographic, computed tomographic, and pathologic findings of another case involving both the condyle and proximal ramus.

Case Report

This case involves a 44-year-old edentulous white woman who presented with an 18-month history of progressively worsening pain in the left auricular and temporomandibular joint area. The patient described the pain as sporadic, and not related to mastication. Physical examination was unremarkable except for mild tenderness in the left medial and lateral pterygoid muscles. A routine panoramic radiograph of the mandible demonstrated an expansile, radiolucent lesion with a striate appearance involving the condylar neck and proximal ramus. The patient was referred to the radiology department for additional panoramic zonographic views of the temporomandibular joints to define the lesion better. These images were obtained in parasagittal and coronal planes using a Zonarc unit (Instrumentarium Corporation, Helsinki, Finland). These studies again demonstrated an expansile, radiolucent lesion with a "striate" or "sunburst" appearance involving the left condyle, condylar neck and proximal ramus (Fig 1A and B). This finding was best demonstrated on the coronal image (Fig 1B). On the basis of the lesion's similar striate appearance to that seen in vertebral and mandibular body hemangiomas, a tentative diagnosis of an intraosseous hemangioma was made. However, a non-contrast-enhanced and a contrast-enhanced computed tomography (CT) examination were ordered to con-

firm the plain film diagnosis and determine the full extent of the lesion.

Axial CT sections through the temporomandibular joints demonstrated preservation of the shape of the condylar head and a prominent radiolucent central region (Fig 1C). Sections through the condylar neck demonstrated a generalized expansion with loss of normal shape, a marked degree of cortical thickening, and a prominent central radiolucency (Fig 1D). Sections through the proximal ramus demonstrated evidence of new bone formation on the lateral and medial aspect of the ramus with areas of incomplete mineralization peripherally (Fig 1E). The lesion did not demonstrate any evidence of contrast enhancement on rapid sequence images through the area after the bolus injection of intravenous contrast. The failure of the lesion to enhance after bolus contrast injection did not support the diagnosis of an intraosseous hemangioma, and in light of the other CT findings it was felt that the possibility of an osteogenic or chondrogenic neoplasm could not be ruled out. The patient subsequently underwent surgery for removal of the condylar head and proximal ramus, followed by reconstruction of the temporomandibular joint using a condylar prosthesis and plate.

Gross examination of the pathologic section demonstrated the condylar head to be twice its normal size. The external surface was composed of extremely thin cortical bone traversed by thick bands of dense cancellous bone with the intervening spaces filled with spongy, hemorrhagic redish black tissue (Fig 2A). Microscopic examination showed attenuated cortical bone with adjacent osteoclasts and rare focal areas of endosteal new bone formation, but without definite pathologic fracture or fracture callous. Struts of dense cancellous bone divided the medullary cavity which contained a cavernous hemangioma composed of numerous thin-walled, blood-filled vascular spaces lined by attenuated endothelial cells (Fig 2B). The patient's postoperative course was unremarkable.

Discussion

Intraosseous hemangiomas constitute 0.7% of osseous neoplasms, and 10% of primary benign neoplasm involving the skull (2). In the skull, the vast majority are located

Received June 2, 1992, accepted and revision received March 3, 1993.

From the Departments of Radiology (A.M.D.), Otolaryngology and Head and Neck Surgery (J.B.B.), and Pathology (L.M.W.), State University of New York at Buffalo School of Medicine and Biomedical Sciences and Erie County Medical Center, Buffalo, NY.

Address reprint requests to Angelo M. DelBalso, MD, Department of Radiology, Erie County Medical Center, 462 Grider St, Buffalo, NY 14215.

AJNR 15:1703-1705, Oct 1994 0195-6108/94/1509-1703 © American Society of Neuroradiology

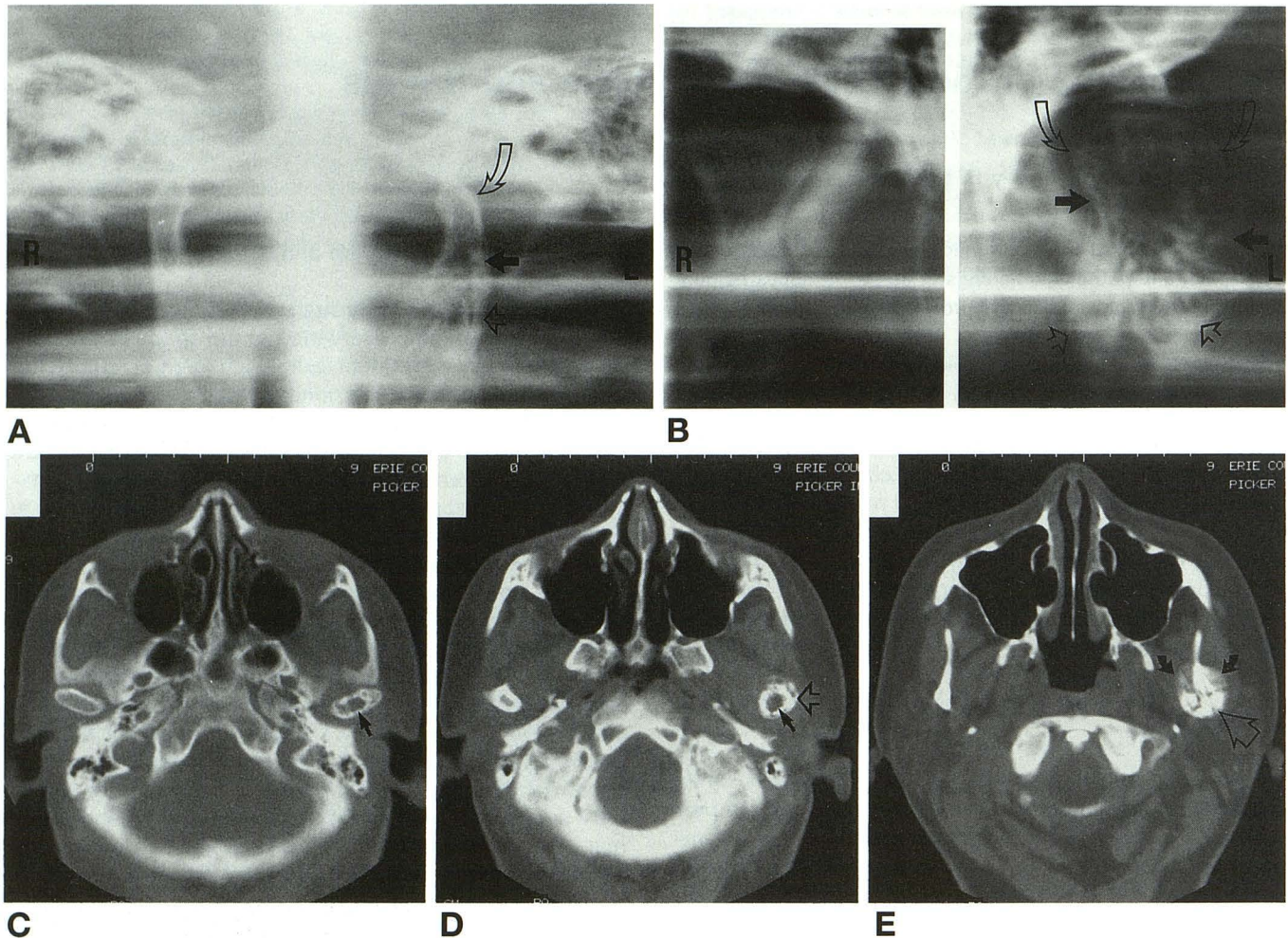


Fig 1. A, Parasagittal and B, coronal images of the temporomandibular joints obtained on a Zonarc unit demonstrate a "striate" or "honeycomb" appearance to the left condylar head (*open curved arrow*), condylar neck (*arrow*), and proximal ramus (*open arrow*). The lesion is causing expansion of the condylar neck and proximal ramus. Views of the normal right side (R) are included in each figure for comparison.

Contrast-enhanced, axial CT sections through C, the condylar head, D, the condylar neck, and E, the proximal ramus. Section through condylar head and neck demonstrates a prominent central radiolucent area (*arrow*). A generalized expansion of the condylar neck (*open arrow, B*) and proximal ramus (*large arrow, E*) is also demonstrated. There is evidence of new bone formation on the lateral and medial aspect of the ramus (*open arrow, E*) with areas of incomplete mineralization (*small curved arrow*).

in the frontal and parietal bones, and present radiographically as well-circumscribed radiolucent lesions with a "honeycombed," "sun ray," or "spoke wheel" appearance. In the facial bones, intraosseous hemangiomas, though rare, have been reported in the zygoma (3), nasal bones (4), maxilla (5–8), and mandible (5, 6, 9–12) with the mandible appearing to be the most common site. Although the true incidence of intraosseous hemangiomas involving the jaws is unknown, Batsakis noted there are only 60 reported cases involving the jaws, with two thirds of these occurring in the mandible (2, 7). Mandibular hemangiomas occur nearly always in the ramus and body. In the mandible, intraosseous hemangiomas are not as well defined as those occurring in calvarium; however, they invariably present as radiolucent lesions, which may have a unicystic, multicystic, "soap bubbly," "honeycomb," or "trabeculated" appearance (2, 6–8, 10). The differential

diagnosis for this radiographic appearance must also include: ameloblastoma, odontogenic keratocyst, central giant cell granulomata, giant cell tumor of hyperparathyroidism, aneurysmal bone cyst, and metastatic lesions (7). Tangential views may show some spicules radiating from the cortex, suggestive of an osteogenic sarcoma (13). Our review of the literature found one other case of an intraosseous hemangioma involving the temporomandibular joint region (1). Diagnostic imaging of this case consisted exclusively of orthopantomograms, which demonstrated a well-circumscribed, nonspecific, radiolucent lesion on the anterior aspect of the condyle; these nonspecific findings are in marked contrast to the plain film findings in the present case suggestive of an intraosseous hemangioma.

Stassi et al described the CT findings of an intraosseous hemangioma occurring in the maxilla (8). These consisted

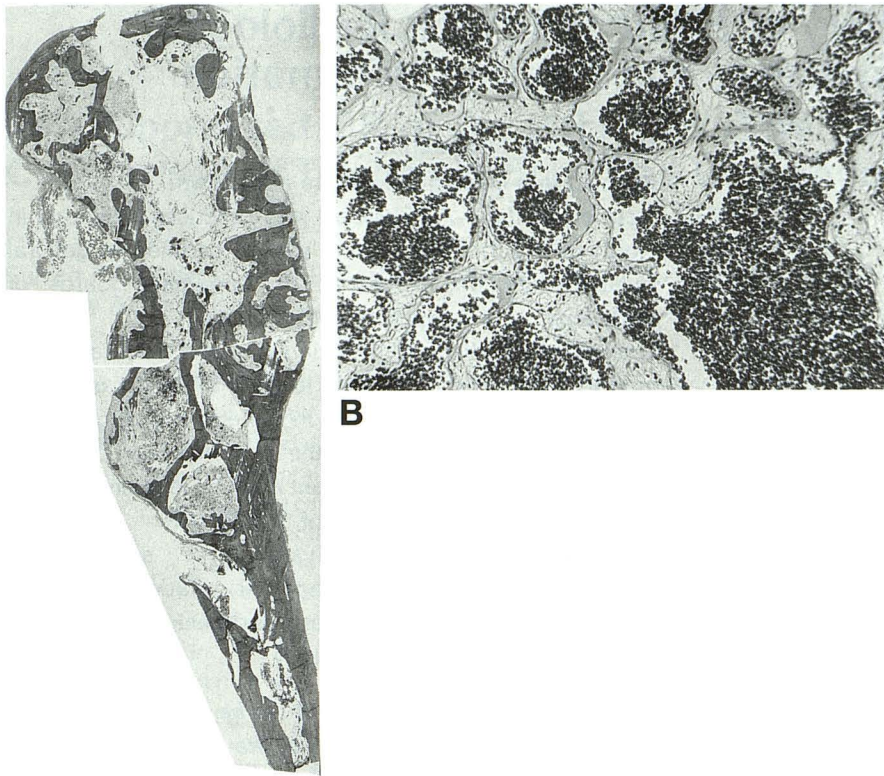


Fig 2. A, Composite photomicrograph of sections at two different levels of the resected left mandibular ramus and condylar showing bulbous dilation and cortical thinning of the condyle and a hemorrhagic vascular process involving the medullary cavity (magnification $\times 10$).

B, Photomicrograph of the condylar cavernous hemangioma showing conglomerates of dilated, thin-walled, blood-filled vascular channels in a loose connective tissue stroma (magnification $\times 200$).

A

primarily of a soft-tissue mass eroding the maxilla and extending into the soft tissues of the adjacent cheek and infratemporal fossa. The large soft tissue mass associated with this maxillary hemangioma are in marked contrast to the predominantly osseous lesion noted in the present case.

Although the exact etiologic factors underlying the development of intraosseous hemangiomas in the facial bones are unknown, they are believed to result from mesenchymal rests which undergo endothelial differentiation and proliferation into blood vessels (2, 5). Clinically, hemangiomas of the mandible often present as slow-growing expansile lesions. They occur twice as often in female patients (2, 7). Massive, potentially life-threatening hemorrhage can occur when dental extractions or biopsies violate the lesion (10, 11, 13). Preoperative angiography will demonstrate both the afferent and efferent vessels, and may permit the embolization of major feeding vessels thereby significantly reducing bleeding at the time of surgery (13).

The intraosseous hemangioma represents an uncommon lesion of the maxillofacial region. However, it should be included in the differential diagnosis of expansile radiolucent lesions, especially if a striate appearance is noted.

References

1. Uotila E, Westerholm N. Hemangioma of the temporomandibular joint. *Odontol Tidskr* 1966;74:202-206
2. Batsakis JG. Vascular tumors of the facial bones. *Tumors of the Head and Neck*. Baltimore: Williams & Wilkins, 1979:390-395
3. Jeter TS, Hackney FL, Aufdemorte TB. Cavernous hemangioma of the zygoma: report of a case. *J Oral Maxillofac Surg* 1990;48:512-515
4. Bridger MW. Haemangioma of the nasal bones. *J Laryngol Otol* 1976;90(2):191-200
5. Gamez-Araujo JJ, Toth BB, Luna MA. Central hemangioma of the mandible and maxilla: review of a vascular lesion. *Oral Surg* 1974;37:230-237
6. Lund BA, Dahlin DC. Haemangioma of the mandible and maxilla. *Oral Surg* 1962;22:234-242
7. Matteson SR. Benign tumors of the jaws. In: Goaz PW, White SC, eds. *Oral Radiology Principles and Interpretation*. St Louis: CV Mosby Co, 1987:514-565
8. Stassi J, Rao VM, Lowry L. Hemangioma of bone arising in the maxilla. *Skeletal Radiol* 1982;12:187-191
9. Cran JA. Cavernous haemangioma in the mandible. *Br J Oral Maxillofac Surg* 1990;3:32-35
10. Martis H, Karakasis D. Central hemangioma of the mandible: report of a case. *Oral Surg* 1973;31:613-616
11. Shira RB, Guernsey LH. Central hemangioma of the mandible. *Oral Surg* 1965;23:636-642
12. Wilde JN, Tur JJ, Call DE. Hemangioma of the mandible: report of a case. *Oral Surg* 1966;24:549-542
13. Guibert-Tranier F, Piton J, Riche MC, Merland JJ, Caile JM. Vascular malformations of the mandible (intraosseous haemangiomas). *Eur J Radiol* 1982;2:257-272
14. Gelfand G, Dixox RA, Gans BJ. Central cavernous hemangioma of the mandible. *J Oral Surg* 1975;33:448-453