

Are your **MRI contrast agents** cost-effective?

Learn more about generic **Gadolinium-Based Contrast Agents**.



FRESENIUS
KABI

caring for life

AJNR

CT of postmeningitic deafness: observations and predictive value for cochlear implants in children.

M H Johnson, M S Hasenstab, M A Seicshnaydre and G H Williams

AJNR Am J Neuroradiol 1995, 16 (1) 103-109

<http://www.ajnr.org/content/16/1/103>

This information is current as of April 24, 2024.

CT of Postmeningitic Deafness: Observations and Predictive Value for Cochlear Implants in Children

Michele H. Johnson, M. Suzanne Hasenstab, Michael A. Seicshnaydre, and George H. Williams

PURPOSE: To demonstrate CT abnormalities encountered in children with postmeningitic deafness and to assess the value of CT in the prediction of cochlear implantation difficulties. **METHODS:** Thirteen children with postmeningitic deafness were evaluated with high-resolution, thin-section CT. CT findings were correlated with surgical anatomy at the time of cochlear implantation, with particular regard to the prediction of implant success. **RESULTS:** CT findings included normal scans (3 of 13, 23.1%), cochlear stenosis (5 of 13, 37.7%), cochlear fibroossific change (1 of 13, 7.7%), cochlear ossification (4 of 13, 30.8%), and osseous hypertrophy at the round window niche (4 of 13, 30.8%). Nine of 10 patients with abnormal findings had incomplete or difficult implantations (90%); 7 (88.8%) of these 9 received limited electrode insertions. **CONCLUSION:** Attention to subtle otological abnormalities on thin-section CT is helpful in the prediction of early success or failure of implantation in children with postmeningitic deafness. Those with CT abnormalities had a 90% risk of incomplete or difficult insertions with a 70% chance of limited electrode insertion.

Index terms: Meningitis; Hearing; Computed tomography, in treatment planning; Ear, prostheses; Pediatric neuroradiology

AJNR Am J Neuroradiol 16:103-109, January 1995

Over the last several years, cochlear-implant technology has become available as a treatment for profound deafness in both adults and children (1). To date, approximately 1200 children worldwide have undergone implantation with the Nucleus cochlear implant device (*Communique*, Cochlear Corp, winter 1991). Seventy percent of these patients (815 patients) are in the United States. Children receive implants for deafness from a variety of causes, including congenital lesions, bacterial meningitis, and cytomegalovirus infection (2-4). Patients with deafness of undetermined cause have also been given implants. At our medical center we have given implants to a series

of 42 patients from all of these etiologic groups.

Prospective and retrospective studies have reported that significant hearing loss develops in 7% to 29% of patients with meningitis (5). Of the total worldwide pediatric population receiving implants, approximately 44% have deafness secondary to meningitis (*Communique*, Cochlear Corp, winter 1991). Our 13 patients who had meningitis, as a group, have had more problems overall than have our patients receiving implants with deafness from other causes. Many had problems with the surgical implantation itself because of cochlear obstruction (6, 7). In addition, in some patients there are difficulties during device programming, particularly after incomplete implantation. Many children with postmeningitic deafness also have cognitive or learning disabilities, which may contribute to postimplantation difficulties (5, 6).

We have evaluated the spectrum of computed tomographic (CT) findings in our patients with postmeningitic deafness and compared these with the surgical anatomy at the time of implantation. Our purpose was to assess ana-

Received July 8, 1992; accepted after revision May 27, 1994.


From the Departments of Radiology (M.H.J.) and Otorhinolaryngology (M.S.H., M.A.S., G.H.W.), Medical College of Virginia, Virginia Commonwealth University, Richmond.

Address reprint requests to Michele H. Johnson, MD, Department of Radiology, Medical College of Virginia, Virginia Commonwealth University, Box 980615 MCV Station, Richmond, VA 23298.

AJNR 16:103-109, Jan 1995 0195-6108/95/1601-0103
© American Society of Neuroradiology

Fig 1. The Nucleus 22-channel cochlear implant device. Note the location of the 22-electrode array (arrows).

Fig 2. Final surgical placement of the device. *RW* indicates round window; *ST*, scala tympani; *FR*, facial recess; and *BTC*, basal turn of the cochlea.



tomic disease using high-resolution CT and attempt to identify the potentially difficult patient receiving a cochlear implant.

Materials and Methods

Thirteen patients with postmeningitic deafness were evaluated with high-resolution, thin-section CT before implantation of the Nucleus cochlear implant device (Cochlear Corp, East Englewood, Colo).

Imaging

Imaging was done in both axial and coronal planes with 1.5- to 2.0-mm section thicknesses and a bone algorithm reconstruction technique. One scan from an outside imaging facility included only axial sections with a 3-mm section thickness. All CT scans were assessed for congenital anomalies, cochlear stenosis, cochlear ossification, and osseous hypertrophy of the round window niche (8–13). The CT scans were interpreted by a single neuro-radiologist (M.H.J.) without knowledge of the surgical findings. Structural abnormalities on CT were subsequently compared with those found at surgery.

Surgical Selection

All patients met the criteria for implantation at our medical center, which are: (a) profound bilateral sensorineural hearing loss; (b) age of 2 to 17 years; (c) normal general development; (d) parental and school support systems; and (e) no medical contraindications to surgery and implantation.

Implantation Technique

The surgical approach to cochlear implantation consists of a limited mastoidectomy. This is followed by opening of the facial recess and entrance into the round window with placement of the electrode array into the scala tympani via the basal turn of the cochlea (Figs 1 and 2) (8). The presence of significant obstruction or narrowing of the

basal turn of the cochlea may inhibit the insertion of the full 22-electrode array of the Nucleus device (1, 3, 6, 7, 12, 14). After implantation, the range of hearing frequencies is programmed over the number of electrodes successfully inserted. Insertion of 19 or more electrodes is considered a good insertion, but even a limited number of inserted electrodes generally results in improved hearing (1, 6, 7).

Results

Meningitic labyrinthitis ossificans (labyrinthine ossification) is a postinflammatory process characterized by fibrous tissue proliferation and ossification within the inner ear (15–17). For the purposes of our analysis, we chose to divide our findings into fibroossific change and cochlear ossification, which are the early and late findings of meningogenic labyrinthitis ossificans, and into ossification of the round window niche and cochlear stenosis, which seem to be more limited manifestations within the spectrum of labyrinthitis ossificans.

The results of our CT analyses and the success of cochlear implantation in our thirteen children with postmeningitic deafness are detailed in Table 1. Careful review of CT scans resulted in an interpretation of 3 normal and 10 abnormal examinations. Several patients had more than 1 abnormal finding on CT evaluation. The distribution of the CT findings are detailed in Table 2. The CT scans were analyzed for the following conditions.

Normal Anatomy

A normal CT scan interpretation indicated normal configuration of the cochlea without narrowing, fibrosis, or bone overgrowth (Fig 3). A normal CT scan did not ensure easy or complete insertion in our patient group (Table 1).

TABLE 1: Results of CT analysis and cochlear implantation in 13 patients with postmeningitic deafness

Patient	Age at Meningitis Onset	Age at Implantation	Findings							Postimplant Difficulties
			Normal	Cochlear Stenosis	Cochlear Ossification	Fibroossific Changes	Round Window Ossification	Complete Implantation (22 Electrodes)	Incomplete or Difficult Implantation	
W.C.	9 mo	2 y 6 mo		X	X				6 electrodes	Migrated electrode array, reimplant
D.M.	3 wk	12 y 9 mo				X			21 electrodes	
E.S.	19 mo	2 y 3 mo		X						
F.R.*	14 mo	3 y 3 mo	X						4-mm drilling	
J.L.	3 y 4 mo	6 y 3 mo		X					22 electrodes	
J.D.	26 mo	12 y 3 mo		X					10 electrodes	
J.H.*	3 y 3 mo	8 y 4 mo				X			6 electrodes	High stimulus levels
M.L.*	6 mo	6 y 2 mo	X†						9 electrodes	
J.S.	5 y 2 mo	6 y 4 mo			X				7 electrodes	High stimulus levels
R.C.*	4 mo	8 y 4 mo			X				7 electrodes	High stimulus levels
C.W.	5 mo	9 y 8 mo		X					8 electrodes	Neural adaptation
S.C.	3 y 3 mo	5 y 10 mo	X						19 electrodes	Possible migration
T.T.	22 mo	3 y 0 mo			X				7 electrodes	Possible migration

Note.—High stimulus levels are required in cases of limited electrode insertion or decreased neural population. Neural adaptation means the device can be worn only for short periods because of saturation. X indicates CT finding.

* Learning disability.

† Outside CT scan, 3-mm images, suboptimal.

TABLE 2: CT findings in patients with postmeningitic diseases

CT Findings	Number of Patients	Percentage
Normal examination	3	23.1
Cochlear stenosis	5	37.7
Fibroossific change	1	7.7
Cochlear ossification	4	30.8
Osseous hypertrophy at the round window niche	4	30.8

Cochlear Stenosis

Narrowing of the basal turn of the cochlea was the most commonly observed finding in our series of patients (5 of 13 patients) and may represent the most limited form of labyrinthine ossification (Fig 4). Narrowing may impede or preclude complete insertion of the electrode array into the scala tympani.

Cochlear Fibroossific Change (Early Labyrinthine Ossification)

The fibrotic cochlea demonstrated hazy increased density within the basal turn of the cochlea on CT (1 of 13 patients) (Fig 5). The pathologic spectrum of fibroossific change ranges from pure fibrosis to fibrosis with significant osseous deposits. This is the most common finding at surgery, and is most frequently misinterpreted as normal on CT (7).

Cochlear Ossification (Late Labyrinthine Ossification)

Discrete focal cochlear ossifications were demonstrated in 4 of 13 patients (Fig 6). This probably represents an extension of the pathologic spectrum of fibroossific change. In the presence of such ossification, extensive drilling into the scala tympani may be required to achieve even limited electrode insertion.

Osseous Hypertrophy of the Round Window Niche

This finding was identified in 4 of 13 patients (Fig 7). Ossification of the round window niche requires the surgeon to drill off the obstructing bone before entering the scala tympani. This condition may not cause significant difficulty with insertion of the electrode array if it is not associated with other cochlear region disease. This focal disease may also represent a more isolated (limited) form of labyrinthine ossification.

Fig 3. A, Axial and B, coronal high-resolution CT scans (1.5-mm section thickness) of a normal temporal bone illustrating the round window niche (RW), the scala tympani (ST), and the most proximal basal turn of the cochlea (BTC).



Implantation and Postimplantation Difficulties

Incomplete and difficult insertions were grouped together for analysis and comparison with preoperative CT interpretations (Tables 1 and 3). Incomplete implantations were defined as those in which, despite drilling at the round window niche or the basal turn of the cochlea, the entire 22-electrode array of the Nucleus device could not be inserted successfully. Difficult insertions were defined as those in which significant drilling at the round window or within the basal turn of the cochlea was required to insert the complete electrode array. Eleven implantations, among our 13 patients, were in the incomplete or difficult group.

Postimplantation difficulties encountered included migration of the implanted electrode array in one child, requiring reimplantation. A second patient is currently undergoing evaluation for possible reimplantation. Problems with device programming were also encountered. High stimulus levels were required for adequate device programming, particularly in patients with limited (less than 10) electrode insertion (4 of 13). In one patient (S.C.) with a 19-electrode insertion, high stimulus levels were re-

quired, suggesting a decreased neuronal population within the cochlear nerve. One patient's (C.W.) hearing improved only when the device was worn for short periods, because of saturation of the available neural tissue. In total, 7 of the 11 incomplete- or difficult-insertion patients had significant postimplantation problems.

Discussion


Ossification of the labyrinth (labyrinthitis ossificans or labyrinthine ossification) is a common histologic end point of severe inflammatory disease of the ear and is often associated with profound deafness and loss of vestibular function (15-17). The causes of labyrinthine ossification may be classified as tympanogenic (chronic otitis, cholesteatoma, or postsurgical), meningogenic (bacterial or viral), or hematogenic (mumps or other hematogenous infections) (16, 17).

In a patient with meningitis, infection spreads from the meninges to the inner ear via the cochlear aqueduct and the internal auditory canal. In patients who have had meningitis and are deaf, the identification of

Fig 4. Axial CT images through the right ear, obtained at 1.5-mm intervals.

A, The scan through the inferior aspect of the cochlea demonstrates tapered narrowing of the basal turn (*arrowheads*).

B, More superiorly, a second area of focal stenosis is visible (*arrowheads*).






Fig 5. Cochlear fibroossific change is demonstrated bilaterally on these 2-mm-thick axial CT images. Hazy increased density is present within the basal turn of the cochlea (*arrowheads*). These changes are most prominent on the right (*A*). Insertion was limited to only six electrodes because of the dense fibrosis encountered at surgery.

new bone formation near the origin of the cochlear aqueduct (in the basilar turn of the cochlea) and near the internal auditory canal (in the apical and middle turns of the cochlea) are evidence to support this mechanism.

The presence of bacteria within the perilymphatic spaces incites an acute inflammatory response, characterized by leukocyte infiltration and fibroblast proliferation (initial acute stage). The fibroblasts are derived from undifferentiated mesenchymal cells located in the endosteum, modiolus, and basilar membrane. Fibroblast proliferation leads to fibrosis within the labyrinth (fibrotic stage). Some of these mesenchymal cells and fibroblasts differentiate into osteoblasts, which form ossific deposits within the labyrinth (ossification stage).

Green et al studied histologic sections of 24 temporal bones with labyrinthine ossificans (15). In each case, fibrous tissue and new bone were present within the fluid containing spaces of the inner ear after an inflammatory insult (15). Eleven of these patients had meningogenic labyrinthitis. The most common location for fibrosis and new bone deposition in these cochlea was within the basilar turn of the scala tympani. Ossification in this series was found to extend further into the cochlea in patients with meningogenic labyrinthitis ossificans than in

those patients with other causative factors. Ossification near the round window membrane was found in all cases of tympanogenic labyrinthitis but was not specifically mentioned in the meningogenic group (15). Swartz et al reported a series of cases of labyrinthine ossification resulting from a variety of causes. Two patients who had previous bacterial meningitis demonstrated marked labyrinthine ossification (16). Becker et al presented a series of 20 children who received cochlear implants as treatment for profound postmeningitic deafness and who were assessed with polytomography after surgery. Fourteen of these patients had round window ossification at surgery. These authors described cochlear and round window ossification as mild forms of labyrinthine ossification (15). Eisenberg et al reported a series of pediatric patients who had meningitis, 80% of whom required drilling of round window or scala tympani ossification at the time of cochlear implantation (18).

The number of CT scans with no abnormal findings in our postmeningitic deafness population was small (3 of 13, 23.1%). On axial CT images, volume averaging at the top or bottom of the basal turn of the cochlea occasionally suggested cochlear stenosis. Analysis of coronal images may reduce the incidence of this




Fig 6. Axial images of the *A*, right and *B*, left temporal bones, obtained at 1.5-mm intervals. There is narrowing of the basal turn of the cochlea on the right with several focal ossifications identified within its lumen (*A*, *arrowheads*). On the left, less prominent cochlear stenosis and focal ossifications are demonstrated (*B*, *arrowheads*).



Fig 7. CT in the axial plane of the left temporal bones demonstrates a large bone overgrowth overlying the round window niche (*arrow*).

interpretation error (Fig 8). False-negative interpretation may result from failure to diagnose the earliest manifestations of labyrinthine ossification—fibroossific change—within the basal turn. This diagnosis may be particularly difficult to make when there is little ossification within the fibrous matrix. In our series, only 1 patient with CT findings interpreted as normal received a complete implantation; however, 1 additional patient received more than 19 electrodes (considered a good insertion). The third patient with normal CT findings was scanned outside our institution. The examination was performed at 3-mm intervals, which may have contributed to a suboptimal assessment in that case. Although our series of 13 patients is small, a normal, high-resolution, thin-section CT scan indicated a high probability of a good insertion.

In several patients in our series a combination of pathologic findings in the cochlear region contributed to the management of possible incomplete or difficult insertions. The right ear is generally selected for implantation. One patient had bilateral pathologic CT findings that were worse in the right ear, so the left ear (with the lesser disease) was chosen (by the surgeon) for implantation (Fig 9).

Fig 8. A, Midcochlea. Volume averaging of the basal turn suggests cochlear stenosis (*arrowheads*).

B, The direct coronal image demonstrates a normal basal turn.




TABLE 3: Relation between CT interpretation and quality of implantation

	Normal CT	Abnormal CT
Complete implantation	1	1
Incomplete or difficult implantation	2	8

Note.—Two of three were good insertions with more than 19 electrodes.

Of the children with abnormal CT findings in our series, 9 of 10 experienced incomplete or difficult insertions, 7 of 10 patients receiving 10 electrodes or less (70%). An abnormal CT scan was predictive of a 90% probability of a difficult or incomplete insertion.

Conclusion

A high incidence of cochlear region disease was identified by high-resolution CT scans of the temporal bone in a series of pediatric patients with postmeningitic deafness. As demonstrated in our series and others, the changes of meningogenic labyrinthine ossification range from mild fibroossific changes within the labyrinth at the earliest, to profound, near-complete ossification within the cochlea. The ossification of the round window and the cochlear stenosis described in our series seem to be more limited manifestations of labyrinthine ossifications with deposits at the round window or narrowing the cochlea, but without the focal central ossifications demonstrated in more advanced cases. Comparison of the CT analysis with the surgical and postoperative experience suggests that preoperative CT can aid clinicians and families in the anticipation of potential difficulties with cochlear implantation. Preoperative CT review


Fig 9. Axial CT of the right (A) and left (B) temporal bones demonstrate cochlear stenoses (A, arrows; B, arrowhead). In this patient, the observation of more extensive cochlear stenosis on the right led to the selection of the left ear for cochlear implantation. Note the parallel densities representing the myringotomy tube on the right (white arrow).



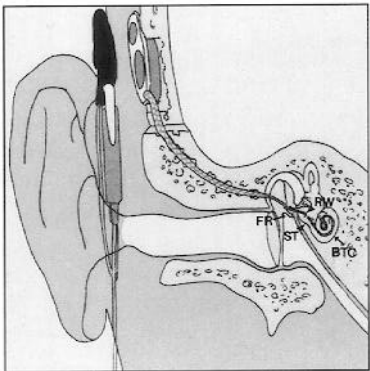
allows the surgeon to anticipate difficulties with cochlear implantation and to plan the surgery accordingly.

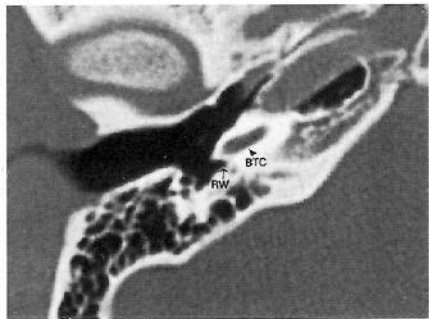
References

- Gantz BJ, McCabe BF, Tyler RS. Use of multichannel cochlear implants in obstructed and obliterated cochleas. *Otolaryngol Head Neck Surg* 1988;98:72-81
- Brookhouser PE, Worthington DW, Kelly WJ. Severe versus profound sensorineural hearing loss in children: implications for cochlear implantation. *Laryngoscope* 1990;100:349-356
- Luxford WM, House WF. Cochlear implants in children: medical and surgical considerations. *Ear Hear* 1985;6:20S-23S
- Silverstein H, Smouha E, Morgan N. Multichannel cochlear implantation in a patient with bilateral Mondini deformities. *Am J Otol* 1988;9:451-455
- Kaplan SL, Catlin FI, Weaver T, Feigin RD. Onset of hearing loss in children with bacterial meningitis. *Pediatrics* 1984;73:575-578
- Novak MA, Fifer RC, Barkmeier JC, Firszt JB. Labyrinthine ossification after meningitis: its implications for cochlear. *Otolaryngol Head Neck Surg* 1990;103:351-356
- Jackler RK, Luxford WM, Schindler RA, McKerrow WS. Cochlear implant candidates: assessment with CT and MR imaging. *Radiology* 1987;164:53-57
- Harnsberger HR, Dart DJ, Parkin JL, Smoker WRK, Osborn AG. Cochlear implant candidates: assessment with CT and MR imaging. *Radiology* 1987;164:53-57
- Phelps PD, Annis JAD, Robinson PJ. Imaging for cochlear implants. *Br J Radiol* 1990;63:512-516
- Seicshnaydre MA, Johnson M, Hasenstab MS, Williams GH. Cochlear implants in children: the reliability of preoperative computed tomography. *Otolaryngol Head Neck Surg* 1992;107:410-417
- Yune HY, Miyamoto RT, Yune ME. Medical imaging in cochlear implantation candidates. *Am J Otol* 1991;12S:11-17
- Wiet RJ, Pyle GM, O'Connor CA, Russell E, Schramm DR. Computed tomography: how accurate a predictor for cochlear implantation? *Laryngoscope* 1990;100:687-692
- Mueller DP, Dolan KD, Gantz BJ. Temporal bone computed tomography in the preoperative evaluation for cochlear implantation. *Ann Otol Rhinol Laryngol* 1989;98:346-349
- Balkany T, Dreisbach J. Workshop: surgical anatomy and radiographic imaging of cochlear implant surgery. *Am J Otol* 1987;8:195-200
- Swartz JD, Mandell DM, Faerber EN, et al. Labyrinthine ossification: etiologies and CT findings. *Radiology* 1985;157:395-398
- Becker TS, Eisenberg LS, Luxford WM, and House WF. Labyrinthine ossification secondary to childhood bacterial meningitis: implications for cochlear implant surgery. *AJNR Am J Neuroradiol* 1984;5:739-741
- Green Jr JD, Marion MS, Hinojosa R. Labyrinthitis ossificans: histopathologic consideration for cochlear implantation. *Otolaryngol Head Neck Surg* 1991;104:320-326
- Eisenberg LS, Luxford WM, Becker TS, House WF. Electrical stimulation of the auditory system in children deafened by meningitis. *Otolaryngol Head Neck Surg* 1984;92:700-705

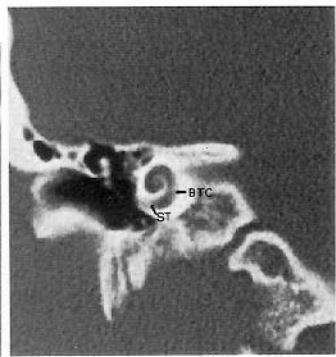


1

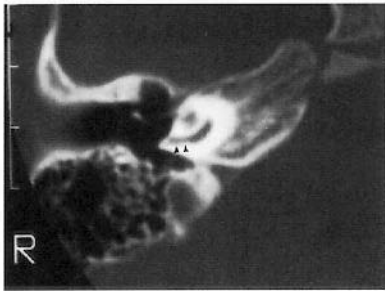




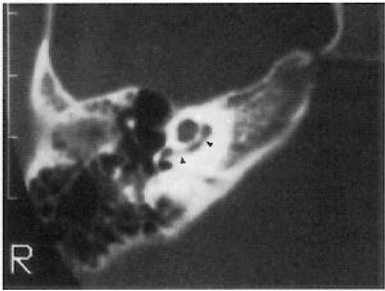
A



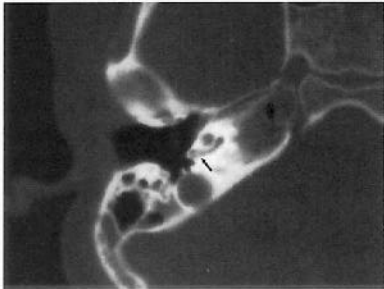
B



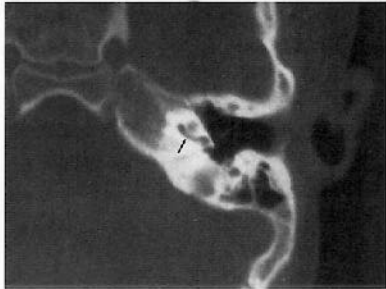
A



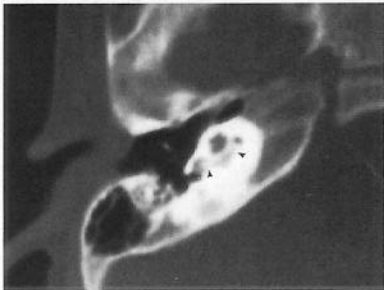
B



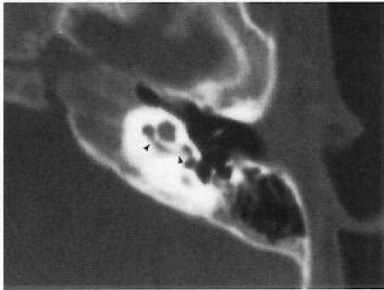
A



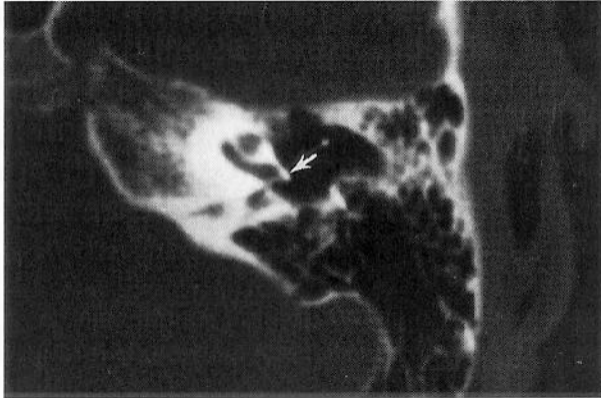B

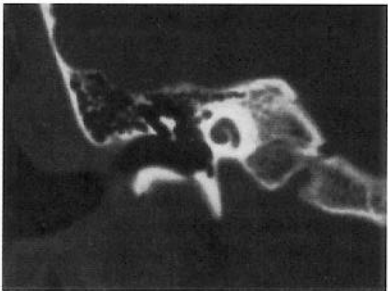
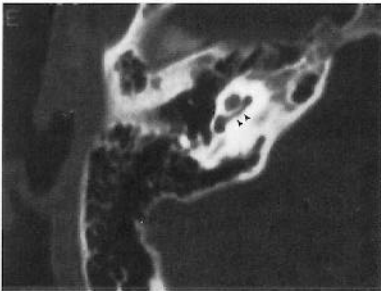


A



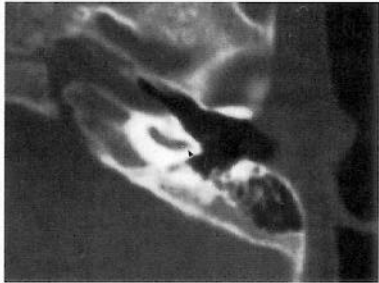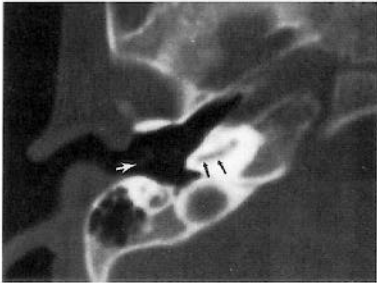
B





A

B



A

B