

Are your MRI contrast agents cost-effective?

Learn more about generic Gadolinium-Based Contrast Agents.



**FRESENIUS
KABI**

caring for life

AJNR

Relation between CT axial cross-sectional area of the oropharynx and obstructive sleep apnea syndrome in adults.

E Avrahami and M Englender

AJNR Am J Neuroradiol 1995, 16 (1) 135-140

<http://www.ajnr.org/content/16/1/135>

This information is current as
of April 10, 2024.

Relation between CT Axial Cross-sectional Area of the Oropharynx and Obstructive Sleep Apnea Syndrome in Adults

Elieser Avrahami and Moshe Englender

PURPOSE: To look for correlation between obstructive sleep apnea syndrome (OSAS) and axial cross-sectional area of the narrowed oropharyngeal lumen. **METHODS:** Thirty-six men with OSAS and 10 control subjects underwent polysomnography with registration of oxygen saturation and number of sleep apnea episodes and their duration. Nine of them underwent uvulopalatopharyngoplasty and repeated polysomnography. Each polysomnography was followed by high-resolution CT scan with reconstructions in sagittal and coronal planes. Measurements of the axial cross-sectional area of the oropharyngeal lumen were taken at the level of the narrowing. **RESULTS:** Twenty-seven patients with severe OSAS (high number and prolonged episodes of OSAS and 22% or greater decrease in oxygen saturation) had a narrowed oropharyngeal cross-sectional area less than 50 mm² wide. The control subjects and 6 patients who had uvulopalatopharyngoplasty without OSAS had a minimal pharyngeal cross-sectional area of 110 mm². Eight patients with moderate OSAS and 3 patients who had uvulopalatopharyngoplasty and diagnoses of OSAS had intermediate values of the narrowest pharyngeal level—between 60 mm² and 100 mm². **CONCLUSION:** The measurement of the axial cross-sectional area of the pharyngeal lumen can play an important role in evaluation of OSAS and indications for surgery.

Index terms: Pharynx, computed tomography; Pharynx, abnormalities and anomalies; Sleep studies; Neck, surgery

AJNR Am J Neuroradiol 16:135–140, January 1995

Patients with obstructive sleep apnea syndrome (OSAS) have narrowing in the oropharynx, usually at the level of the uvula–soft palate complex or the base of the tongue (1, 2). Less frequently, tonsillar hypertrophy, Pickwickian syndrome, pharyngeal tumors, macrognathia, micrognathia, and central nervous system disturbances may cause OSAS (3–9).

Several clinical symptoms such as somnolence, snoring, apnea episodes during sleep, tiredness, daytime hypersomnolence, headache, nocturnal enuresis, impotence, decreased intelligence, hallucinations, and cardiovascular disturbances are present in OSAS. Different modalities, such as polysomnogra-

phy, fiberoptic endoscopy, fluoroscopy, and computed tomography (CT), are used in the diagnosis and evaluation of OSAS (10–16). Diagnosis of OSAS may be difficult in the presence of so many diagnostic procedures. This problem can be even more complicated in choosing the best surgical procedure in each case.

Uvulopalatopharyngoplasty is the procedure of choice for patients with uvulopalatinal narrowing. It is the procedure used to treat patients with snoring and OSAS. It consists mainly of the surgical removal of the tonsils and a part of the soft palate with the aim to enlarge the pharyngeal airway. Tonsillar hypertrophy requires tonsillectomy. Patients with narrowing at the level of the base of the tongue can be referred for maxillomandibular advancement surgery (17–23). Conversely, only patients with severe OSAS are referred for surgery.

The measurements of the axial oropharyngeal cross-sectional area may be important.

Received November 2, 1993; accepted after revision March 28, 1994.

From the Departments of Radiology (E.A.) and Otolaryngology (M.E.), Edith Wolfson Medical Center, Holon, and Tel Aviv University, Faculty of Medicine, Sackler School of Medicine, Tel Aviv University, Israel.

Address reprint requests to Elieser Avrahami, MD, Radiology Department, Edith Wolfson Medical Center, Holon 58100, Israel.

AJNR 16:135–140, Jan 1995 0195-6108/95/1601-0135
© American Society of Neuroradiology

Materials and Methods

Thirty-six men, from 19 to 61 years old, were diagnosed as having OSAS. The diagnosis was established by polysomnography, based on apneic episodes during sleep with a duration of 10 seconds or more. In every patient, the polysomnography was followed by CT examination.

Nine of the patients with severe OSAS underwent laser-assisted uvulopalatopharyngoplasty, repeated polysomnography, and CT scan. Two other patients with severe OSAS underwent tonsillectomy. Ten adult male volunteers without OSAS (including the authors) underwent polysomnography and CT. Altogether 55 polysomnographies and 55 CT scans were performed, as follows (each polysomnography was followed by a CT scan):

Number of patients with OSAS	36
Control subjects	10
Total patients	46
Repeated polysomnographies in 9 patients after uvulopalatopharyngoplasty	9
Total polysomnographies	55

Attention was focused on three polysomnography parameters: number of nocturnal apneic episodes and their duration, and the maximal drop in oxygen saturation. For better illustration of the significance of the findings, the OSAS factor was created from the ratio of the average number of apneic episodes per hour multiplied by their average duration per hour. For example, 150 apneic episodes in 6 hours of polysomnography equals 25 apneic episodes per hour; 25×40 seconds average duration of each episode equals an OSAS index of 1000.

The measurements of the oxygen saturation were performed with the Pulsoxymeter OHMEDA BIOX 3740. The percentage in the drop of the maximal to the minimal oxygen saturation was registered. For example, if the maximal oxygen saturation measured in a patient is 98 and the minimal 76, the drop is 22%.

High-resolution CT examinations of the pharynx were performed using an Elscint 2400 Elite machine. All scans were performed with patient in supine position to prevent overextension of the neck, which may narrow the pharyngeal airway. The patients were advised to be quiet and not to breathe or swallow during the scans. The gantry was tilted parallel to the intervertebral spaces C1-2 and C2-3 to standardize the examinations and to avoid cases with invalid calculations of the cross-sectional areas of the pharynx if the angles of each section were different. In all CT scans, the axial sections ranged from 10 mm above C-1 to intervertebral space C4-5. Consecutive axial sections were obtained with 1,2-mm width and 1-mm increments, followed by sagittal and coronal reconstruction. The computer window of the axial sections was set to 500 HU width and baseline 30 HU. The images were photographed by multiimager Formax Elscint EC4 with a film divided into 16 exposures. The computer zoom was set to 3.05 until 1 cm of the computer scale became equal to 1 real centimeter in the photographed image. Then, using a transparent grid with square millimeters, the axial cross-sectional area of the oropharyngeal lumen was measured on the




Fig 1. Overlay procedure of the measurements of the axial cross-sectional area of the oropharynx.

section showing the maximal luminal narrowing (Fig 1). The use of the transparent millimeter grid was necessary because the computer grids, which are marked in centimeters, are insufficient for accurate measurements. In all of the patients, measurements of a minimum of 10 sections taken at the uvulopalatine level and at the level of the base of the tongue were performed. Only the lowest levels were used for the study. Statistical analysis of the measurements was performed using *t* test.

Nine patients underwent uvulopalatopharyngoplasty using CO₂ laser SHAR PLAN 1030.

Results

Twenty-eight patients (group 1, Table 1) were diagnosed by polysomnography as having severe OSAS. The diagnosis was based on 42 to 63 incidents of sleep apnea per hour (average, 49). The duration of each apnea episode ranged from 32 to 190 seconds (average OSAS factor, 1718; $P < .025$). The oxygen saturation

TABLE 1: Thirty-six patients with OSAS

	Number of Patients	Uvulopalatinal Narrowing	Narrowing at Level of Base of Tongue	Narrowing Caused by Tonsillar Hypertrophy
Group 1 Severe OSAS	28	14	12	2
Group 2 Moderate OSAS	8	4	4	...
Total	36	18	16	2

TABLE 2: Polysomnography in 36 patients with OSAS

	Number of Patients	Average Drop in Oxygen Saturation	Average Number of Sleep Apnea Episodes/hr	Average Duration of Sleep Apneas, s	Average OSAS Factor
Group 1 Severe OSAS	28	24	53	49	1718
Group 2 Moderate OSAS	8	11	29	23	763

dropped from 20% to 29% (average, 24%; $P < .05$). The minimal oropharyngeal axial cross-sectional area ranged from 14 to 48 mm², except in one patient with a 52-mm² minimal oropharyngeal cross-sectional area (average 37 mm²) (Tables 2–4).

Fourteen patients in group 1 had uvulopalatal narrowing of the oropharynx at level C-2 vertebra (Fig 2). The boundaries of the narrowed oropharyngeal area were as follows: (a) anterior—uvulopalate; (b) posterior—the posterior wall of the oropharynx; and (c) lateral—the pharyngeal wall and the tonsils. Nine pa-

tients underwent laser-assisted uvulopalatopharyngoplasty (Table 1). Repeated polysomnograms showed 6 of them as cured. CT scans demonstrated open oropharynx with minimal measurements at the level of the previous narrowing 115 to 387 mm² (Table 4). The polysomnograms in the remaining 3 patients after uvulopalatopharyngoplasty still showed moderate OSAS. Oxygen saturation was lowered to 8% to 12% (average, 10%). The number of apnea incidences per hour ranged from 25 to 33 (average, 28) with duration from 14 to 35 seconds (average, 24 seconds). The measurements of the minimal axial cross-sectional area of the oropharynx was 68 to 89 mm² (Tables 2–4). Eight patients in group 2 were also diagnosed as having moderate OSAS, but they did not have surgery (Table 1). They had a maximal drop in the oxygen saturation during sleep apnea episodes from 8% to 14% (average, 11%). The sleep apnea episodes ranged from 22 to 39 per hour (average, 29) with a duration of 13 to 38 seconds (average, 23 seconds). The narrowest oropharyngeal axial cross-sectional area ranged from 63 to 95 mm² in all of the patients (Tables 2–4).

Ten control patients had values from 110 to 402 mm² (average, 174) (Tables 1–4) (Fig 3).

CT coronal reconstruction of the pharynx demonstrated well the tonsillar hypertrophy in two patients in group 1 (Fig 4). They under-

TABLE 3: Measurements of the minimal axial cross-sectional area of the pharynx

	Number of Patients (N = 46)	Minimal Axial Cross-sectional Area in the Pharynx, mm ²	Average of the Measurements, mm ²	P
Group 1 Severe OSAS	28	14–52	37	<.05
Group 2 Moderate OSAS	8	63–95	73	*
Control subjects No OSAS	10	110–402	174	†

* $P < .05$ together with 3 patients after uvulopalatopharyngoplasty.

† $P < .05$ together with 6 cured patients after uvulopalatopharyngoplasty.

TABLE 4: Patients after uvulopalatopharyngoplasty

	Number of Patients (N = 9)	Minimal Axial Cross-sectional Area in the Pharynx, mm ²	Average Drop in Oxygen Saturation, %	Average Number of Sleep Apnea Episodes/hr	Average Duration of Sleep Apnea, s	Average OSAS Factor
Cured patients	6	115–387
Patients with moderate OSAS	3	68–89	10	28	24	736


Fig 2. 42-year-old man.

A, Severe OSAS. Axial CT at level of C-2 vertebra. The narrowest oropharyngeal cross-sectional area is less than 50 mm².

B, Sagittal CT reconstruction. Uvulopalatal narrowing (*arrow*).

C, After uvulopalatopharyngoplasty. No OSAS. Axial CT at the narrowest oropharyngeal level. The oropharyngeal cross-sectional area is more than 100 mm².

D, Sagittal CT reconstruction after uvulopalatopharyngoplasty. No narrowing of the pharynx.



went tonsillectomy with excellent clinical improvement.

In the remaining 16 patients (12 in group 1 and 4 in group 2), the smallest cross-sectional area was at the level of the base of the tongue. CT sagittal reconstruction demonstrated narrowing of the oropharynx at level C-3 vertebra and the base of the tongue. In two patients this condition was combined with uvulopalatal narrowing (Fig 5).




Fig 3. A 31-year-old male volunteer. No OSAS. Sagittal CT reconstruction. No narrowing of the pharynx.

Discussion

OSAS is a complex disorder characterized by apneic episodes during sleep. The cessation of breathing can last from as little as 10 seconds to several minutes. During these episodes of sleep apnea physiologic alteration may occur, such as increase in arterial blood pressure, increase in pulmonary arterial pressure, hypoxemia, and respiratory acidosis (5, 14). It is reported that CT can guide the therapeutic considerations.

However, CT scans were reported to be performed with 10-mm-thick sections using older generations of scanners (13, 14). Axial cross-sectional area measurements were not performed.

The progress in CT technology allowed us to obtain high resolution 1,2-mm-thick sections. The setting of computer window and zoom factor ensured high accuracy in measurements.




Fig 4. A 14-year-old boy with severe OSAS. Coronal CT reconstruction. Pharyngeal narrowing caused by tonsillar hypertrophy (*arrow*).




Fig 5. A 31-year-old man with severe OSAS. Sagittal CT reconstruction. Double narrowing of the oropharynx: higher uvulopalatal and lower base of tongue (arrows).

In adult men there is correlation between the minimum axial cross-sectional area of the oropharyngeal lumen in axial plane and three parameters: oxygen saturation and number and duration of apnea episodes. All 28 patients (group 1) with severe OSAS, except 1 patient, had minimal oropharyngeal axial cross-sectional area measurements less than 52 mm². The maximal drop in oxygen saturation during sleep apnea episodes was 20% or greater. The OSAS factor in patients with severe OSAS incorporated the number and duration of the sleep apnea episodes. Its average value was 1718 (statistically significant).

Ten volunteers and six patients who had uvulopalatopharyngoplasty did not have OSAS. Their minimal oropharyngeal axial cross-sectional area measurement was greater than 100 mm².

Eight patients of group 2 and 3 patients who had uvulopalatopharyngoplasty and moderate OSAS had the narrowest oropharyngeal axial cross-sectional area, between 60 mm² and 100 mm². The maximal drop in the oxygen saturation did not exceed 14%. Their average OSAS factor also had intermediate values.

We believe that the measurements of the minimal oropharyngeal axial cross-sectional area by modern CT technique correlates with the oxygen saturation and the number and duration of the sleep apnea episodes and that it can be used as a guide for the evaluation of their severity before and after surgery. Coronal CT

reconstruction demonstrates tonsillar hypertrophy well. Sagittal reconstruction can demonstrate the narrowing at the level of the uvulopalatal complex and at the base of the tongue. The CT reconstruction can be important when there are difficulties in deciding which is the procedure of choice. Uvulopalatopharyngoplasty should be the choice when there is only uvulopalatal narrowing.


Patients with greater narrowing (base of tongue) may be candidates for surgical procedures other than uvulopalatopharyngoplasty. Also, patients with more than one location of pharyngeal narrowing would not be referred for this procedure.

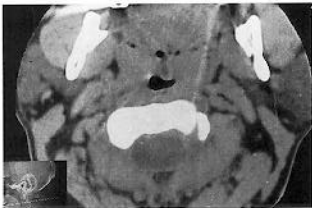
The CT reconstruction is a nonaggressive technique for demonstrating the location of the pharyngeal narrowing.

References

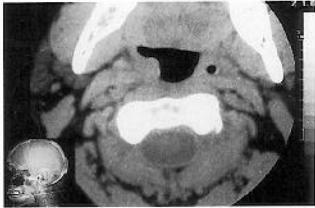1. Bradley TD, Brown LG, Grossman RF, et al. Pharyngeal size in snorers, non-snorers and patients with obstructive sleep apnea. *N Engl J Med* 1986;315:1327-1331
2. Grumley RL, Stein M, Gamsu G, Golden J, Dermon S. Determination of obstructive site in obstructive sleep apnea. *Laryngoscope* 1987;97:301-308
3. Orr WC, Martin RJ. Obstructive sleep apnea associated with tonsillar hypertrophy in adults. *Arch Intern Med* 1981;141:990-992
4. Mangot D, Orr WC, Smith RO. Sleep apnea, hypersomnolence and upper airway obstruction secondary to adenotonsillar enlargement. *Arch Otolaryngol* 1977;103:383-386
5. Guilleminault C, Tikian A, Dement WC. The sleep apnea syndromes. *Annu Rev Med* 1986;27:465-484
6. Sackner M, Landa J, Forrest T, Greeneltch D. Periodic sleep apnea: chronic sleep deprivation related to intermittent upper airway obstruction and central nervous system disturbance. *Chest* 1975;67:164-171
7. Imes NR, Orr WC, Smith RO, Rogers RM. Retrognathia and sleep apnea. *JAMA* 1977;237:1596-1587
8. Vallgo A, Atroy G. Hypoventilation in acquired micrognathia. *Arch Intern Med* 1965;115:307-310
9. Remmers JE, DeGroot WJ, Sauerland EK, Anch AM. Pathogenesis of upper airway occlusion during sleep. *J Appl Physiol* 1978;44:931-938
10. Guilleminault C, Riley R, Powell N. Sleep apnea in abnormal cephalometric measurements. *Chest* 1987;86:783-794
11. Walsh JK, Vatsantonis GP. Somnofluoroscopy as a predictor of UPPP efficacy. *Sleep Res* 1984;13:21(21)
12. Ell S, Jolles H, Galvin J. Cine CT demonstration of fixed upper airway obstruction. *AJR Am J Roentgenol* 1986;146:669-677
13. Haponik EF, Smith PL, Bohlman ME, Allen RP, Goldman SM, Bleecker ER. Computerized tomography in obstructive sleep apnea. *Am Rev Resp Dis* 1983;127:221-226
14. Bohlman ME, Haponik EF, Smith PL, Allen RP, Bleecker ER. CT demonstration of pharyngeal narrowing in adult obstructive sleep apnea. *AJR Am J Roentgenol* 1983;140:534-548

15. Sutatt PM, Dee P, Atkinson RL, Armstrong P, Wilhoit SC. Fluoroscopic and computed tomographic features in the pharyngeal airway in obstructive sleep apnea. *Am Rev Respir Dis* 1983;127:487-492
16. Rivlin J, Hoffstein V, Kolbfleisch J, McNicoles WT, Zamel N, Bryan AC. Upper airway morphology in patients with ideopathic obstructive sleep apnea. *Am Rev Respir Dis* 1984;129:355-360
17. Simmons FB, Guilleminault C, Silvestri R. Snoring and some obstructive sleep apnea can be cured by oropharyngeal surgery: palatopharyngoplasty. *Arch Otolaryngol* 1983;109:503-507
18. DeBerry-Borowiecki B, Kukwa A, Blanks R. Indications for palatopharyngoplasty. *Arch Otolaryngol* 1985;111:659-663
19. Caldarelli D, Cartwright R, Lilie J. Obstructive sleep apnea: variations in surgical management. *Laryngoscope* 1985;95:1070-1073
20. Conway W, Fujita S, Zorik F, Roth R, Martset, Piccione P. Uvulo-palatopharyngoplasty in treatment of upper airway sleep apnea. *Am Rev Respir Dis* 1980;121:121
21. Waite PD, Wooten V, Lachner J, Guyette RF. Maxillomandibular advancement surgery in 32 patients with obstructive sleep apnea syndrome. *J Oral Maxillofac Surg* 1989;47:1256-1261
22. Riley RW, Powell NB, Guilleminault C, Nino-Mureia G. Maxillary, mandibular and hyoid bone advancement: an alternative to tracheostomy in obstructive sleep apnea syndrome. *Otolaryngol Head Neck Surg* 1986;94:584-588
23. Partinen M, Guilleminault C, Quera Salva MA, Jamieson A. Obstructive sleep apnea and cephalometric roentgenograms: the role of anatomic upper airway abnormalities in the definition of abnormal breathing during sleep. *Chest* 1988;93:1199-1205





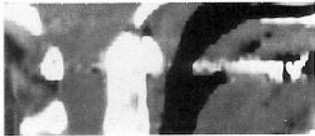A



C



B



D

