

Are your **MRI contrast agents** cost-effective?

Learn more about generic **Gadolinium-Based Contrast Agents**.



FRESENIUS
KABI

caring for life

AJNR

Combined use of endovascular coils and surgical clipping for intracranial aneurysms.

M P Marks, G K Steinberg and B Lane

AJNR Am J Neuroradiol 1995, 16 (1) 15-18

<http://www.ajnr.org/content/16/1/15>

This information is current as
of April 20, 2024.

Combined Use of Endovascular Coils and Surgical Clipping for Intracranial Aneurysms

Michael P. Marks, Gary K. Steinberg, and Barton Lane

Summary: We report two cases in which combined surgical clipping and endovascular coils have been used to treat intracranial aneurysms. In one case, a 59-year-old woman with multiple episodes of subarachnoid hemorrhage had an anterior communicating artery aneurysm, which was initially treated with coils and then clipped to occlude the aneurysm securely. In the second case, a broad-based cavernous aneurysm could not be completely surgically occluded, but surgical clipping did decrease the aneurysm neck size, allowing it to be successfully treated with coils.

Index terms: Aneurysm, intracranial; Interventional neuroradiology

The mainstay of treatment for intracranial aneurysms has been surgical clipping (1). Endovascular therapy of aneurysms may be required when surgical approach is difficult because of aneurysm location and geometry, or when the medical or neurologic condition of the patient significantly increases the risks of anesthesia and surgical intervention (2). Recent reports have described endovascular placement of coiled wire in aneurysm lumens to achieve thrombosis of the aneurysm as an alternative to surgery (3–5). These reports have stressed the use of endovascular therapy as the sole treatment when surgery is unlikely to be successful or has a high risk. We report two cases in which surgery and endovascular coils could be considered adjunctive therapies to the other procedure.

Case Reports

Case 1

A 59-year-old woman was seen at an outside hospital, 9 days before transfer to our institution. She was initially obtunded and confused but improved over the next 3 days and was discharged without workup. She was readmitted two days later, incoherent and obtunded. A lumbar punc-

ture performed at this time showed evidence of subarachnoid hemorrhage, and the next day an angiogram demonstrated an irregularly shaped anterior communicating artery aneurysm and a left middle cerebral artery aneurysm. The patient was transferred to our institution and over the next 4 days gradually improved clinically. She was mildly confused and lethargic but obeyed commands and was oriented to name and place. On the fourth hospital day at our institution, she suddenly became somnolent and was not following commands. A computed tomographic scan demonstrated new subarachnoid blood in the interhemispheric fissure, suggesting a repeat rupture of the anterior communicating artery aneurysm. Because she had bled multiple times and was in poor neurologic condition (Hunt and Hess grade IV), the patient was brought to the angiography suite where the anterior communicating artery aneurysm was selectively catheterized with a Tracker 18 catheter (Target Therapeutics, Fremont, Calif). No evidence of vasospasm was seen in the anterior cerebral artery on the side that was catheterized before coiling. One 2 × 20-mm fibered complex helical coil (Target Therapeutics) was placed into the aneurysm, resulting in thrombosis (Figs 1A and B). The patient's subsequent 2-week hospital course was complicated by vasospasm, which was treated with volume expansion and nimodipine. She developed elevated velocities in the middle cerebral artery circulation on transcranial Doppler and a transient left hemiparesis. She gradually improved and left the hospital without a significant neurologic deficit. Ten months later she returned to our institution for repeat angiographic evaluation and clipping of the previously untreated middle cerebral artery aneurysm. At this time the patient was noted to have a poor short-term memory, but no other neurologic deficits were noted. The preoperative angiogram confirmed that the anterior communicating artery aneurysm was thrombosed, and the middle cerebral artery aneurysm had not changed (Fig 1C). At surgery, the middle cerebral artery aneurysm was clipped, and the anterior communicating artery aneurysm was explored and observed to be thrombosed; however, a small portion of the coil was noted to be protruding out of the dome of the aneurysm into the subarachnoid space. A clip was placed just beneath the margin of the intraaneurysmal coil across

Received October 23, 1992; accepted after revision March 22, 1993.

From the Departments of Diagnostic Radiology (M.P.M., B.L.) and Neurosurgery (M.P.M., G.K.S., B.L.), Stanford (Calif) University Medical Center.

Address reprint requests to Michael P. Marks, MD, Department of Diagnostic Radiology, Stanford University Medical Center, Stanford, CA 94305.





Fig 1. Case 1. Fifty-eight-year-old woman after subarachnoid hemorrhage from an anterior communicating artery aneurysm.

A, Oblique view of right internal carotid artery angiogram demonstrates a 5-mm anterior communicating artery aneurysm with cross-filling through a patent anterior communicating artery and contrast in both anterior cerebral arteries.

B, Right internal carotid artery angiogram obtained 9 months after placement of one coil in the aneurysm shows complete thrombosis of the aneurysm and a patent anterior communicating artery with filling of both anterior cerebral arteries.

C, Left internal carotid artery angiogram at 9 months shows an additional middle cerebral artery aneurysm (*large arrow*). The coil within the thrombosed anterior communicating artery aneurysm is also noted (*small arrow*).

D, View of the anterior communicating artery aneurysm through an operating microscope at the time of surgery for clipping of the left middle cerebral artery aneurysm (9 months after endovascular treatment). Coil loops are noted within the completely thrombosed aneurysm (*straight arrow*). A small segment of the coil is noted to extend through the dome of the thrombosed aneurysm into the subarachnoid space (*curved arrow*). This thrombosed aneurysm was also clipped at surgery.

E, Right carotid artery angiogram after clipping of the thrombosed anterior communication artery aneurysm shows continued patency of the anterior communicating artery with the clip at the base of the aneurysm adjacent to the coil.

the neck of the aneurysm to ensure continued thrombosis (Fig 1D and E). After surgery, the patient did well, and a postoperative angiogram demonstrated thrombosis of both aneurysms.

Case 2

A 26-year-old Vietnamese man had an intraventricular and subarachnoid hemorrhage from a large left hemispheric arteriovenous malformation 9 years before being seen at our institution. Workup before planned radiosurgery demonstrated a small supraclinoid carotid artery aneurysm and a large broad-based intracavernous aneurysm (Fig 2A). The intracavernous aneurysm neck was judged too broad based to allow stable intraaneurysmal coil placement. In addition, the aneurysm extended too deeply into the cavernous sinus to be clipped completely. We decided to fashion a smaller neck at surgery and complete the treatment of the intracavernous portion of the aneurysm with endovascular coiling.

The distal supraclinoid aneurysm was clipped using a curved Sugita clip. The larger broad-based aneurysm was approached after drilling off the anterior clinoid, optic strut, and roof of the optic canal. The paraclinoid carotid artery



Fig 2. Case 2. Twenty-six-year-old man with a left basal ganglia arteriovenous malformation and two aneurysms in the left internal carotid artery circulation.

A, Left internal carotid artery angiogram demonstrates early filling of the arteriovenous malformation from multiple dilated lenticulo-striate arteries. A large cavernous carotid aneurysm (*large arrow*) and a smaller supraclinoid carotid aneurysm (*small arrow*) are noted.

B, Left internal carotid artery angiogram obtained after surgery. The supraclinoid carotid aneurysm has been successfully clipped. In addition, the superior portion of the cavernous aneurysm has also been clipped, creating a smaller neck on the aneurysm, making coil placement easier.

C, Left internal carotid artery angiogram after placement of five coils within the aneurysm, achieving complete thrombosis.

was dissected away from the dural ring surrounding the carotid artery as it entered the cavernous sinus. Here, three straight fenestrated Sugita clips were placed along the base of the upper portion of the aneurysm to narrow the neck. The clips encircled the internal carotid artery with the clip apertures. The more inferior portion of the aneurysm could not be completely clipped without extensive dissection of the cavernous sinus. After surgery, the aneurysm was selectively catheterized from the femoral route using a Tracker 18 catheter, and three 3×20 -mm and two 2×20 -mm fibered complex helical coils (Target Therapeutics) were placed into the aneurysm. After this, control angiography demonstrated no residual filling of the aneurysm (Fig 2B and C). The patient did well after endovascular therapy, and follow-up angiography 4 months later demonstrated continued thrombosis of the aneurysm.

Discussion

Vasospasm and rebleeding have been implicated as the leading causes of morbidity and mortality after aneurysm hemorrhage. Although early surgery may prevent the risk of rebleeding, there does not seem to be a significant overall benefit, because there is a higher rate of complication in early surgery than in late surgery (1). An endovascular technique that allows for thrombosis of the aneurysm without initial surgical clipping may be of benefit in the treatment of patients with acute subarachnoid hemorrhage, because it should significantly reduce

the risk of rebleeding and allow for more aggressive treatment of vasospasm with pressors and volume expansion. In case 1 of this report, the aneurysm responsible for acute subarachnoid hemorrhage was coiled and effectively thrombosed. This aneurysm was subsequently clipped during surgical exploration for an additional aneurysm. Although it is true that the aneurysm in this case was completely thrombosed, this case effectively shows that endovascular coiling can be used in conjunction with aneurysm clipping. Aneurysm coiling does not always achieve complete thrombosis. However, even if complete thrombosis cannot be achieved with coiling, there may be benefit in partial coiling with occlusion and thrombosis in the dome, because this region has been implicated as the site of hemorrhage in more than 80% of aneurysm ruptures (6). Rehemorrhaging from an endovascularly treated aneurysm has been reported when complete thrombosis is not achieved (2, 7). There may therefore be benefits in surgical clipping if coiling has not completely thrombosed the aneurysm. This may prove true particularly if the patient's neurologic condition after subarachnoid hemorrhage has prohibited a surgical procedure from being safely performed, and at a later period the patient could then be surgically treated.

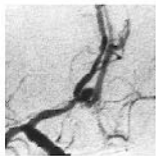Every aneurysm shape may not be amenable to endovascular coiling. Endovascular treatment of saccular aneurysms requires that the aneurysm neck be relatively narrow compared with the aneurysm diameter. A broad-based neck will not ensure safe and stable positioning of coils within the aneurysm. In addition, flow into and out of a broad-based aneurysm is likely to be more rapid than flow in an aneurysm with a narrow neck. Preliminary coiling results suggest that aneurysms with broader-based necks are less likely to thrombose, and that coils are more likely to migrate and become compacted (7). One solution used here (case 2) during treatment of a broad-based cavernous aneurysm combined surgery and endovascular treatment. By clipping the portion of the aneurysm neck that was surgically accessible, a narrower neck was created, which allowed for safe coil placement. This may prove to be an alternative treatment for large cavernous aneurysms and bulbous bifurcation aneurysms (such as large basilar tip aneurysms) that cannot be easily approached to place a clip completely across the aneurysm neck, of which the broad base prevents effective coiling.

Intraaneurysm coiling depends on achieving stable placement of the catheter within the aneurysm before coil release. There are inherent risks in the placement of conventional coils such as those used in these cases. One modification has been the development of retractable coils that are electrolytically detached (3, 7). A mechanically detachable coil has also been developed and used in an animal model of aneurysms, and successfully used to occlude a human carotid artery (8). We have more recently used this coil design successfully to treat aneurysms endovascularly. Although, the conventional coils reported in these two cases will

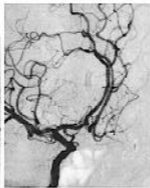
likely be replaced by retractable coils, this report is of value for several reasons. It demonstrates that coil thrombosis of acutely ruptured aneurysms does not prevent future surgical clipping and may therefore be a useful adjunct to later surgery by preventing rebleeding. The technique may reduce the risk of rebleeding even when complete thrombosis is not achieved but the dome of the aneurysm has been thrombosed. It also demonstrates the use of a combined surgical and endovascular approach to achieve aneurysm thrombosis, when the aneurysm shape or location prohibits success of either technique alone. Advances in coil design and release techniques will no doubt improve the efficacy of this procedure.

References

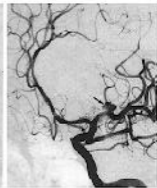
1. Kassell NF, Torner JC, Jane JA, Haley EC, Adams HP. The international cooperative study on the timing of aneurysm surgery, 2: surgical results. *J Neurosurg* 1990;73:37-47
2. Higashida RT, Halbach VV, Barnwell SL, et al. Treatment of intracranial aneurysms with preservation of the parent vessel: results of percutaneous balloon embolization in 84 patients. *AJNR Am J Neuroradiol* 1990;11:633-640
3. Guglielmi G, Vinuela F, Dion J, Duckwiler G. Electrothrombosis of saccular aneurysms via endovascular approach, 2: preliminary clinical experience. *J Neurosurg* 1991;75:8-14
4. Higashida RT, Halbach VV, Dowd CF, Barnwell SL, Hieshima GB. Interventional neurovascular treatment of a giant intracranial aneurysm using platinum microcoils. *Surg Neurol* 1991;35:64-68
5. Lane B, Marks MP. Coil embolization of an acutely ruptured saccular aneurysm. *AJNR Am J Neuroradiol* 1991;12:1067-1069
6. Crompton MR. Mechanism of growth and rupture in cerebral berry aneurysms. *Br Med J* 1966;1:1138-1142
7. Guglielmi G, Vinuela F, Duckwiler G, et al. Endovascular treatment of posterior circulation aneurysms by electrothrombosis using electrically detachable coils. *J Neurosurg* 1992;77:515-524
8. Marks MP, Chee H, Lidell RP, Steinberg GK, Panahian N, Lane B. A mechanically detachable coil for the treatment of aneurysms and occlusion of blood vessels. *AJNR Am J Neuroradiol* 1994;15:821-827



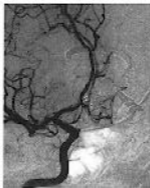
A



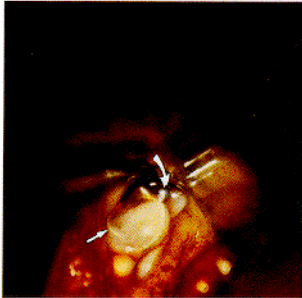B



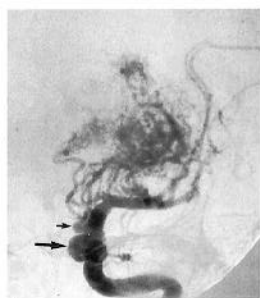C



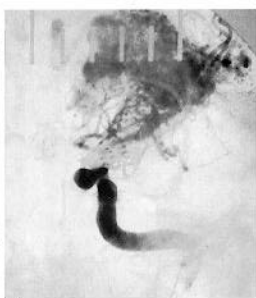D



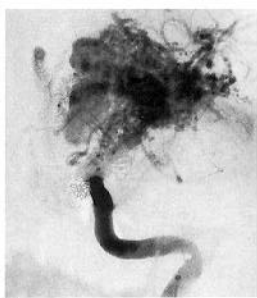D



A



B



C