

Are your MRI contrast agents cost-effective?
Learn more about generic Gadolinium-Based Contrast Agents.



AJNR

Trilateral retinoblastoma: two variations.

D A Finelli, S B Shurin and D S Bardenstein

AJNR Am J Neuroradiol 1995, 16 (1) 166-170
<http://www.ajnr.org/content/16/1/166>

This information is current as
of April 17, 2024.

Trilateral Retinoblastoma: Two Variations

Daniel A. Finelli, Susan B. Shurin, and David S. Bardenstein

Summary: Two cases of trilateral retinoblastoma (a syndrome of midline, undifferentiated, intracranial tumor in a child with hereditary, bilateral ocular retinoblastoma) are described, one with a unique location of the intracranial tumor, and the other with an unusual temporal course of disease.

Index terms: Retina, neoplasms; Infants, neoplasms

Trilateral retinoblastoma is a syndrome in which a solitary, midline intracranial neoplasm occurs in association with hereditary retinoblastoma (1–4). Fewer than 50 cases of trilateral retinoblastoma have been reported in the literature, but several typical patterns emerge: (a) nearly all patients have hereditary bilateral retinoblastoma; (b) the third lesion is most commonly an undifferentiated primitive neuroectodermal tumor in the pineal region (pinealoblastoma); (c) the ocular retinoblastoma diagnosis is made much earlier than the typical 15 months reported for classical bilateral retinoblastoma (5); (d) there is a mean latent period of more than 32 months between the clinical diagnosis of bilateral retinoblastoma and trilateral retinoblastoma (6); and (e) patients die soon after diagnosis of trilateral retinoblastoma, with extensive central nervous system dissemination. In approximately 25% of the cases we found reported, the third lesion has been an undifferentiated tumor in the parasellar or suprasellar region.

Two cases of trilateral retinoblastoma are presented here, both having unusual features. The first patient is a 5-month-old infant with hereditary bilateral retinoblastoma who was found at magnetic resonance (MR) examination to have a primitive neuroectodermal tumor of the fourth ventricle region. The location of the

intracranial tumor, early diagnosis of bilateral retinoblastoma, and the short time interval for diagnosis of trilateral retinoblastoma make this case a unique variation of trilateral retinoblastoma. The second patient is a 15-month-old infant who presented with symptoms of the intracranial lesion, a pineal region primitive neuroectodermal tumor, before the diagnosis of ocular disease.

Case Reports

Case 1

A 5-month-old girl with a history of bilateral retinoblastoma presented in December 1991 for MR imaging of the orbits. She had been diagnosed at age 7 weeks with bilateral retinoblastoma, at which time a computed tomographic (CT) scan had shown no evidence of intracranial masses. External beam radiation therapy, cryosurgical therapy, and laser photocoagulation therapy had failed; the child had multifocal recurrent ocular disease and was being evaluated for episcleral radioactive plaque therapy. An MR examination was obtained to evaluate for optic nerve head invasion. The infant's mother had a history of right eye enucleation at age 2 years for retinoblastoma; she had no evidence of tumor in the left eye and had received no further therapy.

Axial fat-saturated T1-weighted scans of the orbits revealed the bilateral retinoblastoma, appearing as discreet intraocular masses on the posterior retinal surfaces (Fig 1A). The T2-weighted scan of the entire brain showed a subtle 1.5-cm area of increased signal intensity in the medial (fourth ventricular) surface of the right cerebellar hemisphere (Fig 1B). The unmagnified oblique sagittal T1-weighted scan (Fig 1C) and axial fat-saturated T1-weighted image (Fig 1D) after gadolinium administration confirmed the presence of an inhomogeneously enhancing mass in the inferior vermian region, extending along the medial right cerebellar hemisphere. The infant underwent

Received November 17, 1992; accepted after revision March 11, 1993.

Presented at the 30th Annual Meeting of the American Society of Neuroradiology, St Louis, Mo, May 1992.

From the Department of Radiology, Neuroradiology Section, MetroHealth Medical Center/Case Western Reserve University School of Medicine (D.A.F.), and the Departments of Pediatrics (S.B.S.) and Ophthalmology (D.S.B.), University Hospitals of Cleveland/Case Western Reserve University School of Medicine, Cleveland, Ohio.

Address reprint requests to Daniel A. Finelli, MD, Department of Radiology, MetroHealth Medical Center, 2500 MetroHealth Dr, Cleveland, OH 44109-1998.

AJNR 16:166–170, Jan 1995 0195-6108/95/1601-0166 © American Society of Neuroradiology




Fig 1. Case 1. *A*, Axial fat-saturated, T1-weighted (600/20/2 [repetition time/echo time/excitations]) scans of the orbits revealed the bilateral retinoblastoma, appearing as discrete intraocular masses on the posterior retinal surfaces (*arrows*).

B, T2-weighted (2500/90/1) scan of the posterior fossa shows a subtle 1.5-cm area of increased signal intensity in the medial (fourth ventricular) surface of the right cerebellar hemisphere (*arrow*).

C, Unmagnified, oblique sagittal T1-weighted scan and *D*, axial fat-saturated, T1-weighted image after gadolinium administration confirmed the presence of an inhomogeneously enhancing mass in the inferior vermian region, extending along the medial right cerebellar hemisphere (*arrows*), which was surgically resected and found to be a primitive neuroectodermal tumor.

craniotomy and resection of the fourth ventricle mass, which was found to be a primitive neuroectodermal tumor with neuronal differentiation. The child then received episcleral plaque radiation therapy for her bilateral retinoblastoma and systemic chemotherapy for her residual intracranial disease. She is alive and without evidence of intracranial disease 10 months after diagnosis of the intracranial mass and is still receiving chemotherapy at age 15 months.

Case 2

A 15-month-old girl presented in August 1991 with headache and vomiting. A CT scan disclosed a large 5-cm pineal region mass producing obstructive hydrocephalus. Bilateral intraocular masses were also evident on the head CT scan, compatible with bilateral retinoblastoma. The patient did not have a family history of retinoblastoma. MR imaging was performed the following day, and T1-weighted scans after gadopentetate dimeglumine administration (Fig 2A and B) again showed the large, enhancing pineal region mass, producing obstructive hydrocephalus at the level of the aqueduct of Sylvius. A scan through the orbits (Fig 2C) revealed the bilateral, enhancing intraocular masses on the retinal surface, compatible with bilateral retinoblastoma. A craniotomy and resection was at-

tempted, but because of the extensive tumor, only a debulking procedure was performed. A ventriculoperitoneal shunt was placed, and external beam radiation therapy was begun. The infant had progressive neurologic deterioration and died 7 weeks after diagnosis. Widespread metastatic pinealoblastoma was evident at autopsy.

Discussion

The development of a midline, undifferentiated intracranial malignant neoplasm is relatively uncommon in patients with retinoblastoma; Pesin and Shields (7) reported seven cases of trilateral retinoblastoma of 245 patients with retinoblastoma (2.8%) referred to their institution over a 4-year period. Six of these 7 patients had bilateral retinoblastoma, and 1 patient had unilateral retinoblastoma. The development of a midline, undifferentiated malignant neoplasm in unilateral retinoblastoma has been described and is considered to represent a *forme fruste* of trilateral retinoblastoma (1, 4, 7-10). Patients with trilateral retinoblastoma frequently have multicentric and




Fig 2. Case 2. A, Axial and B, sagittal T1-weighted spin-echo images of the brain after gadopentetate dimeglumine administration. There is a 4- to 5-cm enhancing mass in the pineal region (*arrows*), compatible with a pinealoblastoma.

C, Axial image at the level of the orbits shows the enhancing bilateral, intraocular retinoblastoma masses (*arrows*), confirming the diagnosis of trilateral retinoblastoma.

recurrent ocular disease (6, 7, 11). Holladay et al (6) in 1991 reported three cases and reviewed 32 cases in the literature of "true" trilateral retinoblastoma, with respect to their clinical presentation, treatment, and outcome. The mean age of diagnosis of ocular disease was 7.2 months and intracranial disease was 39.7 months; thus, the mean latent interval was 32.6 months. However, nearly all the patients reviewed by Holladay et al (6) seem to have presented clinically with increased intracranial pressure as the clue to the presence of the intracranial lesions, therefore they likely all had advanced disease, with either overt obstructive hydrocephalus or diffuse central nervous system drop metastases. Interestingly, the patients with parasellar or suprasellar lesions seemed to have much shorter latency periods than those with pineal tumors, some even predating the diagnosis of retinoblastoma (7, 8). Our patient with the fourth ventricle region primitive neuroectodermal tumor, which was diagnosed with MR imaging in a preclinical stage within 4 months of her retinoblastoma, fits this pattern of the non-pineal region third lesions occurring earlier than the pineal lesions in trilateral retinoblastoma. The fourth ventricular lesion was small, and had it

not been discovered on the MR scans, it would have remained subclinical for several months.

Nelson et al (11) recently described three cases of trilateral retinoblastoma in which early, preclinical diagnoses of pineal region tumors were made with CT or MR imaging; in all three infants, the intracranial pineal lesions were diagnosed within 8 months of their retinoblastoma. This is much earlier than the clinical latency period of 32.6 months described by Holladay et al (6). Our second case is unusual in that the intracranial disease was diagnosed before the infant's ocular disease, although the ocular tumors were already fairly large. It is now apparent that the clinical latency periods described by Holladay et al (6) and others (7, 8) probably should not be considered true latency periods. The previously described difference in latency periods by location may merely reflect the size of the lesion versus critical location for obstruction, neurologic deficit, or potential for cerebrospinal fluid seeding, which determines clinical presentation.

Retinoblastoma is a prototypical hereditary human cancer, with 30% to 40% of patients having heritable predisposition to the tumor (12). This hereditary predisposition to retinoblastoma is caused by mutant alleles occurring

at the q14 band of chromosome 13 (13); retinoblastoma will develop in 80% to 90% of persons with this chromosomal defect (12). It is believed that the tumor cells of all ocular retinoblastomas carry the genetic defect, which is present as a transmitted, germ-line mutation in patients with hereditary disease (12, 14). A diagnostic test for this genetic predisposition has been developed, which identifies restriction fragment-length polymorphisms within the retinoblastoma gene locus (14) in leukocytes. In our case 1, identical defects within the retinoblastoma gene locus were identified by restriction fragment-length polymorphism analysis in the infant, her mother, and in the cells of the resected fourth ventricular region primitive neuroectodermal tumor.

Before the recognition of the trilateral retinoblastoma syndrome, the intracranial lesions were thought to represent metastatic retinoblastoma. Arguments against this include: that there are no direct vascular or neuronal channels between the retina and the pineal gland, that intracranial lesions have been seen in patients with small, noninvasive retinoblastoma that almost never metastasize, and that the pineal gland has not proved a metastatic site of retinoblastoma (4). The pinealoblastoma in trilateral retinoblastoma usually demonstrates neuronal differentiation, with evidence of Homer Wright rosettes and positive immunohistochemical staining for neuronal markers. Pinealoblastoma, particularly when associated with retinoblastoma, can demonstrate evidence of retinal differentiation, with Flexner-Wintersteiner rosettes and fleurettes, having the 9 + 0 cilia configuration normally observed in photoreceptors (15). Both pineal and parasellar or suprasellar primitive neuroectodermal tumors have been accepted in the current definition of trilateral retinoblastoma (6-8); the compelling genetic studies of the fourth-ventricle region primitive neuroectodermal tumor in our case 1 clearly indicate that this case should also be accepted within scope of trilateral retinoblastoma.

Despite local control of the ocular retinoblastoma, it is the lethality of the intracranial lesion that dramatically affects patient outcome. In the patients reviewed by Holladay et al (6), after the diagnosis of trilateral retinoblastoma, patients survived an average of 6.6 months, with those having no treatment surviving 1.3 months and those with any form of

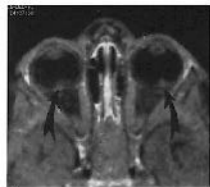
definitive therapy surviving an average of 9.7 months. As suggested by Pesin et al (7), more successful treatment for patients with TRB may well hinge on the possibility of early preclinical detection of lesions with MR imaging or CT. This has been demonstrated in the study by Nelson et al (11), in which the three reported patients have no active disease 1 to 8 years after treatment with systemic and intrathecal chemotherapy, as well as craniospinal irradiation. Although the infant in case 2 died soon after presenting with advanced disease, the infant in case 1 is alive 10 months after surgery and systemic chemotherapy, with no clinical or radiologic evidence of intracranial disease.

In conclusion, these two cases of trilateral retinoblastoma represent variations of classical trilateral retinoblastoma in which either the temporal course of disease or the location of the intracranial malignant neoplasm was unusual. It is now apparent that the intracranial tumor in trilateral retinoblastoma may present at any time, in any midline location. Because of the lethality of the third lesion in trilateral retinoblastoma, early detection of preclinical lesions is very important; this has translated into improved survival in several recently described cases. Patients with hereditary bilateral retinoblastoma presenting for orbital MR imaging should also have scans including the pineal, parasellar, suprasellar, and fourth ventricular regions. Monitoring with brain MR examinations at 6- to 12-month intervals may be of benefit to this small group of patients with a high propensity for very aggressive intracranial malignant neoplasms.

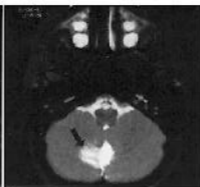
References

1. Jacobiec FA, Tso MO, Zimmerman LE, Danis P. Retinoblastoma and intracranial malignancy. *Cancer* 1977;39:2048-2058
2. Jensen RD, Miller RW. Retinoblastoma: epidemiologic characteristics. *N Engl J Med* 1971;285:307-311
3. Bader JL, Miller RW, Meadows AT, et al. Trilateral retinoblastoma. *Lancet* 1980;2:582-583
4. Bader JL, Meadows AT, Zimmerman LE, et al. Bilateral retinoblastoma with ectopic intracranial retinoblastoma: trilateral retinoblastoma. *Cancer Genet Cytogenet* 1982;5:203-213
5. Francois J, Matton MT, DeBie S, Tonaka Y, Vandenbulcke D. Genesis and genetics of retinoblastoma. *Ophthalmologica* 1975;170:405-425
6. Holladay DA, Holladay A, Montebello JF, Redmond KP. Clinical presentation, treatment, and outcome of trilateral retinoblastoma. *Cancer* 1991;67:710-715

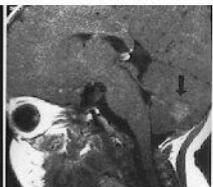7. Pesin SR, Shields JA. Seven cases of trilateral retinoblastoma. *Am J Ophthalmol* 1989;107:121-126
8. Zimmerman LE. Trilateral retinoblastoma. In: Blodi FC, ed. *Retinoblastoma*. New York: Churchill Livingstone, 1985:185-210
9. Whittle IR, McClellan K, Martin FJ, Johnston IH. Concurrent pinealoblastoma and unilateral retinoblastoma: a forme fruste of trilateral retinoblastoma. *Neurosurgery* 1985;17:500-505
10. Stannard C, Knight BK, Sealy R. Pineal malignant neoplasm in association with hereditary retinoblastoma. *Br J Ophthalmol* 1985;69:749
11. Nelson SC, Friedman HS, Oakes WJ, et al. Successful therapy for trilateral retinoblastoma. *Am J Ophthalmol* 1992;114:23-29
12. Vogel F. Genetics of retinoblastoma. *Hum Genet* 1979;52:1-54
13. Sparkes RS, Murphee AL, Lingua RW, et al. Gene for hereditary retinoblastoma assigned to human chromosome 13 by linkage to esterase D. *Science* 1983;219:971-973
14. Wiggs J, Nordenskjold M, Yandell D, et al. Prediction of the risk of hereditary retinoblastoma, using DNA polymorphisms within the retinoblastoma gene. *N Engl J Med* 1988;318:151-157
15. Burger PC, Scheithauer BW, Vogel FS. *Surgical Pathology of the Nervous System and Its Coverings*. 3rd ed. New York: Churchill Livingstone, 1991:386-387



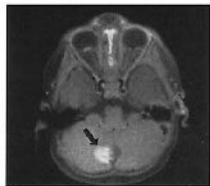
A



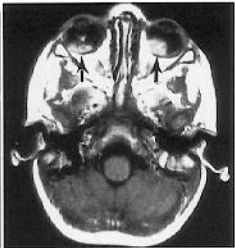
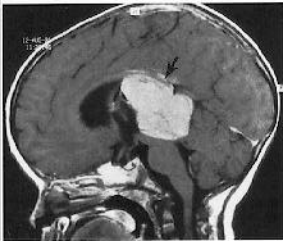
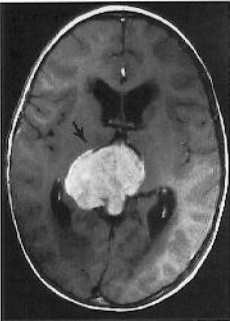B



C



D



A

B

C