AJNR

The anatomy of the inferior petrosal sinus, glossopharyngeal nerve, vagus nerve, and accessory nerve in the jugular foramen.

D Rubinstein, B S Burton and A L Walker

AJNR Am J Neuroradiol 1995, 16 (1) 185-194
http://www.ajnr.org/content/16/1/185

The Anatomy of the Inferior Petrosal Sinus, Glossopharyngeal Nerve, Vagus Nerve, and Accessory Nerve in the Jugular Foramen

David Rubinstein, Bradford S. Burton, and Anne L. Walker

PURPOSE: To define the variations of the courses of the cranial nerves and the inferior petrosal sinuses as they enter and traverse the jugular foramen. **METHODS:** Thirty-nine cadaveric specimens containing the jugular foramen were scanned with 1-mm contiguous axial and coronal CT sections. Each specimen was dissected to evaluate the position of the cranial nerves and inferior petrosal sinus as they entered the jugular foramen. **RESULTS:** The glossopharyngeal nerve entered the most superior, anterior, and medial aspect of the jugular foramen and descended in the anterior portion of the jugular foramen, often within a groove. The vagus and accessory nerves could not be separated by CT. They entered the jugular foramen most often anterior or anterior and inferior to the jugular spine of the temporal bone and descended in a position ranging from medial to anterior to the jugular vein. The inferior petrosal sinus most often coursed inferior to the horizontal portion of the glossopharyngeal nerve and entered the jugular system in the jugular foramen, at the exocranial opening or below the skull base. A pars nervosa and pars venosa could be identified only at the endocranial opening, where the jugular spine separated the pars nervosa containing the inferior petrosal sinus and three cranial nerves from the pars venosa containing the jugular vein. **CONCLUSION:** Our evaluation demonstrated anatomic variation in the area of the jugular foramen.

Index terms: Foramina, jugular; Nerves, anatomy; Nerves, cranial; Skull, base

AJNR Am J Neuroradiol 16:185–194, January 1995

Despite several studies involving dissection of the jugular foramen, the exact anatomy of the foramen is uncertain. Studies have reached different conclusions, probably for two reasons. First, the anatomy of the jugular foramen shows great variation from person to person. Second, dissection of the foramen is a destructive process in which the structures remaining cannot be related to the structures that have been removed. Computed tomography (CT) and magnetic resonance (MR) imaging have provided a nondestructive method to evaluate the complicated anatomy of the jugular foramen. The production of high-speed high-resolution CT scanners has made it possible to study the anatomy of the jugular foramen in situ in a series of specimens. We defined by CT the courses and the variations of the courses of the cranial nerves and the inferior petrosal sinus as they enter and traverse the jugular foramen.

Materials and Methods

Thirty-nine formalin-fixed cadaveric skull base specimens were evaluated. The specimens were obtained from cadavers used for anatomy courses and included one jugular foramen. Each specimen was scanned with 1-mm contiguous axial and coronal sections (Fig 1E and F). The axial sections were performed parallel to a plane approximately 30° above the canthomeatal line, and the coronal sections were obtained approximately perpendicular to the canthomeatal line. Each specimen was scanned twice in each position. The specimens were first scanned with markers for the glossopharyngeal, vagus, and accessory nerves and the inferior petrosal sinus and then scanned without the markers. Twenty-five-gauge needles marked the site of dural penetration of each of the cranial nerves, and an angiographic wire marked the course of the inferior petrosal sinus. A cranial nerve was not marked if definite fibers of that nerve could not be identified. The inferior

Received February 16, 1994; accepted after revision June 3.

From the Department of Radiology, University of Colorado Health Sciences Center, Denver.

Address reprint requests to David Rubinstein, MD, University of Colorado Health Sciences Center, Department of Radiology, 4200 E Ninth Ave, Campus Box A-034, Denver, CO 80262.

AJNR 16:185–194, Jan 1995 0195-6108/95/1601–0185

KEY TO FIGURES
1 Jugular spine of the temporal bone
2 Jugular vein
3 Sigmoid sinus or groove for the sigmoid sinus
4 Glossopharyngeal meatus
5 Trigeminal nerve
6 Abducent nerve or marker for abducent nerve
7 Inferior petrosal sinus or marker for inferior petrosal sinus
8 Facial and vestibulocochlear nerves and/or internal auditory canal
9 Glossopharyngeal nerve or marker for glossopharyngeal nerve
10 Vagus and accessory nerves or marker for vagus and accessory nerves
11 Cochlear aqueduct
12 Hypoglossal nerve or marker for the hypoglossal nerve

petrosal sinus was not marked if the sinus could not be threaded with wire. The specimens were scanned at 200 mA and 120 kV, and with a 1-second scan time on a CT HiSpeed Advantage scanner (General Electric Medical Systems, Milwaukee, Wis). The scans were reconstructed with a 9.6-cm field of view and a bone algorithm. A three-dimensional surface reconstruction was performed of each specimen with and without the markers (Figs 1C and D; 2B and C).

After each specimen was scanned, the dura was removed and blunt dissection was performed to demonstrate the entrance of the cranial nerves into the jugular foramen and their course within the jugular foramen near the endocranial opening (Fig 1A and B). Because the bone margins of the foramen were not altered, the entire course of the cranial nerves throughout the foramen could not be evaluated. The specimens also were evaluated for division of the foramen into separate sections or canals by bone structures by partially or completely removing the contents of the foramen and using sharp and blunt probes to

Fig 1. *See Key to Figures.*
A, Specimen that includes the left jugular foramen viewed from posterior and medial to the specimen.
B, Same specimen after dura has been removed; slightly more posterior view.
C, Three-dimensional CT reconstruction of the same specimen with markers viewed from posterior and medial to the specimen.
D, Three-dimensional CT reconstruction without markers. (*Figure 1 continues.*)



E

Fig 1, *cont'd. E,* One-mm contiguous superior-to-inferior axial CT images. (*Figure 1 continues.*)

evaluate potential canals. The findings from the dissections were compared with the CT images.

Results

The CT scans and dissections demonstrated that at least a portion of the length of the jugular foramen was divided into two canals by bone partition in eight specimens. The division of the foramen was short in most specimens but spanned almost the entire length of the foramen in one (Fig 2D). In five specimens the contents of the canals were determined with certainty. Four had small canals that contained only the glossopharyngeal nerve (Fig 2A and D), and one had a larger anterior canal at the endocranial opening that contained the glossopharyngeal, vagus, and accessory nerves and the inferior petrosal sinus. In the other three specimens, some structures could not be identified. In one specimen the small anterior compartment contained the inferior petrosal sinus and possibly the glossopharyngeal nerve, which was not identified. In one, a small anterior canal contained the glossopharyngeal nerve and possibly the inferior petrosal sinus, which was not identified. In the last specimen with two canals a large anterior compartment was seen, which contained the glossopharyngeal nerve and the inferior petrosal sinus and probably the vagus and accessory nerves, but these two nerves were not identified for certain.

The CT scans suggested that two other specimens may have had divided bone canals. The very thin potential bone separation of the ca-



F

Fig 1, *cont'd. F,* One-mm contiguous posterior-to-anterior coronal CT images. In this specimen the glossopharyngeal nerve enters its meatus and then descends in a groove before entering the anterior jugular foramen, which is one large compartment. The cochlear aqueduct (E and F) extends superiorly from the glossopharyngeal meatus towards the round window of the cochlea. In the foramen the glossopharyngeal nerve is separated from the vagus and accessory nerves by the inferior petrosal sinus, which passes inferior to the glossopharyngeal nerve before joining the jugular vein (F, *arrow*). The vagus and accessory nerves pass inferior to the jugular spine and then anteromedial to the jugular vein. The regions outlined by boxes in E and F have been rewindowed to demonstrate the nerves better.

nals, however, proved fibrous at dissection. The jugular foramen of one specimen was so damaged at harvesting that it could not be determined whether the canal might be divided or not.

In addition to the division of the jugular foramen into two canals described above, the jugular foramen demonstrated varying degrees of partition by bone structures at multiple levels along its length. Only the level of the endocranial opening of the foramen had a consistent partition. The degree of separation at the endocranial opening depended on the size of the jugular spine of the temporal bone, which varied from completely bridging the foramen in the one specimen already described to being extremely small in other specimens. The size of the jugular spine identified on the three-dimensional reconstructions correlated with the size of the jugular spine seen at dissection in all specimens (Figs 1B and D; 2A and C; 3A and B).

At dissection, in 34 of the 35 specimens in which it could be identified, the glossopharyngeal nerve entered the most superior, anterior, and medial portion of the endocranial opening of the jugular foramen (Figs 1B and 3A). In these specimens the glossopharyngeal nerve was located anterior to the most superior portion of the jugular spine of the temporal bone. In the remaining specimen, the glossopharyngeal

Fig 2. *See Key to Figures.*

A, Specimen that includes the right jugular foramen with dura removed viewed from posterior and medial to the specimen.

B, Three-dimensional CT reconstruction of the specimen with markers viewed from posterior and medial to the specimen.

C, Three-dimensional CT reconstruction without markers.

(*Figure 2 continues.*)

nerve entered its own canal in the same location on the surface of the temporal bone (Fig 2A). The 3-D reconstructions of the CT scans demonstrated the same anatomy. On axial CT sections the glossopharyngeal nerve always entered a recess in the temporal bone just inferior to the internal auditory canal (Figs 1E, 2D, and 3C). The cochlear aqueduct was demonstrated on coronal sections to course superiorly from the jugular foramen just superior to the glossopharyngeal nerve as it entered the foramen (Fig 1F).

The course of the glossopharyngeal nerve within the jugular foramen was determined by CT only. The nerve was identified in a groove in the anterior portion of the foramen for all or part of its course in 23 specimens (Fig 1E). In one specimen, it traveled in a groove that extended anteriorly from a canal containing all three cranial nerves and the inferior petrosal sinus. In five specimens the glossopharyngeal nerve traveled in a canal separate from the other nerves (Fig 2D), and in one it traveled in a canal that was indeterminate for containing the vagus and accessory nerves. The glossopharyngeal nerve coursed in the anterior jugular foramen without a groove in six specimens (Fig 3C) and was not identified in four specimens.

The dissections revealed that in all the specimens in which they could be identified, the vagus and accessory nerves entered the foramen together or nearly together, passing through the dura inferior and slightly posterior to the glossopharyngeal nerve. They coursed anterior to the jugular spine of the temporal bone in 15 specimens (Fig 2A and B), anterior and inferior to the spine in 20 specimens (Fig 3A and B), and inferior to the spine in two specimens (Fig 1B and C). The CT scans demonstrated the same position of the nerves relative to the jugular spine in all specimens but could not demonstrate the vagus and accessory nerves as two separate nerves. The nerves were not present at the endocranial opening in two specimens.

CT was used to determine the course of the vagus and accessory nerves within the foramen. In all 37 specimens in which they were identified



D

Fig 2, *cont'd. D,* One-mm contiguous superior-to-inferior axial CT images. In this specimen the glossopharyngeal nerve enters and descends in its own canal before joining the anterior inferior jugular foramen. The entrance to the canal is at the expected location of the glossopharyngeal meatus. The vagus and accessory nerves pass anterior to a large jugular spine and then course anteromedial to the clot-containing jugular vein in the irregularly shaped jugular foramen. The inferior petrosal sinus could be identified only at the entrance of the jugular foramen. The regions outlined by boxes in D have been rewindowed to demonstrate better the glossopharyngeal nerve.

they were encased in tissue, closely apposed to the jugular vein. They were always anteromedial to the jugular vein (Figs 1E, 2D, and 3C) but ranged from nearly medial to nearly anterior to the jugular vein. As at the endocranial opening, the vagus and accessory nerves could not be distinguished as separate nerves. Although the course of the vagus and accessory nerves deep in the foramen could not be determined at dissection, the tissue encasing the nerves was found to be fibrous in nature.

In 22 of the 25 specimens in which the relationship of the inferior petrosal sinus to the glossopharyngeal nerve could be determined, the inferior petrosal sinus entered the foramen by passing inferior to the horizontally oriented and laterally coursing portion of the glossopharyngeal nerve, the portion entering the foramen (Fig 1E and F). In the remaining three cases, the inferior petrosal sinus entered the foramen more inferiorly, heading inferiorly anteromedial or medial to the glossopharyngeal nerve as it descended in the foramen. Further in the jugular foramen, the inferior petrosal sinus coursed inferiorly and laterally passing between the descending portion of the glossopharyngeal nerve anteriorly and the vagus and accessory nerves posteriorly in 16 of the 20 specimens in which all of the structures could be identified (Fig 1E). The sinus remained medial to the nerves in

Fig 3. *See Key to Figures.*
A, Specimen that includes the right jugular foramen with dura removed viewed from posterior and medial to the specimen.
B, Three-dimensional CT reconstruction of the specimen with markers viewed from posterior and medial to the specimen. (*Figure 3 continues.*)

three specimens and passed medial to and then posterior to all three nerves in one specimen. In 27 cases the junction of the inferior petrosal sinus with the jugular venous system was identified. In four the junction was within the jugular foramen (Fig 1E and F), in eight it was at the exocranial opening of the jugular foramen, and in 15 it was below the skull base. The relationships of the inferior petrosal sinus were determined only by CT.

The positions of the cranial nerves and inferior petrosal sinus entering and within the jugular foramen are summarized in the Table.

Discussion

Previous CT and MR reports describing anatomy of the cranial nerves and inferior petrosal sinus in the jugular foramen have suggested uniformity of the area, but few specimens have been studied (1–3). Our evaluation of 39 jugular foramina demonstrated variation in the area.

The most uniform finding in our study was the entrance of the glossopharyngeal nerve into the most superior, anterior, and medial aspects of the endocranial opening of the jugular foramen. On CT this appeared as a recess similar in shape to but smaller than the internal auditory canal. The recess was located several millimeters inferior to the internal auditory canal. The glossopharyngeal nerve entered this recess in all 35 specimens in which the nerve could be identified, and in one the recess had an inferior border producing a canal for the nerve. This recess has been called the "cochlear aqueduct" in the radiologic literature (4–6). The cochlear aqueduct does extend superiorly and laterally from this recess to join the labyrinth near the round window (7–11), but the recess may be more properly thought of as the "glossopharyngeal meatus," because this is where the nerve enters the jugular foramen (7–9). Within the foramen, as previously described (8), the ninth nerve was always found in the anterior portion and was often within a groove in the anterior lateral wall of the foramen.

The vagus and accessory nerves travel together and could not be separated by CT when entering the foramen or when coursing through the foramen. At the entrance to the foramen, the nerves were usually separated by less than a few millimeters as found in other studies (7, 12). Their entrance into the foramen was usually anterior to or anterior and inferior to the jugular spine of the temporal bone. From there they traveled encased in fibrous tissue in a position that was usually anterior and medial to the jugular vein.

The course of the inferior petrosal sinus was somewhat variable. Because we identified the inferior petrosal sinus by threading it with a wire, we most likely indicated the largest of what may be several outflow channels of the sinus. In most cases the inferior petrosal sinus entered the foramen by passing inferior to the horizontally oriented and laterally coursing portion of the glossopharyngeal nerve in the superior foramen and then headed inferiorly.



C

Fig 3, *cont'd. C,* One-mm contiguous superior-to-inferior axial CT images. In this specimen the glossopharyngeal nerve enters its meatus and then descends in the anterior jugular foramen, which has one large compartment. The vagus and accessory nerves pass anteroinferior to a small jugular spine and anteromedial to the jugular vein. The inferior petrosal sinus could not be cannulated. Its presumed location is identified. The regions outlined by the boxes in C have been rewindowed to demonstrate the nerves better.

In the remaining cases it headed inferiorly anterior and medial to the descending portion of the nerve and on no occasion passed superior to the horizontally oriented portion of the nerve. In the foramen, the sinus most often coursed inferolaterally, passing between the descending portion of the glossopharyngeal nerve and the vagus and accessory nerves. All the variations of the inferior petrosal sinus course demonstrated in our study have been documented (7, 8, 12). As demonstrated in other studies, the position where the inferior petrosal sinus joined the jugular venous system was variable and occurred within the foramen, at the exocranial opening of the foramen or below the skull base (7, 12, 13).

The most widely recognized variation in the anatomy of the jugular foramen is the complete division of the foramen by a bone septum. The fraction of foramina that are divided varies in the radiologic (14, 15), anatomic (7, 12), and anthropologic (16–21) studies. The anthropologic studies suggest that at least one factor affecting this finding is the genetic composition of the populations studied (16–21). Our finding that 21% (8 of 38) of the jugular foramina were divided is in the 11%-to-34% range demonstrated in the anatomic and radiologic studies (7, 12, 14). The variation of which structures were in the divided components of the jugular foramen is in agreement with Lang (7) who did

Positions of cranial nerves and inferior petrosal sinus (no. of cases)

	At Entrance to Jugular Foramen	Within the Jugular Foramen
Glossopharyngeal Nerve	In recess at superior anterior aspect of endocranial opening (34/35) In canal at superior anterior aspect of endocranial opening (1/35)	In groove in anterior foramen (23/35) In anterior foramen without groove (6/35) In own canal anterior and lateral to foramen (5/35) In groove in anterior canal containing the three cranial nerves (1/35)
Vagus and Accessory Nerves	Anterior to jugular spine (15/37) Anterior and inferior to jugular spine (20/37) Inferior to jugular spine (2/37)	Anterior to jugular vein (5/37) Anterior and medial to jugular vein (19/27) Medial to jugular vein (13/37)
Inferior Petrosal Sinus	Inferior to horizontal portion of glossopharyngeal nerve (22/25) Anterior and medial or medial to descending portion of glossopharyngeal nerve (3/25)	Between glossopharyngeal and vagus/accessory nerves (16/20) Medial to all three cranial nerves (4/20)

the most detailed analysis of compartmentalization of the foramen.

The division of the jugular foramen into a pars nervosa and pars venosa by fibrous bands or as suggested by bone spurs is a matter of debate. Two groups have formed among those who believe the length of the jugular foramen is separated into a pars nervosa and pars venosa. One group states that the pars nervosa contains the inferior petrosal sinus and the glossopharyngeal, vagus, and accessory nerves and that the pars venosa contains the jugular vein (15, 22). The second group states that the pars nervosa contains only the inferior petrosal sinus and the glossopharyngeal nerve and that the vagus and accessory nerves reside with the jugular vein in the pars venosa (1–4, 12, 14, 16, 23). Authors of only two studies, Lang (7) and Kveton and Cooper (13), believe that within the foramen, there is no constant division into a pars nervosa and pars venosa. Our data are most consistent with these last two authors.

We found a constant division of the jugular foramen only at its endocranial opening but not within the foramen. At the endocranial opening, the jugular spine of the temporal bone suggested a pars nervosa anterior to it that contained the three cranial nerves and the inferior petrosal sinus and a pars venosa posterior to it that contained the jugular vein. The jugular spine divided the superior aspect of the endocranial opening of the jugular foramen, but the inferior aspect was divided only by the imaginary extension of the spine when the spine did not span the foramen. The division was immediately lost as the nerves passed the endocranial opening.

Despite the close apposition of the vagus and accessory nerves to the jugular vein, no divisions of the foramina were evident that included them with or separated them from the jugular vein. In some specimens, the tissue that encased the vagus and accessory nerves appeared to divide the foramen, but this was not a consistent finding and would not place the vagus and accessory nerves in either an anterior or posterior compartment. This inconsistent and ambiguous division may have lead other authors to different conclusions about the division of the jugular foramen (1–4, 7, 12–16, 22, 23).

In summary, the entrance of the glossopharyngeal nerve into the foramen can be recognized by identifying the recess inferior to the internal auditory canal, which serves as its meatus. The glossopharyngeal nerve then travels in the anterior jugular foramen, often in a groove. The accessory and vagus nerves travel together as they enter the foramen anterior or anterior and inferior to the jugular spine of the temporal bone and course in fibrous tissue anterior and medial to the jugular vein. The inferior petrosal sinus most often courses inferior to the horizontally oriented portion of the glossopharyngeal nerve and may join the jugular venous system at any level. Approximately one jugular foramen in five is separated by bone into two canals along a portion of its length. A consistent pars nervosa and pars venosa can be identified only at the endocranial opening but not within

the foramen. The division at the endocranial opening is suggested by the jugular spine and places the three cranial nerves and the inferior petrosal sinus in the anterior pars nervosa and the jugular vein in the posterior pars venosa.

Acknowledgments

We are indebted to Chad Bowers for photographing the specimens, to Helen Pelster for rewindowing portions of the CT scans, and to Deb Reardon for preparing the manuscript.

References

1. Daniels DL, Williams AL, Haughton VM. Jugular foramen: anatomic and computed tomographic study. *AJNR Am J Neuroradiol* 1983;4:1227–1232
2. Daniels DL, Schenck JF, Foster T, et al. Magnetic resonance imaging of the jugular foramen. *AJNR Am J Neuroradiol* 1985;6: 699–703
3. Daniels DL, Czervionke LF, Pech P, et al. Gradient recalled echo MR imaging of the jugular foramen. *AJNR Am J Neuroradiol* 1988;9:675–678
4. Lo WWM, Solti-Bohman LG. High-resolution CT of the jugular foramen: anatomy and vascular variants and anomalies. *Radiology* 1984;150:743–747
5. Virapongse C, Rothman SLG, Kier EL, Sarwar M. Computed tomographic anatomy of the temporal bone. *AJNR Am J Neuroradiol* 1982;3:379–389
6. Russell EJ, Koslow M, Lasjaunias P, Bergeron RT, Chase N. Transverse axial plane anatomy of the temporal bone employing high spatial resolution computed tomography. *Neuroradiology* 1982; 22:185–191
7. Lang J. Anatomy of the brainstem and the lower cranial nerves, vessels, and surrounding structures. *Am J Otol* 1985;(Suppl)1–19
8. Partridge EJ. The relations of the glossopharyngeal nerve at its exit from the cranial cavity. *J Anat* 1918;52:332–334
9. Williams PL, Warwick R, Dyson M, Bannister LH, eds. Osteology. *Gray's Anatomy*, 37th ed. New York: Churchill Livingstone 1989: 359–379
10. Zonneveld FW. The value of non-reconstructive multiplanar CT for the evaluation of the petrous bone. *Neuroradiology* 1983;25: 1–10
11. Jackler RK, Hwang PH. Enlargement of the cochlear aqueduct: fact or fiction? *Otolaryngol Head Neck Surg* 1993;(109):14–25
12. Rhoton AL, Buza R. Microsurgical anatomy of the jugular foramen. *J Neurosurg* 1975;42:541–550
13. Kveton JF, Cooper MH. Microsurgical anatomy of the jugular foramen region. *Am J Otol* 1988;9:109–112
14. Di Chiro G, Fisher RL, Nelson KB. The jugular foramen. *J Neurosurg* 1964;21:447–460
15. Shapiro R. Compartmentation of the jugular foramen. *J Neurosurg* 1972;36:340–343
16. Dodo Y. Observations on the bony bridging of the jugular foramen in man. *J Anat* 1986;144:153–156
17. Dodo Y. A population study of the jugular foramen bridging of the human cranium. *Am J Phys Anthropol* 1986;69:15–19
18. Sawyer DR, Kiely ML. Jugular foramen and mylohyoid bridging in an Asian Indian population. *Am J Phys Anthropol* 1987;72:473–477
19. Sturrock RR. Anatomical note: variations in the structure of the jugular foramen of the human skull. *J Anat* 1988;160:227–230
20. Sawyer DR, Gianfortune V, Kiely ML, Allison MJ. Mylohyoid and jugular foramen bridging in pre-Columbian Chileans. *Am J Anthropol* 1990;82:179–181
21. Hatiboglu MT, Anil A. Short report: structural variations in the jugular foramen of the human skull. *J Anat* 1992;180:191–196
22. Strickler JM. New and simple techniques for demonstration of the jugular foramen. *Am J Roentgenol Radium Ther Nucl Med* 97: 601–606
23. Remley K, Harnsberger R, Smoker WRK, Osborn AG. CT and MRI in the evaluation of glossopharyngeal, vagal, and spinal accessory neuropathy. *Semin Ultrasound CT MR* 1987;8:284–300

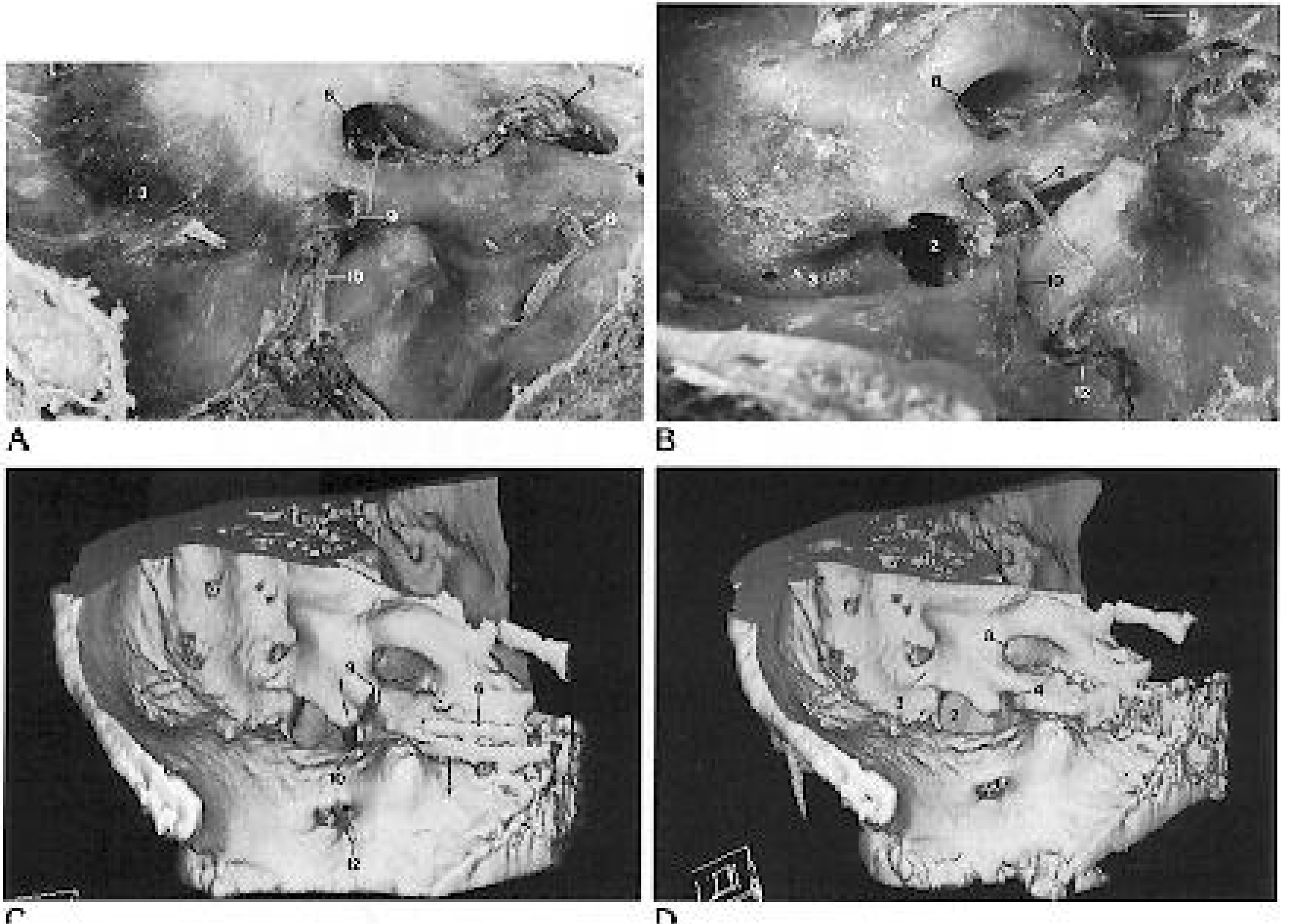
A
B
C
D

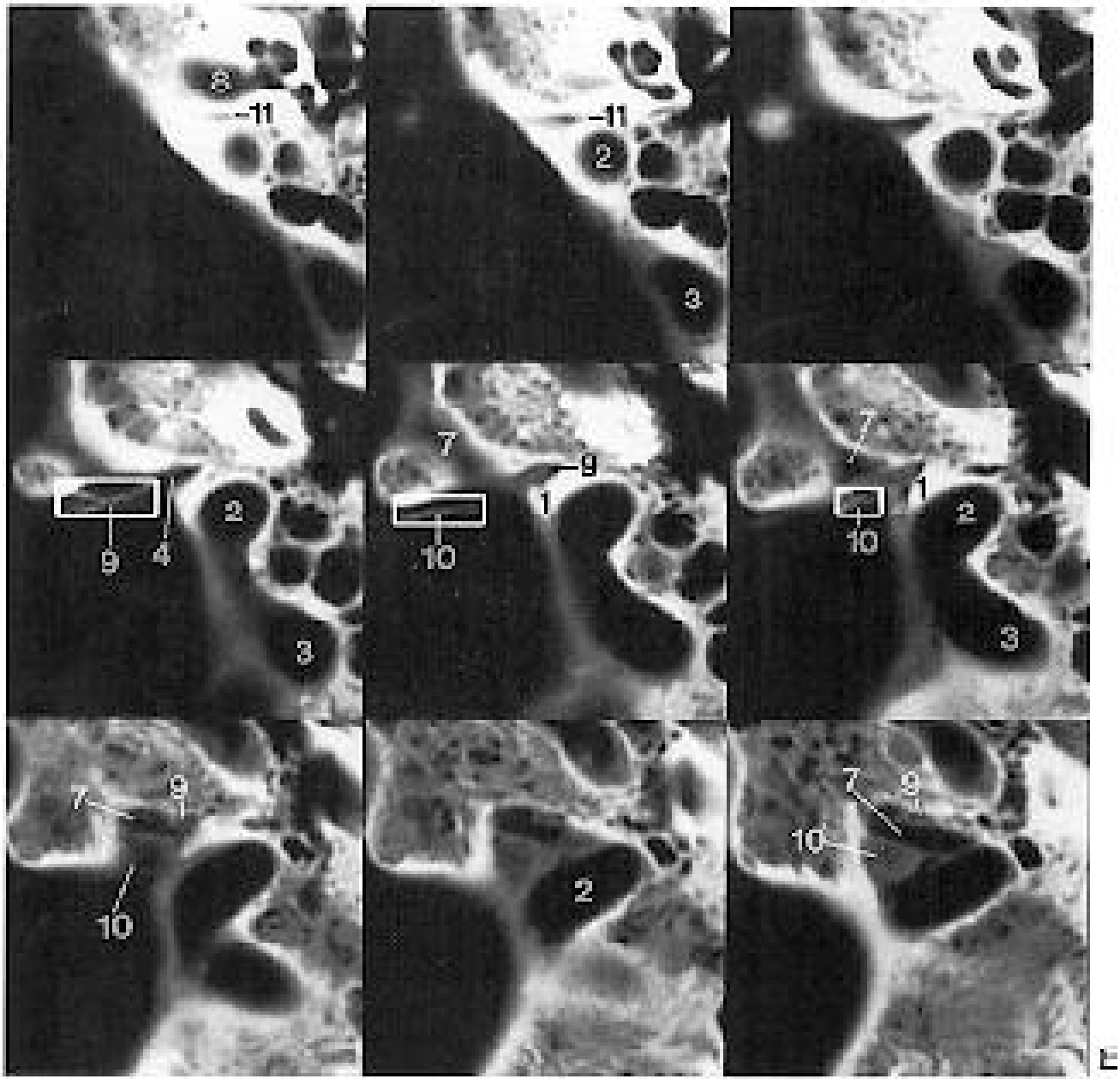
8
11
11
2
3
9
4
2
3
7
9
1
10
7
1
10
2
3
7
9
10
2
7
8
10

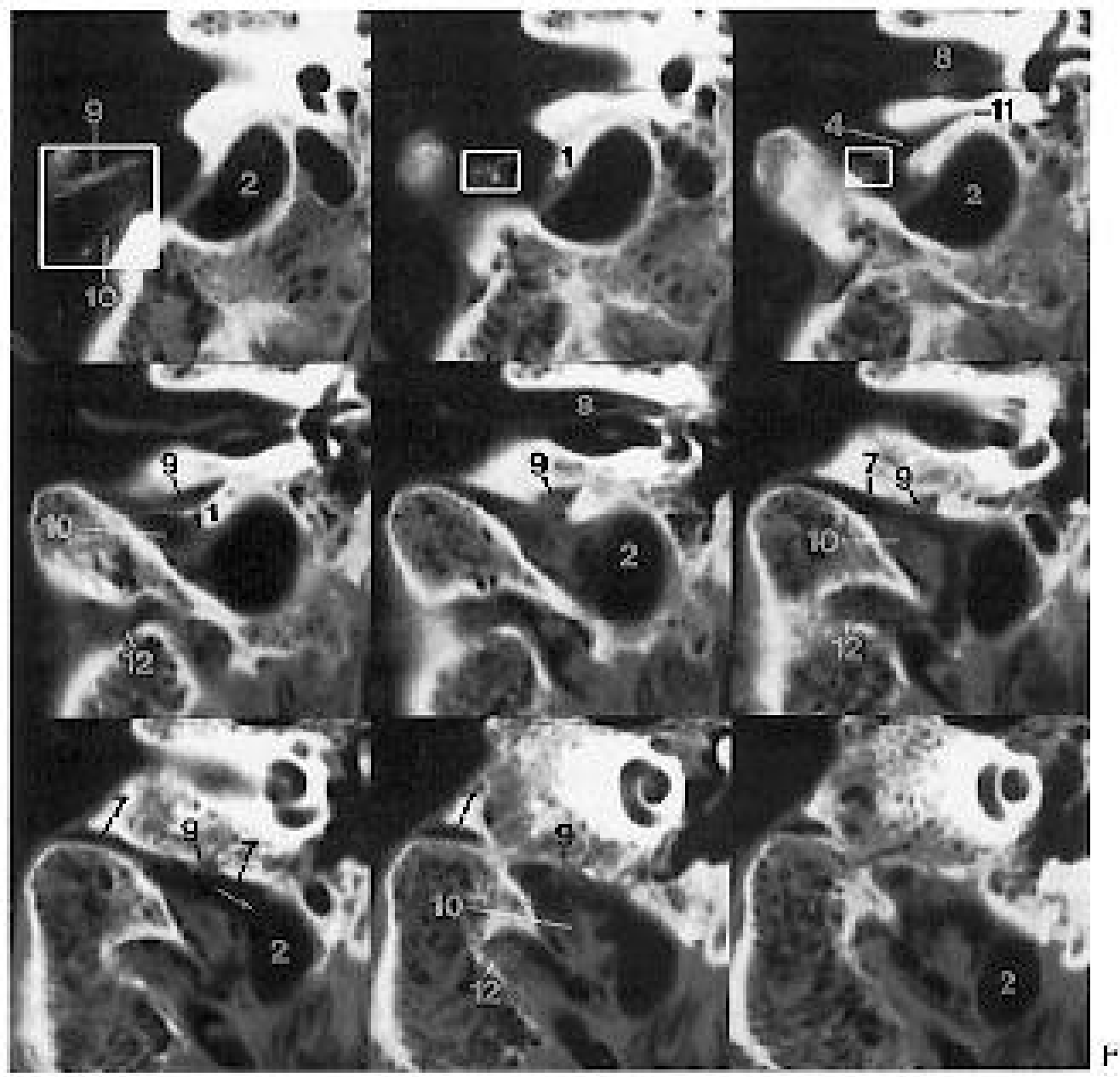

F

A

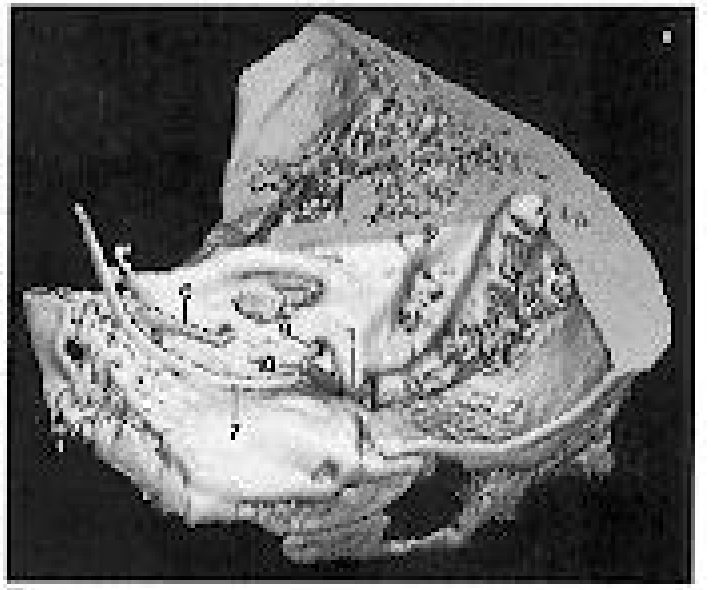

B

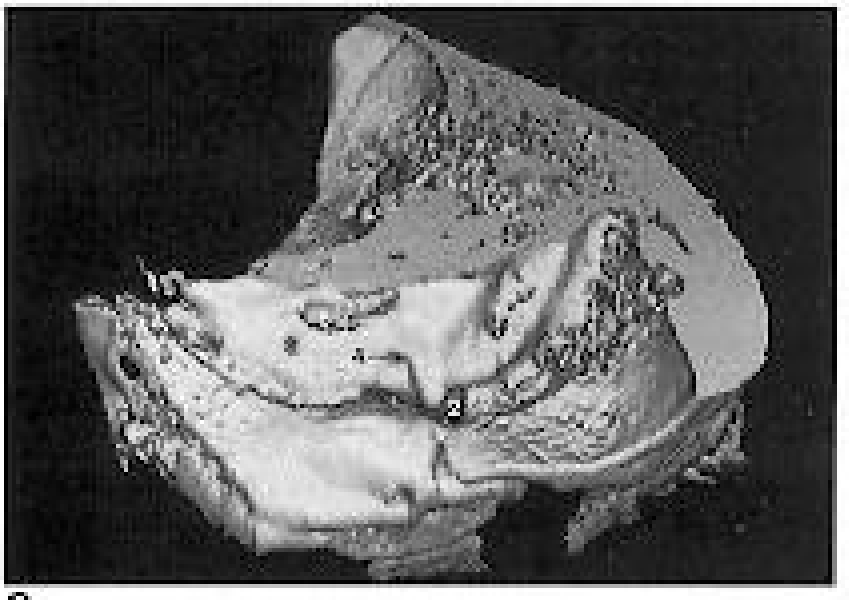

C

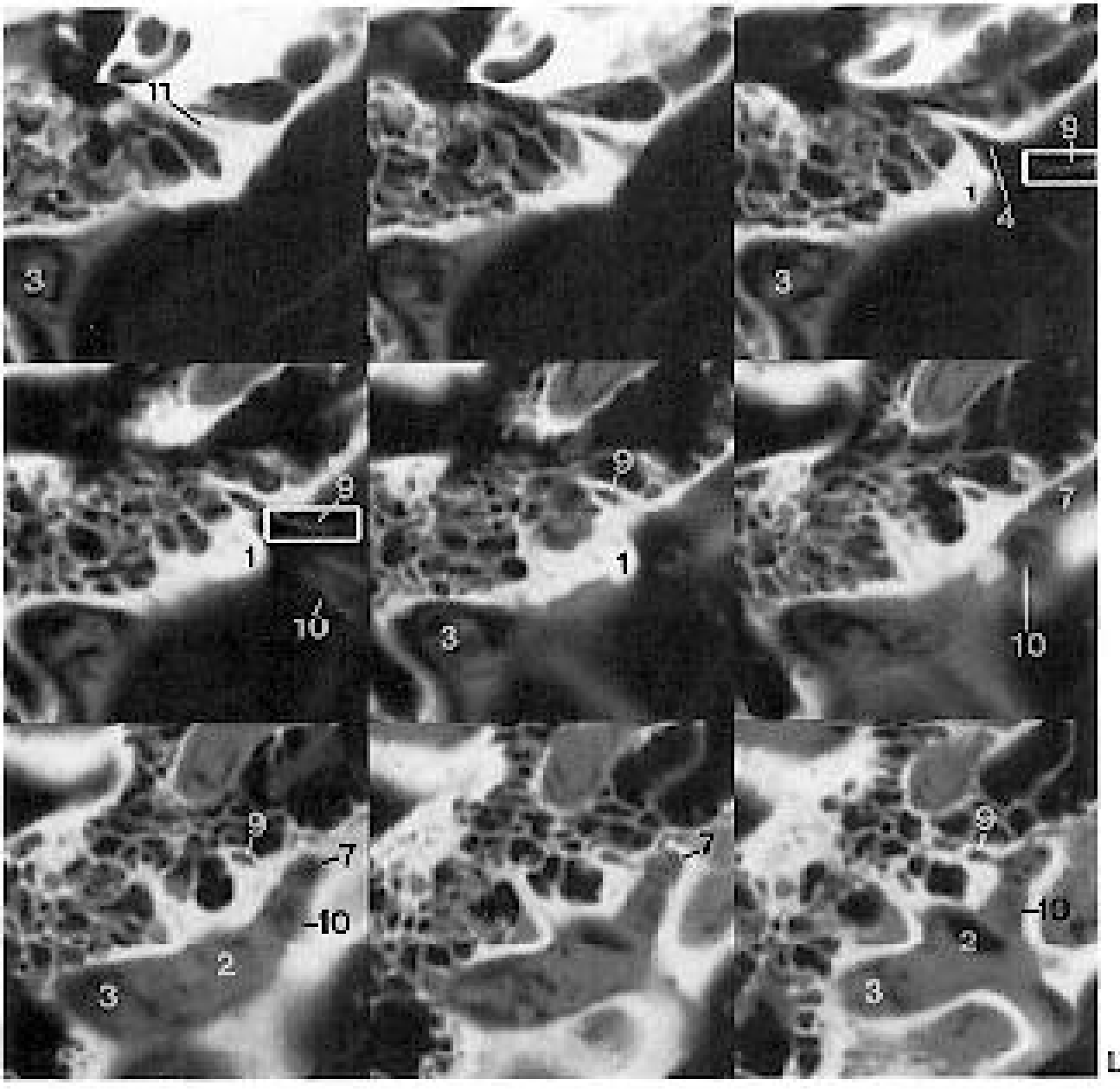

D

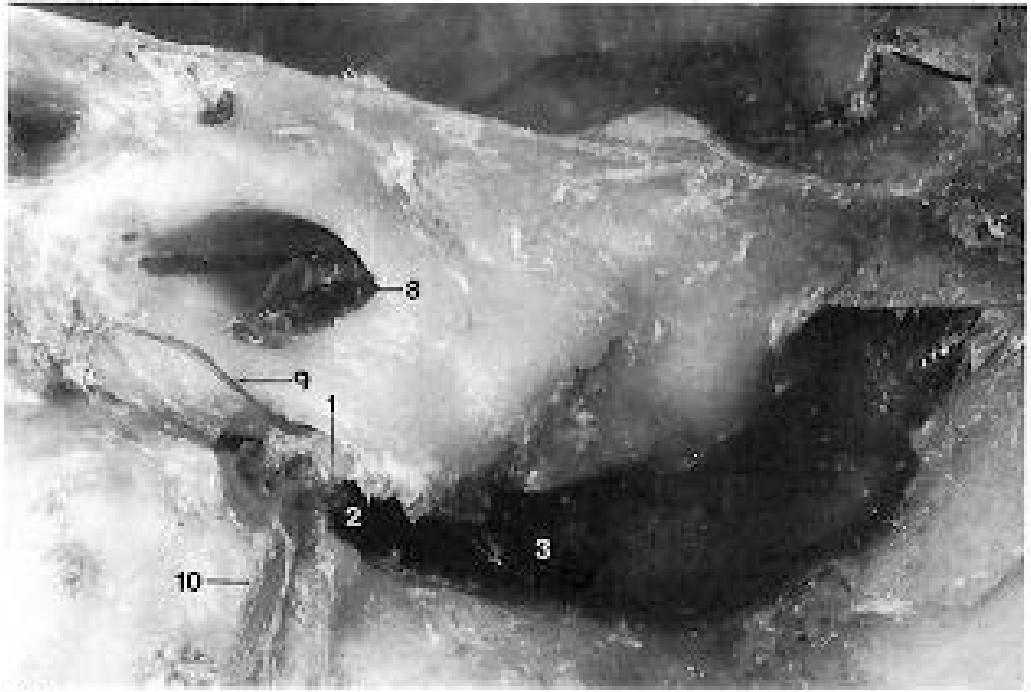

A

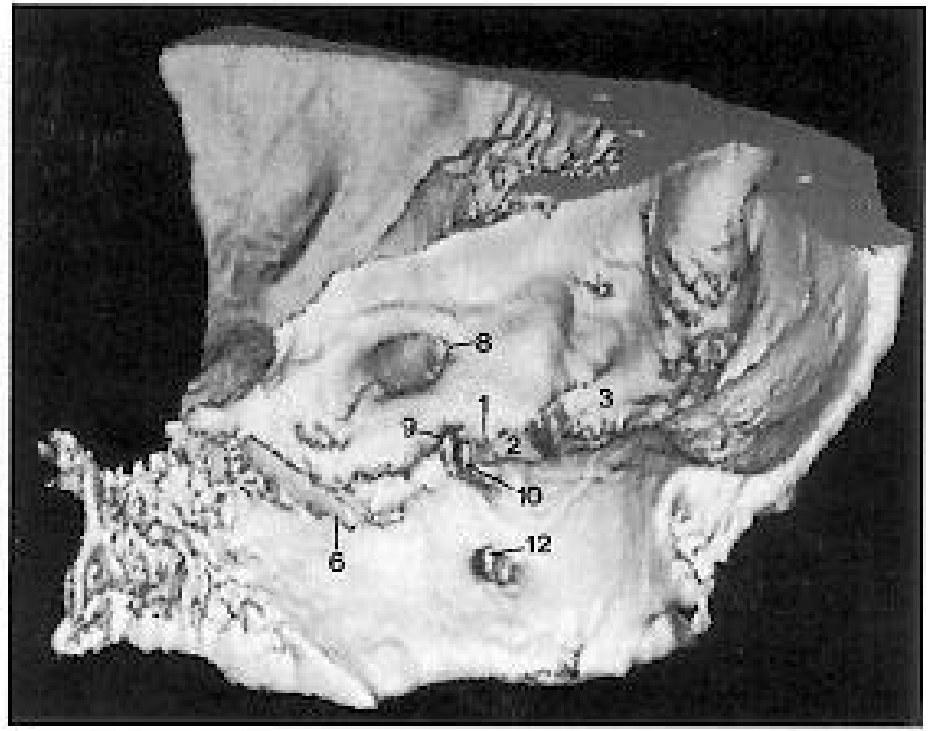

B

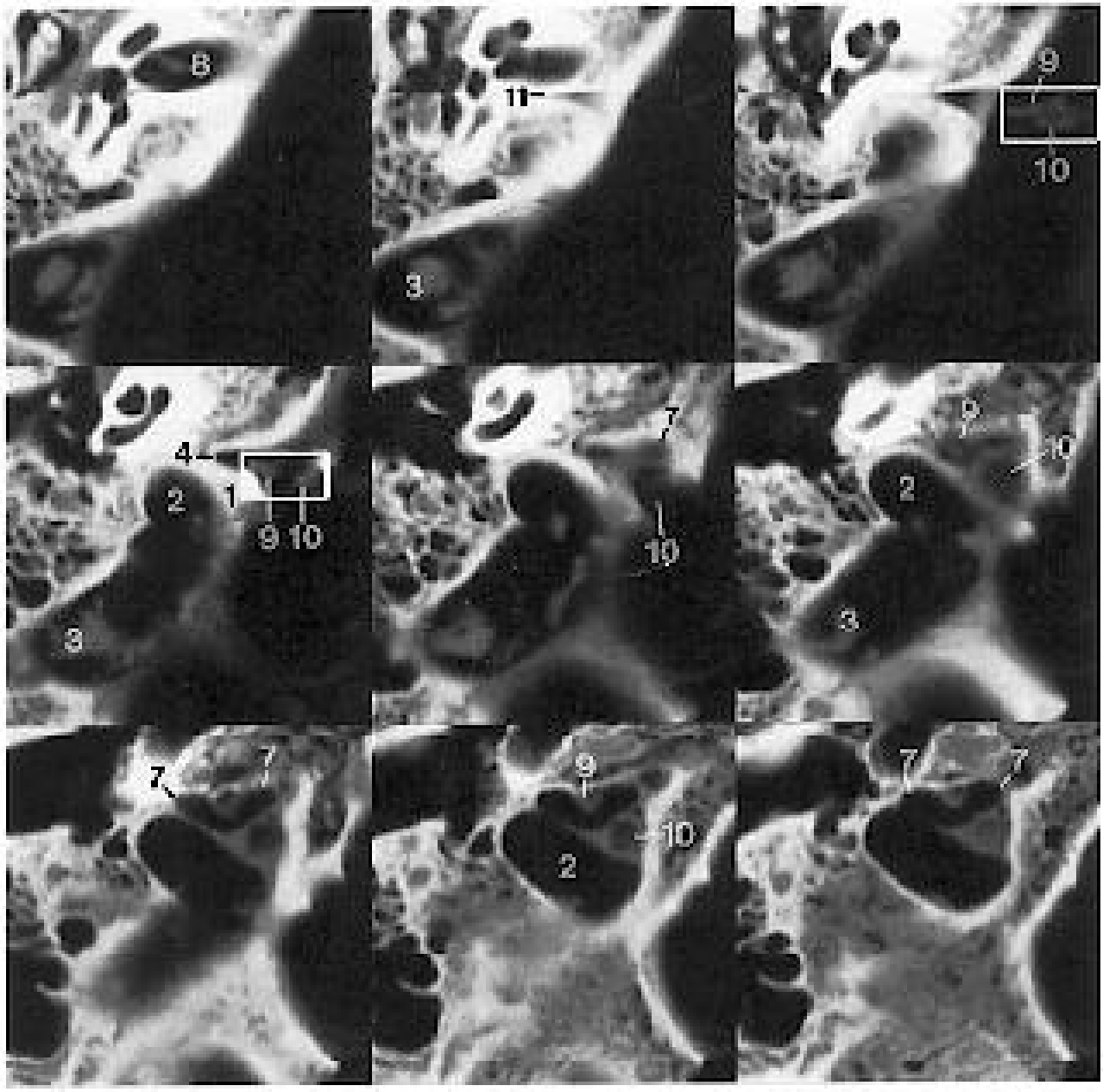

c