Are your MRI contrast agents cost-effective?
Learn more about generic Gadolinium-Based Contrast Agents.
FRESENIUS KABI
caring for life

AJNR

Uncertainties in the diagnosis of brain cysticercosis.

T Corona and C Rivera

AJNR Am J Neuroradiol 1995, 16 (1) 213-214
http://www.ajnr.org/content/16/1/213.citation

This information is current as of April 18, 2024.

LETTERS

Uncertainties in the Diagnosis of Brain Cysticercosis

Recent advances in brain imaging present new challenges for the diagnosis of brain cysticercosis, as illustrated by the following case. A 32-year-old woman was admitted to the neurology department with intracranial hypertension of 9 months duration, mild left hemiparesis (4/5), and a left babinski sign. Cerebrospinal fluid opening pressure was 300 mm H_2O. The fluid contained 25 cells, 120 mg of protein, and 93 mg of glucose/ml. ELISA (enzyme-linked immunosorbent assay) test for cysticercus was positive.

Plain and contrast-enhanced computed tomography (CT) findings were normal (Fig 1). Magnetic resonance (MR) study showed multiple parenchymatous and subarachnoid nodular lesions with diffuse inflammation around lesions, clearly suggestive of cysticercosis (Fig 2).

The advantages of MR over CT for diagnosis of cerebral and subarachnoid cysticercosis have been reported (1–3). In our patient the CT scan was normal, although the MR showed multiple lesions of cysticercotic encephalitis. These findings have implications in regard not only to imaging studies but also to immunologic studies such as ELISA to detect antibodies against cysticerci. Until now CT has been used as the standard diagnostic test to determine sensitivity, specitivity, and predictive values for ELISA test for cysticercosis (4–5). If CT has limitations, the figures obtained by these have to be reassessed according to advances in MR imaging.

Teresa Corona
Julio Sotelo
Instituto Nacional de Neurología y Neurocirugía

Cristina Rivera
Centro Medico Siglo XXI

Mexico City, Mexico

References

1. Chang KH, Lee JH, Han MH, Han MC. The role of contrast-enhanced MR imaging in the diagnosis of neurocysticercosis. *AJNR Am J Neuroradiol* 1991;12:509–512
2. Zee CS, Segall HD, Boswell W, et al. MR imaging of neurocysticercosis. *J Comput Assist Tomogr* 1988;12:927–934
3. Chang KH, Choe YH, Han MC, Kim CW. Magnetic imaging of intracranial cysticercosis: comparison with computed tomography. *Korean J Radiol* 1987;23:524–531
4. Corona T, Pascoe D, Abad P, et al. Anticysticercous antibodies in serum and cerebrospinal fluid patients with cerebral cysticercosis. *J Neurol Neurosurg Psych* 1986;49:1044–1049
5. Rosas N, Sotelo J, Nieto D. ELISA in the diagnosis of neurocysticercosis. *Arch Neurol* 1986;43:353–356

1 2

Fig 1. Enhanced axial CT scan with no abnormalities.
Fig 2. T2-weighted spin-echo MR image (2160/25/2 [repetition time/echo time/excitations]) shows multiple small cystic lesions with variable peripheral edema.

Editor's note.—This letter was referred to Drs Palacios and Silva, whose comments follow.

Reply

The diagnosis and treatment of central nervous system infections remain a challenge, and neurocysticercosis is no exception. As global migration increases, physicians must be constantly aware of the many locations in which this parasitic disease is endemic.

Because of the wide range of nonspecific clinical findings in neurocysticercosis, the diagnosis can be confirmed only with imaging and cerebrospinal fluid studies. Both of these methods have dramatically improved diagnostic accuracy, because they provide evidence of the location of the cysticerci and the degree of host inflammatory reaction.

False-positive results in immune tests are sometime seen in persons from endemic areas, because of contact with the parasite without the development of the disorder. False-negative results in serum also occur because of local production of antibodies without a parallel increase in peripheral blood. In cerebrospinal fluid, there is objective evidence of a host reaction against cysterceri within the subarachnoid space, the degree of inflammation manifested by elevated cells and/or proteins, and a positive immunologic reaction to cysticercal antigens in an ELISA or in the complement fixation test, which, according to Rosas et al (1), have 80% sensitivity and 96% specificity values. This makes them highly reliable and specific in meningeal cysticercosis and somewhat less useful in cases of parenchymal and ventricular neurocysticercosis, particularly in noninflammatory cerebrospinal fluid.

CT has been, and continues to be, important in the diagnosis of parenchymal neurocysticercosis giving reliable information about the location and activity of disease. The CT patterns are: (*a*) vesicular forms, low-density rounded areas that do not enhance with contrast medium (viable cysticerci with immune tolerance by the host); (*b*) colloidal forms, hypodense lesions surrounded by edema and ringlike enhancement (nonviable cysticerci with the host's immune system reacting against the degeneration of the parasite; (*c*) granular nodular forms, isodense areas with nodular enhancement (nonviable cysticerci with immune response and deposition of mineral salts; and (*d*) calcified nodules (sequelae of nonviable granulomas).

One very special pattern is seen in cysticercotic encephalitis, in which there is a multiple infestation of these parasites with a severe acute inflammatory reaction and diffuse brain edema associated with small ventricles and small ringlike lesions with variable enhancement (2). A similar pattern is seen in the case presented above but not depicted in the CT scan because of the small size of the parasites.

New techniques such as MR imaging are of great value in the diagnosis of neurocysticercosis, particularly in cases in which CT findings are not conclusive such as those with intraventricular cysts, lesions in the base of the brain, temporal lobes, brain stem and spine, and the cysticercotic encephalitic form.

It is obvious that MR is superior to CT in the diagnosis of neurocysticercosis. However, this latter imaging method still is a valuable diagnostic tool in neurocysticercosis because of its availability, low cost, and good sensitivity and specificity, including its ability to show small calcifications. We should be knowledgable about the limitations and advantages of each imaging method.

Enrique Palacios
Department of Radiology
MacNeal Hospital
Berwyn, Illinois

Patricia Silva
Department of Radiology
Neurological Institute
Mexico City, Mexico

References

1. Rosas N, Sotelo J, Nieto D. ELISA in the diagnosis of neurocysticercosis. *Arch Neurol* 1985;43:353–356
2. Rodriguez-Carbajal J, Salgado P, Gutierrez-Alvarado R, Escobar-Izquierdo A, Aruffo C, Palacios E. The acute encephalitic phase of neurocysticercosis: computed tomographic manifestations. *AJNR Am J Neuroradiol* 1983;4:51–55

Possible Seasonal Changes in Pituitary Size

It was recently reported that pituitary volume appeared to decrease after two healthy volunteers lived 105 artificial short days and long nights (L10:D14) in the winter (1). The volumes appeared to return to original size after the subjects resumed living with a conventional light-dark cycle (L16:D8) in the spring. It was unclear, however, whether the changes observed, if reliable, were specifically related to the dark condition of the experiment or were related to seasonal changes in the environment outside the experiment (the volunteers lived in their usual environments during the illuminated part of the day). To resolve this question, we took additional measurements of pituitary volume on corresponding dates of the subsequent year when the volunteers were living in their usual environments. Both the experimental and follow-up years' observations are shown in Figure 3. The estimates are averages of coronal and sagittal measurements of scans of 0.7-mm thickness. The woman's scans were all obtained in the follicular phase, with the exception of the winter scan in the first year, which was obtained in the luteal phase.

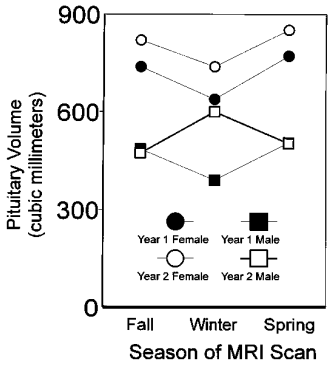

Fig 3. Pituitary volume in three seasons. Year 1 is the year of the original experiment (1); year 2, the following year.

The results are difficult to interpret because pituitary volume decreased in the woman and increased in the man during the follow-up winter. Nevertheless, the fact that the pituitary volume appeared to decrease in three of the four winter measurements compared with the fall and summer measurements raises the possibility that seasonal factors may modify the volume of the pituitary gland. This possibility may be worth investigating further by comparing scans of larger numbers of subjects at different times of year.

Douglas E. Moul
Epidemiology and Psychopathology
Research Branch
National Institute of Mental Health
Rockville, Md

Thomas A. Wehr
Clinical Psychobiology Branch
National Institute of Mental Health
Bethesda, Md

Joseph A. Frank
Laboratory of Diagnostic Radiology Research
Office of Intramural Research
National Institutes of Health
Bethesda, Md

Reference

1. Wehr TA, Moul DE, Barbato G, et al. Conservation of photoperiod-responsive mechanisms in humans. *Am J Physiol* 1993;265: R846–R857

Comment

Moul et al are to be commended for presenting an intriguing hypothesis that pituitary morphology in humans may show specific seasonal variations. As the authors are careful to point out, their data are difficult to interpret. Data on only two subjects does not permit an adequate determination of whether the reported seasonal differences could have resulted from other confounders, such as scan-rescan variability in the technique. Additional information on methodology (such as MR sequence, definition of posterior pituitary boundary, and measurement reliability) may clarify this concern. Thus, their data are probably better viewed as a feasibility study than as evidence supporting their hypothesis.

Despite these issues, this hypothesis remains intuitively attractive and worth studying. In many nonhuman species, the hypothalamic-pituitary axis shows plasticity in response to a variety of environmental and behavioral stimuli (1). Circadian and seasonal changes influence levels of neurohormones, such as the gonadal steroids and some neuropeptides. There is also a growing literature in humans supporting a relationship between the neuroendocrine milieu and pituitary gland morphology (2). For example, normal adolescence, some forms of precocious puberty, primary hypothyroidism, and affective illness have been associated with pituitary "hypertrophy." Anorexia nervosa with amenorrhea and normal aging have been associated with pituitary "atrophy." It can also thus be hypothesized that seasonal influences, if any, on human pituitary morphology will be mediated by one or more of these neurohumoral factors. Given the considerable experience of Moul et al in this field, I would like to encourage from them a larger follow-up study that addresses these issues.

P. Murali Doraiswamy
Duke University Medical Center
Durham, NC

References

1. Doraiswamy PM, Krishnan KR, Nemeroff CB. Hormonal effects on brain function. In: Barrow D, Selman W, eds. *Neuroendocrinology. Vol 5.* Baltimore: Williams & Wilkins, 1993;75–94
2. Doraiswamy PM, Potts J, Axelson D, et al. MR assessment of pituitary gland morphology in healthy volunteers: age and gender-related differences. *AJNR Am J Neuroradiol* 1992;13:1295–1299

Characteristic MR Imaging of the Trichilemmal Cyst

I reported on MR imaging of the trichilemmal cyst, a rare benign tumor of the scalp, and stated that T1-weighted images were useful for differential diagnosis between the trichilemmal and the epidermoid cyst (1). I wish to report MR imaging of another case of trichilemmal cyst. A 68-year-old woman was admitted with a tumor of the left parietal scalp, 20 × 20 × 20 mm. MR revealed an isointense cyst on T1-weighted images, which appeared to be "in the grip of two crab claws" (lipid-rich subcutis) (Fig 4). The cyst was removed and pathologic exam showed a trichilemmal cyst with typical features of trichilemmal keratinization (2).



Fig 4. Trichilemmal cyst of the scalp. The sagittal scan of MR image, spin-echo 500/40, shows an isointense mass in the left parietal scalp, "in the grip of two crab claws" (*arrows*).

The trichilemmal cyst is derived from the outer hair root sheath of the hair follicular isthmus (2). The MR findings of this trichilemmal cyst show an isointense lesion on T1-weighted images. These findings suggest the organ of origin. For example, the epidermoid cyst is derived from epidermis, and the trichilemmal cyst is derived from hair follicles. Isointensity on T1-weighted images is unique to the trichilemmal cyst, and the T1-weighted images distinguish it from other cutaneous keratinizing cysts.

Naoto Adachi
Kokura Memorial Hospital
Kitakyushu, Fukuoka, Japan

References

1. Adachi N, Yamashita T. Trichilemmal cyst of the scalp: MR imaging. *AJNR Am J Neuroradiol* 1989;10:423–424
2. Pinkus H. Sebaceous cysts are trichilemmal cysts. *Arch Dermatol* 1969;99:544–555

Cost-effectiveness of High-Contrast-Dose MR Screening of Asymptomatic Brain Metastasis

We appreciate very much Dr William C. Black's in-depth review (1) of our recent article "Cost-effectiveness of High-Dose MR Contrast Studies in the Evaluation of Brain Metastasis" (2) and the important issues he ad-

dresses in his commentary. We certainly agree and continue to emphasize that the patient population and the method used in our study has many limitations that may have affected the outcome of our cost-effectiveness analysis. Our results have to be treated as preliminary data that require further studies to be confirmed. On the other hand, our limited data did suggest that the high-dose studies may be cost-effective in a selected group of patients with symptoms suggestive of brain metastasis.

We would like to respond to the valid issue raised by Dr Black with regard to the possibility of an increase in cost caused by the improved detection rate of brain metastasis in *asymptomatic* patients with newly diagnosed primary cancers. Because our data did not involve asymptomatic patients, we cannot judge this issue in a scientific manner. However, we do wish to make the following comments.

1. The increased detection rate of brain metastasis in asymptomatic patients may not always increase the cost of treatment. If asymptomatic brain metastasis is found early, particularly at the time of the diagnosis of the primary cancer, the patient is unlikely to benefit from a radical surgical resection of the *primary cancer*. In such an instance, the avoidance of surgery to resect a primary cancer can be cost-effective. In addition, there may be fewer treatment-associated complications. For example, in a patient with newly diagnosed lung cancer, palliative radiation therapy to the lung may be substituted for thoracotomy if brain metastasis is found. The reported mortality rate for thoracotomy with pneumonectomy is 6.2% (3), whereas mortality from lung irradiation is extremely uncommon. The therapeutic cost based on the fee schedule at our institution is in the range of $23200 for thoracotomy and $5300 for lung irradiation.
2. The treatment of brain metastasis found through *early* detection may not always cost more. If asymptomatic brain metastasis is diagnosed earlier because of improved diagnostic techniques, the additional cost for treatment may only be incurred at a different time (earlier) in the course of the patient's disease. Asymptomatic brain metastasis may still need treatment later when the patient becomes symptomatic. The cost of treatment may indeed be lower in some cases if the brain metastasis is treated early. For example, a patient with hydrocephalus caused by a large lesion may require more extensive surgical intervention to alleviate symptoms and prolong life. If such a lesion is detected earlier when it is smaller and asymptomatic, it may require less extensive intervention (ie, less morbidity and lower cost).
3. Although these economic considerations are extremely difficult to quantify in the absence of a well-controlled study, the potential for cost savings does exist when the management of both the brain metastasis and the *primary* cancer is taken into account. Again, these considerations only illustrate the point so well taken by Dr Black and also addressed in our article: that proper patient selection is crucial if high-dose studies are to be beneficial to the overall treatment of the patient. This may also result in cost savings. However, we must not forget that patient benefit, and not just cost containment, has to remain our primary goal.

Nina A. Mayr
David H. Hussey
Division of Radiation Oncology

William T.C. Yuh
Divisions of MRI and Neuroradiology

Department of Radiology
University of Iowa Hospitals and Clinics
Iowa City

References

1. Black WC. High-dose MR in the evaluation of brain metastases: will increased detection decrease costs? *AJNR Am J Neuroradiol* 1994; 15:1062–1064
2. Mayr NA, Yuh WTC, Muhonen MG, et al. Cost-effectiveness of high-dose MR contrast studies in the evaluation of brain metastases. *AJNR Am J Neuroradiol* 1994;15:1053–1061
3. Ginsberg RJ, Hill LD, Eagan RT. Modern thirty-day operative mortality for surgical resection in lung cancer. *J Thorac Cardiovasc Surg* 1983;86:654–658

Reply

I appreciate the letter by Mayr et al and the opportunity to elaborate on the cost-effectiveness of screening asymptomatic cancer patients with high-dose MR.

I agree with their assertion that high-dose MR may not *always* increase the cost of patient treatment. As they point out, the detection of brain metastases might exclude some patients from radical resection of their primary cancer, and the early detection of brain metastases in other patients might decrease the cost of their craniotomies. However, I expect that Mayr et al would also agree with the assertion that increased detection would not always *decrease* the cost of management. Most patients would receive additional contrast, and some might receive one or more additional craniotomies.

The real question is whether high-dose MR would be cost-effective (1, 2) for screening asymptomatic cancer patients as a group. As with screening in general, the answer depends on how these patients are selected and how the screening tests are interpreted with regard to further diagnostic evaluation and treatment. It is probable that, among the innumerable possible strategies of patient selection and MR interpretation, there exists a small subset of strategies that are cost-effective. However, it is unlikely that this subset would be identified or adhered to in the existing health care environment. Outside the setting of a randomized clinical trial, there is no reliable method for evaluating the effect of screening on the outcome of asymptomatic patients. The physician's perception of effectiveness is distorted by biases associated with early

diagnosis (3) and upward stage migration (4). In addition, the physician's behavior is constrained by patient expectations, fee for service reimbursement, and the threat of malpractice. These influences on perception and behavior tend to lower the referring clinician's threshold for testing, the radiologist's threshold for recommending further diagnostic evaluation, and the specialist's threshold for aggressive treatment. Consequently, screening strategies that are not clearly defined with regard to patient selection, interpretation, and treatment tend to evolve in the direction of doing more than is necessary and effective.

Thus, I agree with Mayr et al that there may be some potential for high-dose MR screening to be cost-effective in asymptomatic cancer patients. However, I would not expect this potential to be realized in the existing health care environment.

William C. Black
Department of Diagnostic Radiology
Dartmouth-Hitchcock Medical Center
Lebanon, NH

References

1. Doubilet PM, Weinstein MC, McNeil BJ. Use and misuse of the term "cost effective" in medicine. *N Engl J Med* 1986;314:253–255
2. Black WC. The CE plane: a graphical representation of cost effectiveness. *Med Decis Making* 1990;10:212–214
3. Black WC, Welch HG. Advances in diagnostic imaging and overestimations of disease prevalence and the benefits of therapy. *N Engl J Med* 1993;328:1237–1243
4. Feinstein AR, Sosin DM, Wells CK. The Will Rogers phenomenon: stage migration and new diagnostic techniques as a source of misleading statistics for survival in cancer. *N Engl J Med* 1985;12: 1604–1608

Flow Phenomena in a Cystic Basal Ganglia Structure Do Not Rule Out a Lacunar Infarct

Hirabuki et al (1) increased our understanding of the MR appearance of physiologic perivascular spaces in the cerebral deep gray matter. In addition to the iconography of the standard pulse sequences, they proposed that flow-sensitive imaging could be exploited to demonstrate a lenticulostriate artery within the dilated space and thereby assist in distinguishing between a dilated perivascular space and a lacunar infarct. They stated, "For such instances, the flow-sensitive FLASH [fast low-angle shot] sequence, which can demonstrate the presence of perforating arteries within such foci, may help confirm Virchow-Robin spaces."

We would like to call to the reader's attention that on histologic examination (2) many of the larger (10 mm^3 in volume) lacunes have an intact lenticulostriate artery passing through the center or in the wall of the infarct cavity (Fig 5A). We found that more than 90% of lacunes result from occlusion or stenosis of the second- and third-order branches from the major lenticulostriate arteries (2). These branches do not arborize in the fashion of a spreading oak tree but have the appearance of a Lombardy poplar tree, running parallel to and in some cases wrapping around the parent vessel. At histologic section the larger lacunar infarcts are flame-shaped and surround or run adjacent to a major lenticulostriate artery. The parent artery often continues through the infarct cavity to supply normal brain. We caution that observation of flowing blood of a large vessel in a basal ganglia cystic structure may not rule out the presence of a lacunar infarct on the basis of that information alone. We do agree with the authors that proximity to the basal (pial) surface favors a dilated perivascular space, whereas holes located more superiorly tend to be lacunes. Histologic examination almost always resolves the issue decisively by showing necrotic debris, macrophages, and surrounding gliosis in the case of lacunar infarcts (Fig 5B).



Fig 5. Bare artery in a basal ganglia lacune.

A, Microradiograph of a 500-μm-thick section of the left cerebral hemisphere with alkaline phosphatase staining of the afferent microvasculature. The markedly radiolucent cavity (*large arrow*) has irregular walls. Lacunar softening (*small arrows*) is less radiolucent in this radiograph, because it has had insufficient time to cavitate. Note the smooth perivascular space surrounding the vessel (*arrowhead*) as it passes upward into normal brain (original magnification $\times$5).

B, Photomicrograph of a 100-μm-thick celloidin alkaline phosphatase-stained section from the same lacune. The parent artery, seen in cross-section, has only minimal luminal narrowing caused by hyaline thickening of the tunica media (*arrow*). The outer diameter of the lenticulostriate artery in the cavity measures 170 μm, and there is approximately 20% linear tissue shrinkage. In life the vessel would be somewhat distended by flowing blood. Glial strands, small vessels, and clusters of inflammatory cells and macrophages span the cavity (original magnification $\times$10; cresyl violet acetate and light green counterstain).

Figure 5A illustrates a lacunar infarct *cavity* with a bare artery running through it. More superiorly, adjacent to the lenticulostriate artery, an area of lacunar *softening* is an infarct that has not had time to cavitate. The former should have MR signal characteristics of cerebrospinal fluid, whereas the latter should have a higher signal than cerebral spinal fluid on proton density- and T1-weighted sequences. The main artery, which is only mildly arteriosclerotic, continues superiorly to supply normal brain and likely would show evidence of flow on appropriate flow-sensitive MR images.

Dixon M. Moody
Department of Radiology and Program in Neuroscience

Venkata R. Challa
Departments of Pathology and Radiology

Vincent P. Mathews
Department of Radiology

Bowman Gray School of Medicine of
Wake Forest University
Winston-Salem, NC

References

1. Hirabuki N, Fujita N, Fujii K, Hashimoto T, Kozuka T. MR appearance of Virchow-Robin spaces along lenticulostriate arteries: spin-echo and two-dimensional fast low-angle shot imaging. *AJNR: Am J Neuroradiol* 1994;15:277–281
2. Challa VR, Bell MA, Moody DM. A combined hematoxylin-eosin, alkaline phosphatase and high-resolution microradiographic study of lacunes. *Clin Neuropathol* 1990;9:196–204

Reply

I greatly appreciate the careful reading that Dr Moody and his colleagues have given our article on MR imaging of Virchow-Robin spaces.

In our article we demonstrated that a flow-sensitive FLASH sequence shows lenticulostriate arteries in most Virchow-Robin spaces identified on spin-echo images. At the same time we stated that the demonstration of the arteries was not perfect because of their small size. Actually the in-plane voxel areas in our study were 0.8×1.1 mm despite the fact that the diameters of the arteries usually do not exceed 0.4 mm. In addition, the demonstration is dependent not only on the voxel size but also on substantial flow in the arteries. In my opinion, despite the considerable effects of flow, the sensitivity of our technique approaches the limit, even in lenticulostriate arteries with normal flow.

I agree that many larger lacunes have an intact lenticulostriate artery passing through the center or in the wall of the infarct cavity. However, the patency does not exclude any arteriosclerotic changes of the vessel. In subjects with lacunar infarcts, the parent arteries passed through the lacunes and showed variable degrees of pathologic changes including tortuosity, medial hyalization, intimal hyperplasia, and intimal collections of foam cells (1). All of those changes would diminish the inflow effect in the arteries and obscure their presence on flow-sensitive MR images.

It is reasonable to think that lenticulostriate arteries associated with lacunar infarcts have more arteriosclerotic changes than those without them. Thus, the clear demonstration of a lenticulostriate artery indicates that the artery is probably free from significant arteriosclerotic changes and eventually raises the probability that the surrounding cystic structure is a Virchow-Robin space. At which size normal and arteriosclerotic lenticulostriate arteries can be demonstrated on optimal flow-sensitive MR images is a pending and intriguing problem.

Norio Hirabuki
Department of Radiology
Ohta-Nishinouchi Hospital
Koriyama, Japan

Reference

1. Challa VR, Bell MA, Moody DM. A combined hematoxylin-eosin, alkaline phosphatase and high-resolution microradiographic study of lacunes. *Clin Neuropathol* 1990;9:196–204

Comment

Drs Moody et al and Hirabuki present interesting albeit somewhat opposing views regarding the potential reliability of using MR demonstration of flow in lenticulostriate arteries to differentiate between lacunar infarcts and dilated perivascular spaces as outlined in the paper by Hirabuki et al. Dr Moody correctly points out that in some cases of lacunar infarcts, a patent lenticulostriate artery without significant atherosclerotic changes can be seen microscopically to pass through the infarct cavity. This would presumably result in an incorrect diagnosis of dilated perivascular space using flow detection as the criterion for differentiation. Dr Hirabuki, on the other hand, replies that in his experience atherosclerotic changes exist even within the residual patent lenticulostriate arteries and that these changes are presumably sufficient to slow flow to the point where it is not visible with their flow-sensitive sequences. Therefore they feel that the correct diagnosis of lacunar infarct can be made even in the presence of patent lenticulostriate arteries. This controversy cannot be resolved based on the available data at this time.

Dr Moody raises a good point, although presumably this scenario may be present in only a minority of patients. The report by Dr Hirabuki does not include any patients with lacunar infarcts to test their theory, but clearly the phenomenon of flow demonstration within Virchow-Robin spaces is not 100% ("On FLASH images, most Virchow-Robin spaces . . . were delineated as high intensity foci . . .", p 278). The major limitation, however, to resolving this controversy is the absence of MR-pathologic correlation. Also, Dr Hirabuki's study relied on morphologic MR

criteria to confirm the diagnosis of dilated perivascular spaces. This itself is a potential pitfall because MR criteria for distinguishing these two entities are limited, as all practicing neuroradiologists are aware. Indeed, if such criteria were reliable, then there would be no need for Dr Hirabuki's study.

I commend Dr Hirabuki and colleagues for introducing a new concept that may eventually prove useful. However, more work is needed to document the accuracy of this technique. Comparison between a series of young (less than 50 years old) healthy subjects and a group of patients with lacunar infarcts documented by clinical criteria and by observation of a new infarct cavity over time is needed to provide more objective assessment. This would result in better estimation of the true specificity of this diagnostic technique. I hope that the comments generated from Dr Hirabuki's innovative work stimulate further investigation in this important area.

Kenneth R. Maravilla
Department of Radiology
University of Washington
Seattle

Xenon CT Cerebral Blood Flow: Past, Present, and Future

We share the opinion of Joseph M. Eskridge that medical technologies must prove their clinical utility while being cost-effective in order to earn a place in the future of American health care. However, we do not agree with many of the other conclusions he presented in his commentary, "Xenon-enhanced CT: Past and Present" (1). The commentary was a response to our article (2), which described the use of xenon-enhanced CT blood flow information in conjunction with balloon test occlusion to assess the risk of stroke after carotid occlusion. While his thoughts wandered far afield from our article, he failed to understand the conclusions of the paper, the significance of the underlying physiology, or the past or current facts about xenon CT cerebral blood flow (CBF).

The point of our paper was that we were able to avoid life-threatening infarctions by restricting carotid sacrifice without reconstructive vascular surgery to 33 patients who both passed balloon test occlusion based on clinical examination *and* maintained flow values above 30 mL/100 g per minute in the ipsilateral middle cerebral territory. Only one (3%) person had a long-term, mild deficit. Although three (9%) patients had CT-defined border-zone infarctions on late imaging, these were significantly smaller and more peripheral than the massive infarctions commonly encountered after indiscriminate acute carotid sacrifice. The small size and distal location of the strokes in our series also suggests that compromised perfusion rather than emboli played a causal role. The fact that all three strokes occurred in patients who underwent direct intracranial carotid occlusion during skull base surgery also suggests that preoperative balloon test occlusion may not adequately test the tolerance for intraoperative occlusion while retractors are elevating the brain from the skull base.

Rather than accepting Dr Eskridge's conclusion that it is time to stop using studies of CBF to define the risk of carotid sacrifice better, we are more inclined to use our preliminary results to improve on our already very positive experience. First, we believe that the best approach is not to perform vascular reconstruction with every carotid sacrifice nor to ignore the subgroup of patients who have drops in flow to near ischemic levels and proceed to sacrifice, simply accepting a 5% to 10% (often massive) stroke rate as the "price of doing business." A selective application of vascular reconstruction for the 10% to 15% of patients who display a significant hemodynamic compromise with temporary carotid occlusion is more rational. For persons who failed balloon test occlusion (one by clinical and seven by flow criteria), we have had no complications with proceeding to internal carotid occlusion immediately after establishing a superficial temporal to middle cerebral artery bypass. Second, we may be able to lessen the incidence of border-zone infarctions by either raising the flow threshold for contraindicating direct carotid occlusion and/or by integrating an assessment of borderzone and deep white-matter flow changes into the decision process. Third, preoperative balloon test occlusion should not be expected to test the tolerance for direct intracranial carotid occlusion under two circumstances: while a retractor is pushing against the brain and when additional vessels from those tested need to be closed (ie, opthalamic artery occlusion in conjunction with internal carotid artery occlusion).

Dr Eskridge's comments concerning the history of xenon CT CBF also indicates that he has little understanding of the past and present status of this technology. Xenon CT CBF was, in fact, never "intensely pursued," actively supported, or marketed by any CT manufacturer. Perhaps because of its low cost of acquisition and low cost per study, it was never given a high priority or even properly supported by manufacturers, who were concurrently selling far more expensive technologies such as single-photon emission CT and positron emission tomography. Although it has taken a decade to resolve the theoretical concerns about both the quantitative capacity and safety of xenon CT CBF, these issues were resolved in the early 1990s (3, 4). With the transfer of this technology to smaller, dedicated companies that have created modern, free-standing systems that can be used with any CT scanner, xenon CT CBF has become a fast, relatively simple, low-cost means of acquiring quantitative CBF information. Helical scanners have also made it possible to scan 10 or more levels within the same 4.3 minutes of xenon inhalation.

Although xenon CT CBF studies are time consuming in comparison with standard CT imaging, an entire xenon CT CBF study requires only 6 additional minutes when added to a standard CT study. Compared with the time required to perform xenon-133, single-photon emission CT, or positron emission tomography studies, the time required for a xenon CT study is, in fact, remarkably brief. Xenon CT CBF also differs from these other studies by providing

direct anatomic reference, high-resolution quantitative CBF information, and integration of the partition coefficient into the calculation of flow. The latter fact means that xenon CT-derived flow values are uniquely reliable, even in disease states. Because xenon CT CBF studies can be repeated at 20-minute intervals, the cerebrovascular reserve capacity or the CBF response to proposed therapeutic interventions can be readily examined (3, 5, 6).

Although it is clear that the time is upon us for critical assessment of technologies, it is vital that those who review these issues be knowledgeable of all options and unbiased by past or present experience with any one technology. The appropriate question is whether any technology that measures CBF can aid the critical decision making during the initial hours or days after common disorders such as aneurysmal subarachnoid hemorrhage, ischemic stroke, or head trauma. Xenon CT CBF studies have provided clinically useful information in all of these areas (3, 7, 8).

In the coming years, we must be careful not to come to the blind conclusion, along with our bureaucratic associates, that technology is bad and its access needs to be constrained. Everything we have learned from neurologic imaging tells us differently. The future of neuroradiology, in part, depends on its ability to broaden its horizon into related areas that make radiologists even more vital contributors to clinical decision making. Xenon CT is one CBF technology that does have direct clinical application and, we believe, has earned a place in the cost-effective, technologically advanced future of medicine. We agree with Dr Eskridge that we must carefully choose our technologies so that the bureaucrats of the present and future do not throw out the "baby with the bath water."

Howard Yonas
Department of Neurosurgery

Charles Jungreis
Department of Neuroradiology

University of Pittsburgh (Penn)
School of Medicine

References

1. Eskridge JM. Xenon-enhanced CT: past and present. *AJNR Am J Neuroradiol* 1994;15:845–846
2. Linskey ME, Jungreis CA, Yonas H, et al. Stroke risk after abrupt internal carotid artery sacrifice: accuracy of preoperative assessment with balloon test occlusion and stable xenon-enhanced CT. *AJNR Am J Neuroradiol* 1994;15:829–843
3. Johnson DW, Stringer WA, Marks MP, Yonas H, Good WF, Gur D. Stable xenon CT cerebral blood flow imaging: rationale for and role in clinical decision making. *AJNR Am J Neuroradiol* 1991;12: 201–213
4. Nemati M-N, Dietz H, Holl K, et al. Concomitant effect of acetazolamide and xenon on cerebral blood flow, intracranial, pressure, flow velocity, and electroencephalogram: Possible risk for the patient? In: Yonas H, ed. *Cerebral Blood Flow Measurement with Stable Xenon-Enhanced Computed Tomography*. New York: Raven Press, Ltd, 1992:296–304
5. Tarr RW, Johnson DW, Rutigliano M, et al. Use of acetazolamide-challenge xenon CT in the assessment of cerebral blood flow dynamics in patients with arteriovenous malformations. *AJNR Am J Neuroradiol* 1990;11:441–448
6. Yamashita T, Hayashi M, Kashiwagi S, et al. Cerebrovascular reserve capacity in ischemia due to occlusion of a major arterial trunk: studies by Xe-CT and the acetazolamide test. *J Comput Assist Tomogr* 1992;16(5):750–755
7. Segawa H, Wakai S, Tamura A, Yoshimasu N, Nakamura O, Ohta M. Computed tomographic measurement of local cerebral blood flow by xenon enhancement. *Stroke* 1983;14:356–362
8. Touho H, Karasawa J, Ohnishi H, Shishido H, Yamada K, Shibamoto K. Evaluation of therapeutically induced hypertension in patients with delayed cerebral vasospasm by xenon-enhanced computed tomography. *Neurol Med Chir* (*Tokyo*) 1992;32: 671–678

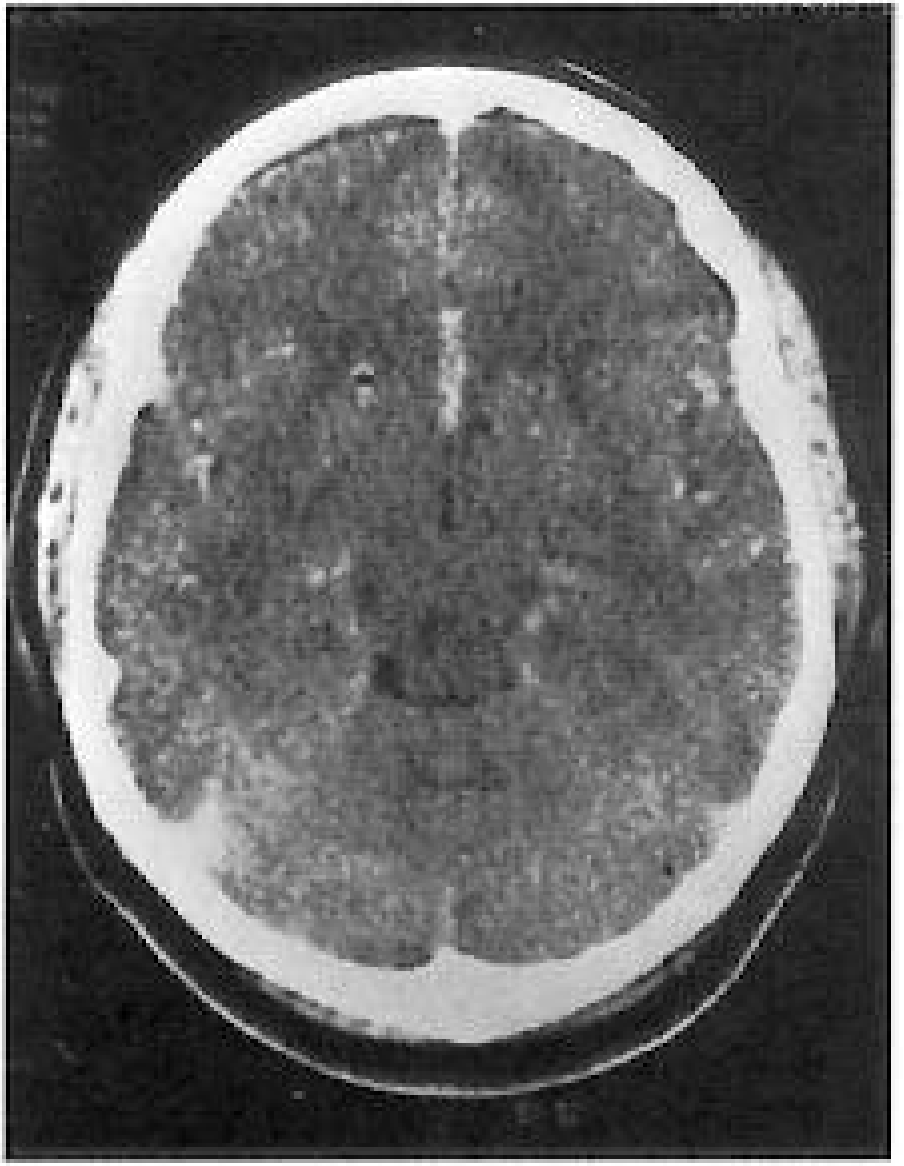

1

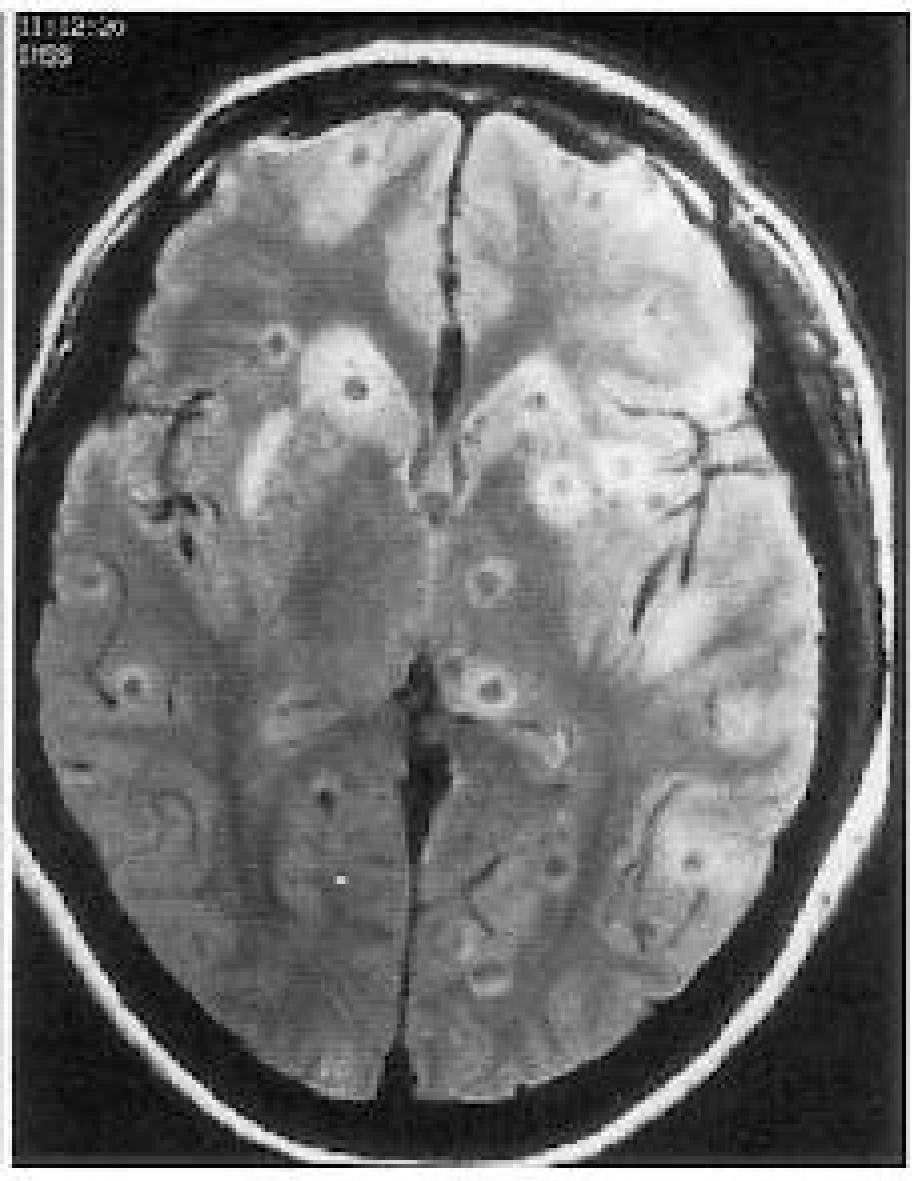

2

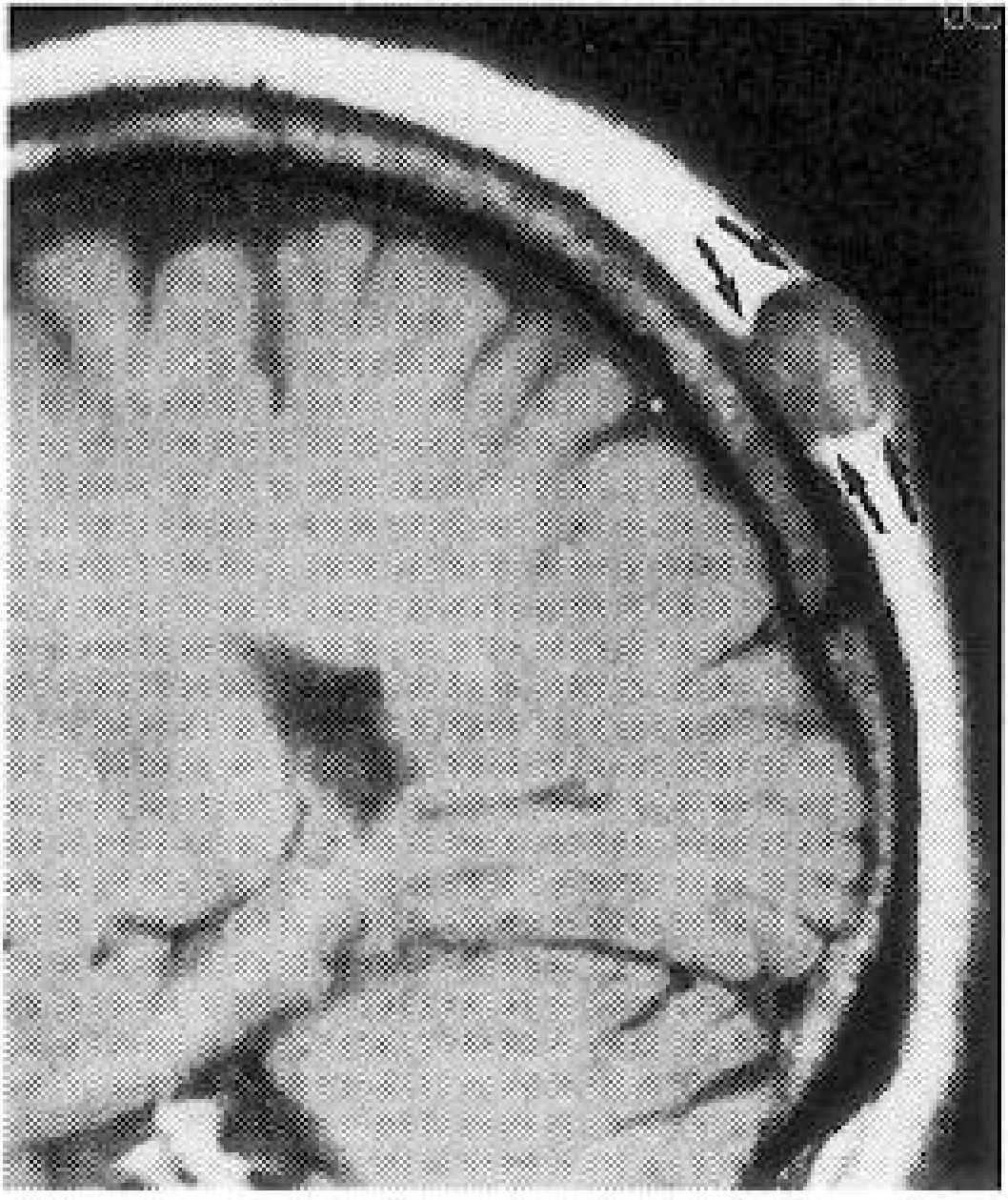

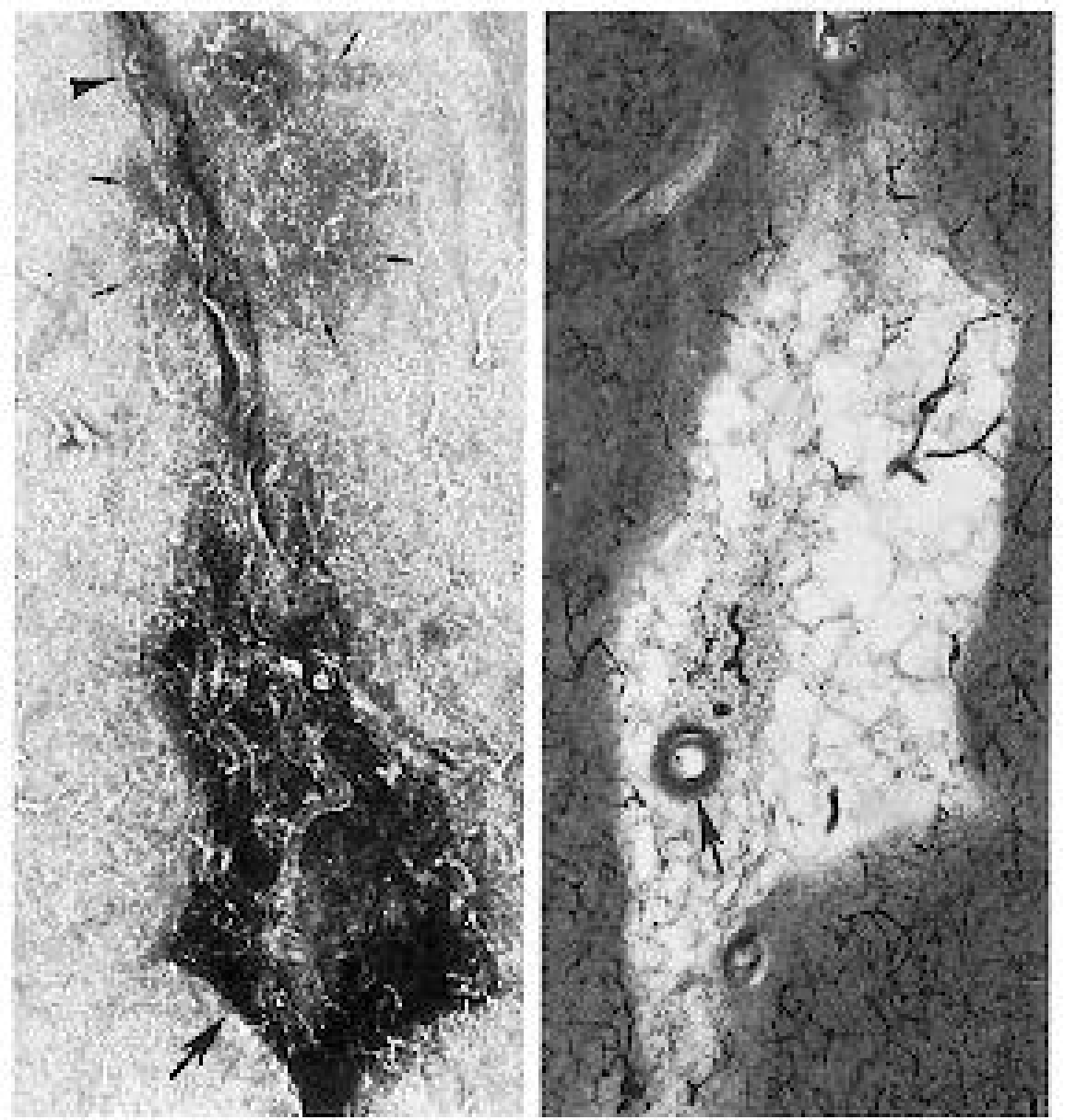

A

B