
Inhaled Oxygen: A Brain MR Contrast Agent?

Yves Berthezène, Philippe Tournut, Francis Turjman, Roger N'Gbesso, Béatrice Falise, and Jean Claude Froment

Summary: Oxygen inhalation led to subtle but readily detectable changes on T2*-weighted images with a conventional MR imager at 1.5 T. We attribute the increase in local signal intensity to changes in blood oxygenation, in particular to a net conversion of deoxyhemoglobin to oxyhemoglobin.

Index terms: Brain, magnetic resonance; Magnetic resonance, contrast enhancement; Oxygen

Blood is a unique source of physiologic contrast in magnetic resonance (MR) imaging because of its oxygenation sensitive paramagnetic characteristics. The erythrocyte contains a high concentration of hemoglobin iron, which changes spin state from diamagnetic low spin in the oxygenated state to high spin in the deoxygenated state (1). Deoxygenation increases the volume magnetic susceptibility within the erythrocyte and thus creates local field gradients around these cells, leading to a decreased signal intensity (2, 3).

The aim of this study was to evaluate the potential of inhaled oxygen as a brain MR contrast agent. We hypothesized that changes in blood oxygenation induced by inhaled oxygen would lead to a net conversion of deoxyhemoglobin to oxyhemoglobin and thus to an increase in local signal intensity.

Materials and Methods

MR imaging was performed with a superconductive unit at 1.5 T with a standard circular head coil. Axial multisection T1-weighted images were obtained (600/15/1 [repetition time/echo time (TE)/excitations], 256 × 256 matrix, section thickness 7 mm, field of view 250 mm). With the use of these images as an anatomic guide, an appropriate axial tilted plane above the ventricular and sinus structures was selected. For the dynamic susceptibility-enhanced oxygen MR imaging, the selected plane was imaged with a fast low-angle shot (FLASH) sequence (91/60/1, pulse angle 40°, 128 × 128 matrix), with the same field of view

and section thickness as in the corresponding anatomic image. The acquisition time of each image was 14 seconds with a delay of 1 second between each image. Twenty FLASH images were acquired with the patient breathing surrounding air, followed by 20 images with the patient breathing pure oxygen at a flow rate of 5 or 10 L/min. This procedure was repeated two times, so that a total of 80 images was obtained over a period of 1200 seconds. Experiments were done on 10 healthy volunteers.

In four volunteers, a range of flip angles (10°, 20°, 30°, and 40°) at a constant TE (60 milliseconds) and a range of TEs (10 and 60 milliseconds) at a constant flip angle (40°) was tested in ambient air and during oxygen inhalation (10 images during air inhalation followed by 10 images during oxygen inhalation). In three other volunteers the images were acquired with a T1-weighted turbo-FLASH sequence consisting of a nonselective 180° pulse followed by a sequential (ie, nonsegmented) image acquisition (6.5/3.5, inversion time 300, 128 × 128 matrix, section thickness 7 mm, field of view 250 mm). The acquisition time of each image was 1 second with a delay of 1 second between each image. Twenty images were acquired with the patient breathing surrounding air, followed by 20 images with the patient breathing pure oxygen (10 L/min).

In a parallel experiment, arterial blood oxygenation, heart rate, and systolic and diastolic blood pressures were monitored with an oxymeter (Satlite Trans, Datex, Helsinki, Finland) in seven volunteers (same individuals that were studied by the T2* techniques) breathing air or pure oxygen (10 L/min).

The dynamic images were analyzed by measuring signal intensities over regions of interest. Global signal intensities were measured across the entire brain section and the right and left hemispheres. Regional signal intensities of at least 10 pixels were also measured in the cerebral gray matter, cerebral white matter, and longitudinal sinus. The region-of-interest boundaries were selected on the anatomic axial image. The percentages of maximum enhancement (MaxEn[%]) were calculated as follows: $\text{MaxEn}(\%) = \frac{(\text{SI}_{\text{post}} - \text{SI}_{\text{pre}})}{\text{SI}_{\text{pre}}} \times 100$, where SI_{post} is the signal intensity during the oxygen inhalation, and SI_{pre} is the signal intensity before oxygen inhalation. Statistical analyses of the enhancement data were performed

Received September 12, 1994; accepted after revision January 17, 1995.

From Hôpital Neurologique et Neurochirurgical, Lyon (Y.B., P.T., F.T., R.N., J.C.F.), and Siemens, Paris (B.F.), France.

Address reprint requests to Yves Berthezène, MD, PhD, Service de Radiologie, Hôpital Neurologique et Neurochirurgical, 59 Blvd Pinel, 69003 Lyon, France.

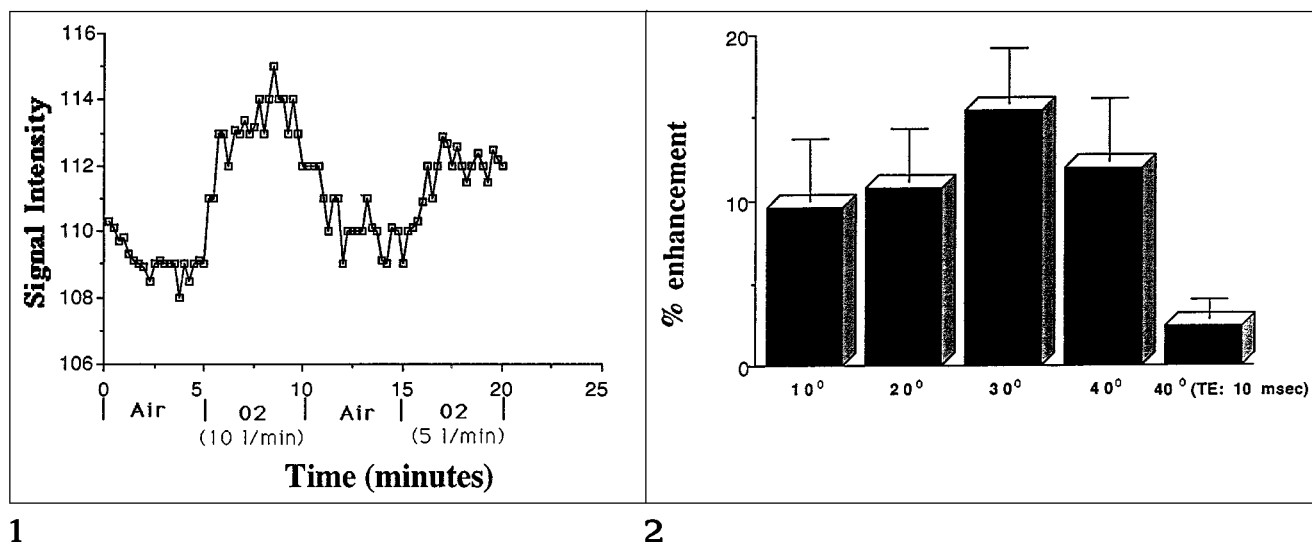


Fig 1. Signal-intensity changes (one volunteer) measured across the entire brain section during oxygen inhalation (10 and 5 L/min) on a T2*-weighted image (FLASH, 91/60, pulse angle 40°). The acquisition time of each image was 14 seconds with a delay of 1 second between each image.

Fig 2. Mean enhancement in the longitudinal sinus obtained with 10°, 20°, 30°, and 40° flip angles (TE of 60; n = 4), and with a TE of 10 milliseconds (flip angle 40°).

with a paired *t* test between each consecutive time point. Statistical significance was defined as $P < .05$.

Results

Before oxygen inhalation, the signal intensity across the entire brain section was stable with no statistical difference between the right and left hemispheres. During oxygen inhalation (10 L/min) signal intensity on FLASH T2*-weighted images increased significantly ($3.17\% \pm 1.32\%$) with no statistical difference between the two lobes. This change in contrast was reversible when the oxygen inhalation was stopped (Fig 1). The maximum enhancement was seen in blood vessels such as the longitudinal sinus ($14.7\% \pm 8.04\%$). The enhancement in the gray matter ($4.23\% \pm 1.94\%$) was significantly greater than that the white matter ($1.92\% \pm 1.28\%$). The enhancement was significantly higher with an oxygen flow rate of 10 L/min ($3.17\% \pm 1.32\%$) than with a flow rate of 5 L/min ($2.12\% \pm 1.43\%$) (Fig 1).

Little difference was seen in brain enhancement during oxygen inhalation achieved with flip angles of 10° to 40°; however, a larger flip angle tended to give the larger enhancement (Fig 2). The maximum enhancement was seen with a flip angle of 30°. The results demonstrate that the enhancement measured with a TE of 60 milliseconds was significantly higher than with a

TE of 10 milliseconds ($P < .05$). T1-weighted turbo-FLASH images demonstrate no significant signal intensity changes during oxygen inhalation. Inhalation of oxygen (10 L/min) produces a significant increase in oxygen arterial saturation (from $98.18\% \pm 0.77\%$ to $99.09\% \pm 0.46\%$; $P < .05$) with no changes in heart rate (from 74.9 ± 12.5 beats per minute to 74 ± 13.9 beats per minute), or systolic (from 12 ± 1.3 mm Hg to 11.9 ± 1.3 mm Hg) or diastolic (from 7.9 ± 0.8 mm Hg to 7.7 ± 0.5 mm Hg) arterial pressure.

Discussion

The data show that oxygen inhalation led to subtle but readily detectable changes on T2*-weighted images with a conventional MR imager operating at 1.5 T. We attribute the increase in local signal intensity to changes in blood oxygenation, in particular to a net conversion of deoxyhemoglobin to oxyhemoglobin. As hemoglobin becomes deoxygenated, it becomes more paramagnetic than the surrounding tissue and thus creates a magnetically inhomogeneous environment. Under normoxic conditions arterial blood is nearly fully oxygenated and should not contribute to blood oxygenation level-dependent contrast, whereas venous blood vessels containing more deoxygenated blood should contribute to the

image contrast. In our study, venous hemoglobin saturation was not measured, but the small increase in arterial hemoglobin saturation during the inhalation of oxygen suggests higher modification in venous blood.

With a single-section technique, one might expect to see an increase in signal intensity because of flow of unsaturated spins into the section during oxygen inhalation. If the inflow of unsaturated spins were a significant contributor to brain enhancement, one would expect a decrease in enhancement with a decreased flip angle. In our study, the enhancement during oxygen inhalation tended to be slightly (but not significantly) greater with larger flip angles. This finding supports the concept that inflow effects may contribute minimally to the brain enhancement during oxygen inhalation. However, the greater enhancement obtained with a TE of 60 milliseconds than with a TE of 10 milliseconds suggests that the major effect of oxygen inhalation is a T2* effect. Longer TEs allow more time for intravoxel dephasing to occur between excitation and readout and thus produce a greater enhancement.

Inhaled oxygen seemed to enhance brain structures proportionally to their blood volume. The maximum enhancement was seen in blood vessels such as the longitudinal sinus ($14.7\% \pm 8.04\%$). Furthermore, the enhancement in the gray matter ($4.23\% \pm 1.94\%$) was significantly greater than that in the white matter ($1.92\% \pm 1.28\%$). It is well established that the ratio of cerebral blood volume in gray and white matter is approximately 2 (4). The brain enhancement was significantly higher with an oxygen flow rate of 10 L/min ($3.17\% \pm 1.32\%$) than with a flow rate of 5 L/min ($2.12\% \pm 1.43\%$). Previous studies have shown an approximately linear relationship between the T2* rate change produced by a paramagnetic contrast agent and the concentration of the agent within the brain (5, 6). Further studies will be necessary to confirm this relationship with blood oxygenation level-dependent contrast.

The stable signal intensities on turbo-FLASH T1-weighted images during oxygen inhalation suggest a nearly stable concentration of free oxygen in blood. Because oxygen is paramagnetic because of its two unpaired electrons, increasing the oxygen concentration causes a decrease in T1 (7). However free oxygen in blood

represents less than 0.3% and is not significantly modified by oxygen inhalation until the hemoglobin is fully saturated. Although deoxyhemoglobin is paramagnetic, it does not cause significant T1 shortening. Because the electron spin relaxation time of deoxyhemoglobin is very short, and because water molecules are unable to approach the heme iron within a distance of 3 Å, the T1 of an aqueous solution of deoxyhemoglobin is not short (8).

There are several potential pitfalls to the method. First, because the sequence is T2* weighted, it is sensitive to susceptibility artifacts created by the paranasal sinuses and petrous ridges. Second, in our study only a single section could be imaged with high temporal resolution. The third and greatest limitation of the dynamic susceptibility-enhanced oxygen MR imaging is the slight brain enhancement induced by oxygen inhalation. The method we demonstrated here is noninvasive, allowing repetitive measurements on a single subject and development and clinical trials of dynamic susceptibility-enhanced oxygen MR imaging. Further validation of this atraumatic technique could lead to significant improvements in diagnosis and treatment of disease related to perfusion and oxygen uptake abnormalities, such as hyperacute stroke.

References

1. Thulborn KR, Waterton JC, Matthews PM, Radda GK. Oxygenation dependence of the transverse relaxation time of water protons in whole blood at high field. *Biochim Biophys Acta* 1982;714:265-270
2. Ogawa S, Lee TM, Nayak AS, Glynn P. Oxygenation-sensitive contrast in magnetic resonance image of rodent brain at high magnetic fields. *Magn Reson Med* 1990;14:68-78
3. Ogawa S, Lee TM, Kay AR, Tank DW. Brain magnetic resonance imaging with contrast dependent on blood oxygenation. *Proc Natl Acad Sci USA* 1990;87:9868-9872
4. Greenberg JH, Alavi A, Reivich M, Kuhl D, Uzell B. Local cerebral blood volume response to carbon dioxide in man. *Circ Res* 1978;48:324-331
5. Majumdar S, Zoghbi S, Pope CF, Gore JC. Quantitation of MR relaxation effects of iron oxide particles in liver and spleen. *Radiology* 1988;169:653-658
6. Rosen BR, Belliveau JW, Vevea JM, Brady TJ. Perfusion imaging with NMR contrast agents. *Magn Reson Med* 1990;14:249-265
7. Runge VM, Stewart RG, Clanton JA, et al. Potential oral and intravenous paramagnetic NMR contrast agent. *Radiology* 1983;147:789-791
8. Singer JR, Crooks LE. Some magnetic studies of normal and leukemic blood. *Clin Eng* 1978;3:357-363