

**Are your MRI contrast agents cost-effective?**

Learn more about generic Gadolinium-Based Contrast Agents.



**FRESENIUS  
KABI**

caring for life

**AJNR**

**Perinatal asphyxia: MR findings in the first 10 days.**

A J Barkovich, K Westmark, C Partridge, A Sola and D M Ferriero

*AJNR Am J Neuroradiol* 1995, 16 (3) 427-438

<http://www.ajnr.org/content/16/3/427>

This information is current as  
of April 18, 2024.

# Perinatal Asphyxia: MR Findings in the First 10 Days

A. James Barkovich, Kaye Westmark, Colin Partridge, Augusto Sola, and Donna M. Ferriero

**PURPOSE:** To determine whether one can detect hypoxic-ischemic brain injury by MR in the first 10 days of life and to identify patterns of injury in affected neonates. **METHODS:** Standard T1- and T2-weighted MR sequences that were performed in the first 10 days of life in 20 patients who suffered hypoxia/ischemia in the intrapartum or neonatal periods were reviewed retrospectively. Images were evaluated for patterns of signal changes. **RESULTS:** Four patients had normal findings and were clinically healthy. The remaining 16 patients were divided into four groups based on pattern of injury: (a) primarily deep gray matter involvement; (b) primarily cortical involvement; (c) primarily periventricular white matter injury; and (d) mixed injury pattern. Two patients had appearances that suggested prepartum injury. T1 shortening was seen in injured tissue as early as 3 days after injury. T2 shortening did not appear until 6 or 7 days after injury. **CONCLUSION:** MR can show brain damage in asphyxiated neonates during the first 10 days of life and shows early appearances of several patterns of brain injury.

**Index terms:** Asphyxia; Brain, ischemia; Infants, injuries; Magnetic resonance, in infants and children

*AJNR Am J Neuroradiol* 16:427-438, March 1995

Magnetic resonance imaging (MR) has had a large impact on the evaluation of the asphyxiated neonate. MR can show parenchymal and intraventricular hemorrhage (1-3), periventricular white matter damage (1, 4-6), and specific patterns of brain damage (7-9) in affected neonates. Most studies, however, have relied on images obtained when the infants were in the intermediate or late phase of injury, weeks to months after the asphyxic episode. Although imaging studies performed in the intermediate or late phase allow identification of injury patterns and, to some extent, prognostication of long-term outcome, they are far removed temporally from important decisions concerning

patient care. The purpose of this study was to evaluate MR studies performed during the first 10 days of life of asphyxiated neonates in order to determine whether MR imaging is sensitive to hypoxic-ischemic brain injury and can show specific patterns of injury during the early postinjury period.

## Patients and Methods

On review of our records, we found MR studies of 20 infants who were examined in the first 10 days of life for evaluation of neonatal hypoxia-ischemia. The MR studies were reviewed retrospectively and correlated with obstetrical records and neonatal clinical summaries. Four patients had normal MR findings, obtained between ages 5 days and 8 days. The birth histories and umbilical cord blood gases of these four infants did not differ noticeably from those of the 16 patients with abnormal imaging studies; they underwent MR examinations as part of a protocol related to their severe birth histories. All 4 had benign postnatal courses and were healthy at their 3-month follow-up clinical examination. In the remaining 16 patients, with whom this article will deal, MR studies were performed on day 2 in 1 patient, on day 3 in 4 patients, on day 4 in 3 patients, on day 5 in 2 patients, on day 6 in 2 patients, on day 7 in 2 patients, and on day 10 in 2 patients (Table). Twelve infants were born at term, 2 at 35 weeks of gestational age, and 2 at 32 weeks of gestational age.

---

Received June 8, 1994; accepted after revision September 2.

Partially supported by grants 1P20NS32553-01 and MO1-RR01271 from the National Institutes of Health.

From the Departments of Radiology, Neuroradiology Section (A.J.B., K.W.), and Pediatrics (A.J.B., A.S., D.M.F.), University of California San Francisco; and the Department of Pediatrics, San Francisco General Hospital (C.P.).

Address reprint requests to A. James Barkovich, MD, Neuroradiology Section, Department of Radiology, University of California San Francisco, 505 Parnassus Ave, L-371, San Francisco, CA 94143-0628.

*AJNR* 16:427-438, Mar 1995 0195-6108/95/1603-0427

© American Society of Neuroradiology

Clinical and imaging information on 16 neonates who had hypoxic-ischemic events, grouped by area of damage

Patient/Obstetric History	Postnatal Clinical Data	Blood Gas (Umbilical artery)	Apgar, 1/5/10/20 min	Age, d	MR Findings
<b>Group 1, deep structures</b>					
1/Term infant; cord prolapse; bradycardia (HR, 30–40 beats per min) for 20–25 min	Multiorgan failure seizures; recurrent bradycardia/cyanosis US normal	pH, 6.86; BD, 19	...	5	T1 shortening lateral thalamus, medial and posterior lentiform nuclei, deep periolandic cortex
2/Term infant; uterine rupture		pH, 6.7; BD, 26	1/3/4/6	5	T1 shortening lateral thalamus, medial and posterior lentiform nuclei, deep periolandic cortex
3/Term; thick meconium; bradycardia (HR, 35 beats per min) for 13 min; total cord occlusion	Seizures for 72 hrs; hypoventilation; US normal	pH, 6.67; BD, 22	1/3/. ./. . .	3	T1 shortening lateral thalamus, medial and posterior lentiform nuclei; edema PLIC; T2 shortening lateral thalamus, posterior putamen
4/Term infant; normal delivery	Cardiorespiratory arrest (for 12 min) at age 2 hrs; seizures for 48 hrs Multiorgan failure; seizures; died at day 13	prearrest pH, 7.41; postarrest, 6.7; BD, 22 pH, 6.7; PO <sub>2</sub> , 30; BD, 25	9/10/. ./. . .	3	T1 shortening lateral thalamus, medial and posterior lentiform nuclei; edema PLIC; long T2 in white matter and basal ganglia
5/34 wk; emergency cesarean section; fetal bradycardia (HR, <40 beats per min); >50% abruptio 15 min before intubation			0/0/1/2	7	Diffuse T1 and T2 prolongation in white matter; T1 shortening lateral thalamus, posterior and medial lentiform nuclei, and depth of many cortical gyri; punctate periventricular T1, T2 shortening
6/38 wk; cord rupture	Multiorgan failure; seizures; died at 6 wk	pH, 6.7; PO <sub>2</sub> , 30; BD, 21	1/4/. ./. . .	4	T1 shortening lateral thalamus, medial and posterior lentiform nuclei, deep periolandic cortex, mesencephalon, cerebellar nuclei; long T2 in basal ganglia and at gray-white matter junction of periolandic region
7/32 wk; emergency cesarean section after auto accident	Aspiration of blood; airway obstruction; US normal	pH, 6.6; BD, 24	1/3/. ./. . .	10	T1, T2 shortening globus pallidus, lateral thalamus, peritrigonal white matter; long T1, T2 in all cerebral white matter; choroid plexus hemorrhage
8/Term infant; 50% abruptio, eclampsia, polyhydramnios	Bilateral pneumothoraces; congenital contractures; low-set ears, small L ear; bilateral simian creases Multiorgan failure; seizures; died at age 4 mo	...	3/4/4/6	4	Injury looks old; atrophy, well localized T1, T2 shortening
9/Term infant; eclampsia, premature rupture of membranes for 28 hrs; labor for 5 d; thick meconium; persistent acidosis		pH, 7.15; PO <sub>2</sub> , 62; BD, 9	2/3/. ./. . .	10	Long T1 dorsal brain stem; short T1 lateral, posterior thalami; short T1 posterior and medial lentiform; short T1 deep periolandic gyri; short T2 lateral thalamus, lateral putamina; long T2 dorsal brain stem and medial cerebral cortex
<b>Group 2, cortex</b>					
10/Term infant; emergency cesarean section for fetal bradycardia (HR, 60 beats per min) for 15 min	Meconium, pneumothorax; transient oliguria; mildly elevated liver function tests	pH, 6.78; BD, 22	1/4/4/6	7	Anterior and posterior T1 and T2 prolongation in the vascular boundary zones; basal ganglia normal

(Table continues.)

Table continued

Patient/Obstetric History	Postnatal Clinical Data	Blood Gas (Umbilical artery)	Apgar, 1/5/10/20 min	Age, d	MR Findings
11/Term infant; home birth; oligohydramnios; postnatal dehydration and cyanosis for 30 hr	Transient oliguria; elevated liver function tests; seizures; US normal	...	...	3	T1 and T2 prolongation anterior and posterior boundary zones; basal nuclei normal
12/Term infant; labor for 4 d; hypovolemia; fetal- maternal transfusion; variable late decelerations	Systolic blood pressure, 20; initial hematocrit, 8; transient oliguria	pH, 7.1; $P_{O_2}$ , 90; BD, 11	2/3/. ./. . .	3	T1 shortening in depths of gyri in vascular boundary zones; diffuse cortical T2 prolongation, greater in boundary zones; severe white matter edema; basal ganglia normal
Group 3, periventricular white matter 13/32 wk	Prolonged respiratory depression; patent ductus arteriosus; hypertonic at 3 mo	...	...	6	Foci of T1, T2 shortening in peritrigonal white matter; diffuse edema
Group 4, mixed 14/35 wk; ruptured cord	Multiorgan failure; died at age 16 wk	pH, 6.5; BD, 26	1/1/3/4	4	Germinal matrix hemorrhage bilateral ganglionic eminence; intraventricular and subarachnoid hemorrhage; short T1, T2 lateral thalami, posterior and medial lentiform, and central cerebral white matter; long T2 entire cortex; edema PLIC
15/35 wk; meconium aspiration; small for gestational age	Periventricular leukomalacia, ? previous injury	pH, 6.8; $P_{O_2}$ , 52; BD, 16	3/5/. ./. . .	6	Diminished hemispheric white matter; short T1 lateral lentiform, right frontal pole; small lentiform nuclei; short T2 in lateral thalami, posterior lentiform, right cerebral peduncle, and deep periolandic cortex; long T2 in much of cerebral cortex; big, irregular ventricles
16/Term infant; maternal chorioamnionitis; arrest at age 7 h, unknown duration	Multiorgan failure; seizures; US normal; died at age 8 d	pH, 6.5; $P_{O_2}$ , 20; BD, 24	1/4/8/. . .	2	T1 shortening in globus pallidus, lateral putamen, and lateral thalami. T2 prolongation in entire cerebral cortex, basal ganglia T1 prolongation PLIC

Note.—BD indicates base deficit; US, ultrasound; HR, heart rate; and PLIC, posterior limb internal capsule.

The infants' charts were reviewed for obstetric history, Apgar scores, umbilical cord blood gases, presence and estimated duration of hypoxic-ischemic episode, and neonatal course. MR studies were performed at 1.5 T and consisted of spin-echo axial 4-mm (400–600/11–20/1 [repetition time/echo time/excitations]), axial 4-mm (3000/50–60, 100–120), and sagittal 3-mm (500–600/11–20) images in all patients. Coronal spin-echo 4-mm (600/11) images were available in 2 patients.

## Results

### *Obstetric History*

A wide variety of obstetric histories were present; details are presented in the Table. Two patients had normal deliveries, but one had a cardiocirculatory arrest for unknown reasons during the first day of life and the other had prolonged postnatal dehydration and cyanosis, possibly related to maternal oligohydramnios. Another patient had a complicated delivery, recovered, then had an unwitnessed arrest of unknown duration at age 7 hours.

Three deliveries were complicated by fetal bradycardia of less than 40 beats per minute for 13 to approximately 30 minutes (it was impossible to obtain exact timing in most cases) and a fourth by bradycardia of 60 beats per minute for approximately 15 minutes. Three patients were born through thick meconium. Two deliveries were complicated by rupture of the umbilical cord, one by uterine rupture, and one by complete umbilical cord occlusion. Other factors leading to the hypoxic-ischemic injury in these neonates were maternal eclampsia (two patients), placental abruption (two patients), polyhydramnios (one patient), and fetal-maternal transfusion with resultant hypovolemia (one patient).

### *Neonatal History (see Table)*

One-minute and 5-minute Apgar scores were available in 12 patients. Ten-minute Apgar scores were available in 6 of the 12 and 20-minute Apgars were available in 5 of those 6 patients. Other than patient 4, who had a normal delivery and arrested later, the available Apgar scores were uniformly poor, ranging from 0 to 3 at 1 minute and from 0 to 5 at 5 minutes.

Umbilical cord blood gases were obtained in 13 patients. Excluding the patient with normal delivery, the pH of the blood ranged from 6.5 to 7.15, with 10 of the 13 below 6.9. Base deficits

ranged from 11 to 26. Seizures were present within the first 24 hours in 8 patients, multiorgan failure was present in 6 patients, transient oliguria in 2 patients, and congenital contractures in 1. Five of the patients died within a few months of birth.

### *Imaging*

We have separated the patients into four groups based on patterns of damage. In one group, abnormal signal was primarily in deep structures, in the second, signal abnormalities were primarily cortical, in the third, abnormal signal was in the periventricular white matter, and in the fourth, the pattern was mixed.

*Group 1.* The largest group consisted of nine patients. Images of these patients showed T1 shortening, predominantly in the lateral thalami, globi pallidi, and posterior putamina; T2-weighted images showed diffuse T2 prolongation, presumably caused by edema. The lateral thalami, globi pallidi, and posterior putamina (Figs 1–3) were hyperintense on T1-weighted images in all patients except patient 7, in whom only the globi pallidi and lateral thalami were affected. T1 shortening of the caudate nuclei was seen in three patients (Fig 2). The T1 shortening in the basal nuclei was diffuse and homogeneous in all except patient 8, in whom it was very localized in the lateral thalami and posterior putamen and associated with T2 shortening in the same regions (Fig 4). Patient 8 also had small basal nuclei and very prominent ventricles and subarachnoid spaces. The posterior limb of the internal capsule, which is usually hyperintense on T1-weighted images in neonates, was conspicuously hypointense in all patients (Figs 1–3). In five patients, the cerebral cortex was involved at the depths of sulci; in most patients, the perirolandic region was particularly affected (Fig 1B). In two patients, abnormal signal intensity was present in the dorsal brain stem, hypointensity (Fig 3B) in patient 9 and patchy hyperintensity in patient 6. In patient 6, the cerebellar white matter showed hyperintensity as well. Patient 9 also had T1 shortening in the claustra (Fig 3A).

*Group 2.* Images of the three patients in the second group (patients 10, 11, and 12) had abnormal signal, predominantly hypointensity on T1-weighted images and hyperintensity on T2-weighted images, in the cerebral cortex and subcortical white matter. The vascular bound-




Fig 1. Patient 1, group 1, born at term. Images at 5 days.

A, Axial spin-echo (500/19) image shows diffuse hyperintensity in the lentiform nuclei and lateral thalami, highlighted by the low intensity of the posterior limb of the internal capsule, which is normally the brightest structure in the brain at this age.

B, Axial spin-echo (500/19) image at the convexity level shows hyperintensity (*arrows*) at the deep portions of the cortical gyri, primarily in the perirolandic region.

C, Axial spin-echo (3000/120) image is normal other than slight hyperintensity of the basal nuclei.



Fig 2. Patient 5, group 1, born at 34 weeks. Image at age 7 days. Axial spin-echo (600/12) image shows abnormal hyperintensity of the thalami, lentiform nuclei (*solid white arrows*) and caudate heads (*curved arrows*), highlighted by abnormal hypointensity of the posterior limb of the internal capsule (*open black arrows*). The cortex at the depths of many sulci (*open white arrows*) are abnormally hyperintense.

ary zones ("watershed zones") between the major cerebral vessels were predominantly involved (Fig 5), although all of the cerebral cortex was involved in patient 12 (Fig 6). Patient 12 had T1 shortening in some of the affected cortex (Fig 6).


*Group 3.* Images of patient 13 had T1 and T2 shortening limited to the periventricular white matter (Fig 7) in conjunction with T1 and T2 prolongation diffusely throughout the cerebral white matter. The deep structures of the brain and the cerebral cortex appeared spared.

*Group 4.* Images of patients 14, 15, and 16 showed a combination of findings seen in the other groups. Patient 14 had abnormal T1 and T2 prolongation in the lateral thalami, globi pallidi, and posterior putamina, T2 prolongation of the entire cerebral cortex, and T1 and T2 shortening in the cerebral white matter, particularly in the frontal and parietal lobes (Fig 8). Germinal matrix and intraventricular hemorrhage was present as well. Patient 15 had T1 shortening in the putamina and heterogeneous T2 shortening and prolongation (Fig 9) in the lateral thalami, posterior lentiform nuclei, right cerebral peduncle, and deep perirolandic cortex. The cerebral cortex showed diffuse T2 prolongation (Fig 9D). Of interest, patient 15 was small for gestational age and had enlarged lateral ventricles with ir-

Fig 3. Patient 9, group 1, born at term. Images at age 10 days.

A, Axial spin-echo (500/12) image shows abnormal hyperintensity of the lateral thalami (*short arrows*), lentiform nuclei (*long arrows*), and claustra (*small arrows*). The abnormal hypointensity of the posterior limb of the internal capsule highlights the hyperintensity of the adjacent structures.

B, Axial spin-echo (500/12) at the level of the mesencephalon shows abnormal hypointensity of the tegmentum (*curved arrows*).



regular ventricular margins (Fig 9), indicating prior injury. Patient 16 had T1 prolongation in the posterior limb of the internal capsule and slight T1 shortening of the lateral thalami in addition to T2 prolongation in the basal nuclei and the entire cerebral cortex.

## Discussion

Modern medical technology and pharmacology allow neonatologists to sustain very sick neonates, such as those who have suffered hypoxic-ischemic injury, until they can maintain homeostasis independently. These drugs and technology are expensive, however, and socioeconomic factors are forcing neonatologists to establish criteria for selecting those patients who are most likely to benefit from inten-


sive therapy. The status of the nervous system is a crucial factor in decisions about treatment of these patients. A recent study of 97 medical records from 111 deaths in an intensive care nursery revealed that central nervous system damage was the most common reason (35% of cases) for withdrawal of life support (10). Unfortunately, differentiation of patients with good developmental prognoses from those with poor prognoses by clinical or laboratory criteria is often difficult. Therefore, finding new methods for the early detection and determination of the extent of brain injury caused by asphyxia is of great importance in the treatment of asphyxiated newborns.

Transfontanel sonography is the imaging study used at most institutions for the initial

Fig 4. Patient 8, group 1, born at term. Images at age 4 days.

A, Axial spin-echo (400/11) image shows punctate hyperintensity in the inferior lentiform nuclei (*open arrows*) and inferolateral thalami (*solid arrows*). The third ventricle and subarachnoid spaces are prominent.

B, Axial spin-echo (3000/100) image shows punctate hypointensity in the inferior lentiform nuclei (*open arrows*) and inferolateral thalami (*solid arrows*). Soft tissue swelling is present in the right frontal region. Cerebrospinal fluid spaces are prominent.






Fig 5. Patient 11, group 2, born at term. Images at age 3 days.

A, Axial spin-echo (3000/120) image shows loss of normal cortical hypointensity in the anterior (*single arrows*) and posterior (*double arrows*) vascular boundary zones. Basal ganglia were normal.

B, Axial spin-echo (3000/120) at age 10 weeks shows shrunken cortex with abnormal hyperintensity of the cortex and subcortical white matter.

assessment of the asphyxiated neonate. Although MR imaging has been established as a useful technique in the assessment of asphyxiated neonates in the intermediate (1, 4, 5, 7) and late (8, 11) stages, little has been written about the usefulness of MR imaging in the first week or 10 days of life. In this study, standard spin-echo MR imaging showed symmetric, sometimes subtle, abnormalities that were detected as early as the second day after birth. Moreover, transfontanel sonograms in five of the patients (all performed within 24 hours of the MR) were all interpreted as normal, even in retrospect, by experienced neurosonographers. Thus, this study suggests that MR imaging is a

useful technique in the evaluation of the asphyxiated neonate during the first few days of life.

Birth and perinatal histories differed among patients in different groups. Most (7 of 9) group 1 patients suffered severe mishaps such as ruptured umbilical cord, occluded umbilical cord, ruptured uterus, profound bradycardia (<40 beats per minute), or cardiocirculatory arrest. The pattern of injury in these patients fits the description of "profound asphyxia" (7). Presumably, the involved brain regions are specifically affected because they are myelinated (12); these regions have higher metabolic requirements (as shown by fludeoxyglucose F 18 positron emission studies [13]).




Fig 6. Patient 12, group 2, born at term. Images at age 3 days.

A, Axial spin-echo (600/20) image shows small ventricles and sulci. T1 shortening is seen in the cortex in some regions. The basal ganglia and internal capsule are normal.



B, Axial spin-echo (3000/120) image shows almost total lack of contrast between cerebral cortex and underlying white matter, presumably secondary to hyperintensity of the cortex resulting from edema.




Fig 7. Patient 13, group 3, born at 32 weeks. Images at 6 days.

A, Axial spin-echo (600/16) image shows punctate hyperintensity (*arrows*) in the peritrigonal white matter. Basal ganglia and thalami are normal for age.

B, Axial spin-echo (3000/120) image shows punctate hypointensity (*arrows*) in the peritrigonal white matter. The high signal intensity in the right temporooccipital region is shading artifact from static field inhomogeneity.





Two patients in group 1 had atypical MR features. In contrast to the diffuse T1 shortening in the lateral thalami and lentiform nuclei in the other patients, there was focal T1 shortening in the lateral thalami and posterior putamina in patient 8 (Fig 4), similar to what has been described in the intermediate period, weeks after injury (1, 4, 7). Moreover, the thalami and dorsal brain stem were small (perhaps atrophic), the subarachnoid spaces were large, the patient had congenital contractures and dysmorphic features, and the pregnancy was complicated by polyhydramnios and eclampsia. These factors suggest an in utero injury, before the abortion at the time of delivery. Patient 9 was atypical in that the dorsal brain stem exhibited prolonged T1 (Fig 3B) and T2 relaxation times, and the umbilical cord blood gases were con-

siderably less abnormal than the other patients in this group. This patient was also born after a complicated prenatal and perinatal course (see Table); thus, it is possible that a significant event occurred some time before delivery, resulting in a less severe acidosis at the time of birth. The very protracted and complicated labor may have contributed to the severity of the dorsal brain stem injury as well. Reports of MR identification of brain stem injury in asphyxiated neonates is uncommon (1, 4, 7, 9), in contrast to reports in the pathology literature, which indicate that dorsal brain stem injury is common in profound asphyxia (14–16). This discrepancy may result from a lack of sensitivity of MR to brain stem injury or from selection bias; brain stem-injured infants presumably suffer higher early mortality and thus may be less likely to

undergo MR imaging and more likely to undergo autopsy. Further elucidation is dependent on more patients undergoing MR relatively early in the postnatal course.

The Apgar scores and umbilical cord blood gases of patients in group 2 are not remarkably different from those in group 1. However, the infants in this group had either less severe bradycardia than group 1 patients (60 beats per minute in patient 5, in contrast to less than 40 beats per minute in group 1 patients) or hypovolemia or anemia; these conditions lead to reduced cerebral blood flow, but not complete cessation of flow. Blood gets shunted to the deep structures of the brain under conditions of reduced flow (17, 18); therefore, it is not unexpected that the basal ganglia, brain stem, and cerebellum are spared while the cerebral cortex is injured. The amount of cortical injury seemed grossly proportional to the duration of the reduced cerebral blood flow. Patient 10, who had reduced blood flow for only about 15 minutes, had small areas of injury, whereas patient 11, who had progressive dehydration and cyanosis over 30 hours, had large areas of injury, and patient 12, who had hypotension and severe anemia for several days secondary to fetal-maternal transfusion, had abnormal signal of the entire cerebral cortex.

T1 and T2 shortening in the periventricular white matter of premature infants with periventricular leukomalacia, such as patient 13, has been noted previously (4) with the observation that the signal changes persist for 1 through 6 weeks. The authors did not comment on how early the signal changes might be seen. If we extrapolate from our data on the infants in group 1 of this study, periventricular T1 shortening in premature neonates might be expected as early as day 3 after injury. However, the sonographic diagnosis of periventricular leukomalacia is not conclusively made until cavitation is seen, usually at the age of 2 to 3 weeks (19). In addition, ultrasound is insensitive to noncavitary periventricular leukomalacia (20). Thus, MR may be more sensitive than ultrasound to the detection of periventricular leukomalacia in the early phases of injury. Obviously, large prospective studies must be performed to confirm this suspicion.

The severity of the blood gas abnormalities was not significantly different in the group 4 patients than in the group 1 patients. These results suggest that the degree of acidosis does

not correlate well with extent of injury; this observation is in agreement with the findings of other studies (21–23). One possible explanation for the marked T2 prolongation in the cerebral cortex of these patients, as compared with group 1 patients, is the duration of the injury. As discussed earlier, we believe that the first structures injured in profound asphyxia are those with the highest metabolic demands. With more prolonged cessation of cerebral blood flow, however, the cerebral cortex will eventually be injured as well. This is the most likely explanation for diffuse T2 prolongation of the cortex in patient 16, who had an unwitnessed arrest of uncertain (but likely prolonged) duration. Evaluation of the injury pattern of patient 14 is more complex because of his prematurity and the significant white matter and germinal matrix hemorrhage that was present. Closer scrutiny of the images of patient 14 showed absence of a normal signal void in the superior sagittal sinus and torcula and acute thrombus in the straight sinus near the torcula. We believe that the hemorrhage in the white matter, and, perhaps, the cortical edema are the result of hemorrhagic venous infarction that was superimposed upon the asphyxic injury affecting the deep gray matter structures. Finally, patient 15 was small for gestational age, indicating that he was subjected to some degree of stress in utero. His MR (Fig 9) findings were diagnostic of end-stage periventricular leukomalacia (24, 25) and are evidence that brain injury occurred before birth. We postulate that the acute injury in the perinatal period (causing damage to the deep gray matter) was superimposed on the more chronic injury (causing damage to the cerebral cortex and white matter) in this patient.

Only patients 7, 8, 9, and 15 had T2 shortening in the lentiform nuclei and lateral thalami. Patients 7 and 9 had imaging on day 10, and patient 15 had imaging on day 6, whereas, as previously discussed, patient 8 (imaging on day 4) most likely had prenatal injuries. (Most likely, patient 15 also had prenatal injury, as described earlier.) T2 shortening was not seen in any other patient imaged day 5 or earlier or in patient 5, imaged at 7 days. Therefore, we think it is reasonable to postulate that T2 shortening develops in the brains of asphyxiated neonates sometime between 6 and 10 days after injury. This is consistent with observations of T2 shortening in the intermediate phase, weeks to months after injury (1, 7) and with the observa-

tions of Keeney et al (4), who noted T2 shortening as early as the "end of the first week." The cause of the T1 and T2 shortening is still obscure (1, 7), but the fact that the T2 shortening develops several days *after* the T1 shortening makes hemorrhage, as suggested by some authors (4), an unlikely cause.

The locations of injuries in our group 1 patients do not correspond to the location of injured tissues in profoundly asphyxiated neonates who undergo imaging later in life (7, 26). The previous reports have emphasized focal injury in the lateral thalami and posterolateral putamina, whereas, in this series, we noted diffuse abnormality affecting the lateral thalami, globi pallidi, putamina, and caudate nuclei. Moreover, we have done sequential imaging of patients (not included in this study) who had signal abnormality in the globi pallidi in the first 20 days of life, but show abnormal T2 prolongation and atrophy in the lateral thalami and posterior putamina, but not in the globi pallidi, on images later in life. We do not have an adequate explanation for this observation. One possibility is that the caudate nuclei and globi pallidi partially or completely recover and that the lateral thalami and posterior putamina recover less because they are more completely myelinated (it is known that certain protein components of myelin inhibit neurite outgrowth [27]). Another possibility is that the lateral thalamus and posterolateral putamen are more seriously injured than the other regions because they are more completely myelinated and, therefore, have higher metabolic demands. Finally, astrocytic response may be more mature in the lateral thalamus and posterior putamen. If so, these regions would be expected to undergo more reactive astrocytosis after injury and thus appear hyperintense on T2-weighted images; the other regions, where the damaged tissue is resorbed with little or no astrocytosis, would not be expected to show signal abnormality. This will be an interesting area for future research.

An important aspect of the early imaging evaluation of asphyxiated neonates is the correlation of imaging findings with outcome. It is not the purpose of this communication to provide that correlation; the number of patients is too small to establish proper correlations, and some of the patients have had imaging too recently to allow adequate follow-up. We are presently involved in a prospective study that will address the issue of outcome.

One final topic that must be mentioned is the safety of sedating, transporting, and imaging these infants, who are often very sick and unstable. We did not scan patients until they were judged to be adequately stable for transportation by the principle caretaking physicians. Each of our patients was sedated, transported, and monitored by physicians and nurses from the intensive care nursery, who remained with the infant at all times. During the imaging procedure, the infants were wrapped in blankets, to immobilize them and keep temperature constant, and monitored by a pulse oximeter, which measures oxygen saturation, and a capnometer that measures expired carbon dioxide concentration. We had no complications. If further studies prove that MR is a valuable tool in the assessment of these infants, we believe that equipment can be developed to facilitate even safer transportation and imaging of these patients.

In summary, we have reviewed MR studies performed during the first 10 days of life in 16 infants who had hypoxic-ischemic brain injury in the perinatal period. MR showed bilateral, symmetric signal abnormalities in all. We have attempted to correlate the pattern of signal abnormality with obstetric, intrapartum, and postnatal events. Our results indicate that MR is useful in evaluating the extent of brain damage in these infants during the first week of life. This information should prove useful in patient treatment. Further studies that correlate MR appearance with patient outcome are under way.

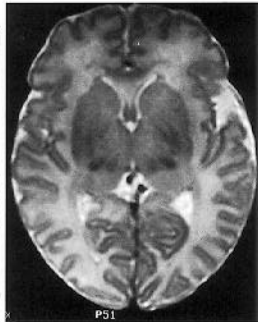
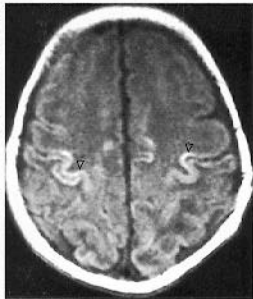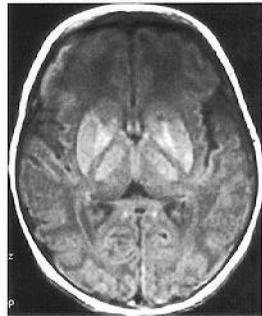## Acknowledgments

We thank Carol Sheldon, MD, David Seidenwurm, MD, and Wallace Peck, MD, for providing information for this study.

## References

1. Steinlin M, Dirr R, Martin E, et al. MRI following severe perinatal asphyxia: preliminary experience. *Pediatr Neurol* 1991;7:164-170
2. McArdle CB, Richardson C, Hayden C, et al. Abnormalities of the neonatal brain: MR imaging, I: intracranial hemorrhage. *Radiology* 1987;163:387-394
3. Keeney SE, Adcock EW, McArdle CB. Prospective observations of 100 high-risk neonates by high field (1.5 Tesla) magnetic resonance imaging of the central nervous system, I: intraventricular and extracerebral lesions. *Pediatrics* 1991;87:421-430

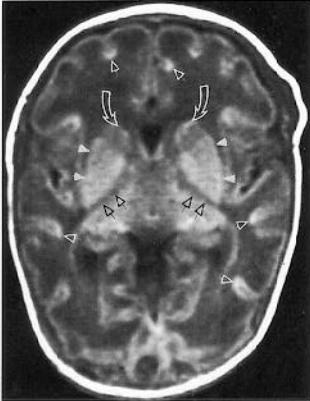
4. Keeney S, Adcock EW, McArdle CB. Prospective observations of 100 high-risk neonates by high field (1.5 Tesla) magnetic resonance imaging of the central nervous system, II: lesions associated with hypoxic-ischemic encephalopathy. *Pediatrics* 1991;87:431-438
5. McArdle CB, Richardson CJ, Hayden CK, et al. Abnormalities of the neonatal brain: MR imaging, II: hypoxic-ischemic brain injury. *Radiology* 1987;163:395-403
6. Schouman-Clays E, Henry-Feugeas M-C, Roset F, et al. Periventricular leukomalacia: correlation between MR imaging and autopsy findings during the first 2 months of life. *Radiology* 1993;189:59-64
7. Barkovich AJ. MR and CT evaluation of profound neonatal and infantile asphyxia. *AJNR Am J Neuroradiol* 1992;13:959-972
8. Barkovich AJ, Truwit CL. MR of perinatal asphyxia: correlation of gestational age with pattern of damage. *AJNR Am J Neuroradiol* 1990;11:1087-1096
9. Baenziger O, Martin E, Steinlin M, et al. Early pattern recognition in severe perinatal asphyxia: a prospective MRI study. *Neuroradiology* 1993;35:437-442
10. Wall S, Partridge JC. Withdrawal of life support in the intensive care nursery: decisions and practice by neonatologists. *Clin Res* 1993;41:91A
11. Byrne P, Welch R, Johnson MA, Darrah J, Piper M. Serial magnetic resonance imaging in neonatal hypoxic-ischemic encephalopathy. *J Pediatr* 1990;117:694-700
12. Hasegawa M, Houdou S, Mito T, Takashima S, Asanuma K, Ohno T. Development of myelination in the human fetal and infant cerebrum: a myelin basic protein immunohistochemical study. *Brain Dev* 1992;14:1-6
13. Chugani HT, Phelps ME, Mazziotta JC. Positron emission tomography study of human brain functional development. *Ann Neurol* 1987;22:487-497
14. Schneider H, Ballowitz L, Schachinger H, Hanefeld F, Droszus JJ. Anoxic encephalopathy with predominant involvement of basal ganglia, brain stem, and spinal cord in the perinatal period. *Acta Neuropathol (Berl)* 1975;32:287-298
15. Leech RW, Alvord EC Jr. Anoxic ischemic encephalopathy in the human neonatal period: the significance of brain stem involvement. *Arch Neurol* 1977;34:109-113
16. Roland EH, Hill A, Norman MG, Flodmark O, MacNab AJ. Selective brainstem injury in an asphyxiated newborn. *Ann Neurol* 1988;23:89-92
17. Ashwal S, Majcher JS, Longo L. Patterns of fetal lamb regional cerebral blood flow during and after prolonged hypoxia: studies during the post-hypoxic recovery period. *Am J Obstet Gynecol* 1981;139:365-372
18. Behrman RE, Lees MH, Peterson EN, de Lannoy KCW, Seeds AE. Distribution of the circulation in the normal and asphyxiated fetal primate. *Am J Obstet Gynecol* 1970;108:956-969
19. Dubowitz LMS, Bydder GM, Mushin J. Developmental sequence of periventricular leukomalacia: correlation of ultrasound, clinical, and nuclear magnetic resonance functions. *Arch Dis Child* 1985;60:349-355
20. Goldstein RB, Filly RA, Hecht S, Davis S. Noncystic "increased" periventricular echogenicity and other mild cranial sonographic abnormalities: predictors of outcome in low birth weight infants. *J Clin Ultrasound* 1989;17(8):553-562
21. Dijkhoorn M, Visser G, Huisjes H, et al. The relation between umbilical pH values and neonatal neurological morbidity in full-term AFD infants. *Early Hum Dev* 1985;11:33-42
22. Goodwin TM, Belai I, Hernandez P, Durand M, Paul RH. Asphyxial complications in the term newborn with severe umbilical acidemia. *Am J Obstet Gynecol* 1992;162:1506-1512
23. Ruth V, Raivo K. Perinatal brain damage: predictive value of metabolic acidosis and the Apgar score. *Br Med J* 1988;297:24-27
24. Flodmark O, Lupton B, Li D, et al. MR imaging of periventricular leukomalacia in childhood. *AJNR Am J Neuroradiol* 1989;10:111-118
25. Flodmark O, Roland EH, Hill A, Whitfield MF. Periventricular leukomalacia: radiologic diagnosis. *Radiology* 1987;162:119-124
26. Menkes J, Curran JG. Clinical and magnetic resonance imaging correlates in children with extrapyramidal cerebral palsy. *AJNR Am J Neuroradiol* 1994;15:451-457
27. Caroni P, Schwab ME. Two membrane protein fractions from rat central myelin with inhibitory properties for neurot growth and fibroblast spreading. *J Cell Biol* 1988;106:1281-1288

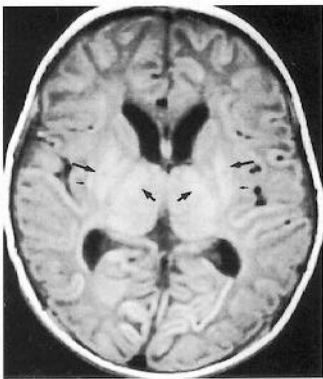


**A**

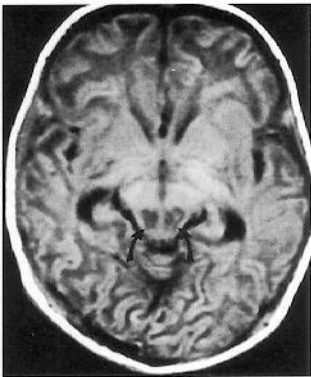**B**

**C**



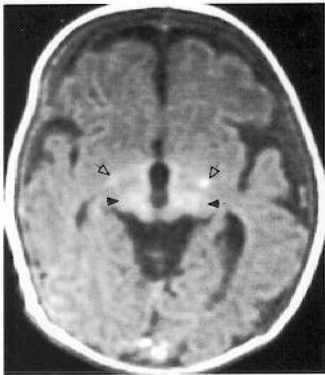


**A**

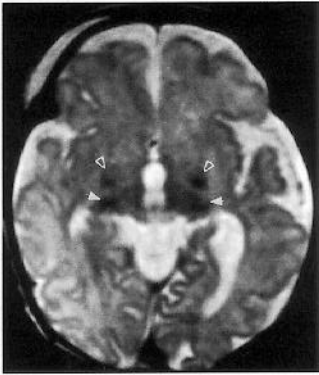

**B**

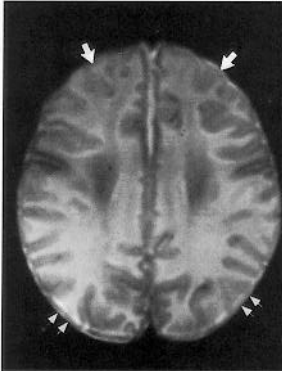




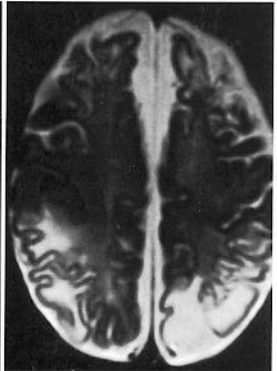**A**



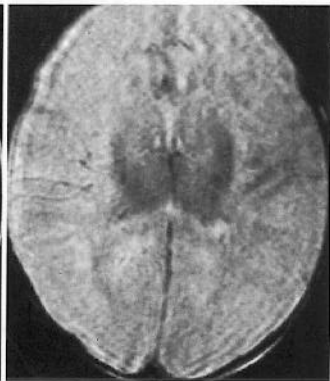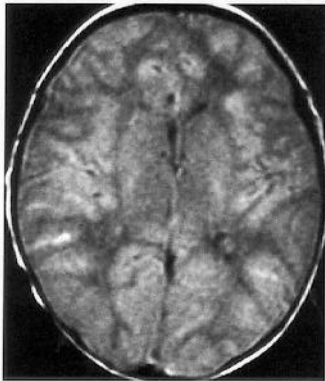
**B**



**A**

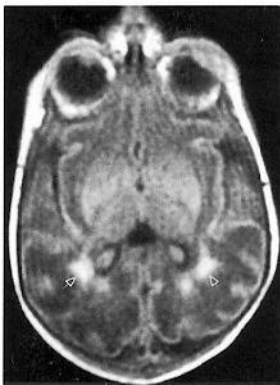


**B**

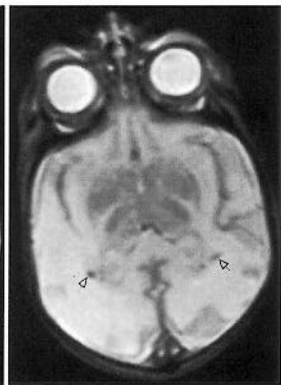


**A**

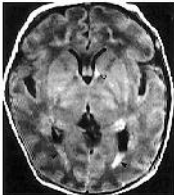**B**



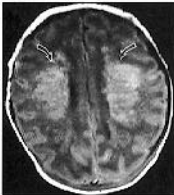
**A**



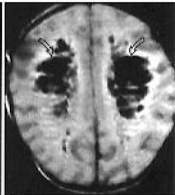
**B**



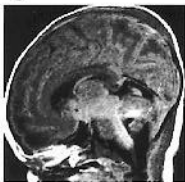
A



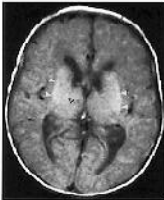
B



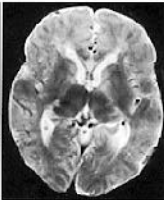
C



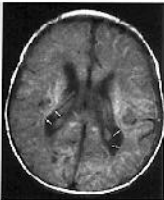D



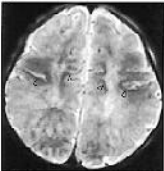
A



B



C



D