

A Comparison of Functional MR Activation Patterns during Silent and Audible Language Tasks

F. Zerrin Yetkin, Thomas A. Hammeke, Sara J. Swanson, George L. Morris, Wade M. Mueller, Timothy L. McAuliffe, and Victor M. Haughton

PURPOSE: To compare word generation tasks performed silently and aloud as paradigms for functional MR. **METHODS:** Images were obtained at 1.5 T, with echoplanar acquisition in nine subjects performing word generation aloud or silently. Functional images created from the echoplanar images by means of cross-correlation techniques were superimposed on anatomic reference images. The location of activation from the two tasks was tabulated; the number of activated pixels in each region from the two tasks was compared. **RESULTS:** Both silent and aloud word generation produced activation in the inferior frontal lobes, sensorimotor cortex regions, supplementary motor areas, and anterior cingulate gyri, predominantly in the dominant hemisphere. Significantly more activated pixels and fewer artifacts were detected with silent word generation than with word generation aloud. **CONCLUSION:** Word generation silently or aloud produce activation in the brain. Greater activation can be detected in the left frontal lobe with silent word generation, although the subject's performance of the task cannot be monitored independently during silent word generation.

Index terms: Speech; Magnetic resonance, functional; Brain, magnetic resonance

AJNR Am J Neuroradiol 16:1087-1092, May 1995

Functional magnetic resonance (MR) imaging may be applied to the mapping of functionally eloquent regions of the brain for research or for surgical planning. The "activation" secondary to motor, sensory and cognitive tasks (1-13) is detected in functional MR as the result of changes in regional cerebral blood flow and deoxyhemoglobin that accompany neuronal activity. In susceptibility-weighted functional MR acquisitions, the major contrast mechanism is the reduction in deoxyhemoglobin that occurs when blood flow increases in excess of that needed to meet the increased oxygen needs of functioning neurons (6, 10). To apply functional MR to cerebral mapping in patients, techniques that minimize acquisition time, motion artifacts,

and random variation are needed. Head movement is an obvious cause of artifact that must be minimized (14). A less obvious cause of artifact is the movement of the tissues in the neck and face during swallowing or vocalization, which also degrade image quality (Haughton VM, Yetkin FZ, Cox RW, "Motion-Related Artifacts in Functional MR Imaging," presented at the Radiological Society of North America 80th Scientific Assembly and Annual Meeting, Chicago, Ill, November 27-December 2, 1994). Functional imaging studies based on tasks that require no movement of the face or neck are likely to produce images with less artifact than tasks requiring patient movement. In this study we compared the functional MR activation patterns secondary to language tasks performed silently and performed audibly.

Methods

A "bird cage" type head coil designed to optimize signal detection from the cerebrum (Wong EC, Boskamp E, Hyde JS, "A Volume Optimized Quadrature Elliptical Endcap Birdcage Brain Coil," presented at the 11th Annual Meeting of the Society of Magnetic Resonance in Medicine,

Received July 27, 1994; accepted after revision December 27.

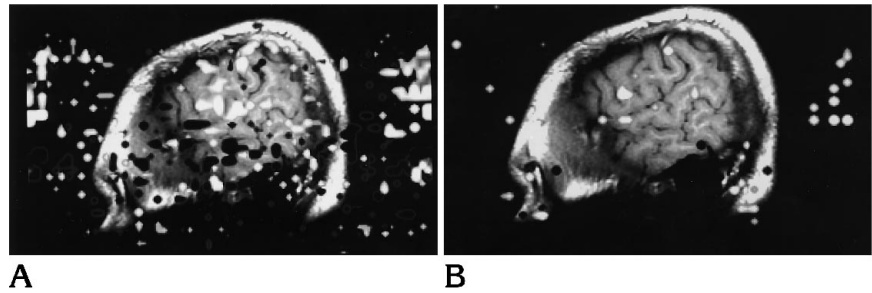
From the Departments of Radiology (F.Z.Y., V.M.H.), Neurology (T.A.H., S.J.S., G.L.M.), Neurosurgery (W.M.M.), and Biostatistics (T.L.M.), The Medical College of Wisconsin, Milwaukee.

Address reprint requests to Victor M. Haughton, MD, Department of Radiology, Medical College of Wisconsin, 8700 W Wisconsin Ave, Milwaukee, WI 53226.

AJNR 16:1087-1092, May 1995 0195-6108/95/1605-1087

© American Society of Neuroradiology

Fig 1. Functional images in parasagittal plane through the left hemisphere in one volunteer during word generation performed aloud (A) and word generation performed silently (B). More artifacts are present in the images of word generation performed aloud.



Berlin, 1992) and a blipped echoplanar acquisition (Wong EC, Bandettini PA, Hyde JS, "Echoplanar Imaging of the Human Brain Acquired with a Three Axis Local Gradient Coil," presented at the 11th Annual Meeting of the Society of Magnetic Resonance in Medicine, Berlin, 1992) were used with a commercial 1.5-T imager. Subjects between 20 and 40 years of age who had no symptoms of neurologic disease were recruited. Inclusion criteria included: English speaking; healthy; no contraindication to MR; and no previous head trauma, craniotomy, or neurologic disease. Handedness was determined by means of the Edinburgh Handedness Inventory (15). After signing a consent form, the subjects were instructed and rehearsed in the word generation task, asked to remain as still as possible in the scanner, and, having inserted ear plugs, were positioned on the gantry. Anatomic and functional MR images were obtained in each subject. A series of locater images was obtained in the axial plane. On the basis of these images, a series of 13 parasagittal planes, 1 cm in thickness, encompassing the entire brain was selected for obtaining the anatomic reference images. Typically these anatomic reference images were obtained with spin-echo acquisitions, 800/25/2 (repetition time/echo time/excitations), 24 cm field of view, 128×256 matrix, and 10-mm section thickness. A series of functional images was then obtained in the same planes. The functional images were created from 140 gradient-echo echoplanar images in the selected plane at 2-second intervals while the subject alternately rested for 20 seconds and performed the specified language task for 20 seconds. Technical parameters for the images included 2000/40/1; matrix, 64×92 ; field of view, 20; section thickness, 10 mm; acquisition time, 40 milliseconds. The series of images was screened for head movement by viewing the images in cine mode. In the acquisitions without visible head motion, the time course of the signal intensity in each pixel was compared with a synthesized square reference wave function with a period of 40 seconds. By means of a cross-correlation program (16) with a threshold set at a correlation coefficient of 0.7, pixels temporally correlated change in signal intensity were displayed as activated pixels. The activated pixels were overlaid on the anatomic reference images. Activated pixels that did not correlate with brain tissue or intracranial vessels were considered artifacts probably caused by motion.

Two tasks were performed by each subject. For the *silent word generation* task, the subject was cued to think

of as many words as possible starting with a letter of the alphabet specified by the investigator. The subject continued the word generation silently until cued by the investigator to stop after 20 seconds. The subjects were instructed to avoid moving and thinking of words as much as possible during the 20-second intervals ("rest") between tasks. The *audible word generation* task was identical except that the subject said words aloud for 20 seconds when cued by the investigator. Different letters were supplied by the investigator for each task period. Each functional acquisition consisted of subjects performing the word generation task three times, interspersed with four intervals of rest.

The order in which the tasks were performed was audible first and then silent in each subject. The activation was measured by counting the number of activated pixels in specific brain regions in the functional images. Brain regions were identified by conventional methods used for parcellation in functional imaging studies (17, 18). The Sylvian fissure and its anterior and posterior ascending rami and the anatomically related gyri were identified. The anterior ascending and horizontal rami were used to identify the inferior frontal gyrus. Activation adjacent to the central sulcus was classified as occurring in the sensorimotor cortex. On the midline images, the anterior cingulate gyrus, marginal sulcus, paracentral lobule, and the supplementary motor areas were identified by criteria previously used (17, 18). Activated pixels in the superior temporal, middle temporal, inferior temporal gyri, and parietal gyri also were counted. The excess of activated pixels in left hemisphere regions compared to the right in each brain region was calculated as $(L-R)/(L+R)$, where L and R are the number of activated pixels in the region in the left and right hemispheres, respectively.

Results

Eight right-handed subjects and one left-handed subject were studied. Functional images without observable head motion were obtained in each subject. Regions of activation lying outside the brain, attributable to artifact, were more frequently identified in the images of the aloud condition than in the silent condition (Fig 1). Activation in the word generation tasks performed silently and audibly was distributed

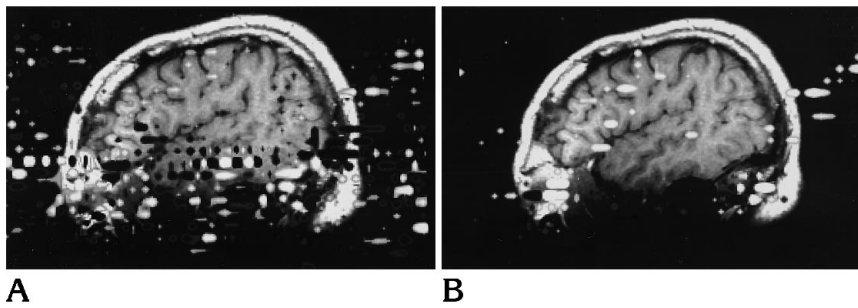


Fig 2. Functional images in parasagittal plane in another subject during aloud (A) and silent word generation (B).

in a similar pattern (Figs 1–3). The inferior frontal gyrus and/or adjacent regions of the middle and precentral frontal gyrus were regularly activated by the two tasks, as were the sensorimotor cortex, the anterior cingulate gyrus, and the supplementary motor area. Activation also was seen in the thalami and parietal, temporal, and occipital lobes in some subjects during silent or aloud word generation.

The number of pixels demonstrating activation in the left hemisphere by silent word generation is summarized in Fig 4. In the left hemisphere, both the inferior frontal gyrus and the adjacent middle frontal and precentral gyri were activated by silent word generation in all cases. The average number of pixels activated in the inferior frontal and adjacent frontal gyri

was 12 and 16, respectively. On average, in the sensorimotor cortex 6 pixels and in the anterior cingulate gyrus 8 pixels were activated by word generation silently. In the supplementary motor area and in the temporal gyri, on average 5 or fewer activated pixels were identified.

Activation in the left hemisphere by word generation aloud is summarized in Figure 5. In the left hemisphere, on average 7 pixels were activated in the inferior frontal gyrus and 14 in the adjacent middle, frontal, and precentral gyri by word generation aloud. In the sensorimotor cortex, anterior cingulate gyrus, supplementary motor area, and temporal gyri 2 to 7 activated pixels were seen on average from word generation aloud (Fig 5). On average, more pixels were activated in the silent word generation task

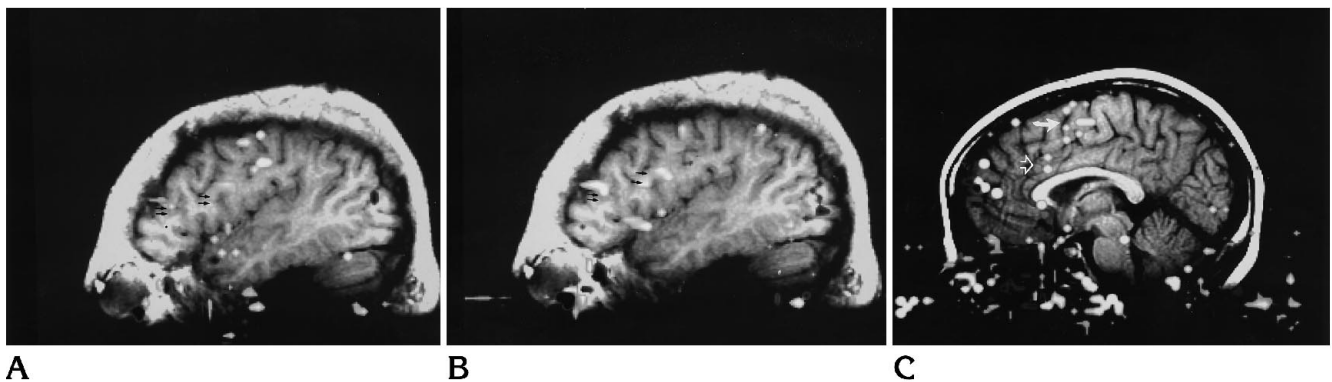
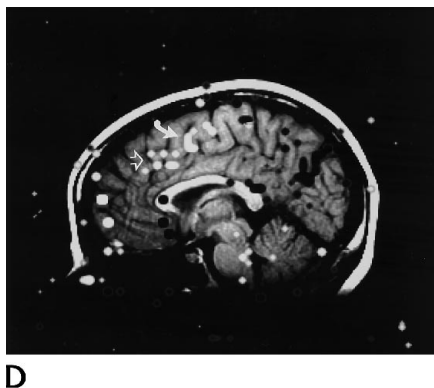


Fig 3. Functional images in parasagittal plane through the left hemisphere (A, B) and the midline (C, D) demonstrating activation during aloud (A, C) and silent (B, D) tasks. The inferior frontal, precentral (*small arrows*), and anterior cingulate gyri (*open arrows*) and supplementary motor area (*closed arrows*) are labelled.



D

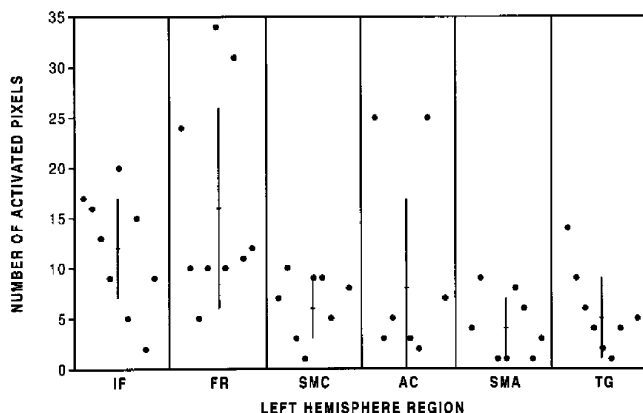


Fig 4. Activation in nine subjects in each left hemisphere region performing word generation silently. Key to abbreviations: IF indicates inferior frontal gyrus; FR, adjacent frontal gyri; SMC, sensorimotor cortex; AC, anterior cingulate gyrus; SMA, supplementary motor area; and TG, temporal gyri.

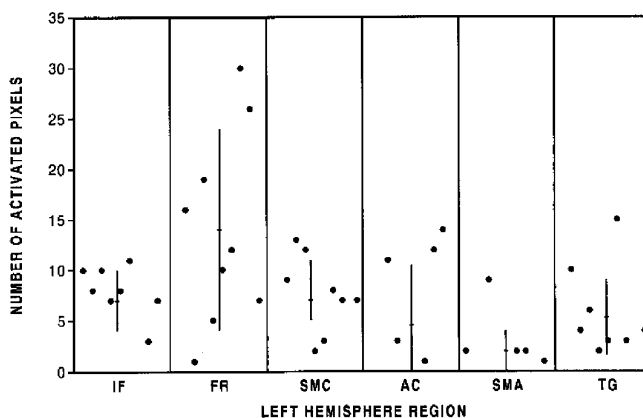


Fig 5. Activation in each left hemisphere region in each subject performing word generation aloud. (See Figure 4 legend for key to abbreviations.)

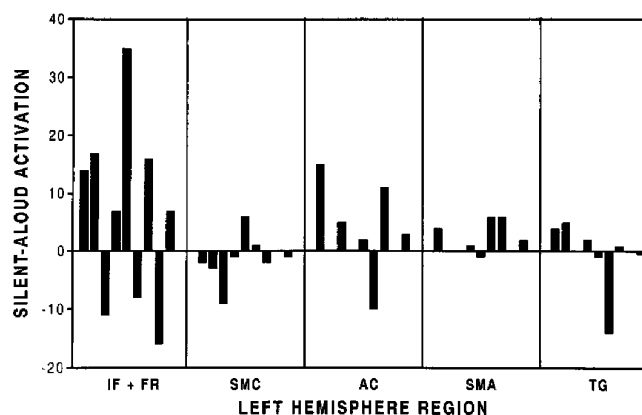


Fig 6. Difference in number of activated pixels in the left hemisphere of right-handed subjects performing word generation silently and aloud. (See Figure 4 for key to abbreviations.)

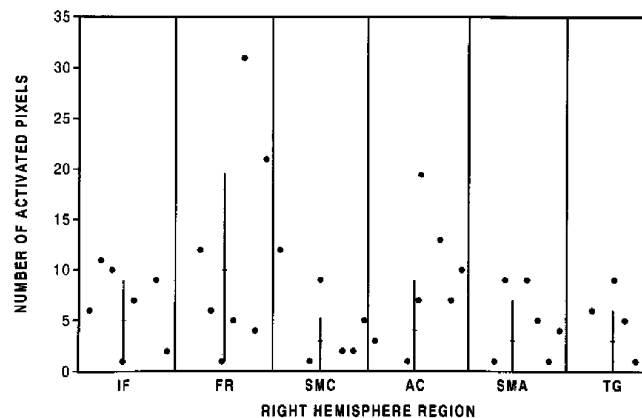


Fig 7. Activation in each region in the right hemisphere in each subject performing silent word generation. (See Figure 4 legend for key to abbreviations.)

than in the word generation task aloud. The difference in activation from silent and aloud word generation in the seven right-handed subjects is shown in Figure 6. On average, for right handers, 7 more pixels were activated in the left frontal lobe (inferior frontal and adjacent precentral and middle frontal gyri) by word generation silently than by word generation aloud. The difference was statistically significant ($P = .05$, Student's t test for a paired sample). For the sensorimotor cortex, on average fewer pixels were activated in right handers by the word generation task aloud than by word generation silently (difference = 1.25, not significant). For the anterior cingulate region, 2.75 more pixels were on average activated by the silent compared to the aloud word generation ($P = .09$). For the supplementary motor area and the tem-

poral gyri, the difference in activation between word generation silently and aloud was small and insignificant.

Activation in the right hemisphere secondary to silent word generation is tabulated in Figure 7. In the silent word generation task, on average 5 activated pixels were identified in the inferior right frontal lobe and 10 in the adjacent right middle frontal and precentral gyri. In one case in which activation was identified in the left frontal lobe, no activation was identified in the right frontal region. On average fewer than 4 activated pixels were identified in the other regions that were tabulated.

The activation in the right and left frontal lobes from silent word generation is compared in Figure 8. In all right-handed subjects, more activation was seen in the left than in the right

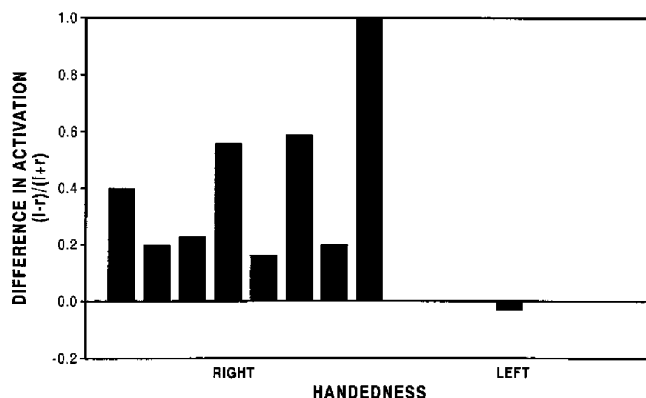


Fig 8. Comparison of activation in left and right hemisphere in right and left handers performing word generation silently.

frontal lobe. In one subject, the ratio of $(L-R)/(L+R)$ was 1 because no right frontal lobe activation was detected. In right handers, activation in the left frontal lobe exceeded that in the right frontal lobe by 37%. In the one left-handed subject, activation on the right frontal lobe exceeded that on the left (Fig 8). In six subjects, the $(L-R)/(L+R)$ ratio was similar in the silent and aloud word generation tasks. In the one left-handed subject, a slight excess of activation in the left frontal lobe (ratio = 0.1) was seen with word generation aloud. On another subject the ratio dropped from 1 to 0.27, and in one other it increased from 0.2 to 0.5.

Discussion

This functional MR study showed activation in the inferior frontal lobe, the sensorimotor cortex region, the anterior cingulate gyrus, and the supplementary motor area in subjects performing word generation silently or aloud. Similar results have been reported previously (19–22), although silent and aloud word generation have not been compared (3, 4, 12). Functional MR imaging with word generation showed more activation in the left hemisphere than in the right hemisphere in right-handed subjects. It also showed greater right hemisphere activation in a left-handed subject.

The study showed more activation in the dominant frontal lobe in subjects performing the word generation task silently than aloud. The greater number of activated pixels in silent word generation might be attributable to physiologic differences in the two tasks, or to technical differences, such as decreased

noise during the task, minimizing movement of the head and facial structures. The increased activation in the sensorimotor cortex secondary to tasks performed audibly may reflect actual movement of the lips, tongue, and facial muscles. Activation in sensorimotor cortex, secondary to silently performed tasks, observed in functional MR imaging and positron emission tomography (19), is not yet explained. Differences in activation between subjects may represent differences in the way individuals performed the tasks. The physiologic significance of regions activated secondary to these tasks is beyond the scope of this study.

Motion of the head or of objects in the magnetic field during the acquisition of functional MR data degrades the functional information (14). Head motion was monitored in this study, and any acquisition with head motion was excluded. Movement of facial structures was not monitored, and subtle mouth or jaw movement during silent tasks cannot be excluded. Subvoxel head movement also is not excluded. The increased number of artifactual activations in the audible tasks compared with silent tasks is consistent with the increased facial movements needed to perform the tasks.

The precision and accuracy of functional MR have not been studied systematically. Anatomic location of pixels adjacent to sulci (eg, near the inferior frontal gyrus or central sulcus) may be inexact. Therefore, in some tabulations we combined the activation in the inferior frontal and adjacent gyri and the activation in precentral and postcentral gyri as sensorimotor cortex. Because of susceptibility artifacts near the base of the skull, detection of activation in the inferior temporal gyrus may be less reliably detected than activation elsewhere. Practice effects (ie, decreased activation in the repetitions) were not observed in this study.

This study shows that for the purposes of mapping language functions with functional MR, the word generation task may be performed silently or aloud. An advantage of silent word generation is that more activation and fewer artifacts result from motion of the head, jaw, tongue, or throat. A disadvantage of the silent version of the language task is the inability to monitor the patient's performance of the task.

References

1. Frahm J, Bruhn H, Merboldt K, et al. Dynamic MR imaging of human brain oxygenation during rest and photic stimulation. *J Magn Reson Imaging* 1992;2:501-505
2. Kwong KK, Belliveau JW, Chesler DA, et al. Dynamic magnetic resonance imaging of human brain activity during primary sensory stimulation. *Proc Natl Acad Sci* 1991;89:5675-5679
3. Binder JR, Rao SM, Hammeke TA, et al. Functional magnetic resonance imaging of human auditory cortex. *Ann Neurol* 1994;35:662-672
4. Rueckert L, Appollonio I, Grafman J, et al. MRI functional activation of left frontal cortex during covert word production. *J Neuroimaging* 1994;4:67-70
5. Cao Y, Towle VL, Levin DN, Balter J. Functional mapping of human cortical activation by conventional MRI at 1.5T. *J Magn Reson Imaging* 1993;3:869-875
6. Bandettini PA, Wong EC, Hincks RS, et al. Time course EPI of human brain function during task activation. *Magn Res Med* 1992;25:390-397
7. Blamire AM, Ogawa S, Ugurbil K, et al. Dynamic mapping of the human visual cortex by high speed magnetic resonance imaging. *Proc Nat Acad Sci* 1992;89:11069-11073
8. Menon RS, Ogawa S, Kim S-G, et al. Functional brain mapping using magnetic resonance imaging: signal changes accompanying visual stimulation. *Invest Radiol* 1992;27:S47-S53
9. Belliveau JW, Kwong KK, Kennedy DN, et al. Magnetic resonance image mapping of brain function: human visual cortex. *Invest Radiol* 1992;27:S59-S65
10. Ogawa S, Tank DW, Menon R, et al. Intrinsic signal changes accompanying sensory stimulation: functional brain mapping with magnetic resonance imaging. *Proc Nat Acad Sci* 1992;89:5951-5999
11. Jack CR, Thompson R, Butts RK, et al. Sensory motor cortex: presurgical mapping with functional MR imaging and invasive cortical mapping. *Radiology* 1994;190:85-92
12. Hinke R, Hu X, Stillman AE, et al. Functional magnetic resonance imaging of Broca's area during internal speech. *Neuro Report* 1993;4:675-678
13. Morris GL, Mueller WM, Yetkin FZ, et al. Functional magnetic resonance imaging in partial epilepsy. *Epilepsia* 1994;35:1194-1198
14. Hajnal J, Myers R, Oatridge A, Schwieso JE, Young IR, Bydder GM. Epilepsia: Artifacts due to stimulus correlated motion in functional imaging in brain. *Magn Reson Med* 1994;31:283-291
15. Oldfield RC. The assessment and analysis of handedness: the Edinburgh inventory. *Neuropsychologia* 1971;9:97-113
16. Bandettini PA, Jesmanowicz A, Wong EC, et al. Processing strategies for time-course data sets in function MRI of the human brain. *Magn Reson Med* 1993;30:161-173
17. Sobel DF, Gallen CC, Schwartz BJ, et al. Locating the central sulcus: comparison of MR anatomic and magnetoencephalographic functional methods. *AJNR Am J Neuroradiol* 1993;14:915-925
18. Rademacher J, Galaburda AM, Kennedy DN, Filipek PA, Caviness VS. Human cerebral cortex: localization, parcellation, and morphometry with magnetic resonance imaging. *J Cognitive Neurosci* 1992;4:352-358
19. Friston KJ, Frith CD, Liddle PF, Frackowiak RSJ. Investigating a network model of word generation with positron emission tomography. *Proc R Soc Lond [Biol]* 1991;244:101-106
20. Wise R, Chollet F, Hadar U, Friston K, Hoffner E, Frackowiak R. Distribution of cortical neural networks involved in word comprehension and word retrieval. *Brain* 1991;114:1803-1817
21. Haxby JV, Grady CL, Ungerleider LG, Horwitz B. Mapping the functional neuroanatomy of the intact human brain with brain work imaging. *Neuropsychology* 1991;29:539-555
22. Peterson SE, Fiez JA. The processing of single words studied with positron emission tomography. *Ann Rev Neurosci* 1993;16:509-530