

Radiating Pain to the Lower Extremities Caused by Lumbar Disk Rupture without Spinal Nerve Root Involvement

Pierre C. Milette, Suzanne Fontaine, Luigi Lepanto, and Guy Breton

PURPOSE: To locate the origin of the pain during lumbar diskography by means of a limited intradiskal injection of a local anesthetic. **METHODS:** Lumbar diskography by the direct central posterior approach was performed in 235 consecutive patients. In 17 patients, severe and persistent low back pain, with unilateral or bilateral radiation to the lower extremities, was provoked by contrast injection into only one disk. One milliliter of 1% lidocaine was then slowly injected in the center of these disks. **RESULTS:** A 75% to 100% reduction of the low back pain was experienced by 13 patients, and a 75% to 100% reduction of the radiating pain was experienced by 16 patients within 60 seconds after the intradiskal injection of lidocaine. Radiographs demonstrated radial tears through the entire annulus thickness in 16 of 17 disks. **CONCLUSION:** Our results suggest that, in some patients with low back pain and unilateral or bilateral radiation to the lower extremities, the pain arises from within the disk. In these cases, pain radiating to the lower limb seems to be a referred type and seems unrelated to direct nerve root compression or irritation by a disk fragment in the epidural space.

Index term: Spine, intervertebral disks, herniation

AJNR Am J Neuroradiol 16:1605-1613, September 1995

Low back pain is now recognized as the most common and expensive ailment of the middle-aged patient in the industrialized societies of the western nations (1). Despite recent developments in imaging technology, we still have a very limited understanding of the pathophysiology of low back pain, and what is imaged is often not directly related to the clinical problem (2-4). In their 1934 description of a "fracture of the annulus" or "rupture of the intervertebral disk" (an expression that they preferred to "herniation of the nucleus pulposus"), Mixter and Barr (5) did not imply that the radiating pain to the lower extremity associated with certain "disk prolapses" was caused by spinal nerve

root compression or irritation. Nevertheless, this explanation seemed so logical as to be more or less taken for granted and practically never challenged (6-13).

The possibility that a disk rupture or annular tear could cause radiating pain to the lower extremity, in the absence of any direct nerve root involvement, has been suggested (11, 14, 15). The extravasation through such a tear of irritating nuclear mucopolysaccharides could induce an inflammatory reaction involving the outer annular fibers, in which there is a rich nerve supply, and this area would then behave as a trigger zone, causing low back pain with lower-extremity radiation through nervous pathways still poorly understood (16-22). Even though gadopentetate dimeglumine-enhanced magnetic resonance (MR) can now be used to demonstrate annular tears in a noninvasive way, the concept of diskogenic pain has been met with skepticism (23).

The purpose of this prospective study was to confirm the existence of diskogenic pain in the lower extremity, by observing the effects of injecting, during diskography procedures, a measured quantity of a local anesthetic in the center

Received September 13, 1994; accepted after revision February 1, 1995.

Presented at the 32nd Annual Meeting of the American Society of Neuroradiology, Nashville, Tenn, May 3-7, 1994.

From the Department of Radiology, Hôpital Saint-Luc, Montreal, Quebec, Canada.

Address reprint requests to Pierre C. Milette, MD, Department of Radiology, Hôpital Saint-Luc, 1058 Saint-Denis St, Montreal, Quebec, Canada H2X 3J4.

AJNR 16:1605-1613, Sep 1995 0195-6108/95/1608-1605

© American Society of Neuroradiology

of disks that seemed responsible for low back pain with radiation to the leg.

Patients and Methods

During a 3-year period (January 1991 to January 1994), 469 outpatients were referred to our institution for lumbar diskography. All these patients had previously been investigated by either computed tomography (CT), CT myelogram, or MR and were requested to bring these studies with them for review at the time of their appointments. In this group, 235 patients met the selection criteria defined for this prospective study, namely: (a) presence of low back pain with some type of unilateral or bilateral radiation below the gluteal fold; (b) no previous lumbar spinal surgery; (c) no spondylolysis or spondylolisthesis; and (d) no obvious disk herniation with nerve root compression on previous imaging studies.

Lateral and anteroposterior radiographs of the lumbosacral spine were obtained in all patients. An anteroposterior projection of the dorsal spine was also obtained to rule out transition phenomena and to ascertain proper labeling of lumbar disks. One-, two-, or three-level lumbar diskograms were performed on these patients in the prone position, with a direct posterior transdural approach under fluoroscopic guidance. The procedures were performed under local infiltration anesthesia (skin, subcutaneous tissues, and paraspinal muscles) with 1% lidocaine (Xylocaine, Astra, Mississauga, Ontario, Canada). Patients were not premedicated or given other sedation. A double-needle technique was used, combining a 6.35-cm-long 20-gauge Quincke-type point needle (Becton Dickinson, Franklin Lakes, NJ) with a 14-cm-long 25-gauge Idakko needle (Havel's, Cincinnati, Ohio).

The short and larger-gauge needle was used as a leader and was inserted into the interspinous ligament, near the ligamentum flavum. The longer smaller-gauge needle was then inserted through the larger one and slowly inserted, through the dural sac, into the central third of the intervertebral disk space. The patient was then turned on the left side, and the position of the needle tip in the middle third of the disk, in the sagittal plane, was ascertained. A lateral test film was also obtained to provide a permanent record of the needle position before injection and to verify the adequacy of the technical radiographic factors.

Approximately 0.2 mL of iohexol (Omnipaque, Winthrop Laboratories, Aurora, Ontario, Canada) was then manually injected into each disk, using a 5-mL syringe, with fluoroscopic confirmation of intranuclear injection. A total of 0.25 to 2.5 mL of iohexol was then injected into each disk, the injected quantity being essentially limited by mechanical resistance to hand injection or patient tolerance to pain.

Stereoscopic anteroposterior and lateral radiographs of the lower lumbar region were then obtained as quickly as possible by experienced technicians, while the patient's reaction to the different injections was recorded by the radiologist. The films were generally developed and avail-

able for examination within 4 minutes after the last disk had been injected.

The final decision to include a patient in our series was made at this time, if the following two additional criteria were met: (a) reproduction of the patient's typical low back pain, including downward radiation to the lower extremity, by injection of one disk only; and (b) injection-provoked pain persisting with at least 50% of the intensity felt immediately after the contrast injection. Patients who had presenting symptoms of bilateral radiation to the lower extremity were included even if only unilateral radiation had been reproduced. In situations in which unilateral radiation had been the presenting symptom, patients were included if radiation below the gluteal fold had been reproduced in the homolateral lower limb, even though the characteristic topography of the usual radiation had not been entirely reproduced: for example, a patient with usual symptoms of low back pain with radiating pain to the buttock, thigh, lower leg, and foot was included if the contrast injection had reproduced homolateral radiation limited to the buttock and thigh only.

Thirty-three patients remained in the series after this new elimination process. The radiologist responsible for the procedure explained to each patient, at that time, that an anesthetic substance would now be injected inside the disk responsible for the pain, in the hope of reducing the pain. Patients were warned that this procedure could initially make their pain worse for a few seconds. One milliliter of 1% lidocaine was then slowly injected in the central portion of the disk, without moving the needle.

In 16 patients, the intradiskal pressure and resistance was so high that the lidocaine injection was not possible, and these patients had to be excluded. Our final series therefore consisted of 17 patients. The reasons for patient exclusion from the initial group of 235 patients are as follows:

Patients included in original series:	235
No reproduction of usual painful symptoms by any disk injection:	11
Reproduction of typical low back pain without typical lower extremity radiation:	95
Reproduction of typical low back pain and radiation in more than one disk:	74
Typical low back pain with lower extremity radiation, but mild and short lasting:	22
Impossible lidocaine injection because of high intradiskal pressure:	16
Patients included in definitive series:	17

The final series consisted of 15 men and 2 women. The mean patient age was 36 years (range, 23 to 56 years). All had low back pain with either unilateral (n = 9) or bilateral (n = 8) radiation to the lower extremity. They had been symptomatic for periods varying from 8 months to 9 years. The mean time interval between the latest previous imaging study and the diskograms was 5 months (range, 2 to 14 months).

Sixty seconds after the end of the lidocaine injection, these 17 patients were asked to evaluate the intensity of their pain by comparing it to the pain felt immediately after

the initial contrast injection. The following question was presented to all patients by the same investigator: "On a scale from 0 to 100, 0 being no relief at all, and 100 being complete relief, how do you evaluate your pain now, compared to the pain you felt immediately after the initial contrast injection?" (choice of 0%, 25%, 50%, 75%, and 100%). The patients were requested to assess separately their low back pain and their radiating pain.

Earlier in the study, 74 patients with multiple symptomatic disks had been excluded, because it would not have been possible to respect a uniform time interval to evaluate the effect of the lidocaine injection for all disks. In this subgroup, 20 patients received second injections of 1 mL of iohexol, in one of the symptomatic disks, because the initial set of radiographs did not show conclusive findings. This subset of patients served as a control group. A Welch's alternate *t* test was used for statistical analysis.

At the end of the procedure, we proposed to all patients, as part of our routine, an intradiskal (when possible) and epidural injection of steroids at the level(s) at which typical symptoms had been at least partly reproduced by the intradiskal injections of contrast. All qualifying patients agreed to this additional procedure, which involved injecting a total of 2 mL (80 mg) of methylprednisolone acetate (Depo-Medrol, Upjohn, Don Mills, Ontario, Canada) at each symptomatic level (the total dosage being divided in two or three equal injections in patients with multiple symptomatic disks). In all cases, the injection was begun when the tip of the needle was still in the center of the disk and was continued as the needle was being slowly pulled out to the anterior epidural space, the amount of fluid injected at each level being split equally, when possible, between the disk and the anterior epidural space. In pulling the needle out while simultaneously injecting, it was assumed that the tip of the needle was out in the anterior epidural space when an abrupt decrease in resistance to injection was felt. The different steps of the procedure are schematically illustrated in Figure 1.

Results

In the group of 17 patients in whom lidocaine had been injected, the reduction of low back pain was estimated as being 50% by 4 patients, 75% by 7 patients, and 100% by 6 patients. In the control group of 20 patients in whom iohexol had been injected, the low back pain was described as unchanged by 3 patients; the other patients evaluated the low back pain as being 25% worse ($n = 2$), 50% worse ($n = 6$), 75% worse ($n = 4$), and 100% worse ($n = 5$) (Fig 2). In the lidocaine group, the reduction of the radiating pain was evaluated as being 50% by 1 patient, 75% by 6 patients, and 100% by 10 patients. In the control group, the radiating pain was described as unchanged by 7 patients; the other patients evalu-

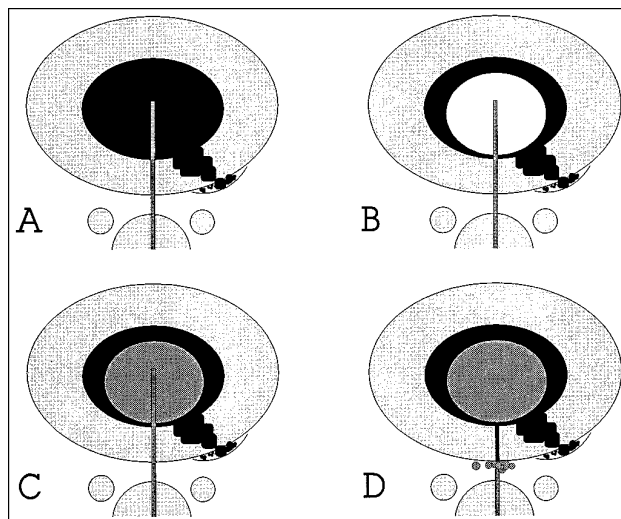


Fig 1. Schematic representation of the procedure.

A, Disk puncture using a central posterior transdural approach followed by contrast injection, demonstrating, in this case, a left posterolateral annular tear.

B, One milliliter of lidocaine (or additional contrast) is injected in the center of the disk.

C and D, Two milliliters of steroids are thereafter injected inside the disk and immediately behind the disk in the anterior epidural space.

ated the radiating pain as being 25% worse ($n = 2$), 50% worse ($n = 8$), 75% worse ($n = 2$), and 100% worse ($n = 1$) (Fig 3).

The mean percentage value for low back pain reduction was 79.41% in the lidocaine group, and -57.50% in the iohexol group. The mean percentage value for radiating pain reduction was 88.24% in the lidocaine group and -35.00% in the iohexol group. The two-tailed *P* value was $< .0001$, considered extremely significant, for both low back pain and radiating pain. In the lidocaine group, 13 patients (76%) reported a 75% to 100% reduction of their low back pain, whereas 16 patients (94%) reported a 75% to 100% reduction of their radiating pain. The lidocaine injection was thus more effective in alleviating the radiating pain than the low back pain.

The injection of steroids that followed the lidocaine or iohexol injection did not cause any pain as long as the tip of the needle was still within the disk; however, moderate to severe pain was felt by all patients in both groups as soon as the needle tip was in the anterior epidural space.

Sixteen of 17 disks that seemed responsible for the radiating pain in the 17 patients submitted to the lidocaine injection showed radial an-

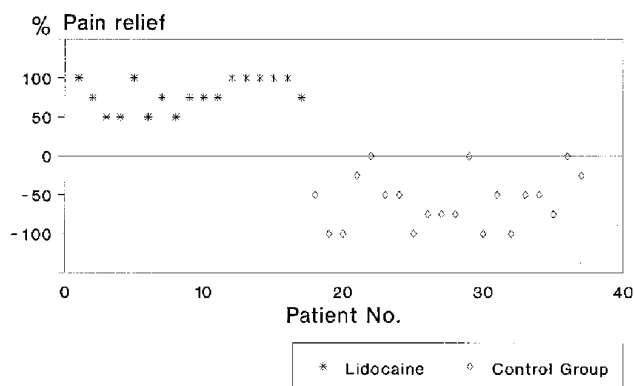


Fig 2. Low back pain reduction, 60 seconds after the end of injection of lidocaine or additional iohexol (control group). The difference between the two groups was statistically highly significant ($P < .0001$).

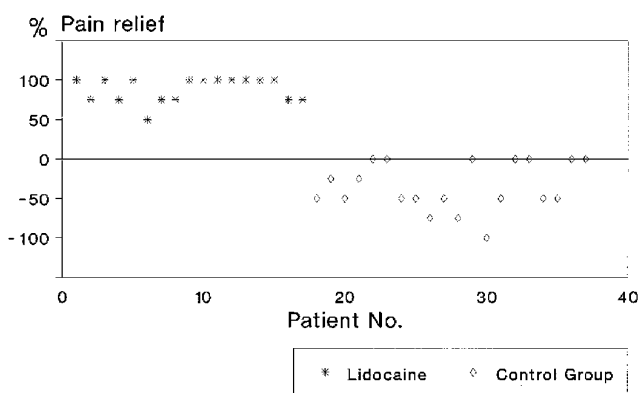


Fig 3. Radiating pain reduction, 60 seconds after the end of injection of lidocaine or additional iohexol (control group). The difference between the two groups was also highly significant ($P < .0001$). Lidocaine injection was more effective in alleviating radiating pain than low back pain.

nular tears extending either through the entire thickness of the annulus or to its external layers (Fig 4). One disk showed an incomplete anterior radial tear that seemed to reach the inner layers of the external part of the annulus (Fig 5). The involved disks and the locations of the tears seen are listed in the Table. It is noteworthy that, in 10 patients (59%), the symptomatic disk demonstrated a posterior central tear.

Discussion

Skepticism surrounding the concept of diskogenic pain is essentially derived from skepticism toward diskography, which is the only test with which we can diagnose this entity (24).

Lumbar diskography, introduced by Linblom in 1948 (25), has been a controversial subject, especially since the publication of Holt's article in 1968 (26). Holt performed three-level diskograms on 30 healthy young asymptomatic volunteers (prison inmates, 21 to 41 years old) and reported a 37% false-positive rate. He therefore concluded that diskography was an unreliable diagnostic test. Although the results of this study can be explained by major technical flaws that have since been exposed (27–29), Holt's contention is still being quoted as a major argument against the use of diskography.

The validity of diskography as a morphologic study demonstrating normal or abnormal lumbar disk anatomy has been clearly established in studies of postmortem specimens (30–33). Also, its reliability in evaluating disk integrity in vivo, provided careful and meticulous techniques are used, is conceded even by those who oppose its routine clinical use (34, 35). The validity of diskography as a pain-provoking test remains the real controversial issue. Those who question the value of diskography argue that, although a patient states on contrast injection in a disk that the pain experienced has the same distribution as the usual pain, this fact does not prove that this disk is really causing the symptoms (A. L. Nachemson, oral communication, 1992). Although we could not conceive an experimental protocol that would entirely solve this problem, we undertook the present study hoping to increase our knowledge of the role lumbar disks may play in generating low back pain and unilateral or bilateral radiating pain to the lower extremities.

Injection of a few drops of a local anesthetic inside a disk immediately after the initial contrast injection, to manage an unusually severe painful response, has been proposed by Collis (36) and used routinely for decades by experienced diskographers. Published data of estimated normal lumbar disk capacity show a considerable discrepancy, with figures ranging from 0.5 to 4.0 mL (36–41). In our experience, all normal disks will admit at least 1.0 mL of fluid, and most normal disks will admit 1.5 to 2.0 mL (by hand injection using a 5-mL ordinary plastic syringe). A ruptured disk generally admits larger amounts. By limiting to 1 mL the amount of lidocaine injected, we think it is most unlikely that spillage or diffusion of the anesthetic in the epidural space, with an anesthetic effect on spinal nerve roots, could explain the

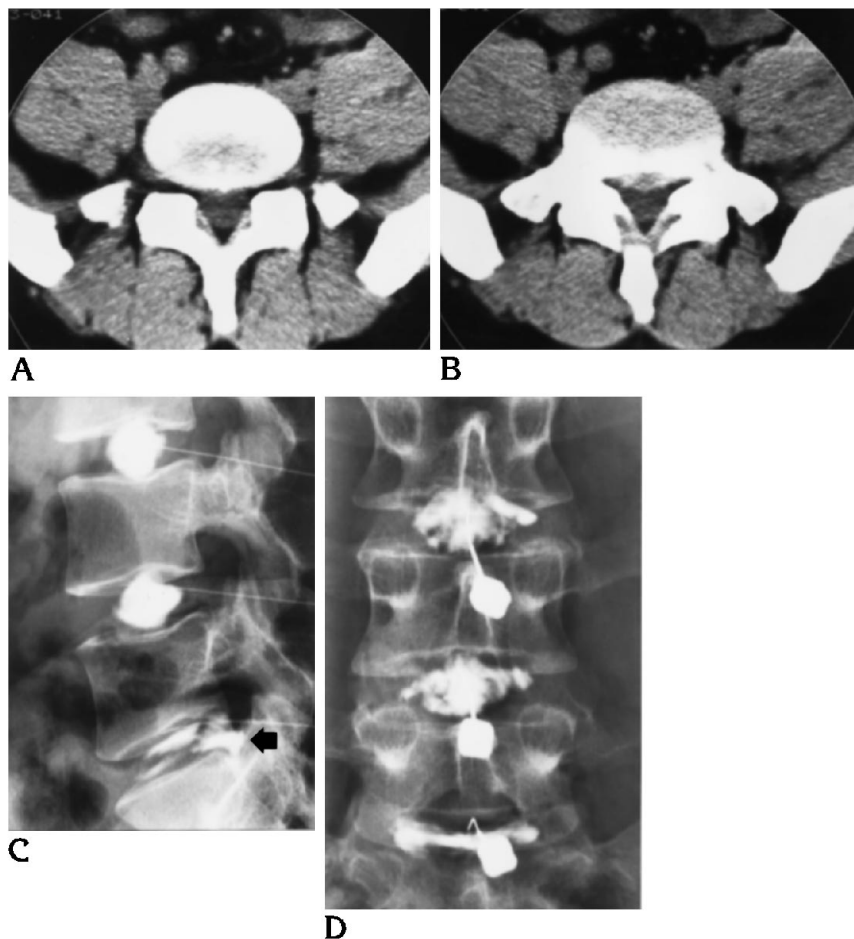


Fig 4. Patient 8, a 24-year-old man with low back pain radiating to both lower extremities.

A and *B*, Consecutive 5-mm-thick CT sections through the L5-S1 disk space show small posterior central herniation without obvious nerve root compression.

C, Three-level diskogram, lateral projection, shows complete rupture of the L5-S1 posterior annulus with reflux of contrast beyond the posterior margin of the disk space (*arrow*). Injection reproduced the patient's typical low back pain with radiation down the left buttock and thigh.

D, Anteroposterior view shows the central direction of the posterior annular tear.

marked reduction of the radiating pain that was reported 60 seconds after the injection.

The benefits of injecting steroids inside a disk and in the anterior epidural space are controversial (42–46), and the present study was not intended to assess the value and potential dangers of this procedure. However, the observation that, in all 17 patients injected with lidocaine as in the control group, the subsequent steroid injection was painless as long as the needle was still within the disk but created moderate to severe pain when the needle tip was pulled out into the anterior epidural space, offers additional evidence that the lidocaine had not reached the epidural structures, including the nerve roots, 60 seconds after the injection. This argument is also supported by the fact that 10 (59%) of 17 tears were found in the posterior and central direction; if the reduction of low back pain and radiating pain had resulted from lidocaine spilling through the tear and affecting the epidural pain-sensitive nerve endings, including the spinal nerve roots, the injection of

steroids directly behind the disk, in the anterior epidural space, should have been painless.

The results of our study suggest that the pain-sensitive structures responsible for the radiating pain to the lower extremity are located somewhere inside the disk, probably in the external part of the annulus fibrosus and in the longitudinal ligaments. The existence of such sensory nerve fibers and endings has recently been demonstrated in rats (47), and it is reasonable to infer that they probably also exist in humans.

The typical low back pain itself is probably reproduced by the sudden increase in intradiscal pressure with stretching of these nerve endings as a result of the initial contrast injection, rather than by irritation from the contrast medium. The following observations support this: (a) the pain is often violent and provoked immediately at the onset of injection when a very small tear is found; (b) when large posterior ruptures are found with intact posterior longitudinal ligament attachments to the vertebral body edges, the pain occurs at the end of the

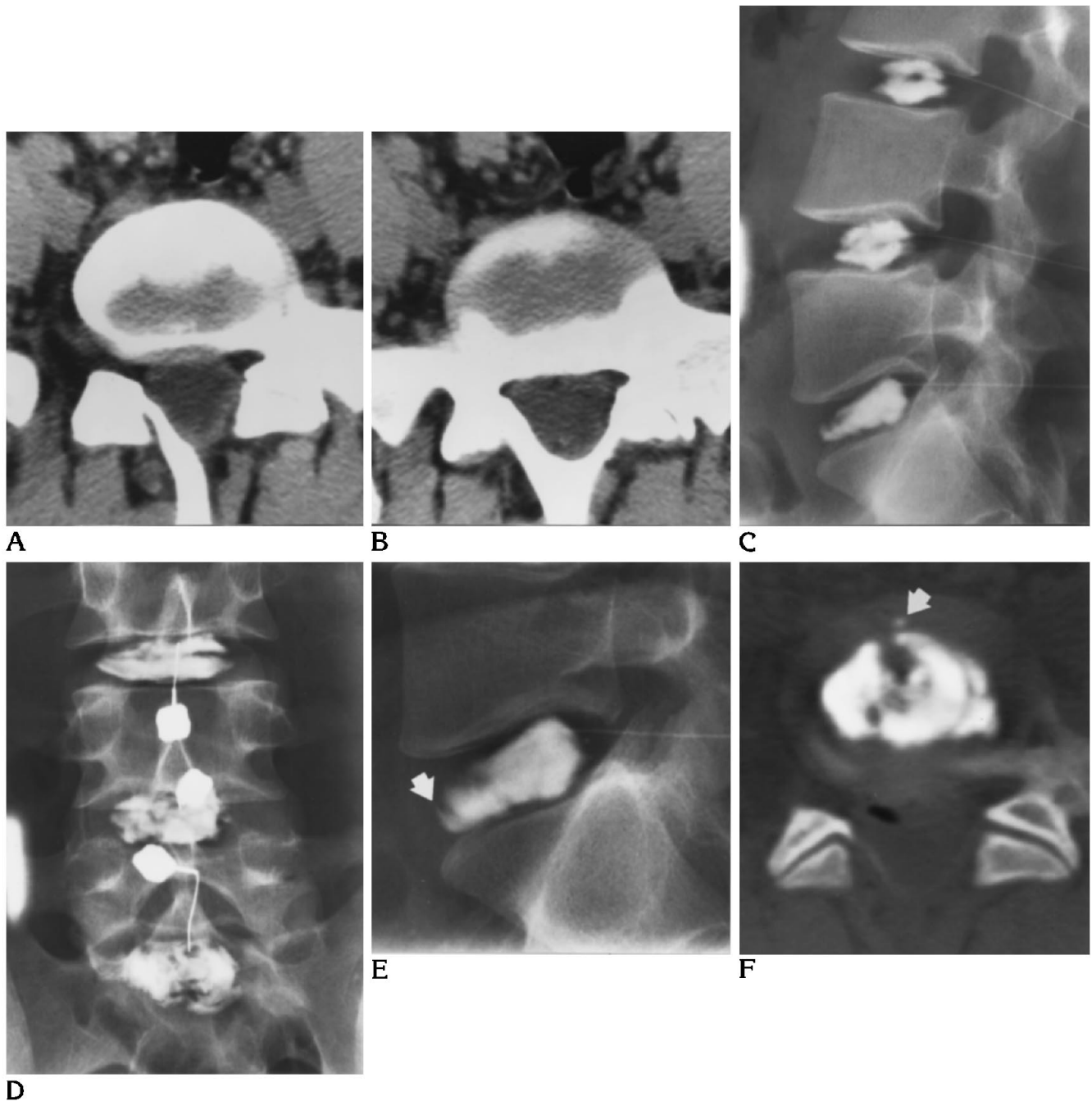


Fig 5. Patient 10, a 23-year-old man with low back pain radiating to the left buttock and left thigh.

A and B, Consecutive 5-mm-thick CT sections through the L5-S1 disk space (suboptimal because inclination of the disk plane exceeded the maximum gantry tilt capacity). The disk appears normal.

C and D, Three-level diskogram shows abnormal extension of contrast into the central anterior part of the annulus of the L5-S1 disk. Injection into the disk reproduced the patient's typical symptoms, including radiation to the left buttock and thigh. Injection of L3-4 and L4-5 disks did not cause any pain; these disks show a normal appearance.

E, Close-up lateral view of the L5-S1 disk shows incomplete rupture of the anterior annulus with extension of contrast to the approximate level of the inner concentric fibers of the outer part of the annulus (*arrow*).

F, Postdiskogram CT section through the L5-S1 disk (not part of the usual protocol) confirms the limited extension of the anterior tear to the approximate junction of the internal and external parts of annulus (*arrow*). This study also failed to demonstrate the left direction of the tear or additional tears leading to the left side of the disk, which could explain this patient's radiating pain to the left lower extremity.

Clinicoradiologic findings and results of intradiskal lidocaine injection in 17 patients with only one symptomatic disk

Case	Age, y/Sex	Duration of Symptoms	Type of Radiation	Diskography Levels	Reduction of Low Back Pain, %	Reduction of Radiating Pain, %	Symptomatic Disk	Type of Tear
1	38/M	6 mo	RLE	L3-4, L4-5, L5-S1	100	100	L5-S1	PM
2	56/M	2 y	LLE	L3-4, L4-5	75	75	L4-5	PM
3	26/M	4 y	RLE	L4-5, L5-S1	50	100	L5-S1	RPL
4	40/M	8 mo	RLE	L4-5, L5-S1	50	75	L5-S1	PM
5	48/F	3 y	LLE	L3-4, L4-5, L5-S1	100	100	L5-S1	MD
6	36/M	5 mo	RLE	L4-5, L5-S1	50	50	L4-5	RPL
7	30/M	1 y	BLE	L3-4, L4-5, L5-S1	75	75	L5-S1	PM
8	34/M	2 y	BLE	L3-4, L4-5, L5-S1	50	75	L5-S1	PM
9	23/M	10 mo	BLE	L3-4, L4-5, L5-S1	75	100	L5-S1	PM
10	23/M	3 y	LLE	L3-4, L4-5, L5-S1	75	100	L5-S1	ANT
11	42/F	5 y	BLE	L3-4, L4-5, L5-S1	75	100	L5-S1	LPL
12	31/M	7 mo	RLE	L3-4, L4-5, L5-S1	100	100	L5-S1	PM
13	37/M	9 y	BLE	L3-4, L4-5	100	100	L4-5	LPL
14	30/M	3 y	BLE	L5-S1	100	100	L5-S1	PM
15	53/M	2 y	LLE	L3-4, L4-5, L5-S1	100	100	L3-4	MD
16	30/M	1 y	BLE	L4-5, L5-S1	100	75	L5-S1	PM
17	38/M	4 y	BLE	L3-4, L4-5	75	75	L4-5	PM

Note.—BLE indicates bilateral lower extremity; LLE, left lower extremity; RLE, right lower extremity; ANT, anterior annular tear (incomplete); MD, multidirectional annular tears; LPL, left posterolateral annular tear; RPL, right posterolateral annular tear; and PM, posterior midline annular tear.

filling of the available closed space, when resistance to injection starts to be felt; (c) the provoked pain is generally less severe when there is a more extensive posterior tear with avulsion of the posterior longitudinal ligament attachments to the vertebral bodies and easy spillage of contrast in the anterior epidural space with practically no resistance to injection; in such cases, the total amount of injected contrast medium in one disk space may be doubled or tripled without causing more pain; and (d) we have observed no decrease in the frequency or severity of pain reproduction during lumbar diskograms since nonionic contrast media have replaced the more irritating ionic media.

Pain caused by stimulation and stretching of nerve endings during disk injection by contrast media seems related to the presence of an annular tear. Previous studies have shown a statistically highly significant correlation between the presence of radial tears and the creation of pain during disk injections: patients usually feel nothing or experience only mild to moderate pressure discomfort on intranuclear injection of a morphologically intact disk (48).

In our series, the lidocaine injection caused a 75% to 100% reduction of low back pain intensity in 13 patients (76%) and a 75% to 100% reduction of radiating pain in 16 patients (94%). The fact that the injection seemed more effective in relieving the radiating pain than the low

back pain might be because, in all but one patient, more than one disk was injected; the remaining pressure sensation from the injection of these other disks could easily have been confused with residual low back pain by the patients.

The radiating pain to the lower extremities that was markedly reduced by the lidocaine injection and that might be considered "radicular pain" by some observers seems to be a referred type of pain, unrelated in our series to disk material in the epidural space causing direct spinal nerve root compression or irritation. The mechanism for the production of this referred pain is not obvious. Contrary to what seems to be the case with low back pain, pressure does not seem sufficient to explain it. In patients with a localized partial or complete disk rupture, typical low back pain is reproduced by disk injection in almost all situations. The radiating pain is much more difficult to reproduce. In our initial series of 235 patients with presenting low back pain and unilateral or bilateral radiating pain below the gluteal fold, only the typical low back pain could be reproduced in 95 patients. In many patients we found very frustrating the fact that the typical radiating pain could not be reproduced during injection of disks with contrast media, although radiographs clearly showed complete radial annular ruptures on the usual clinical side of the pain. A referred type of pain

seems to be, by exclusion, the only acceptable explanation. The concept of sciatica as a referred pain syndrome is not new (49). The mechanisms of referred pain have very complex patterns that we are just beginning to understand (50).

By recreating a patient's painful symptoms with an injection of contrast medium in a disk demonstrating an annular tear, and then relieving these symptoms by injecting a local anesthetic with a range of action that did not seem to extend beyond the disk margins, our study supports the existence of diskogenic pain and leads to the conclusion that a simple disk rupture, without direct nerve root compression by disk material, can account for low back pain with radiating pain to the leg. At these disk levels, CT may show no abnormality, or an unimpressive broad- or narrow-based bulge of the disk margin, whereas MR is likely to show, in addition, a partial loss of disk signal intensity on a T2-weighted image. The referring physician should be alerted that these CT or MR images may well represent disk ruptures that could explain a patient's radiating pain to the leg. The fact that these disks are generally labeled "degenerated bulging disks" misleads the referring physician and the patient to think that the cause of the symptoms has not been identified. This problem situation may then lead the patient to consult another physician, who will perhaps request a diskogram with the sole purpose of demonstrating what should have been at least suspected on the noninvasive imaging studies. We support the view that diskography should be reserved for exceptional problematic cases (51), but we agree with Swartz (52) that we should benefit from lessons derived from the interpretation of diskography to refine our interpretation of CT and MR images.

References

- Nachemson AL. Newest knowledge of low back pain (editorial comment). *Clin Orthop* 1992;279:2
- Taveras J. Radiological aspects of low back pain and sciatic syndromes (editorial). *AJNR Am J Neuroradiol* 1989;10:451-452
- Modic MT, Ross JS. Morphology, symptoms and causality. *Radiology* 1990;175:619-620
- Enzmann DR. On low back pain. *AJNR Am J Neuroradiol* 1994;15:109-113
- Mixter WJ, Barr JS. Rupture of the intervertebral disc with involvement of the spinal canal. *N Engl J Med* 1934;211:210-214
- Kieffer SA, Sherry RG, Wellenstein DE, King RB. Bulging lumbar intervertebral disk: myelographic differentiation from herniated disk with nerve root compression. *AJNR Am J Neuroradiol* 1982;3:51-58
- Kieffer SA, Cacayorin ED, Sherry RG. The radiological diagnosis of herniated lumbar intervertebral disk. *JAMA* 1984;251:1192-1195
- Thornbury JR, Fryback DG, Turski PA, et al. Disk-caused nerve compression in patients with acute low-back pain: diagnosis with MR, CT myelography, and plain CT. *Radiology* 1993;186:731-738
- Smyth MJ, Wright V. Sciatica and the intervertebral disc. *J Bone Joint Surg [Am]* 1958;40:1401-1418
- Olmarker K, Rydevik B, Holm S. Edema formation in spinal nerve roots induced by experimental, graded compression. *Spine* 1989;14:569-573
- McCarron RF, Wimpee MW, Hudgkins PG, et al. The inflammatory effect of the nucleus pulposus. *Spine* 1987;12:759-764
- Parke WW. The significance of venous return impairment in ischemic radiculopathy and myelopathy. *Orthop Clin North Am* 1991;22:213-221
- Marshall LL, Trethewie ER, Curtain CC. Chemical radiculitis. *Clin Orthop* 1977;129:61-67
- Jaffray D, O'Brien JP. Isolated intervertebral disc resorption. A source of mechanical and inflammatory back pain. *Spine* 1986;11:397-401
- Park WM, McCall IW, O'Brien JP, Webb JK. Fissuring of the posterior annulus fibrosus in the lumbar spine. *Br J Radiol* 1979;52:382-387
- Naylor A, Happey F, Turner RL, West DC. Enzymatic and immunological activity in the intervertebral disc. *Orthop Clin North Am* 1975;6:51-58
- Crock HV. Internal disc disruption. A challenge to disc prolapse fifty years on. *Spine* 1986;11:650-653
- Weinstein J, Claverie W, Gibson S. The pain of discography. *Spine* 1988;13:1344-1348
- Jenkins JR, Whittemore AR, Bradley WG. The anatomic basis of vertebrogenic pain and the autonomic syndrome associated with lumbar disk extrusion. *AJNR Am J Neuroradiol* 1989;10:219-231
- Konttinen YT, Gronblad M, Antti-Poika I, et al. Neuroimmunohistochemical analysis of peridiscal nociceptive neural elements. *Spine* 1990;15:383-386
- Kuslich SD, Ulstrom CL, Michale CJ. The tissue origin of low back pain and sciatica: a report of pain response to tissue stimulation during operations on the lumbar spine using local anesthesia. *Orthop Clin North Am* 1991;22:181-187
- Weinstein J. Neurogenic and nonneurogenic pain and inflammatory mediators. *Orthop Clin North Am* 1991;22:235-246
- Ross JS, Modic MT, Masaryk TJ. Tears of the annulus fibrosus: assessment with Gd-DTPA-enhanced MR imaging. *AJNR Am J Neuroradiol* 1989;10:1251-1254
- Bernard TN. Lumbar discography followed by computed tomography. Refining the diagnosis of low-back-pain. *Spine* 1989;15:690-707
- Linblom K. Diagnostic puncture of intervertebral disks in sciatica. *Acta Orthop Scand* 1948;17:231-239
- Holt EP. The question of lumbar discography. *J Bone Joint Surg* 1968;50:720-726
- Milette PC, Melanson D. Lumbar discography (letter). *Radiology* 1987;163:828-829
- Simmons JW, Aprill CN, Dwyer AP, Brodsky AE. A reassessment of Holt's data on: "the question of lumbar discography." *Clin Orthop* 1988;237:120-124

29. Walsh TR, Weinstein JN, Spratt KF, Lehmann TR, Aprill C, Sayre H. Lumbar discography in normal subjects. *J Bone Joint Surg [Am]* 1990;72:1081-1088
30. Erlacher PR. Nucleography. *J Bone Joint Surg [Br]* 1952;34:204-210
31. Kieffer SA, Stadlan EM, Mohandas A, Peterson HO. Discographic-anatomical correlation of developmental changes with age in the intervertebral disc. *Acta Radiol* 1969;9:733-739
32. Adams MA, Dolan P, Hutton WC. The stages of disc degeneration as revealed by discograms. *J Bone Joint Surg [Br]* 1986;68:36-41
33. Yu S, Haughton VM, Sether LA, Wagner M. Comparison of MR and discography in detecting radial tears of the annulus: a postmortem study. *AJNR Am J Neuroradiol* 1989;10:1077-1081
34. Nachemson A. Lumbar discography—where are we today? (editorial comment). *Spine* 1989;14:555-557
35. Bell GR, Modic MT. Radiology of the lumbar spine. In: Rothman RH, Simeone FA, eds. *The Spine*. Philadelphia: Saunders, 1992: 137-138
36. Collis JS. *Lumbar discography*. Springfield: Charles C. Thomas, 1963
37. Feinberg SB. The place of diskography in radiology as based on 2,320 cases. *AJR Am J Roentgenol* 1965;92:1275-1281
38. Legré M, Dufour M, Debaene A, Dalmas J, Burrou A. La discographie lombaire. Valeur et indications après 300 examens. *Neurochirurgie* 1971;17:559-578
39. Patrick BS. Lumbar discography: a five year study. *Surg Neurol* 1973;1:267-273
40. Sachs BL, Vanharanta H, Spivey MA, et al. Dallas discogram description: a new classification of CT/discography in low-back disorders. *Spine* 1987;12:287-294
41. Fabris G, Lavaroni A, Leonardi M. *Discography*. Udine: Edizioni del Centauro, 1991
42. Feffer HL. Treatment of low back pain and sciatic pain by the injection of hydrocortisone into degenerated intervertebral discs. *J Bone Joint Surg [Am]* 1956;38:585-592
43. Feffer HL. Regional use of steroids in the management of lumbar intervertebral disc disease. *Orthop Clin North Am* 1975;6:249-253
44. Graham CE. Chemonucleolysis: a preliminary report on a double blind study comparing chemonucleolysis and intradiscal administration of hydrocortisone in the treatment of backache and sciatica. *Orthop Clin North Am* 1975;6:259-263
45. Wilkinson HA, Schuman N. Intradiscal corticosteroids in the treatment of lumbar and cervical disc problems. *Spine* 1980;5:385-389
46. Simmons JW, McMillin JN, Emery SF, Kimmich SJ. Intradiscal steroids. *Spine* 1992;17(suppl):S172-S175
47. McCarthy PW, Carruthers B, Petts P. Immunohistochemical demonstration of sensory fibers and endings in lumbar intervertebral discs of the rat. *Spine* 1991;16:653-655
48. Milette PC, Melanson D. A reappraisal of lumbar discography. *Can Assoc Radiol J* 1982;33:176-182
49. King JS, Lagger R. Sciatica viewed as a referred pain syndrome. *Surg Neurol* 1976;5:46-50
50. Jinkins JR. The pathoanatomic basis of somatic and autonomic syndromes originating in the lumbosacral spine. *Neuroimaging Clin North Am* 1993;3:443-463
51. Greenspan A, Amparo EG, Gorczyca DP, Montesano PX. Is there a role for discography in the era of magnetic resonance imaging? Prospective correlation and quantitative analysis of computed tomography-discography, magnetic resonance imaging, and surgical findings. *J Spinal Disord* 1992;5:26-31
52. Swartz JD. Letter from the guest editor: protrusion, extrusion . . . confusion! *Semin Ultrasound CT MRI* 1993;14:383-384

Please see the commentary on page 1614 in this issue.