

Are your **MRI contrast agents** cost-effective?

Learn more about generic **Gadolinium-Based Contrast Agents**.



FRESENIUS  
KABI

caring for life

**AJNR**

**Rupture of a cerebral aneurysm during embolization for a cerebral arteriovenous malformation.**

T Abe, S Nemoto, T Iwata, M Shimazu, K Matsumoto and K Liu

*AJNR Am J Neuroradiol* 1995, 16 (9) 1818-1820

<http://www.ajnr.org/content/16/9/1818>

This information is current as of April 18, 2024.

---

# Rupture of a Cerebral Aneurysm during Embolization for a Cerebral Arteriovenous Malformation

Takumi Abe, Shigeru Nemoto, Takanobu Iwata, Motohiko Shimazu, Kiyoshi Matsumoto, and Kiyotaka Liu

**Summary:** An aneurysm ruptured during superselective catheterization into the posterior cerebral artery for a left temporal arteriovenous malformation. The rupture may have been caused by stretching and displacement of the basilar and posterior cerebral arteries while the microcatheter with guide wire was advanced.

**Index terms:** Arteriovenous malformations, embolization; Iatrogenic disease or disorder; Interventional neuroradiology, complications

Endovascular embolization procedures have undergone dramatic evolution in recent years. Despite these advances, complications of embolization have been reported (1–4). Mechanical vascular perforations caused by catheters and guide wires have been described (2, 4). We report the rupture of an aneurysm on a feeding artery of the arteriovenous malformation during superselective catheterization.

## Case Report

A 38-year-old man presented with a generalized seizure disorder. There was no significant family history. Computed tomography and magnetic resonance imaging demonstrated a large arteriovenous malformation nidus approximately 4 cm in diameter with enlarged variceal drainage in the left temporal lobe (Fig 1A). Left vertebral angiography revealed a large high-flow arteriovenous malformation fed by the posterior cerebral artery and a small aneurysm of the proximal posterior cerebral artery (Fig 1B, C). The arteriovenous malformation also was fed by the meningohypophyseal artery and drained into the left transverse sinus through a varix. According to the classification of Spetzler and Martin (5), this arteriovenous malformation was grade III. Combined therapy with endovascular embolization and stereotactic radiosurgery was planned. Endovascular embolization was performed 2 months later. A Tracker-18 catheter (Target Therapeutics, San Jose, Calif) was placed superselectively into a branch

of the left posterior cerebral artery, which was a feeding artery to the arteriovenous malformation. After a provocation test, embolization with silk suture was performed, and the feeder was occluded. The catheter was then removed. Another branch of the left posterior cerebral artery was cannulated with a Tracker-18 catheter. While the catheter was being advanced, the basilar bifurcation was displaced slightly. Suddenly, the patient reported a severe headache and became comatose within a few minutes. Left vertebral angiography demonstrated enlargement of the posterior cerebral artery aneurysm with extravasation (Fig 1D). The vertebrobasilar system was patent. Computed tomography was performed, which showed a massive subarachnoid hemorrhage (Fig 1E). The ruptured aneurysm of the left posterior cerebral artery was successfully surgically clipped, and the patient gradually recovered. Hydrocephalus subsequently developed 3 months after the hemorrhage and was treated by shunting. A second endovascular embolization was performed for the residual arteriovenous malformation nidus on July 9, 1993. With superselective catheterization of the left posterior cerebral artery branch with a Magic 1.8-F catheter (Bal, France), embolization was carried out without difficulty. Magnetic resonance imaging demonstrated that the arteriovenous malformation nidus was reduced to approximately 2.5 cm in diameter. Stereotactic radiosurgery was performed 2 months after completion of staged embolization. The patient was discharged without neurologic deficits 6 months after admission.

## Discussion

Recently, endovascular embolization procedures and radiosurgery have benefited from dramatic technical advances. Several patients with large arteriovenous malformations in the area of eloquence have been selected for combined therapy with embolization followed by radiosurgery of the residual nidus (3, 6). In most cases, endovascular treatment reduces the size

---

Received September 20, 1994; accepted after revision February 13, 1995.

From the Department of Neurological Surgery, Showa University School of Medicine (T.A., T.I., M.S., K.M.), the Department of Neurological Surgery, Tokyo University School of Medicine (S.N.), and the Department of Radiology, Kikuna Memorial Hospital (K.L.), Tokyo, Japan.

Address reprint requests to Takumi Abe, MD, Department of Neurological Surgery, Showa University School of Medicine, 5-8 Hatanodai, Shinagawa-ku, Tokyo 142, Japan.

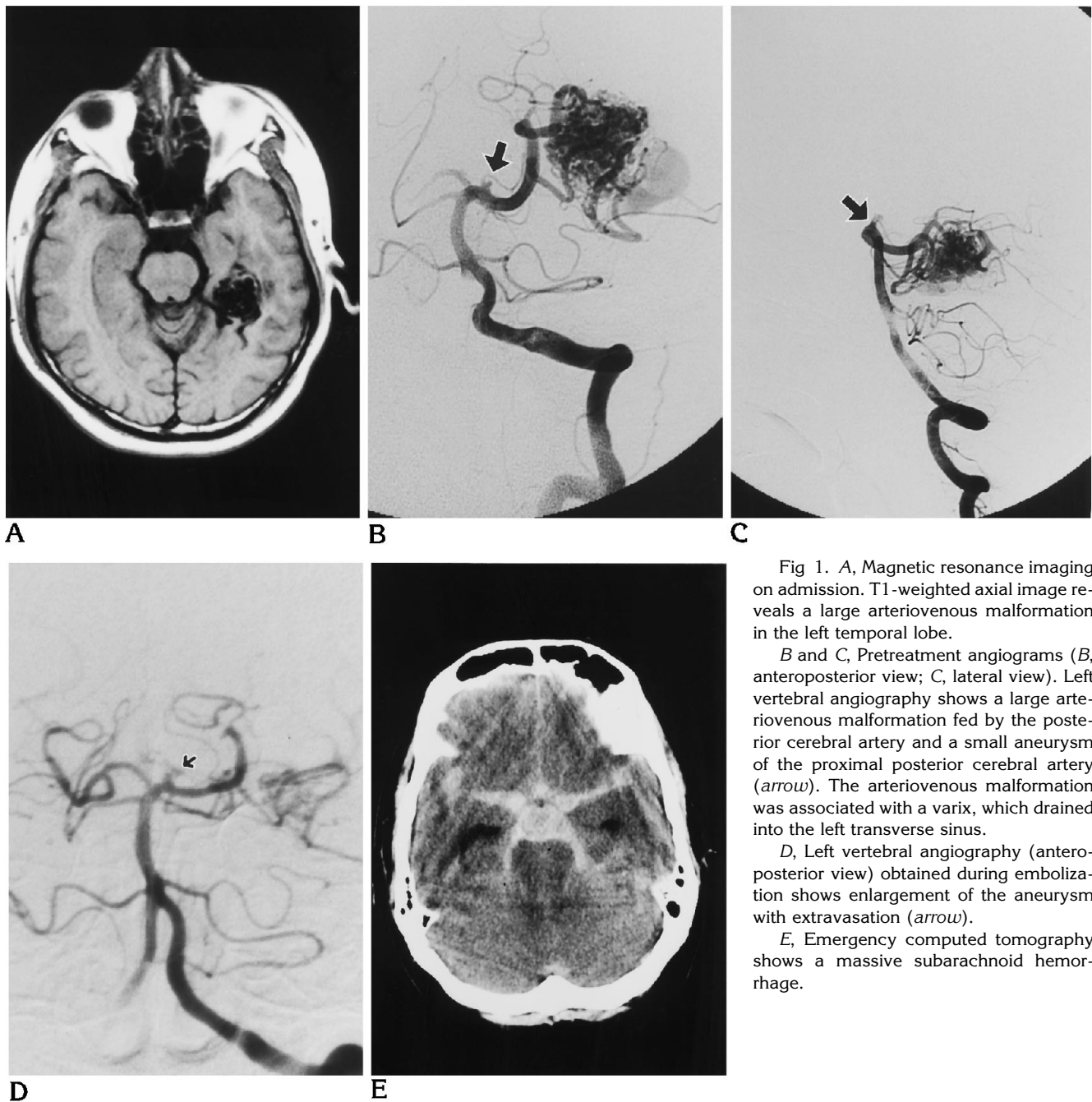


Fig 1. A, Magnetic resonance imaging on admission. T1-weighted axial image reveals a large arteriovenous malformation in the left temporal lobe.

B and C, Pretreatment angiograms (B, anteroposterior view; C, lateral view). Left vertebral angiography shows a large arteriovenous malformation fed by the posterior cerebral artery and a small aneurysm of the proximal posterior cerebral artery (arrow). The arteriovenous malformation was associated with a varix, which drained into the left transverse sinus.

D, Left vertebral angiography (anteroposterior view) obtained during embolization shows enlargement of the aneurysm with extravasation (arrow).

E, Emergency computed tomography shows a massive subarachnoid hemorrhage.

of the arteriovenous malformation, allowing treatment with surgery or stereotactic radiosurgery.

Despite the development of softer steerable guide wires and microcatheters, soft detachable balloons, and road-mapping techniques, vascular perforations may sometimes occur during endovascular procedures. Halbach et al (4) have reported that vascular perforations could be grouped into three probable mechanisms: mechanical perforation of a normal vessel, me-

chanical disruption of a dysplastic vessel or aneurysm, and fluid overinjection. In our case, although a Tracker-18 catheter had passed through a feeding artery of the arteriovenous malformation, a proximal aneurysm on the feeder ruptured.

Intraluminal pressure in the feeding artery increases as a result of embolization, which may cause the hemorrhage from the arteriovenous malformation (7-9). Handa et al (7) have reported that the pressure in the feeding artery

was more significantly increased after an effective embolization than after a poor embolization. Partial occlusion of the nidus would thus avoid significant increases in intraluminal pressure. In our case, only a small portion of the arteriovenous malformation nidus was occluded before the bleeding occurred. Hemodynamic changes, then, could not have been the cause of bleeding.

The mechanism of rupture of the aneurysm was postulated to result from mechanical traction. The basilar and posterior cerebral arteries were stretched and displaced during catheterization with the guide wire, which caused mechanical traction on the small aneurysm, resulting in rupture. In this regard, manipulation of a floppy catheter without a guide wire would be safer in cases with similar anatomy.

During superselective catheterization, advancing a guide wire into an artery with a fragile structure including aneurysms has the potential to cause hemorrhage. A floppy catheter without a guide wire could be used to avoid such risk. When using a guide wire, a fine-tipped guide wire with a soft shaft should be selected, and special efforts to avoid hazardous tension on the vessels should be made.

## References

1. Schumacher M, Horton JA. Treatment of cerebral arteriovenous malformations with PVA: results and analysis of complications. *Neuroradiology* 1991;33:101-105
2. Purdy PD, Batjer HH, Samson D. Management of hemorrhagic complications from preoperative embolization of arteriovenous malformations. *J Neurosurg* 1991;74:205-211
3. Fournier D, TerBrugge KG, Willinsky R, Lasjaunias P, Montanera W. Endovascular treatment of intracerebral arteriovenous malformations: experience in 49 cases. *J Neurosurg* 1991;75:228-233
4. Halbach VV, Higashida RT, Dowd CF, Barnwell SL, Hieshima GB. Management of vascular perforations that occur during neurointerventional procedures. *AJNR Am J Neuroradiol* 1991;12:319-327
5. Spetzler RF, Martin NA. A proposed grading system for arteriovenous malformations. *J Neurosurg* 1986;65:476-483
6. Dawson III RC, Tarr RW, Hecht ST, et al. Treatment of arteriovenous malformations of the brain with combined embolization and stereotactic radiosurgery: results after 1 and 2 years. *AJNR Am J Neuroradiol* 1990;11:857-864
7. Handa T, Negoro M, Miyachi S, Sugita K. Evaluation of pressure changes in feeding arteries during embolization of intracerebral arteriovenous malformations. *J Neurosurg* 1993;79:383-389
8. Jungreis CA, Horton JA, Hecht ST. Blood pressure changes in feeders to cerebral arteriovenous malformations during therapeutic embolization. *AJNR Am J Neuroradiol* 1989;10:575-577
9. Spetzler RF, Hargraves RW, McCormick PW, Zabramski JM, Flom RA, Zimmerman RS. Relationship of perfusion pressure and size to risk of hemorrhage from arteriovenous malformations. *J Neurosurg* 1992;76:918-923