

Are your **MRI contrast agents** cost-effective?

Learn more about generic **Gadolinium-Based Contrast Agents**.



**FRESENIUS  
KABI**

caring for life

**AJNR**

**Lymph node metastases from glioblastoma  
multiforme.**

C J Wallace, P A Forsyth and D R Edwards

*AJNR Am J Neuroradiol* 1996, 17 (10) 1929-1931

<http://www.ajnr.org/content/17/10/1929>

This information is current as  
of April 17, 2024.

---

# Lymph Node Metastases from Glioblastoma Multiforme

Carla J. Wallace, Peter A. Forsyth, and Dylan R. Edwards

**Summary:** Extranodal metastases from glioblastoma multiforme are rare. Spread to the extracranial head and neck may be evident on routine follow-up images of the original lesion. We present two cases, one with documented metastatic adenopathy in the head and neck from glioblastoma and the other with probable metastatic disease in a lymph node in which biopsy was not performed, and discuss probable mechanisms of extraneural extension of this tumor.

**Index terms:** Glioblastoma multiforme; Neck, neoplasms

Head and neck metastases from glioblastoma multiforme (GBM) are rare, but they can be disfiguring and debilitating. Metastatic deposits of GBM may be found in the skull, scalp, and neck. They may be detectable on routine follow-up imaging of patients with GBM, and can alter therapy and prognosis. We describe two cases of GBM with cervical extraneural metastases and discuss possible mechanisms of extraneural spread of this tumor.

## Case Reports

### Case 1

A 41-year-old man had a 3-week history of headache, nausea and vomiting, and a mild left hemiparesis. Computed tomography (CT) showed a large enhancing mass of the right frontal lobe (Fig 1A). Craniotomy was performed with gross total resection of a GBM. The patient was treated with 6000 cGy of external beam radiation therapy and two cycles of chemotherapy with carmustine. Three months later, a rubbery mass developed just behind the scalp incision. Fine-needle aspiration was nondiagnostic and there was no improvement with antibiotics. Painful bilateral cervical adenopathy developed (Fig 1B and C), and results of a lymph node biopsy showed metastatic GBM. Further external beam radiation therapy (4500 cGy) was delivered to the patient's scalp and neck, and he received 3 weeks of chemotherapy. He died 8 months after surgery of repeated aspiration due to recurrent right-sided laryngeal nerve palsy caused by massive cervical adenop-

athy. Autopsy showed metastatic GBM in the cervical and supraclavicular lymph nodes. Only a thin rim of residual tumor was seen at the original resection site. GBM was also found in the extraocular muscles and limbus of the right eye.

### Case 2

A 39-year-old man had a 3-week history of progressive headache and episodic metamorphopsia. CT scans showed a cystic lesion with peripheral enhancement in the right frontal temporal region. An anterior temporal lobectomy revealed a GBM. The patient received radiation therapy (6000 cGy), but 5 months later he had progressive headache, drowsiness, and numbness on the right side of the face, nose, and tongue. CT and magnetic resonance (MR) studies (Fig 2A and B) showed a local recurrence with extension through the overlying skull and along the anterior fossa into the right orbit. A second mass in the preauricular lymph node region had the same signal characteristics and was consistent with a GBM metastasis; no biopsy was performed. A second craniotomy was performed with subtotal removal of the GBM. Neck and facial swelling progressed, and the patient died 7 months after the first surgery.

## Discussion

Extranodal metastases from GBM or other gliomas are surprisingly rare, as these are highly malignant tumors. Since a report in 1928 (1), approximately 250 cases have been reported (2). The most common sites of extraneural metastases from GBM are lungs and pleura, liver, mediastinal and cervical lymph nodes, and bone or bone marrow (3). At least 24 well-documented cases of cervical lymph node metastases from GBMs have been reported (2, 4–7).

In our two cases, MR studies were useful in confirming the diagnosis and altering patient treatment. In patient 1, the increase in adenop-

---

Received October 13, 1995; accepted after revision February 14, 1996.

From the Departments of Diagnostic Imaging (C.J.W.) and Clinical Neurosciences (P.A.F.), Foothills Hospital, Calgary, and the Cancer Biology Research Group, University of Calgary (D.R.E.), Alberta, Canada.

Address reprint requests to Carla Wallace, MD, Department of Radiology, Foothills Hospital, 1403 29 St NW, Calgary, Alberta, Canada T2N 2T9.

AJNR 17:1929–1931, Nov 1996 0195-6108/96/1710–1929 © American Society of Neuroradiology

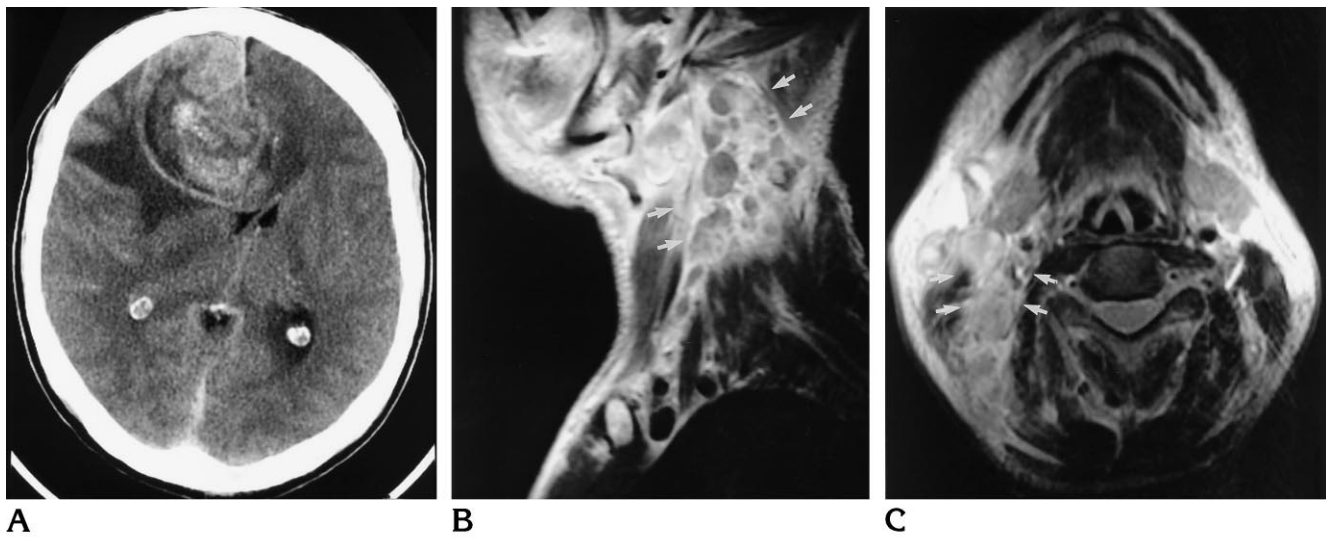
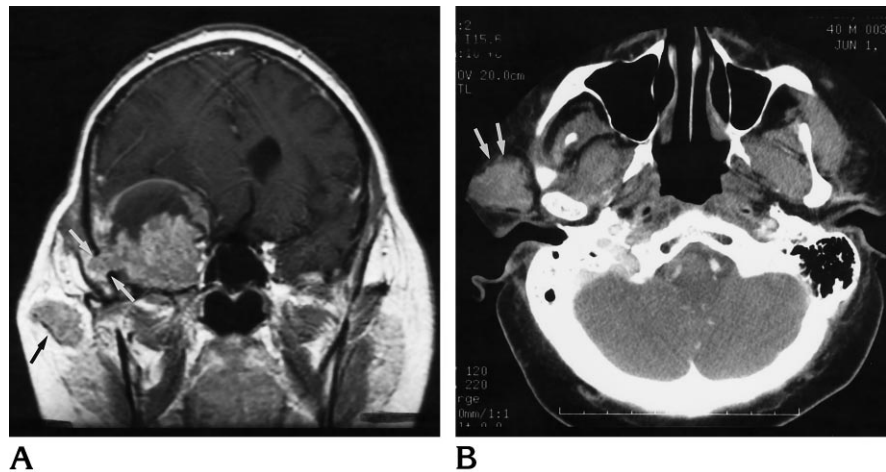


Fig 1. Case 1: 41-year-old man with a 3-week history of headache, nausea, and vomiting, and a mild left hemiparesis.  
 A, Contrast-enhanced CT scan shows irregularly enhancing mass in the right frontal lobe, extending into the genu of the corpus callosum, with moderate mass effect and edema.  
 B and C, Contrast-enhanced right parasagittal T1-weighted (500/14/2 [repetition time/echo time/excitations]) and axial T2-weighted (2000/80/1) MR images of the neck, respectively, show extensive adenopathy in the deep cervical and spinal accessory chains (*arrows*).

Fig 2. Case 2: 39-year-old man with a 3-week history of progressive headache and episodic metamorphopsia.

A, Contrast-enhanced coronal T1-weighted MR image (600/19/2) shows extension of right temporal mass through the craniotomy defect (*white arrows*) as well as a separate right-sided preauricular mass (*black arrow*).

B, Contrast-enhanced CT scan shows the preauricular mass (*arrow*).



athy seen on MR images after a trial of intravenous antibiotics convinced us to pursue an open lymph node biopsy even though the fine-needle aspiration was nondiagnostic. Although a tissue diagnosis was not obtained on the lymph node in patient 2, its imaging features and proximity to the transcranial extension were considered to be diagnostic of extraneural metastases and helped to determine further treatment. The presence of extraneural metastases does not significantly affect the already dismal prognosis of recurrent GBM, but appropriate therapy may make the patient more comfortable.

It is puzzling that extraneural metastases from GBMs are so rare in light of their highly malignant nature. Presumably, GBMs are prevented from metastasizing by the relatively impassable dura, by the extracellular matrix, by the tough basement membrane that surrounds intracerebral blood vessels, and by the lack of true lymphatics in the brain. Extraneural metastases from GBMs are seen most commonly with procedures that give the glioma cells access to extrameningeal structures, such as ventricular shunting or repeated craniotomies. In most cases of lymph node involvement the patient has undergone repeated craniotomies (7), and

presumably the tumor gains access to lymphatics by dural or scalp extension through the surgical defect. However, these factors do not explain the occurrence of extraneural metastases in all patients, and there are reports of lymph node or distant metastases before surgery, with no clinical or radiologic evidence of transgression of scalp or skull (2, 5). In some patients the properties of the tumor cells themselves may predispose to metastases.

Metastasis to the head and neck in patients with GBMs may rarely be seen on routine follow-up imaging studies (as in patient 2) and this information is important clinically. In addition to an assessment of the intracranial contents, the neuroradiologist should not omit a careful assessment of the extracranial structures visible on follow-up brain imaging.

## References

1. Davis L. Spongioblastoma multiforme of the brain. *Ann Surg* 1928;87:8-14
2. Pasquier B, Pasquier D, N'golet A, et al. Extraneural metastases of astrocytomas and glioblastomas: clinicopathological study of two cases and review of literature. *Cancer* 1980;45:112-125
3. Liwnicz BH, Rubinstein LJ. The pathways of extraneural spread in metastasizing gliomas: a report of three cases and review of the literature. *Hum Pathol* 1979;10:453-467
4. El-Gindi S, Salama M, El-Henawy M, Farag S. Metastases of glioblastoma multiforme to cervical lymph nodes: report of two cases. *J Neurosurg* 1973;38:631-634
5. Dolman CL. Lymph node metastasis as first manifestation of glioblastoma. *J Neurosurg* 1974;41:607-609
6. Zappia JJ, Wolf GT. Cervical metastatic glioblastoma multiforme. *Arch Otolaryngol Head Neck Surg* 1992;118:755-756
7. Campora RG, Salaverri CO, Ramirez FV, Villadiego MS, Davidson HG. Metastatic glioblastoma multiforme in cervical lymph nodes: report of a case with diagnosis by fine needle aspiration. *Acta Cytol* 1993;37:938-942