Are your MRI contrast agents cost-effective?
Learn more about generic Gadolinium-Based Contrast Agents.
FRESENIUS KABI
caring for life

AJNR

Reversible empty sella in idiopathic intracranial hypertension: an indicator of successful therapy?

M T Zagardo, W S Cail, S E Kelman and M I Rothman

AJNR Am J Neuroradiol 1996, 17 (10) 1953-1956
http://www.ajnr.org/content/17/10/1953

This information is current as of April 19, 2024.

Reversible Empty Sella in Idiopathic Intracranial Hypertension: An Indicator of Successful Therapy?

Michael T. Zagardo, Wayne S. Cail, Shalom E. Kelman, and Michael I. Rothman

Summary: Idiopathic intracranial hypertension is commonly associated with an empty sella, caused by herniation of subarachnoid cerebrospinal fluid through an absent or patulous diaphragma sellae. We describe the findings in two patients who presented with headache, papilledema, and visual disturbances. Diagnosis of idiopathic intracranial hypertension was made on the basis of clinical symptoms and laboratory data. Initial imaging studies in each patient showed an empty sella. After treatment, one with acetazolamide and the other with lumboperitoneal shunting, the appearance of the sellar contents became normal.

Index terms: Hypertension; Pseudotumor cerebri; Sella turcica, empty

We present the findings of two patients with idiopathic intracranial hypertension in which initial imaging studies revealed empty sellae. After treatment, follow-up magnetic resonance (MR) images showed normal sellar contents.

Case 1

An 18-year-old woman was referred for evaluation of papilledema and headache. She initially noted neck and occipital head pain that lasted for approximately 1 to 2 weeks. Blurred vision developed and she was referred to an ophthalmologist. The patient's history was significant for recent weight gain (22.5 kg) and the use of medroxyprogesterone acetate for birth control. Fundoscopic examination revealed papilledema, and a lumbar puncture demonstrated an opening pressure of 500 mm H_2O. Sagittal and coronal MR images showed a partial empty sella; no mass or other significant findings were noted (Fig 1A and B). Ventricular size was normal. The patient was started on acetazolamide 500 mg twice a day, which resulted in some improvement of visual fields; however, central vision remained diminished because of macular edema.

The patient returned 2 weeks later with no change in visual acuity; however, repeat MR imaging revealed a normal-appearing pituitary gland and sella without other interval change (Fig 1C and D). Two weeks later, visual acuity was stable without improvement. The decision was made to continue medical therapy and then reassess the need for more aggressive treatment, such as optic nerve fenestration (1). Two weeks later, physical examination revealed improvement in visual acuity, and macular edema had nearly resolved. After 6 more weeks of medical therapy, a fundoscopic examination showed resolution of macular edema and normal visual acuity. Acetazolamide was discontinued 9 months after initial presentation and the patient has remained asymptomatic without headache or visual disturbance.

Case 2

A 31-year-old obese woman had been followed up since 1977 for idiopathic intracranial hypertension diagnosed by an elevated opening lumbar pressure of 540 mm H_20, papilledema, and symptoms of severe intermittent frontooccipital headache. Cerebrospinal fluid (CSF) analysis was normal. Initial computed tomography (CT) performed on admission showed small ventricles but no masses or other abnormalities. She was treated with dexamethasone and furosemide for her initial episode and for two other exacerbations, one in 1980 and the second in 1984. Because of worsening visual field defects in 1984, head CT studies including coronal scans through the sella turcica were obtained, which were interpreted as showing a large symmetrically expanded pituitary fossa containing CSF density. Some enhancing pituitary tissue was seen on the floor of the fossa anteriorly. This was thought most likely to represent an empty sella, but because the pituitary stalk was not well seen, a cystic mass within the fossa could not be excluded and CT cisternography was recommended. This revealed herniation of CSF into the sella turcica with flattening of the pituitary gland along the sellar floor (Fig 2A). The infundibulum was midline in location. Visual acuity did not improve with medical therapy. Fundoscopic examination revealed lack of spontaneous venous pulsations.

After placement of a lumboperitoneal shunt, the patient's symptoms improved and her visual fields returned

Received September 8, 1995; accepted after revision February 26, 1996.

From the Departments of Diagnostic Radiology (M.T.Z., S.E.K.) and Ophthalmology (M.I.R.), University of Maryland Medical System, Baltimore, and the Department of Diagnostic Radiology, University of Virginia Health Sciences Center, Charlottesville (W.S.C.).

Address reprint requests to Michael Zagardo, MD, Department of Radiology, University of Maryland Medical System, 22 S Greene St, Baltimore, MD 21201.

AJNR 17:1953–1956, Nov 1996 0195-6108/96/1710–1953 © American Society of Neuroradiology

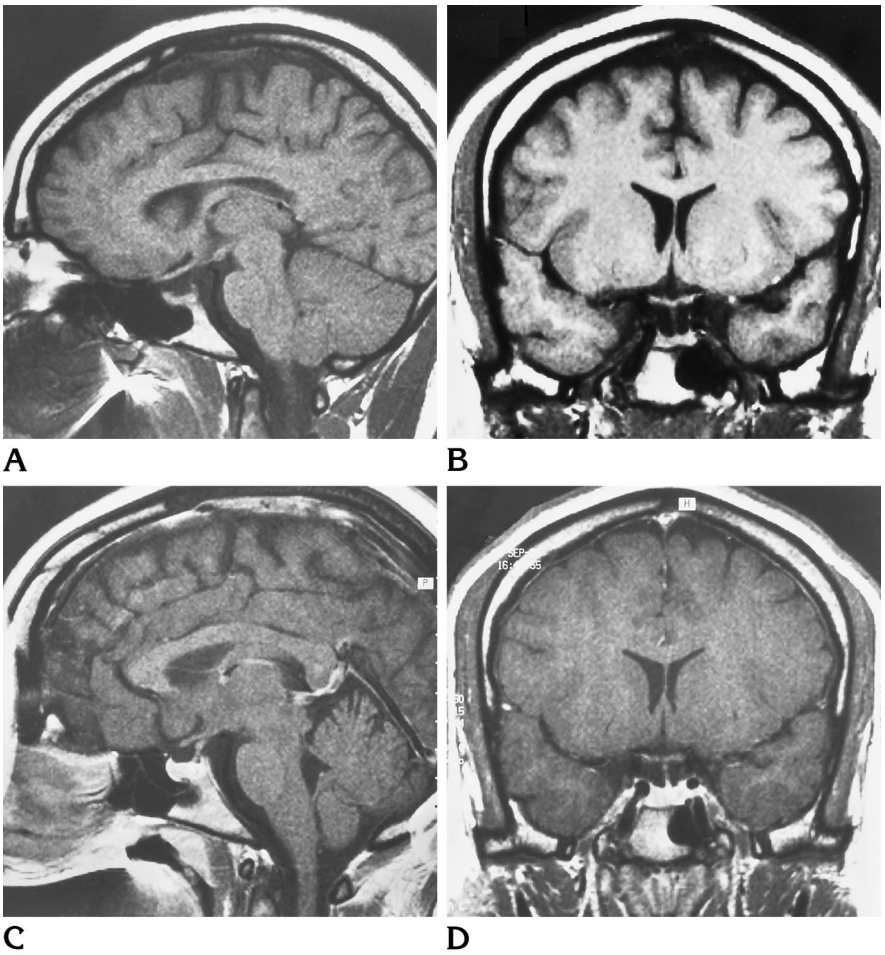

Fig 1. Case 1: 18-year-old woman with papilledema and headaches.

A, Oblique sagittal T1-weighted (400/15/3 [repetition time/echo time/excitations]) MR image through the sella turcica shows flattening of pituitary gland with extension of suprasellar CSF into the sella turcica.

B, Coronal T1-weighted (500/15/3) MR image through the sella at the level of the optic chiasm and infundibulum confirms the partially empty sella.

C, Sagittal contrast-enhanced T1-weighted (450/15/4) MR image through sella obtained 11 days later shows normal morphology of gland.

D, Coronal contrast-enhanced T1-weighted (450/15/4) MR image through the sella at the level of the optic chiasm confirms normal appearance. Superior margin of gland now is at the superior margin of the proximal parasellar carotid artery.

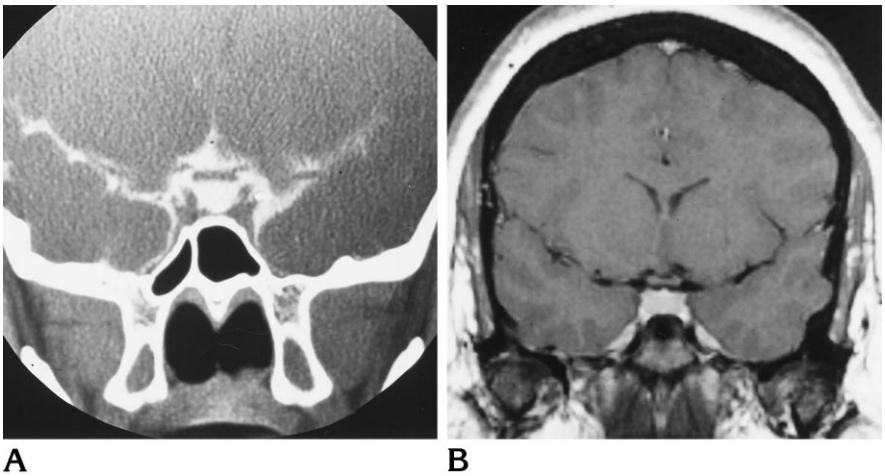

Fig 2. Case 2: 31-year-old woman with idiopathic intracranial hypertension.

A, Coronal CT scan (1-mm thick) through the sella turcica at the level of optic chiasm after intrathecal administration of contrast material shows extension of suprasellar cistern into the sella turcica with flattening of the pituitary gland.

B, Coronal MR image (520/20/3) after intravenous administration of contrast material shows normal-appearing pituitary gland.

to near normal. She had two other episodes of clinical deterioration in 1986 and 1987, manifested by headache and blurred vision, which were treated with shunt revision with good clinical response. In 1990, recurrent headaches developed. Plain radiographs showed no change in shunt components. An indium-111 shuntogram showed normal intrathecal movement of the radioisotope but no activity within the shunt tube or peritoneal cavity. Neuroophthalmologic examination revealed stability, and the patient was treated with acetazolamide, which was discontinued 1 month later without relapse.

In 1991, routine follow-up neuroophthalmologic examination showed normal visual fields. The patient had no subjective visual symptoms, but she continued to have several episodes of bifrontal headache lasting 4 to 5 minutes and occurring two to three times a day. Exacerbation of idiopathic intracranial hypertension was thought to be unlikely, but MR imaging was performed to exclude other causes of the symptoms. A coronal enhanced T1-weighted MR sequence showed normal configuration and size of the pituitary gland (Fig 2B), and the partial empty sella identified on a prior contrast-enhanced cisternogram had resolved. The patient's visual fields were stable at the most recent fundoscopic examination, performed in 1995, and while her lumboperitoneal shunt is nonfunctional, she has required no further therapy to date.

Discussion

Idiopathic intracranial hypertension, also known as *pseudotumor cerebri* and *benign intracranial hypertension*, is a syndrome characterized by increased intracranial pressure and papilledema in patients without focal neurologic findings, except for an occasional sixth nerve palsy. It is a diagnosis of exclusion, and radiologic examinations are used to help exclude lesions that produce intracranial hypertension, such as obstructive hydrocephalus, tumor, chronic meningitis, and dural sinus thrombosis. Opening lumbar CSF pressure is elevated but CSF composition is normal (2). Generalized brain swelling is present, and interstitial and/or intracellular edema of brain parenchyma has been noted on biopsy specimens from patients with idiopathic intracranial hypertension (2). The pathophysiology of this syndrome is still uncertain; however, an increase in resistance to CSF absorption at the level of the arachnoid villi, resulting in interstitial brain edema, is suspected (3). When a cause can be determined, this syndrome has been associated with menstrual irregularities, obesity, endocrinopathies, steroid withdrawal, hypoparathyroidism, hyperparathyroidism, hypothyroidism, hypervitaminosis A, tetracycline therapy, use of birth control medication, Guillain-Barré syndrome, and lithium therapy (4). While reported in all age groups, it is most frequent in obese female subjects between the ages of 10 and 40 years.

In the past, it was thought that no matter how patients with idiopathic intracranial hypertension were treated, the condition improved spontaneously without causing serious intracerebral damage; however, a number of studies have shown that this disorder is frequently a persistent condition (5), and the associated papilledema can seriously damage the vision of adults and children (6). Permanent visual loss due to chronic papilledema is, in fact, the chief hazard for patients with idiopathic intracranial hypertension. After the diagnosis has been clearly established by means of lumbar puncture and imaging techniques, therapy is directed toward lowering the intracranial pressure, controlling headaches, and encouraging weight loss. Careful vision monitoring is the mainstay for determining whether more invasive procedures such as optic nerve fenestration or, less frequently, lumboperitoneal shunting are necessary to preserve vision (7).

A number of CT and MR imaging findings have been reported in association with idiopathic intracranial hypertension, including an enlarged optic nerve sheath, reversal of the optic nerve head, small ventricles, enlarged or small extraventricular CSF spaces, increased T2 signal within the white matter on MR images, and empty sella (8–12). The term *empty sella* refers to a condition in which the sella turcica is filled mainly with CSF. The mechanism by which an empty sella develops in patients with idiopathic intracranial hypertension is intrasellar herniation of CSF and arachnoid membrane through an absent or open diaphragma sellae in association with increased intracranial pressure (10). The pituitary gland is flattened and distorted. The infundibulum is midline and extends down to the floor of the sella turcica. A strong statistical correlation between an empty sella and idiopathic intracranial hypertension has been well established (13). The frequency of some degree of empty sella in patients with idiopathic intracranial hypertension has been

reported to be as high as 94% (16 of 17 patients) (11).

Our two cases illustrate that the empty sella seen in patients with idiopathic intracranial hypertension can be a temporary radiologic finding that resolves with successful therapy. The mechanism for the development of reversible empty sella in these two patients is uncertain. A correlation between the amount of increased intracranial pressure and the prevalence of an empty sella together with evidence of pituitary compression on some CT and MR studies has been described; it is postulated that an empty sella and enlarged optic nerve sheaths most likely represent the consequence of chronically increased intracranial pressure (10). On the basis of this hypothesis, reversibility of the empty sella may be dependent on the chronicity of the syndrome and, we propose, on the initial mechanical integrity of the sellar diaphragm. It is possible that the patients described here belong to the 20% of the population who have absent or rudimentary diaphragma sellae (14). This could cause intrasellar herniation of CSF and arachnoid membrane to result from transiently increased intracranial pressure. In patients with more acute clinical presentations, a rapid diagnosis and expedient effective therapy may prevent an acutely deformed pituitary gland from becoming permanently deformed, depending on the inherent resiliency and elasticity of the tissues. In patients with chronically increased intracranial pressure, resultant permanent deformity of the pituitary gland may explain the persistence of an empty sella even after effective therapy has produced normal or decreased intracranial pressure. Our case 2 demonstrates that the empty sella can resolve even after multiple intermittent exacerbations of idiopathic intracranial hypertension.

The clinical significance of normalization in the appearance of sellar contents in these two patients is uncertain. One patient was successfully treated with medical therapy. The second patient required lumboperitoneal shunting and, upon the discovery of a malfunctioning shunt, was treated with a 1-month course of medical therapy. In patients treated for idiopathic intracranial hypertension who receive a follow-up MR study, the observation of a reversible empty sella may indicate a positive response to therapy and possibly denote a corresponding decrease in intracranial pressure. The return to a normal appearance of the sellar contents in these two patients supports the theory that the interaction of intracranial hypertension with a congenitally deficient sellar diaphragm is the cause of the empty sella in some patients with idiopathic intracranial hypertension.

In summary, an empty sella is a relatively common radiologic finding in patients with idiopathic intracranial hypertension. This report describes the MR findings of two patients with idiopathic intracranial hypertension in whom the appearance of the pituitary gland normalized after different treatments.

Acknowledgments

We thank Linda Clarke for the preparation of the manuscript and David Crandall for the photographic reproductions.

References

1. Sergott RC, Savino PJ, Bosky TM. Modified optic nerve sheath decompression provides long term visual improvement for pseudotumor cerebri. *Arch Ophthalmol* 1988;106:1384–1390
2. Ahlskog JE, O'Neill BP. Pseudotumor cerebri. *Ann Int Med* 1982; 97:249–256
3. Sorenson PS, Krogsaa-BordGjerros F. Clinical course and prognosis of pseudotumor cerebri: a prospective study of 24 patients. *Acta Neurol Scand* 1988;77:164–172
4. Griffin JP. A review of the literature on benign intracranial hypertension association with medication. *Adverse Drug React Toxicol Rev* 1992;11:41–58
5. Corbett JJ, Savino PJ, Thompson HS, et al. Visual loss in pseudotumor cerebri: followup of 57 patients from 5 to 41 years and a profile of 14 patients with permanent severe visual loss. *Arch Neurol* 1982;39:461–474
6. Orcult JC, Page NGR, Sanders MD. Factors affecting visual loss in benign intracranial hypertension. *Ophthalmology* 1984;91:1303–1312
7. Corbett J, Thompson S. The rational management of idiopathic intracranial hypertension. *Arch Neurol* 1989;146:1049–1051
8. Weisberg LA. Computed tomography in benign intracranial hypertension. *Neurology* 1985;35:1075–1078
9. Moser FG, Hilne S, Abrams G, Bello J, Schipper H, Silver AJ. MR imaging of pseudotumor cerebri. *AJNR Am J Neuroradiol* 1988; 9:903–909
10. Wessel K, Thron A, Linden D, Peterson D, Dichgans J. Pseudotumor cerebri: clinical and neuroradiological findings. *Eur Arch Psychiatry Clin Neurosci* 1987;237:54–60
11. Gibby WA, Cohen M, Goldberg H, Sergott R. Pseudotumor cerebri: CT findings and correlation with vision loss. *AJR Am J Roentgenol* 1993;160:143–146
12. Silbergleit R, Junck L, Feborski SS, Hatfield MK. Idiopathic intracranial hypertension (pseudotumor cerebri): MR imaging. *Radiology* 1989;170:207–209
13. Foley KM, Posner JB. Does pseudotumor cerebri cause the empty sella syndrome and benign intracranial hypertension? *Neurology* 1975;25:565–569
14. Busch W. Die Morphologie der Sella turcia and ihre Beziehunger Zur Hypophyse. *Virchows Arch Path Anat Physiol* 1951;32D: 437–458