

Are your **MRI contrast agents** cost-effective?

Learn more about generic **Gadolinium-Based Contrast Agents**.



FRESENIUS
KABI

caring for life

AJNR

Preoperative endovascular embolization of craniospinal hemangioblastomas.

J M Eskridge, W McAuliffe, B Harris, D K Kim, J Scott and H R
Winn

AJNR Am J Neuroradiol 1996, 17 (3) 525-531

<http://www.ajnr.org/content/17/3/525>

This information is current as
of April 18, 2024.

Preoperative Endovascular Embolization of Craniospinal Hemangioblastomas

Joseph M. Eskridge, William McAuliffe, Basil Harris, D. K. Kim, John Scott, and H. R. Winn

PURPOSE: To determine whether hemangioblastomas, highly vascular tumors requiring surgery that is potentially complicated by excessive bleeding, can be embolized safely by using interventional techniques that furnish a more avascular surgical field. **METHODS:** Nine hemangioblastomas involving either the cerebellum or the spinal cord were embolized preoperatively. In each case the feeding artery was selectively catheterized with a microcatheter and the hypervascular tumor nidus was devascularized with polyvinyl alcohol particles. **RESULTS:** Two patients who had undergone recent attempts at surgical resection at another institution had repeat surgery after endovascular embolization rendered the tumor nidus avascular. At surgery, the tumor was completely removed in one case and markedly debulked in the other. In all nine cases, blood loss after embolization was reported to be less than expected by experienced surgeons. In addition, manipulation and removal of the tumor was reported to be subjectively easier in these embolized tumors. The embolization procedure caused no permanent complications; however, one patient with a posterior fossa hemangioblastoma and hydrocephalus worsened clinically within 12 hours of embolization. This event was thought to be caused by obstructive hydrocephalus resulting from tumor swelling. Emergency craniotomy, ventricular decompression, and surgical resection of the tumor produced complete resolution of the signs and symptoms. **CONCLUSIONS:** Our results indicate that preoperative embolization of hemangioblastomas is a safe procedure that is useful in aiding surgical resection of these highly vascular tumors.

Index terms: Hemangioblastoma; Interventional materials, particles and microspheres; Surgery, resective

AJNR Am J Neuroradiol 17:525-531, March 1996

Hemangioblastomas are benign hypervascular tumors found primarily in the cerebellum and spinal cord. They constitute 1.1% to 2% of all craniospinal neoplasms (1). The hypervascular nidus may be associated with a tumor cyst, and these lesions can be difficult to resect owing to the hypervascularity of the nidus and to the location of the tumor in the posterior fossa (2-4). High rates of morbidity and mortality are associated with uncontrollable intraoperative hemorrhage (5). Spinal lesions are also associated with an in-

creased rate of morbidity, which is related to the vascular nature of the tumor (6). With the recent availability of microcatheters (Target Therapeutics Corp, San Jose, Calif), superselective catheterization of the small arteries of the posterior fossa and spinal cord that supply these tumors is now possible (7, 8). Before the advent of these catheters, selective catheterization of the posterior fossa had to be done entirely with flow-directed catheters, which require high-flow arteries such as those supplying arteriovenous malformations (AVMs) (9). This study was undertaken to determine whether hemangioblastomas could be safely and effectively devascularized preoperatively using modern endovascular techniques.

Materials and Methods

Nine patients (five men and four women, 16 to 60 years old) who had clinical and cross-sectional imaging evidence of craniospinal hemangioblastomas underwent pre-

Received December 19, 1994; accepted after revision September 29, 1995.

From the Departments of Radiology (J.M.E., W.McA., J.S.) and Neurological Surgery (J.M.E., B.H., D.K.K., H.R.W.), University of Washington, Seattle.

Address reprint requests to William McAuliffe, FRACR, Department of Radiology, SB-05, University of Washington, Seattle, WA 98195.

AJNR 17:525-531, Mar 1996 0195-6108/96/1703-0525

© American Society of Neuroradiology

Patients with hemangioblastoma who had preoperative embolization with polyvinyl alcohol (PVA) particles

Patient	Age, y/Sex	Tumor Location	Associated Cyst	Vessels Embolized	Volume of PVA, mL	Percentage of Tumor Embolized
1	32/M	C-4	No	Ascending cervical/ PSA	0.2	100
2	39/F	C-2	No	PSA	2	100
3	50/M	Cerebellar	Yes	SCA	1.2	100
4	60/F	Cerebellar	No	Occipital, APA, AMA, MMA, AICA	4.6	80
5	42/M	T-10 to T-12	No	T-10 intercostal bilaterally	3	50
6	36/F	Cerebellar	Yes	PICA	0.3	100
7	30/M	Cerebellar	Yes	SCA	1.8	100
8	16/F	Cerebellar	Yes	PICA	1.7	100
9	36/M	T-6	No	T-8 intercostal	2	100

Note.—PSA indicates posterior spinal artery; SCA, superior cerebellar artery; APA, ascending pharyngeal artery; AMA, accessory meningeal artery; MMA, middle meningeal artery; AICA, anterior inferior cerebellar artery; and PICA, posterior inferior cerebellar artery.

operative embolization between February 1988 and July 1994 (Table). In each case, the lesion was detected by computed tomography (CT) or magnetic resonance (MR) imaging, and a complete diagnostic angiographic work-up was obtained. All patients had signs and symptoms related to mass effect from the tumor.

Two patients (cases 5 and 9) with multiple craniospinal hemangioblastomas were known to have von Hippel-Lindau disease. Five of the patients had symptomatic cerebellar lesions, of which four consisted of a hypervascular tumor nidus associated with a cyst. None of these had been treated surgically. The other patient (case 4) had had surgery elsewhere 4 years before, and had a recurrence of a large solid tumor in the right cerebellar hemisphere. Four patients had had embolization of solid hypervascular spinal lesions, two in the cervical cord and two in the thoracic region. Two patients (cases 5 and 9) had had recent (less than 1 month earlier) attempts at tumor resection at other institutions; both of which were complicated by hemorrhage.

In every case, embolization was performed with the patient under neuroleptic anesthesia with monitoring of somatosensory evoked potentials (8). Monitoring of brain stem auditory evoked potentials was also done in three patients with tumors of the posterior fossa (10). A 5F to 7F guiding catheter was placed in the parent vessel and full heparinization was initiated (5000 to 6000 U of heparin), resulting in an activated coagulation time of greater than 300 seconds.

High-resolution digital fluoroscopy with road mapping capability and subtraction techniques (8) were used to enable safe catheterization of the feeding artery by a variable-stiffness 0.018-in microcatheter and microguidewire combination. Following catheter placement, the patient was awakened from anesthesia, examined neurologically, and injected with a standardized quantity of amobarbital sodium (Amytal Sodium) (30 mg was used for examinations of spinal arteries and 50 mg for examinations of posterior fossa vessels). Complete neurologic testing was repeated, as was evaluation of somatosensory evoked potentials after injection of amobarbital sodium. If no deficit was detected, embolization was

performed with a dilute solution of small (149 to 250 μm) polyvinyl alcohol (PVA) particles in nonionic contrast material (11). In each case, the 0.018-in microcatheter lumen, which has a dead space volume of 0.3 mL, was filled with this dilute mixture, which was slowly injected with a flush of normal saline. Care was taken to slowly infuse the particles with low-pressure hand injections, monitoring for reflux of PVA particles into the parent vessel. At the completion of the embolization procedure, repeat control angiography was performed in the parent vessel to verify that the vascular nidus had been obliterated.

Results

Six patients had never had surgery. In these cases, only small amounts of the PVA solution were required, typically 2 mL or less, to obliterate any tumor blush completely. Results of the embolization procedure were confirmed by a control arteriogram in the parent vessel (see Figs 1 and 2).

Among the three patients who had had previous surgery, one (case 9) underwent an unsuccessful attempt at surgical removal of a midthoracic lesion 2 weeks earlier at another hospital. Surgery had been discontinued because of hemorrhage. Subsequent embolization resulted in 100% obliteration of the tumor blush, and the mass was successfully removed with minimal blood loss 72 hours later. In another patient (case 5), surgery was terminated at another hospital because the residual tumor in the midthoracic region appeared highly vascular. Three days later, elective embolization diminished the vascular blush by 50%; the procedure was limited by the fact that the anterior spinal artery arose at the same level (left T-10). A

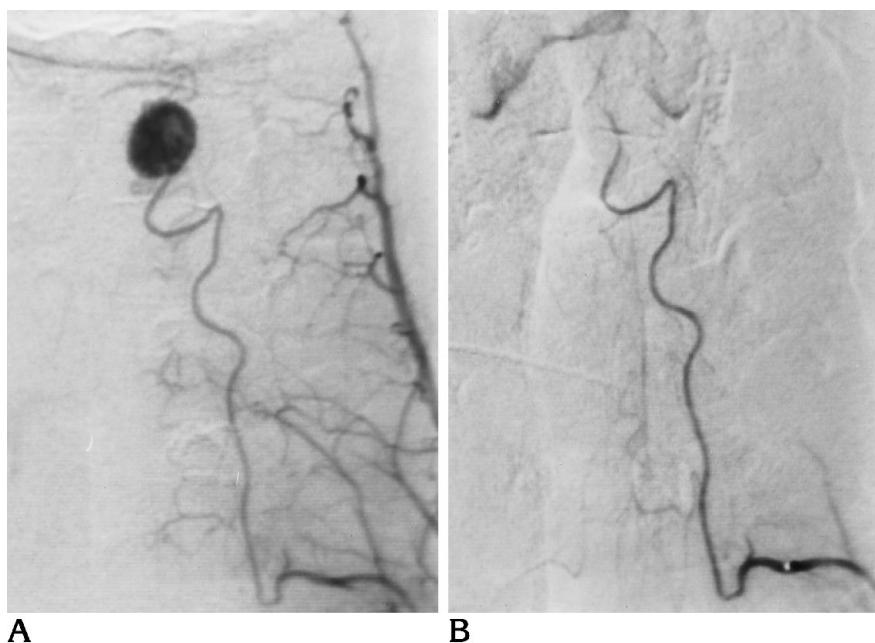


Fig 1. Case 1: 32-year-old man with progressive quadraparesis.

A, Anteroposterior view of a left ascending cervical angiogram shows left posterior spinal supply to midcervical hemangioblastoma.

B, Postembolization selective angiogram obtained with microcatheter shows complete devascularization of the tumor.

successful debulking procedure 72 hours later produced only a small amount of blood loss. Both these patients had large, solid lesions.

The third patient who had had previous surgery (case 4) had a recurrence of a large, solid 5-cm tumor in the right cerebellar hemisphere, which had initially been resected elsewhere 4 years earlier. Since then, the patient had experienced signs and symptoms of increasing ataxia in the right upper limb (Fig 3). Significant blood supply had been recruited from meningeal arteries, including the middle and accessory meningeal arteries and the transmastoid branch of the occipital artery and the neuro-meningeal trunk of the ascending pharyngeal artery. These vessels were embolized in addition to the anterior inferior cerebellar artery, with a total of 4.6 mL of PVA particles. More than 90% of the tumor was removed, and stable 3- to 4-mm residual nodules were seen on follow-up MR images in the base of the resection cavity at follow-up examination more than a year later.

In all nine cases, the tumor nidus was largely avascular at surgery and the surgeon reported that the bleeding was less than expected, with only a few tiny feeding arteries entering the periphery of the tumor and requiring cauterization. The surgeon also reported that devascularization of the nidus seemed to facilitate manipulation and extraction of the tumor.

There were no immediate complications dur-

ing embolization. However, one patient (case 6) (Fig 4), who had a large amount of posterior fossa mass effect and asymptomatic hydrocephalus before embolization, had signs and symptoms 6 hours after embolization that were associated with increased intracranial pressure, including headache, nausea, and vomiting. Because of the acute nature of these signs and symptoms, the patient was taken to the operating room, where the ventricular system was decompressed with a ventriculostomy catheter and the devascularized tumor completely removed. The patient made a full recovery, and results of a neurologic examination at 6 months' follow-up were normal.

Discussion

Hemangioblastomas are benign, usually highly vascular tumors that often have a cystic component when involving the cerebellar hemisphere, although midline lesions of the brain stem and spinal cord are usually solid (12). These tumors have a low mitotic rate, and, microscopically, the solid components are composed of thin-walled vessels and capillaries (12). Because of their location in the posterior fossa and spinal cord, hemangioblastomas can be difficult to remove (2-4), especially when they are midline and solid. Mortality can be associated with simple biopsy and/or decompression of hemangioblastomas of the cervicomedullary junction (3, 12-15). The

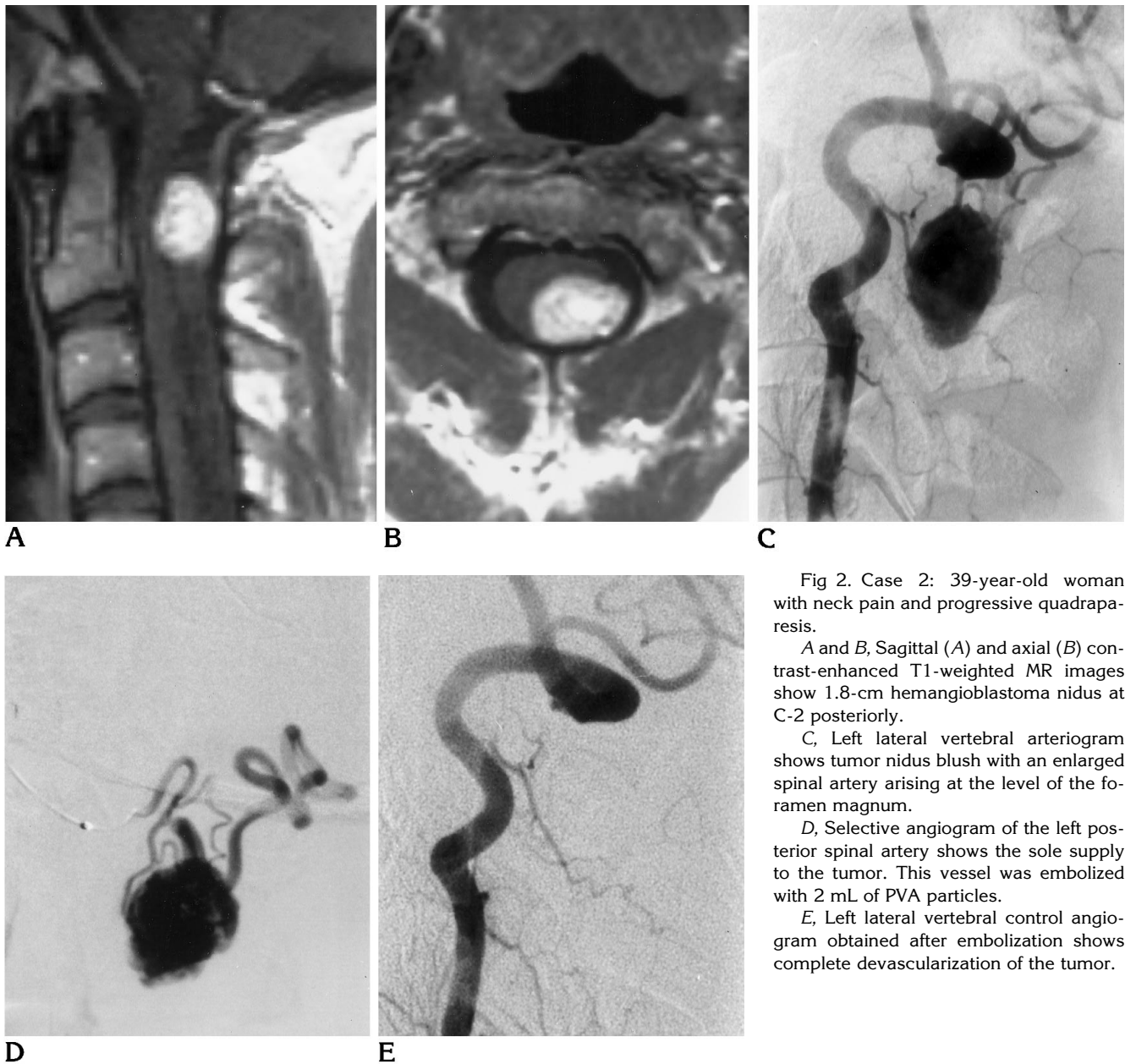


Fig 2. Case 2: 39-year-old woman with neck pain and progressive quadraparesis.

A and B, Sagittal (A) and axial (B) contrast-enhanced T1-weighted MR images show 1.8-cm hemangioblastoma nidus at C-2 posteriorly.

C, Left lateral vertebral arteriogram shows tumor nidus blush with an enlarged spinal artery arising at the level of the foramen magnum.

D, Selective angiogram of the left posterior spinal artery shows the sole supply to the tumor. This vessel was embolized with 2 mL of PVA particles.

E, Left lateral vertebral control angiogram obtained after embolization shows complete devascularization of the tumor.

vascularity of the tumor nidus (2) also contributes to the difficulty sometimes encountered during surgical resection. Modern neurointerventional techniques, including the use of microcatheters, microguidewires, and high-resolution angiography with subtraction facilities and road-mapping techniques (8), have enabled devascularization of other primary cerebrospinal lesions, such as AVMs before surgery (16). Neurologic examination and monitoring of somatosensory evoked potentials during the procedure have also increased the safety of embolization (8). The use of microcatheters and microguidewires in combinations of

various degrees of stiffness allows catheterization of normal-size intracranial vessels, not just those with high flow or that have been dilated, such as are desirable for flow-directed catheters (9). The variable-stiffness microcatheters also allow embolization with particulate agents, such as PVA particles, which was not possible with the calibrated leak balloons (8). PVA is our preferred embolic agent, as these particles quickly and adequately devascularize the nidus by penetrating deep into the microcirculation. Moreover, only a small amount (0.25 to 2.0 mL) is required for angiographic devascularization of most heman-

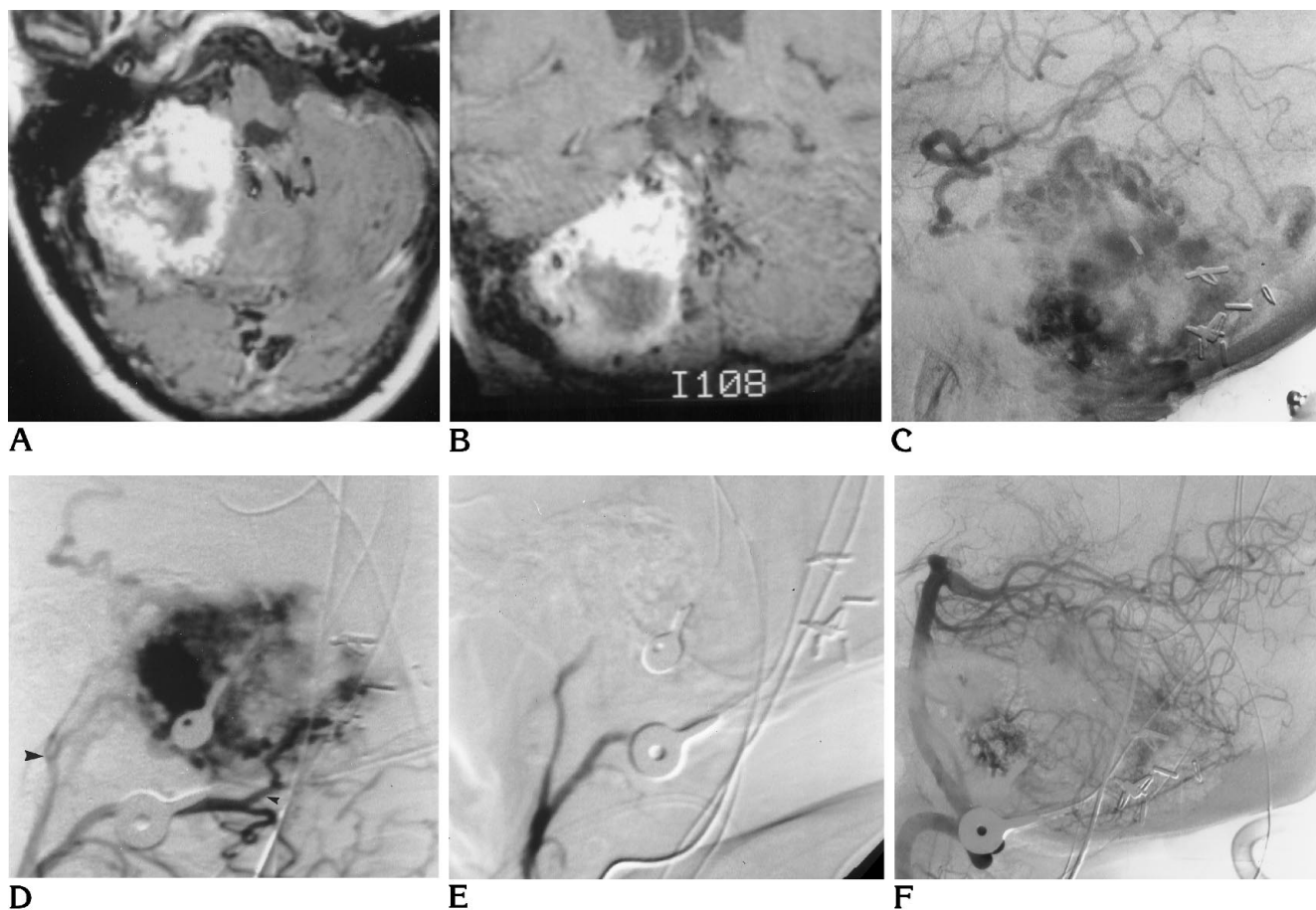


Fig 3. Case 4: 60-year-old woman with worsening right upper limb ataxia and a history of resection of a hemangioblastoma of the right cerebellar hemisphere 4 years earlier.

A and B, Axial (A) and coronal (B) contrast-enhanced T1-weighted MR images show an enhancing recurrent hemangioblastoma involving the right cerebellar hemisphere.

C, Right lateral vertebral angiogram, in late arterial phase, shows the hypervascularity of the tumor.

D, Right lateral occipital angiogram shows occipital artery supply to the tumor with an enlarged transmastoid branch (small arrowhead) and supply from the neuromeningeal division of the ascending pharyngeal artery (large arrowhead).

E, After embolization, a right lateral occipital artery injection shows obliteration of the tumor supply from the occipital artery and ascending pharyngeal arteries.

F, Right lateral vertebral angiogram obtained after embolization shows marked decrease in tumor vascularity. The right anterior inferior cerebellar artery was also embolized (not shown).

gioblastomas. Therefore, a slow infusion, using only the dead space afforded by the 0.018-in microcatheter (0.3 mL) with a saline bolus flush, seems sensible and safe. Small lesions are supplied by a single pial vessel, such as a branch of the posteroinferior cerebellar or superior cerebellar artery. The spinal lesions are usually supplied by an anterior or posterior spinal artery. Lesions that have previously have been treated surgically, however, can be supplied by multiple pial vessels and also by meningeal branches of the carotid and vertebral arteries. This scenario was demonstrated by our case 4 and emphasizes the need for complete angiographic assessment before embolization.

Further, large, solid hemangioblastomas have multicompartmental vascular supplies, with parts of the tumor being fed by different vessels (cases 4 and 5). Therefore, control angiography of potential feeding arteries at the completion of embolization is important to assess fully the degree of devascularization achieved.

We found 10 other cases of preoperative embolization of hemangioblastomas in the English-language literature (17-19) (R. T. Baumgartner, et al, "Hemangioblastoma Embolization," presented at the 60th Annual Meeting of the American Association of Neurological Surgeons, April 11-16, 1992, San Francisco, Calif). In reviewing

Fig 4. Case 6: 36-year-old woman with headache and ataxia.

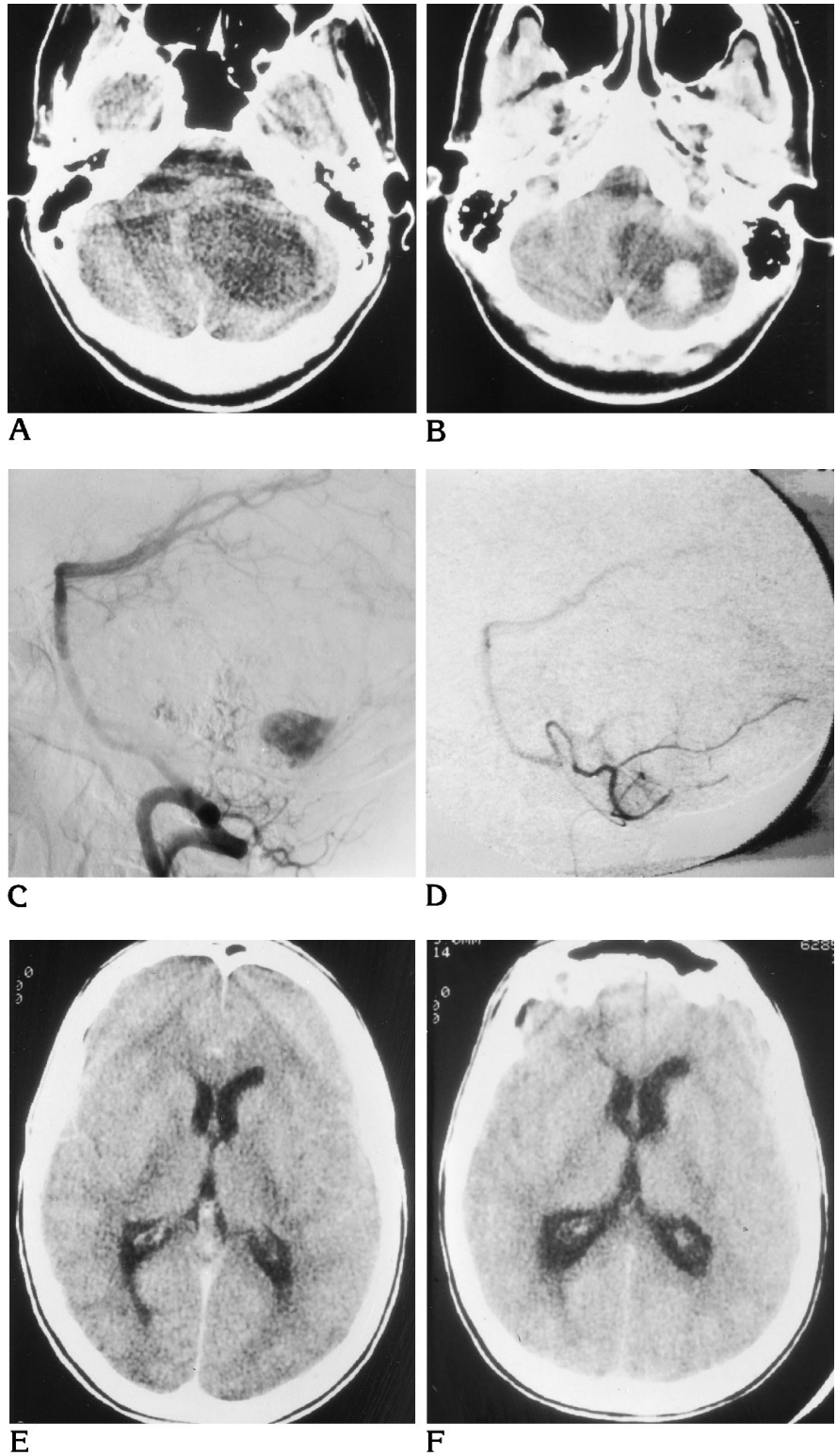
A and B, Axial CT scans without (A) and with (B) contrast material show a cerebellar hemangioblastoma with an enhancing nidus and a large surrounding cyst that is compressing the fourth ventricle and aqueduct.

C, Lateral vertebral angiogram shows the hypervascular nidus.

D, Lateral angiogram of the posterior inferior cerebellar artery obtained after embolization shows that the tumor has been devascularized and the rest of the arterial territory is patent.

E, Axial CT scan before embolization shows mild enlargement of the ventricles.

F, Axial CT scan obtained after the onset of nausea and vomiting shows hydrocephalus. The appearance of the tumor in the posterior fossa was unchanged from its appearance in A and B. The patient made a full recovery after tumor resection with a ventriculostomy catheter.



all the cases, Baumgartner et al reported intratumoral hemorrhage complicating PVA embolization in one case. We did not encounter such a complication; however, one patient had signs and symptoms of raised intracranial pressure after embolization (case 3), which necessitated emergency craniotomy with ventriculostomy and removal of the tumor. The signs and symptoms were probably caused by worsening of hydrocephalus due to ischemia, which produced swelling of the tumor and further compression of the fourth ventricle, although this is speculative. The signs and symptoms resolved after ventricular shunting and tumor resection.

All patients undergoing embolization need to be observed closely, and we prescribe intravenous steroids because of the danger of tumor swelling. Ideally, resection is done 48 to 72 hours after embolization, as the effect of PVA is temporary. We have not experienced any complications other than the one described here, and the surgical removal of these lesions was facilitated in all cases by embolization. In two patients, tumors that had previously defied surgical resection owing to excessive blood loss were successfully resected or markedly debulked (cases 5 and 9).

In conclusion, preoperative embolization of hemangioblastoma is a useful and safe procedure that can potentially decrease the morbidity and mortality of surgical resection of craniospinal hemangioblastoma. These tumors usually require small amounts of dilute PVA particles to obliterate tumoral blush completely. Large, solid tumors can be supplied from both pial and meningeal branches, which are recruited and need to be assessed in large tumors. Surgery is usually performed within 72 hours, and careful observation of the patients in the hospital is required in case complications from tumor swelling or hemorrhage ensue.

Acknowledgments

We gratefully acknowledge the preparation and editing of the manuscript by Renee Czarapata, and preparation of the illustrations by Janet Schukar and Paul Schwartz.

References

1. Russell DS, Rubenstein LJ. Tumors and hematomas of the blood vessel. In: *Pathology of Tumors of the Nervous System*, 4th ed. Baltimore, Md: Williams & Wilkins, 1977:116-127
2. Palmer DG. Hemangioblastomas, a review of 81 cases. *Acta Neurochir* 1972;27:125-148
3. Yasargil MG, Antic J, Laciga R, de Preux J, Fideler RW, Boone SC. The microsurgical removal of intramedullary spinal hemangioblastomas: report of twelve cases and a review of the literature. *Surg Neurol* 1976;6:141-148
4. Modkar VP, McKissock W, Russell RWR. Cerebellar hemangioblastomas. *Br J Surg* 1967;54:45-49
5. Djindjian M. Successful removal of a brainstem hemangioblastoma. *Surg Neurol* 1986;25:97-100
6. Neumann HPH, Eggert HR, Weigel K, Friedburg H, Wiestler OD, Schollmeyer P. Hemangioblastomas of the central nervous system: a 10-year study with special reference to von Hippel-Lindau syndrome. *J Neurosurg* 1989;70:24-30
7. Kikuchi T, Strother CM, Boyar M. New catheter for endovascular interventional procedures. *Radiology* 1987;165:870-871
8. Eskridge JM. Interventional radiology. *Radiology* 1989;172:991-1006
9. Kerber CW, Bank WP, Cromwell LO. Calibrated leak balloon micro-catheter: a device for arterial exploration and occlusive therapy. *AJR Am J Roentgenol* 1979;132:207-212
10. Grundy DL. Monitoring of sensory evoked potentials during neurosurgical operations: methods and applications. *Neurosurgery* 1982;11:556-575
11. Kerber CW, Bank WP, Horton JA. Polyvinyl alcohol foam: prepacking emboli for therapeutic embolization. *Radiology* 1978;130:1193-1194
12. Sanford RA, Smith RA. Hemangioblastoma of the cervicomedullary junction: report of three cases. *J Neurosurg* 1986;64:317-321
13. Chou SN, Erickson DL, Ortiz-Suarez JH. Surgical treatment of vascular lesions in the brain stem. *J Neurosurg* 1975;42:23-31
14. Krayenbühl H, Yasargil G. Das Kleinhirnhämangiom. *Schweiz Med Wochenschr* 1958;88:99-104
15. Okawara SH. Solid cerebellar hemangioblastoma. *J Neurosurg* 1973;39:514-518
16. Debrun G, Vinuela F, Fox AJ, Drake CG. Embolization of cerebral arteriovenous malformations with bucrylate: experience with 46 cases. *J Neurosurg* 1982;56:615-627
17. Tampieri D, Leblanc R, TerBrugge K. Preoperative embolization of brain and spinal hemangioblastomas. *Neurosurgery* 1993;33:502-505
18. Horton JA, Eelkema E, Albright AL. Preoperative embolization of a hemangioblastoma. *AJNR Am J Neuroradiol* 1989;10:203
19. Standard SC, Ahuja A, Livingston K, Guterman LR, Hopkins LN. Endovascular embolization and surgical excision for the treatment of cerebellar and brain stem hemangioblastomas. *Surg Neurol* 1994;41:405-410