

Are your MRI contrast agents cost-effective?

Learn more about generic Gadolinium-Based Contrast Agents.



**FRESENIUS
KABI**

caring for life

AJNR

Endovascular treatment of multiple aneurysms involving the posterior intracranial circulation.

T F Massoud, G Guglielmi, F Viñuela and G R Duckwiler

AJNR Am J Neuroradiol 1996, 17 (3) 549-554

<http://www.ajnr.org/content/17/3/549>

This information is current as
of April 17, 2024.

Endovascular Treatment of Multiple Aneurysms Involving the Posterior Intracranial Circulation

Tarik F. Massoud, Guido Guglielmi, Fernando Viñuela, and Gary R. Duckwiler

Summary: The results of surgery on multiple intracranial aneurysms that involve the vertebrobasilar circulation are poor, and associated patient mortality remains high. We describe the endovascular treatment of four patients with multiple aneurysms that involved the posterior intracranial circulation. Satisfactory occlusion of all aneurysms was achieved by using electrolytically detachable coils, and all patients had a good clinical recovery. Our early experience suggests that endovascular coil occlusion may be a particularly suitable method for treating this high-risk condition.

Index terms: Aneurysm, embolization; Aneurysm, intracranial; Interventional instruments, coils

Intracranial saccular aneurysms are the main cause of nontraumatic subarachnoid hemorrhage, and are responsible for about 22% to 25% of all deaths relating to cerebrovascular events (1). The presence of multiple intracranial aneurysms, especially when involving the posterior intracranial circulation, represents an even higher risk than does a single aneurysm, because there is a higher associated mortality in patients with multiple lesions (2, 3). In addition, the risk of rebleeding from the original aneurysm is higher and occurs earlier in this group of patients (4). Unfortunately, the literature suggests that there is no clear-cut strategy regarding the optimal management of multiple intracranial aneurysms (3).

In recent years, endovascular treatment of intracranial aneurysms has gained acceptance for poor surgical candidates or difficult/inoperable aneurysms. The occlusion of intracranial aneurysms by use of Guglielmi electrically detachable coils (Target Therapeutics, Fremont, Calif) and electrothrombosis has recently been introduced as a safe and controllable therapeutic method via the less invasive endovascular

route (5). The endovascular treatment of multiple intracranial aneurysms by using simple coils has been reported previously in one patient (6). We describe our experience in the occlusion of eight aneurysms in four patients using Guglielmi electrically detachable coils and highlight the benefits of this technique for treating this particular subset of patients. Case 2 has been reported previously (7).

A detailed description of the mechanical structure of the electrically detachable coils has already been published (8). Recently, improvements to this device have been made (9). Briefly, the main components include a 175-cm stainless steel core soldered to a very soft platinum coil varying in length from 4 to 30 cm (up to 40 cm previously). The latter has a circular memory that allows it to be deposited in the dome of the aneurysm without traumatizing the fragile wall. The diameter of the detachable coil can be 0.025 or 0.038 cm (0.010 or 0.015 in), and it is manufactured to be used in conjunction with a special version of Tracker 10 or 18 microcatheters (Tracker microcatheters with two markers manufactured by Target Therapeutics, Fremont, Calif). Most procedures are performed with the patient awake under neuroleptic analgesia and with systemic heparinization. Via the transfemoral route, a Tracker microcatheter is advanced coaxially through a 6F guiding catheter and into the aneurysmal sac. After check angiography, a 1.0- to 1.5-mA/2.0- to 3.1-V positive direct electrical current is applied to the proximal end of the stainless steel delivery wire. The negative ground pole is connected to a conductive pad positioned on the patient's skin. In 2 to 6 minutes the current dissolves the stainless steel immediately proximal to the platinum

Received October 26, 1994; accepted after revision June 30, 1995.

Presented at the 32nd Annual Meeting of the American Society of Neuroradiology, Nashville, May 1994.

From the Department of Radiological Sciences, Endovascular Therapy Service, University of California at Los Angeles Medical Center.

Address reprint requests to Tarik F. Massoud, MD, Endovascular Therapy Service, Department of Radiological Sciences, University of California at Los Angeles Medical Center, 10833 Le Conte Ave, Los Angeles, CA 90024.

AJNR 17:549-554, Mar 1996 0195-6108/96/1703-0549 © American Society of Neuroradiology

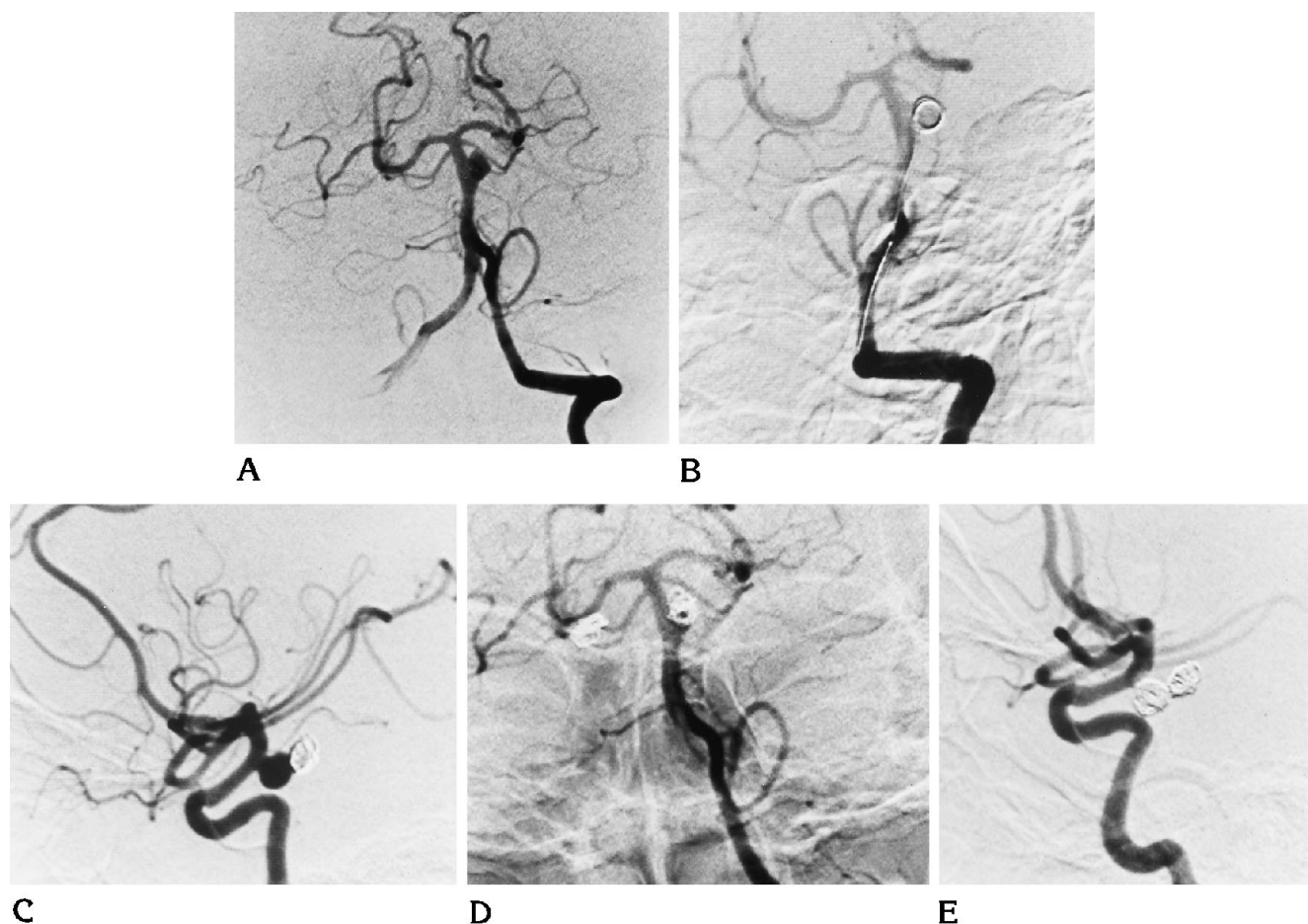


Fig 1. A-E, Left vertebral arteriograms show a midbasilar artery aneurysm (A) and delivery of the larger first coil (B), which acts as a nest for the subsequent coil. A right internal carotid arteriogram (C) shows an aneurysm of the posterior communicating artery and coils in an occluded aneurysm of the basilar artery. After successful embolization of both aneurysms, as seen on a left vertebral arteriogram (D) and a right internal carotid arteriogram (E), a small residual aneurysmal neck is seen in the basilar artery aneurysm on the frontal view.

coil by electrolysis, allowing the platinum coil to detach within the aneurysm. The delivery wire is then withdrawn. More coils can be introduced and detached according to the size of the aneurysm. At the end of the procedure, the microcatheter is removed and an angiogram is obtained to assess aneurysmal occlusion and parent vessel patency. A repeat angiogram is obtained in 3 to 5 days.

Case Reports

Case 1

A 41-year-old woman sustained a subarachnoid hemorrhage after a 2-year history of occipital headaches. Angiography revealed an aneurysm of the right posterior communicating artery and another aneurysm of a midbasilar artery fenestration. Both aneurysms were occluded by using Guglielmi electrically detachable coils (Figs 1A-

E), the posterior communicating artery aneurysm with 30 cm of platinum and the basilar artery aneurysm with 18 cm of platinum (leaving a tiny neck remnant). After embolization, the patient had a right-sided ischemic event, most likely resulting from an embolism from the right posterior communicating aneurysm, which occurred during treatment. However, the symptoms resolved totally within a few days, and the patient remains well.

Case 2

A 30-year-old woman was admitted for embolization of aneurysms of the posterior circulation. Over the previous 6 months she had suffered moderate occipital headaches and one episode of sudden transient diplopia. She had no nausea, vomiting, or syncope. Examination revealed the presence of cerebral aneurysms and a minor subarachnoid hemorrhage. She had a long-standing history of hypertension resulting from renal artery stenosis, which had required a right-sided nephrectomy 7 years earlier. Her

blood pressure was, however, well controlled by antihypertensive medication. No abnormality was found on physical examination. Three-vessel angiography was performed before embolization. Right vertebral artery injection showed a 7-mm basilar tip aneurysm and a 1-cm aneurysm of the P1 segment of the right posterior cerebral artery. There was no filling of the P2 segment of the right posterior cerebral artery. Collateral flow into the anterior and middle cerebral territories was noted on the left. A left common carotid artery injection showed diffuse narrowing throughout the internal carotid course, with external to internal carotid collaterals. A right internal carotid artery injection showed segmental narrowing of the cavernous internal carotid artery. The right middle and anterior cerebral distributions were normal. The angiographic diagnosis of moyamoya disease associated with cerebral aneurysms was made. By means of a Tracker microcatheter, the basilar tip aneurysm was occluded with one 20-cm and two 8-cm Guglielmi electrically detachable coils and the right P1 aneurysm was occluded with one 40-cm Guglielmi electrically detachable coils.

A postembolization angiogram showed a tiny residual neck in the basilar tip aneurysm and 95% obliteration of the P1 aneurysm. No parent vessel occlusion was identified. The patient remained well, and a repeat angiogram 4 days later showed no change in the basilar tip aneurysm and complete obliteration of the P1 aneurysm resulting from progression of intraaneurysmal thrombosis. The patient was asymptomatic upon discharge the next day. The 12-month follow-up angiogram showed complete occlusion of both aneurysms. She was symptom free at the 2-year clinical follow-up examination.

Case 3

A 49-year-old woman with a grade I subarachnoid hemorrhage was referred for embolization of intracranial aneurysms. Ten days earlier, she had suffered a subarachnoid hemorrhage for which she underwent a craniotomy. It was presumed at the time that an aneurysm of the right posterior communicating artery had bled. At surgery, however, this aneurysm was found to be unruptured but unclippable (wide-necked). Preembolization angiographic assessment showed an additional aneurysm of the left posterior inferior cerebellar artery. Endovascular embolization of the posterior communicating artery aneurysm was first undertaken, and complete occlusion achieved with a 10-cm Guglielmi electrically detachable coil. Next, the aneurysm of the left posterior cerebellar artery was embolized with two 8-cm coils. During delivery of the second coil, the aneurysm ruptured and the patient became comatose. She was intubated and ventilated, and continued delivery and detachment of the second coil resulted in occlusion of the aneurysm. A postembolization CT scan confirmed the presence of a large subarachnoid hemorrhage. The patient required a ventriculostomy, and ensuing severe vasospasm was treated within a few hours by intracranial angioplasty. She gradually recovered, and angiography at 18-months follow-up showed persistent

occlusion of both aneurysms. She was well at the 2-year clinical follow-up examination.

Case 4

A 42-year-old woman had a grade I subarachnoid hemorrhage. Angiography revealed two aneurysms of the vertebrobasilar junction, one pointing anteriorly and the other posteriorly. A suboccipital craniotomy was performed several days after hemorrhage, with partial clipping of the anterior aneurysm. Both aneurysms were subsequently occluded with Guglielmi electrically detachable coils, the larger posterior aneurysm with a total of 14 cm of platinum and the smaller anterior aneurysm with 4 cm of platinum. The larger aneurysm was completely occluded, and a tiny wedge remnant was seen along the superior aspect of the smaller aneurysm. The patient remains well.

Discussion

The average reported frequency of multiple intracranial aneurysms in clinical studies is 15% to 20% when these are defined as the combination of at least one ruptured and one or more silent aneurysms (3). Importantly, many of the studies reporting these figures were conducted without routine four-vessel angiography. Also, aneurysms of a few millimeters in diameter are easily missed on preoperative angiograms (10). Careful use of cerebral panangiography may reveal a frequency of multiple intracranial aneurysms of close to 45% (2). Naturally, there are cases of multiple aneurysms without any rupture, so the actual frequency of multiple intracranial aneurysms may be even higher than reported previously. Necropsy studies reporting a frequency of 50% (11) lend support to this suspicion. Therefore, the not infrequent presence of multiple intracranial aneurysms in patients with aneurysmal subarachnoid hemorrhage may add considerably to existing therapeutic problems for these patients.

A correlation between the natural history and the surgical risk in patients with multiple intracranial aneurysms has been established by Baena et al (12), who found that untreated unruptured aneurysms bled at a rate of 3% per year, with a cumulative mortality rate of 20%. Other accounts place the annual risk of rupture from an intact aneurysm in the presence of multiple intracranial aneurysms at 1% per year and the mortality rate at 4% over a 5-year period (10). In one series, 83% of patients with inoperable multiple intracranial aneurysms died within 1 year of the initial subarachnoid hemorrhage.

Therefore, the view that such aneurysms (including those unruptured) should be actively treated has recently become dominant (13).

Opinions regarding surgical strategy for multiple intracranial aneurysms have been divided. These have varied from nonintervention for unruptured aneurysms to operation only on those unruptured aneurysms that can be reached via the same craniotomy as for ruptured aneurysms. More recently, Mizoi et al advocated surgery for all multiple intracranial aneurysms in a one-stage operation whenever possible, or even by a second operation if this were necessary to clip the unruptured aneurysms (13). Adoption of such a strategy has resulted in one-stage surgical treatment in 78% of patients, two-stage treatment in 7% of patients, and partial treatment (unruptured aneurysm left untreated) in 15% of patients.

In one large series (13), patients with multiple intracranial aneurysms were classified into four groups according to the location of the aneurysms: the first three groups were composed of patients with various combinations of anterior circulation aneurysms; the fourth group included patients with vertebrobasilar artery aneurysms. Only 42% of patients in group 4 could be treated by one-stage operations, compared with 60% to 90% in the other groups. Furthermore, the surgical results in group 4 were poor, with a mortality rate of 27%, compared with 6% to 8% in the other groups. This poor outcome in patients with multiple intracranial aneurysms involving the posterior circulation was mainly the result of bleeding from untreated vertebrobasilar aneurysms, which were thought to be unruptured aneurysms preoperatively. Of note is the relatively high overall frequency (25%) of posterior circulation aneurysms in patients with multiple intracranial aneurysms as compared with the frequency of 8% in those patients with only a single aneurysm, further emphasizing the need for complete preoperative diagnostic angiography (2). However, despite careful panangiography and computed tomography or magnetic resonance imaging (14), and even in light of surgical findings, it is not always possible to determine which aneurysm has bled (13).

Although the surgical risk of direct operation for multiple intracranial aneurysms is only slightly worse than for single aneurysms (13), several factors adversely affect the outcome after surgery in these patients. As explained above, problems remain with regard to one-

stage operations in patients with aneurysms located in the posterior circulation. Misdiagnosis of the location of a ruptured aneurysm among multiple intracranial aneurysms also results in a poorer outcome (15). Aneurysms located in multiple sites, requiring multiple craniotomies/surgical approaches during the acute stage, result in a worse outcome than obtained with multistaged surgery. However, multistaged surgery can be performed with low morbidity and mortality only if the ruptured aneurysm (with the assumption that this was diagnosed correctly) has already been clipped. Nemoto et al (15) have reported that the size of unruptured aneurysms among multiple intracranial aneurysms is also a significant prognostic factor. Postoperative morbidity in patients with aneurysms less than 5 mm in diameter was 1%, whereas it was 20% with aneurysms measuring 10 mm or more. In addition, the increasing rate of occurrence of multiple intracranial aneurysms with advancing age presents a therapeutic dilemma in that although the risks of rebleeding in these patients is higher, so are the associated risks of surgery (2). Therefore, in one series comprising 105 patients with multiple intracranial aneurysms (15), surgery for unruptured aneurysms caused 2% morbidity in patients 28 to 55 years old and 18% morbidity in patients over 56 years old. A larger series of patients reported by Inagawa (16) also confirms a poorer surgical outcome in patients older than 60 years.

The optimum treatment of an intracranial aneurysm is its total occlusion with preservation of the parent artery, and with minimal morbidity and mortality related to the procedure. Since the early 1970s, endovascular treatment in selected cases of intracranial aneurysms has emerged as a therapeutic alternative to direct surgery. Many of the aneurysms considered for endovascular treatment have been surgically inaccessible or difficult to treat. As outlined above, the presence of multiple intracranial aneurysms conveys a higher risk to patients and can offer neurosurgeons particular therapeutic challenges and difficulties. Upon careful consideration of these difficulties, the less invasive endovascular approach may seem an attractive alternative to surgery for patients with multiple intracranial aneurysms.

The endovascular approach to aneurysmal occlusion has progressed considerably over the last decade. Previously, such treatment had been limited to balloon embolization. This tech-

nique, however, carries the significant risk of aneurysmal rupture during balloon inflation, the frequent occurrence of posttreatment aneurysmal remnants, and late balloon deflation. Treatment with Guglielmi electrically detachable coils has been recently developed as a less traumatic and more controllable endovascular method of aneurysmal occlusion. These devices have three main advantages: 1) they are very soft and less traumatic to the aneurysm wall; 2) they are detachable by application of electric current, which is also believed to induce thrombosis by attraction and accumulation of negatively charged blood elements; and 3) they are retrievable before detachment, which allows safe and accurate placement within the aneurysm. It is possible with this technique to achieve complete occlusion in aneurysms with small necks. Complete occlusion is more difficult to achieve in wide-necked aneurysms because of the risk of coil deposit in the parent artery. Careful angiographic follow-up of patients with wide-necked subtotally occluded aneurysms is mandatory to check for potential aneurysmal regrowth and rupture.

Single aneurysms in the posterior fossa generally pose difficult surgical problems, which may be accentuated by the presence of multiple intracranial aneurysms, with their higher propensity for posterior circulation distribution. Therefore, an alternative endovascular technique would be of particular benefit in this group of patients. The results of using Guglielmi electrically detachable coils in 43 aneurysms of the posterior fossa have been reported previously by Guglielmi et al (9), who showed an associated low morbidity and mortality rate, especially for patients in Hunt and Hess grade III or better. Complete occlusion was achieved in 13 of 16 small-necked aneurysms in this group. This initial experience suggests that Guglielmi electrically detachable coils are both safe and effective in the treatment of aneurysms of the posterior fossa.

A further benefit of the endovascular approach for treatment of multiple intracranial aneurysms is the elimination of the hazard of misdiagnosing and thus not treating the aneurysm responsible for hemorrhage. Instead, by using this technique, all aneurysms (ruptured and unruptured) may be endovascularly occluded at the same time. This technique also eliminates the problems associated with multiple craniotomies/surgical approaches that may be neces-

sary in some cases. Furthermore, multistaged treatment can be performed, even within relatively short intervals of follow-up after the initial treatment. Retreatment may be necessary for wide-necked aneurysms that exhibit coil compaction caused by persistent exposure to the circulation. Finally, the avoidance of general anesthetic, craniotomy, brain retraction, and surgical vessel manipulation may be particularly advantageous in elderly patients, who have a greater preponderance of multiple intracranial aneurysms and who are also at higher surgical risk because of their age (16). Notwithstanding these advantages, ischemic and hemorrhagic complications do occur with the use of Guglielmi electrically detachable coils for embolization of aneurysms. In 140 consecutive patients treated at our institution, 14 had ischemic complications (five resulting in permanent deficits; nine transient ischemic attacks) and five aneurysmal ruptures (two patients who were in Hunt and Hess grade IV and V died, and three patients in grades I to III are well). The complications encountered in two of the cases in this report were transient and the patients' outcomes were good.

Further accumulation of experience (clinical and angiographic) in use of the Guglielmi electrically detachable coils for treatment of both single and multiple intracranial aneurysms, along with critical comparative studies with surgery, will aid in verifying the long-term efficacy and true role of this recently developed technique. Our early experience with Guglielmi electrically detachable coils in the treatment of multiple intracranial aneurysms, particularly those involving the vertebrobasilar system, suggests that it may be a particularly suitable therapeutic method for this high-risk condition.

References

1. Yong-Zhong G, van Alphen HAM. Pathogenesis and histopathology of saccular aneurysms: review of the literature. *Neurol Res* 1990;12:249-255
2. Wilson FMA, Jaspan T, Holland IM. Multiple cerebral aneurysms: a reappraisal. *Neuroradiology* 1989;31:232-236
3. Vajda J. Multiple intracranial aneurysms: a high risk condition. *Acta Neurochir* 1992;118:59-75
4. McKissock W, Richardson A, Walsh L, et al. Multiple intracranial aneurysms. *Lancet* 1964;1:623-626
5. Guglielmi G, Viñuela F, Dion J, et al. Electrothrombosis of saccular aneurysms via endovascular approach, II: preliminary clinical experience. *J Neurosurg* 1991;75:8-14

6. Aymard A, Gobin YP, Casasco A, et al. Multiple intracranial aneurysms: endovascular treatment by coils. *Neurochirurgie* 1992; 38:353-357
7. Massoud TF, Guglielmi G, Viñuela F, Duckwiler GR. Saccular aneurysms in moyamoya disease: endovascular treatment using electrically detachable coils. *Surg Neurol* 1994;41:462-467
8. Guglielmi G, Viñuela F, Sepetka I, et al. Electrothrombosis of saccular aneurysms via endovascular approach, I: electrochemical basis, technique and experimental results. *J Neurosurg* 1991; 75:1-7
9. Guglielmi G, Viñuela F, Duckwiler G, et al. Endovascular treatment of posterior circulation aneurysms by electrothrombosis using electrically detachable coils. *J Neurosurg* 1992;77:515-524
10. Inagawa T. Surgical treatment of multiple intracranial aneurysms. *Acta Neurochir* 1991;108:22-29
11. Suzuki J, Sakurai Y. The treatment of intracranial multiple aneurysms. In: Suzuki J, ed. *Cerebral aneurysms*. Tokyo: Neuron Co, 1979:293-307
12. Baena RR, Rainoldi F, Silvani V, et al. Surgical treatment of multiple supratentorial aneurysms. *Neurochirurgia* 1986; 29:20-24
13. Mizoi K, Suzuki J, Yoshimoto T. Surgical treatment of multiple aneurysms. *Acta Neurochir* 1989;96:8-14
14. Nehls DG, Flom RA, Carter LP, et al. Multiple intracranial aneurysms: determining the site of rupture. *J Neurosurg* 1985;63:342-348
15. Nemoto M, Yasui N, Suzuki A, et al. Problems of surgical treatment for multiple intracranial aneurysms. *Neurol Med Chir* 1991; 31:892-898
16. Inagawa T. Multiple intracranial aneurysms in elderly patients. *Acta Neurochir* 1990;106:119-126