

Noninvasive Evaluation of Malignancy of Brain Tumors with Proton MR Spectroscopy

Hiroaki Shimizu, Toshihiro Kumabe, Teiji Tominaga, Takamasa Kayama, Kazushi Hara, Yasuki Ono, Koetsu Sato, Nobuyuki Arai, Satoru Fujiwara, and Takashi Yoshimoto

PURPOSE: To test clinical proton MR spectroscopy as a noninvasive method for predicting tumor malignancy. **METHODS:** Water-suppressed single-voxel point resolved spectroscopy in the frontal white matter of 17 healthy volunteers and 25 patients with brain tumors yielded spectra with peaks of *N*-acetyl aspartate (NAA), choline-containing compounds (Cho), creatine/phosphocreatine (Cre), and lactate. These peak intensities were semiquantitated as a ratio to that of the external reference. The validity of the semiquantitation was first evaluated through phantom and volunteer experiments. **RESULTS:** The variation in measurements of the designated region in the volunteers was less than 10%. Normal ranges of NAA/reference, Cho/reference, and Cre/reference were 3.59 ± 0.68 , 1.96 ± 0.66 , and 1.53 ± 0.64 (mean \pm SD), respectively. In 17 gliomas, the Cho/reference value in high-grade gliomas was significantly higher than in low-grade gliomas. Levels of NAA/reference were also significantly different in low-grade and high-grade malignancy. In eight meningiomas (four newly diagnosed and four recurrent), the level of Cho/reference was significantly higher in recurrent meningiomas than in normal white matter or in newly diagnosed meningiomas. **CONCLUSIONS:** Higher grades of brain tumors in this study were associated with higher Cho/reference and lower NAA/reference values. These results suggest that clinical proton MR spectroscopy may help predict tumor malignancy.

Index terms: Brain neoplasms, magnetic resonance; Magnetic resonance, spectroscopy

AJNR Am J Neuroradiol 17:737-747, April 1996

Despite expectations of noninvasive tumor characterization by clinical proton magnetic resonance (MR) spectroscopy, previous studies have yielded somewhat disappointing results (1). Initial studies indicated that proton MR spectroscopy might be able to aid in the diagnosis of various types or malignancy of brain tumors (2-4). The studies that followed were conducted on larger series of patients and

showed the ability of clinical proton MR spectroscopy to give information on the basic metabolic processes (such as anaerobic metabolism) in tumors (5-8). However, these studies concluded that there was no reliable indicator for discriminating among tumor types or malignancy.

The aim of this study was to test the usefulness of single-voxel proton MR spectroscopy as a noninvasive method to evaluate the malignancy of brain tumors. In contrast to previous studies, we used the semiquantitative approach for spectral analysis by using an external reference. Because this approach has not previously been applied to the study of brain tumors, the methodological limitations were first evaluated in phantoms as well as in volunteer subjects. To avoid intolerable examination times for the patients, we did not try to measure T1 and T2 relaxation times of each metabolite. Therefore, absolute molar concentrations were not calculated. Nonetheless, the present method showed

Received June 29, 1995; accepted after revision September 25.

Supported in part by a research grant from the Ministry of Health and Welfare, Japan.

From the Department of Neurosurgery, Tohoku University School of Medicine, Sendai, Japan (H.S., T.Ku., T.T., K.H., Y.O., T.Y.), the Department of Neurosurgery, Kohnan Hospital, Sendai, Japan (H.S., S.F.), the Department of Neurosurgery, Yamagata University School of Medicine, Yamagata, Japan (T.Ka.), the Department of Radiology, Kohnan Hospital, Sendai, Japan (K.S.), and GE Yokogawa Medical Systems, Tokyo, Japan (N.A.).

Address reprint requests to Hiroaki Shimizu, MD, Department of Neurosurgery, Tohoku University School of Medicine, Sendai 980-77, Japan.

AJNR 17:737-747, Apr 1996 0195-6108/96/1704-0737

© American Society of Neuroradiology

that clinical proton MR spectroscopy can provide information to help discriminate among tumor grades.

Subjects and Methods

For the external reference, we prepared 200 mmol/L of *N*-acetyl L-alanine (Sigma, St Louis, Mo) solution containing 5 mmol/L of NiCl₂ in a small glass tube (diameter, 4 cm; length, 11 cm). These concentrations of chemicals were determined through preliminary experiments so that effective signal-to-noise ratio (SNR > 200:1) and T1 shortening (T1 relaxation time of *N*-acetyl L-alanine = 740 milliseconds) were achieved.

The present study included 17 healthy volunteers (all men; age range, 24 to 38 years) and 25 patients with brain tumors. Consent was obtained in all human subjects.

A 1.5-T whole-body system and a standard head coil for MR imaging, which produces a highly homogeneous B1 field (9), were used to perform single-voxel point resolved spectroscopy (PRESS). Shimming and water suppression were achieved by using automated software developed by the manufacturer (Probe, GE Medical Systems, Fremont, Calif). Water-suppression pulses consisted of three chemical-shift selective pulses. An additional manual tuning of the third pulse was usually performed for additional optimization. These procedures resulted in a half-height width of the unsuppressed water signal of 1 to 4 Hz and more than a 99.9% water suppression rate.

The external reference was set to the head coil so that its position was not altered throughout the study. A spectrum was first obtained from the brain of the subject and then from the reference without moving the subject. Acquisition parameters were as follows: spectral width, 2500 Hz; 2048 data points; 2000/272 (repetition time/echo time); and 128 excitations for the reference and 256 for the brain. In most of the patients, an additional acquisition was obtained with an echo time of 136 milliseconds and 64 to 128 excitations. The volume of interest (VOI) was varied from 13.0 × 13.0 × 15.0 mm³ to 20.0 × 20.0 × 20.0 mm³ for the brain, the VOI was 16.5 × 16.5 × 20.0 mm³ for the reference.

A radio frequency coil loading is expected to change for every new examination because of the different head sizes of subjects. This might change the signal from the reference. However, we found that the coil impedance differed by 1% among three adult volunteers, and we speculated that the coil loading may not change significantly among adult subjects. In addition, even if the coil loading changed, it would affect the brain signals as well as the reference signal. Thus, we expected that changes in the coil loading would be canceled by taking a ratio of the brain signal to the reference signal. When different regions of interest within the same plane were examined, as was the case in the present study, the receiver gain remained constant because of automated tuning by the system.

Spectra were processed by using SA/GE software supplied by the manufacturer (GE Medical Systems, Fremont,

Calif). After zero filling, 2 Hz of exponential filtering, Fourier transformation, manual zero-order phasing, and baseline correction, a gaussian line fit was applied to measure the signal area under the peak. For the reference, a single peak caused by the acetyl residue of *N*-acetyl L-alanine was used. Four dominant peaks were analyzed in the brain: *N*-acetyl aspartate (NAA) at 2.0 ppm, creatine/phosphocreatine (Cre) at 3.0 ppm, choline-containing compounds (Cho) at 3.2 ppm, and lactate at 1.3 ppm (5). The lactate assignment was made by the formation of the characteristic doublet caused by the J coupling and/or inversion of the peak at the echo time of 136 milliseconds caused by the J modulation (6). These signal areas were divided by the size of the VOI for a volume correction. The final step of the present method of semiquantitation was to calculate a ratio of the signal area of each metabolite versus the reference signal area to give a semiquantitation value for each metabolite.

Phantom Experiments

Measurement reproducibility of the reference signal was tested by performing PRESS five times successively. This was repeated on five different occasions. To investigate possible chemical degradation of *N*-acetyl L-alanine over time, the reference was repeatedly measured up to 350 days after preparation. The signal intensity was compared with that of a newly prepared solution of the same contents at each point in time. To confirm good linearity between the volume examined and the signal intensity, the size of the VOI within the reference was varied by five steps from 1.0 to 8.7 mL. Finally, to prove the feasibility of using the external reference, the following experiment was performed: A large bottle (diameter, 20 cm; length, 45 cm) filled with 10 mmol/L of *N*-acetyl L-alanine and 0.25 mM of NiCl₂ (10-mmol/L solution) was placed in the head coil as a sample mimicking the brain. The external reference was set as in the human studies. At five different VOIs along the horizontal axis (Fig 1), absolute quantitation was performed by using the stimulated echo-acquisition mode (10). To measure the T1 and T2 relaxation times of the object (*N*-acetyl L-alanine of 10-mmol/L solution), spectra were collected with repetition times of 1500, 3000, and 5000 milliseconds at an echo time of 30 milliseconds and with echo times of 30, 50, 90, 136, and 272 milliseconds at a repetition time of 3000 milliseconds (mixing time was 13.5 milliseconds). Spectra from the external reference were acquired with the same protocol. The concentrations for each VOI were calculated by using the following equation and were then compared with the known concentration (10 mmol/L):

$$C(s) = [S(s) \times C(r) \times V(r) \times F(T1:r) \times E(T2:4)] / [S(r) \times V(s) \times F(T1:s) \times E(T2:s)],$$

where s and r denote the sample (each VOI in the 10-mmol/L solution) and the reference, respectively; S is the signal intensity at a repetition time of 3000 milliseconds and an echo time of 30 milliseconds; C is the concentra-

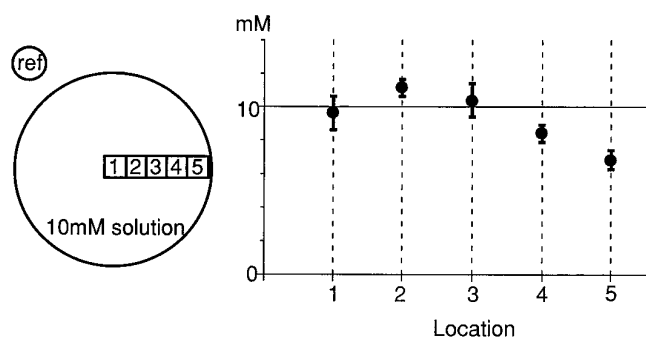


Fig 1. An absolute quantitation experiment using a solution of 10 mmol/L of *N*-acetyl L-alanine (10mM solution) and a 200-mmol/L *N*-acetyl L-alanine external reference (ref). The diagram on the left shows the placements of the sample and the reference in the head coil and the locations of five VOIs (1 through 5) in the 10-mmol/L solution. The size of each VOI is $17.5 \times 17.5 \times 20.0 \text{ mm}^3$. The graph on the right shows the results of the quantitation experiment for each VOI as a mean \pm SD ($n = 3$). At locations 1, 2, and 3, the calculated concentrations were within 10% of the difference from the actual concentration (10 mmol/L). At locations 4 and 5, the differences were larger.

tion; V is the volume at the location from which spectra were acquired; $F(T1)$ is the T1 saturation factor; and $E(T2)$ is the T2 factor.

The stimulated-echo acquisition mode sequence was used in this experiment because short echo times, such as 30 and 50 milliseconds, were not compatible with the PRESS sequence used for the rest of the study. Because several different VOIs were examined, this experiment also provided an estimation of spatial inhomogeneity in the coil sensitivity.

Experiments in Healthy Volunteers

The volunteers were placed in the head coil with the external reference fixed. The frontal white matter and the reference were alternatively measured three times at a single stage in each of four volunteers, and the NAA/reference variation was calculated. The repeatability was assessed by performing the same measurement every 5 to 7 days over a period of 1 month in seven volunteers. Furthermore, the normal ranges of the semiquantitation values of each metabolite were tentatively calculated as mean \pm 2 SD from the spectra of the frontal white matter in the 17 volunteers. Normal ranges were also calculated for the conventionally analyzed data by using metabolite ratios Cho/NAA, Cho/Cre, and NAA/Cre.

Clinical Application

A total of 25 tumors (17 gliomas and 8 meningiomas) were examined by using the present method before any treatment (except steroid therapy). All the patients underwent surgery to remove the tumors after the examination, and the complete histologic diagnosis of each tumor was provided by the pathologists. Tumors were included in the

study only when we could locate at least 2.5 mL of VOI within the tumor body while avoiding the inclusion of macroscopic cysts and necrosis in the VOI. Spectra were also analyzed by the conventional method of taking metabolite ratios. The malignancy of the gliomas was classified from grade 1 to 4 according to the World Health Organization grading (11). The meningiomas were divided into two categories: newly diagnosed ($n = 4$) and recurrent ($n = 4$).

Statistics

Because there were only two grade 4 gliomas, they were pooled with grade 3 gliomas as high-grade gliomas for statistical analysis. Differences among normal frontal white matter, low-grade (grade 2) and high-grade (grades 3 and 4) gliomas, and the two groups of meningiomas were assessed by the factor analysis of variance, followed by the Scheffe's F test for multiple comparisons. Differences of $P < .05$ were considered to be statistically significant.

Results

Phantom Experiments

The signal intensity from the reference varied by 2% ($100 \times \text{SD}/\text{mean}$) within five successive measurements. The signal of a single reference did not show any significant changes over the 350 days when expressed as a ratio to the newly prepared one at each point in time. The ratio fluctuated by 1.7% on average ($n = 37$). Figure 2 shows the relationship between the size of the

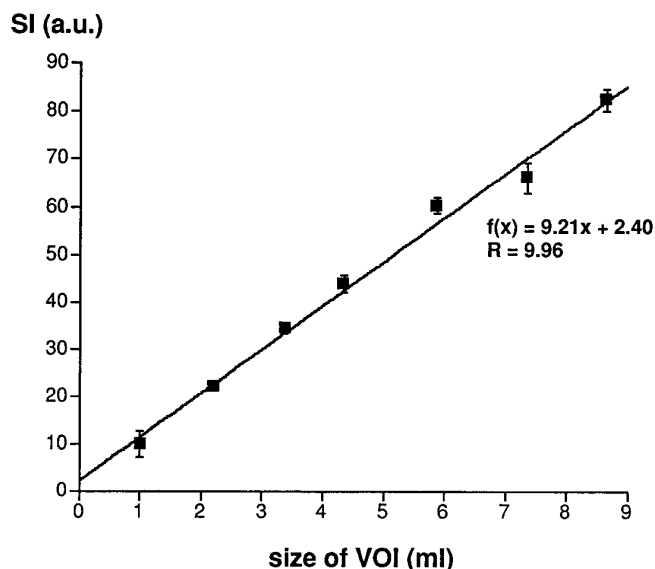


Fig 2. The relationship between the *N*-acetyl L-alanine signal intensity (SI, arbitrary units) and the voxel size in the water solution of 10 mmol/L of *N*-acetyl L-alanine (containing 0.25 mmol/L of NiCl_2). A tight linear relationship was observed.

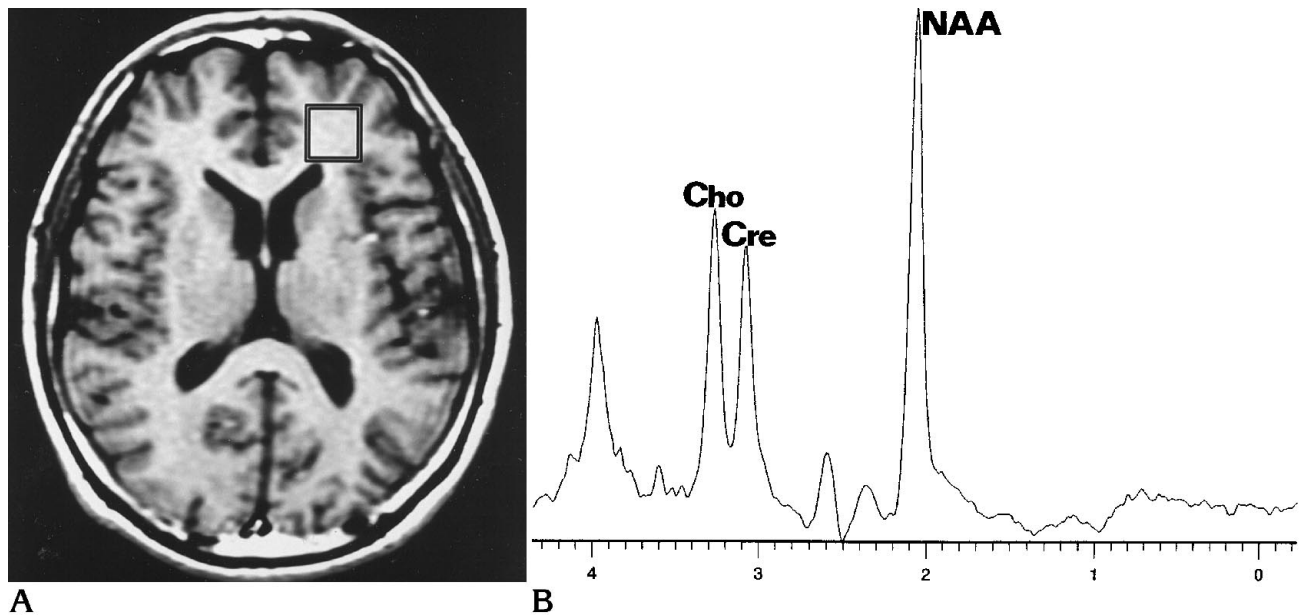


Fig 3. A, MR image shows the location of the VOI ($17.5 \times 17.5 \times 20.0 \text{ mm}^3$) at the frontal white matter of a healthy volunteer. B, The spectrum from the VOI shown in A, acquired with PRESS (2000/272/256 [repetition time/echo time/excitations]). Three dominant peaks are NAA at 2.0 ppm, Cre at 3.0 ppm, and Cho at 3.2 ppm.

TABLE 1: Data from normal frontal white matter

Measurement	Semiquantitation Values			Metabolite Ratios		
	Cho/Ref	Cre/Ref	NAA/Ref	Cho/NAA	Cho/Cre	Cre/NAA
Mean	1.96	1.53	3.59	0.54	1.35	0.42
SD	0.33	0.32	0.34	0.10	0.37	0.07
Normal range (mean \pm 2 SD)	1.30–2.62	0.88–2.18	2.91–4.27	0.34–0.74	0.60–2.10	0.27–0.56

Note.—Cho indicates choline-containing compounds; Ref, external reference; Cre, creatine/phosphocreatine; and NAA, *N*-acetyl aspartate. $n = 17$ for NAA/ref; $n = 14$ for Cho/ref, Cre/ref, Cho/NAA, Cho/Cre, and Cre/NAA.

VOI and the signal intensity. A tight linear relationship was observed ($r = .996$, $P < .0001$). Figure 1 illustrates the quantitation experiment using the 10-mmol/L *N*-acetyl *L*-alanine solution. In the three VOIs positioned near the center of the object (locations 1, 2, and 3), the calculated concentrations were found to be good estimations, with errors of less than 10%. In the two VOIs positioned more peripherally (locations 4 and 5), the concentrations were underestimated significantly (16% and 23%, respectively).

Experiments in Healthy Volunteers

Figure 3 shows the location of the external reference and the VOI in the frontal white matter and the acquired spectrum in a typical volunteer. The variations in the NAA/reference in three successive data sets were 2.8%, 4.5%,

4.7%, and 10.8% (mean, 5.7%) in the four volunteers. The variations in the NAA/reference obtained on different occasions were 5.5%, 5.9%, 8.4%, 8.3%, 10.8%, 16.0%, and 16.2% ($n = 2$ to 5; mean, 10.2%) in seven volunteers. The normal ranges of NAA/reference, Cho/reference, and Cre/reference were estimated as the means \pm 2 SD (Table 1).

Clinical Applications

The study included 14 male patients and 10 female patients (age range, 14 to 79 years). Seventeen gliomas included 1 grade 1 tumor (pilocytic astrocytoma), 5 grade 2 tumors (4 astrocytomas and 1 ganglioglioma), 9 grade 3 tumors (8 anaplastic astrocytomas and 1 anaplastic ependymoma), and 2 grade 4 tumors (1 glioblastoma and 1 gliosarcoma). Pathologic diagnoses of 4 newly diagnosed meningiomas

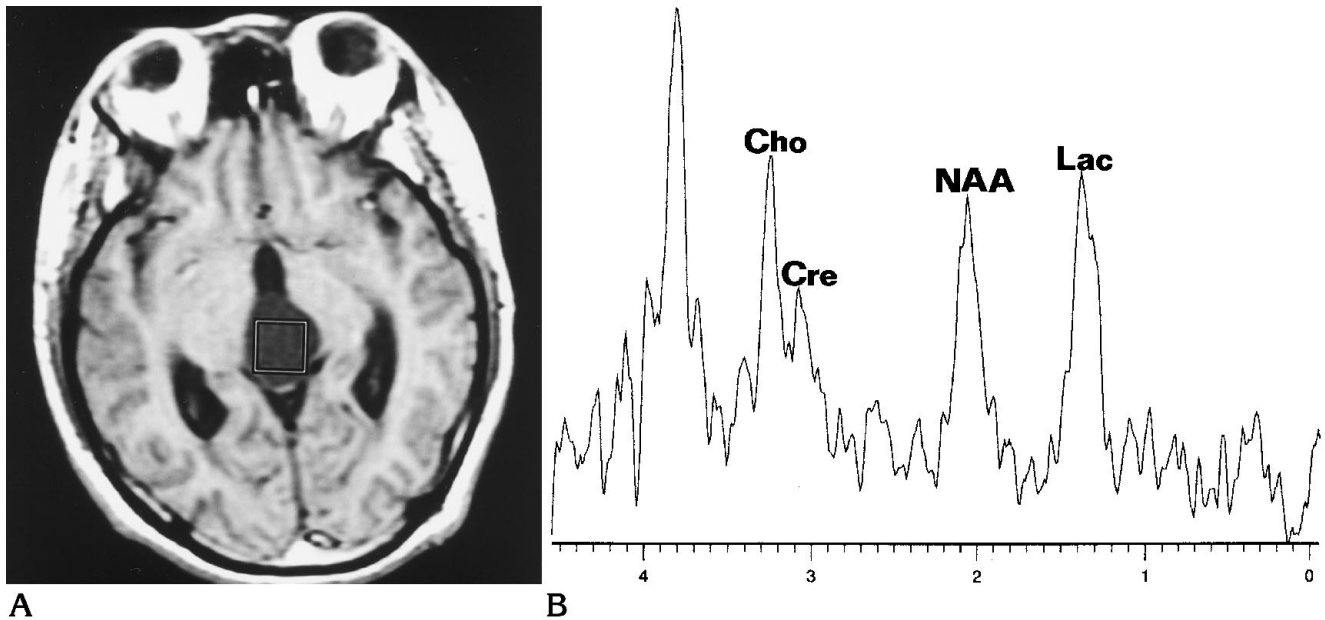


Fig 4. A, MR image of pilocytic astrocytoma (grade 1) at the third ventricle. The VOI was located within the tumor.
 B, The spectrum from the VOI, acquired with PRESS (2000/272/256). Cho/reference, 0.80; Cre/reference, 0.96; and NAA/reference, 1.72. The peak at 1.3 ppm is not a typical doublet for lactate; however, it has been assigned to lactate (*Lac*) because it was inverted at an echo time of 136 milliseconds (lactate/reference, 1.61).

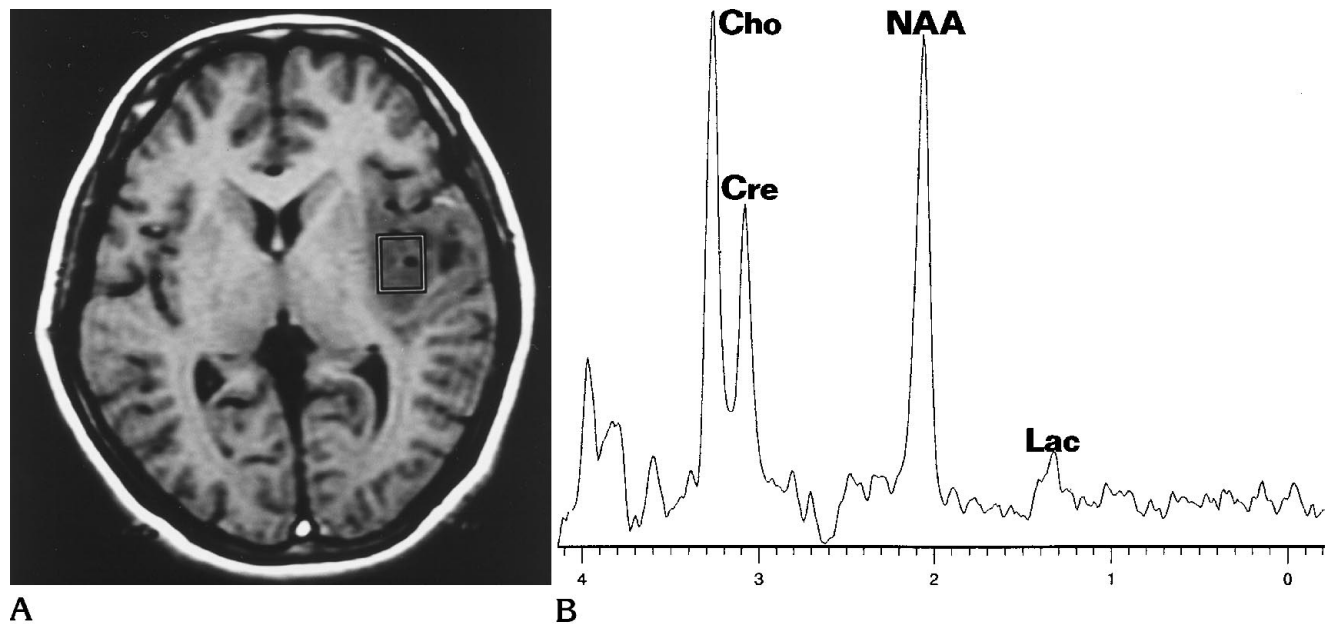


Fig 5. A, MR image of fibrillary astrocytoma (grade 2) at left temporal region.
 B, The spectrum from the VOI shown in A, acquired with PRESS (2000/272/256). Cho/reference, 2.78; Cre/reference, 1.61; and NAA/reference, 3.04. The small peak at 1.3 ppm has been assigned to lactate (*Lac*) after confirming its inversion at an echo time of 136 milliseconds (lactate/reference, 0.59).

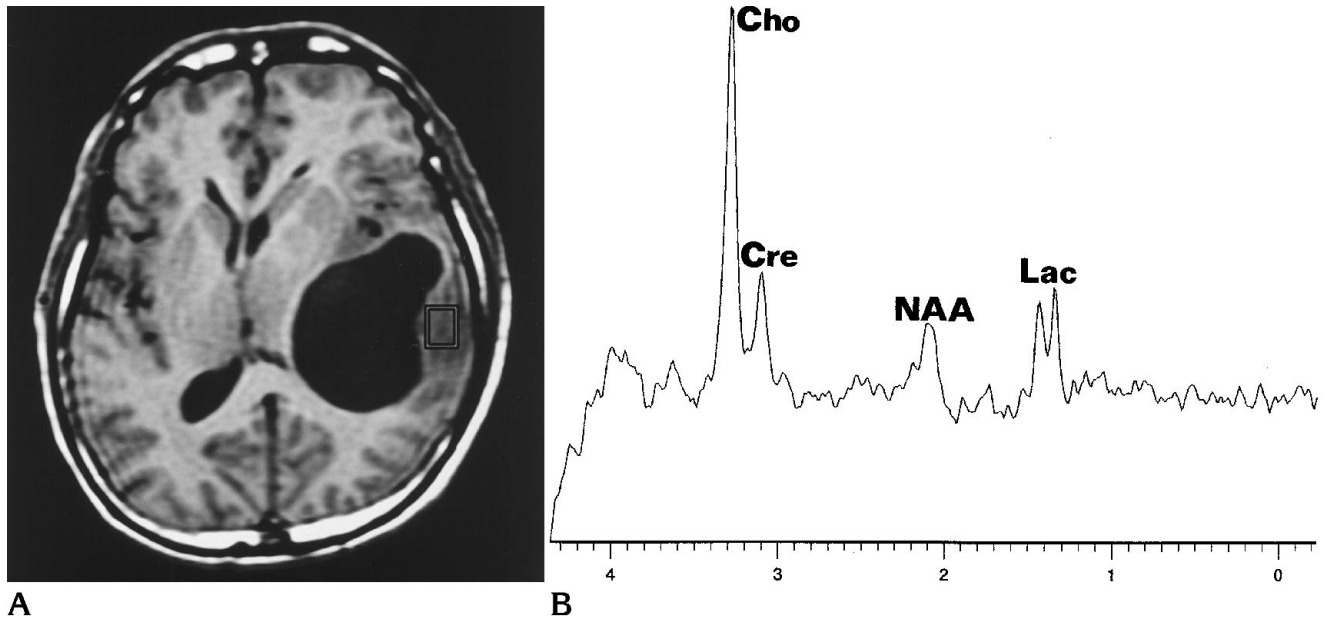


Fig 6. A, MR image of cystic anaplastic astrocytoma (grade 3). The VOI was carefully located within the tumor body.
 B, The spectrum from the VOI was acquired with PRESS (2000/272/256). Cho/reference, 4.19; Cre/reference, 1.06; NAA/reference, 1.52; and lactate (Lac) peak was confirmed by its inversion at an echo time of 136 milliseconds.

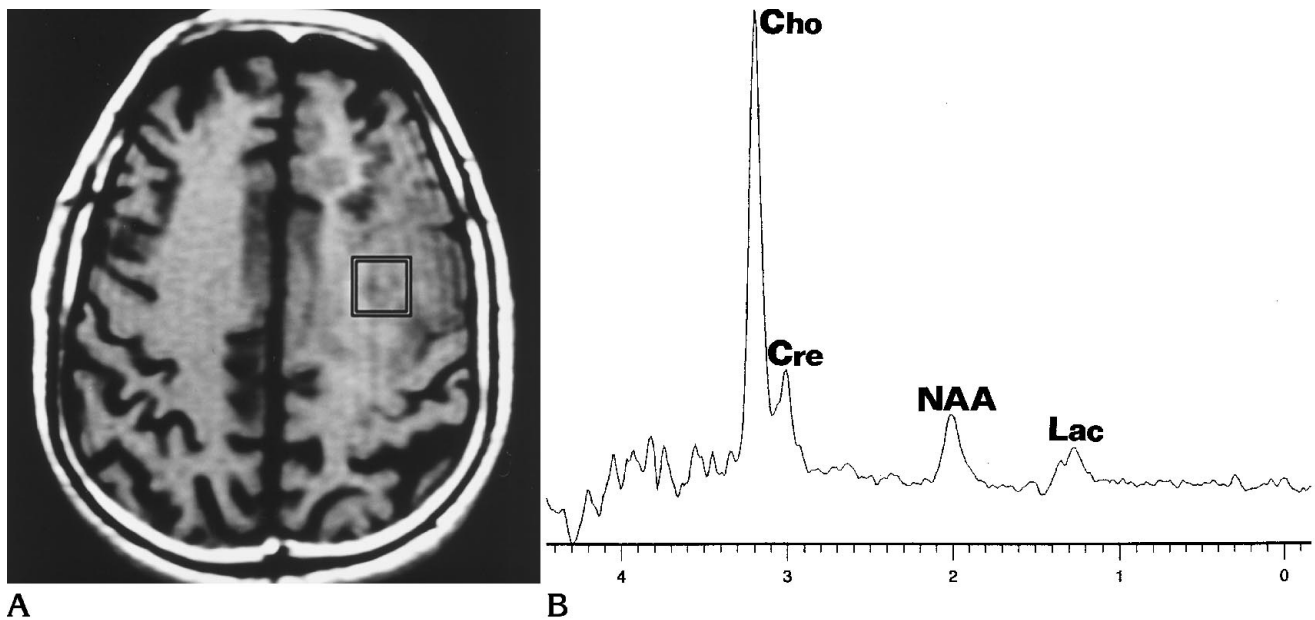


Fig 7. A, MR image of gliosarcoma (grade 4) at left frontal region.
 B, The spectrum from the VOI shown in A, acquired with PRESS (2000/272/256). Cho/reference, 5.52; Cre/reference, 1.02; NAA/reference, 1.18; and lactate (Lac) peak was confirmed by its inversion at an echo time of 136 milliseconds.

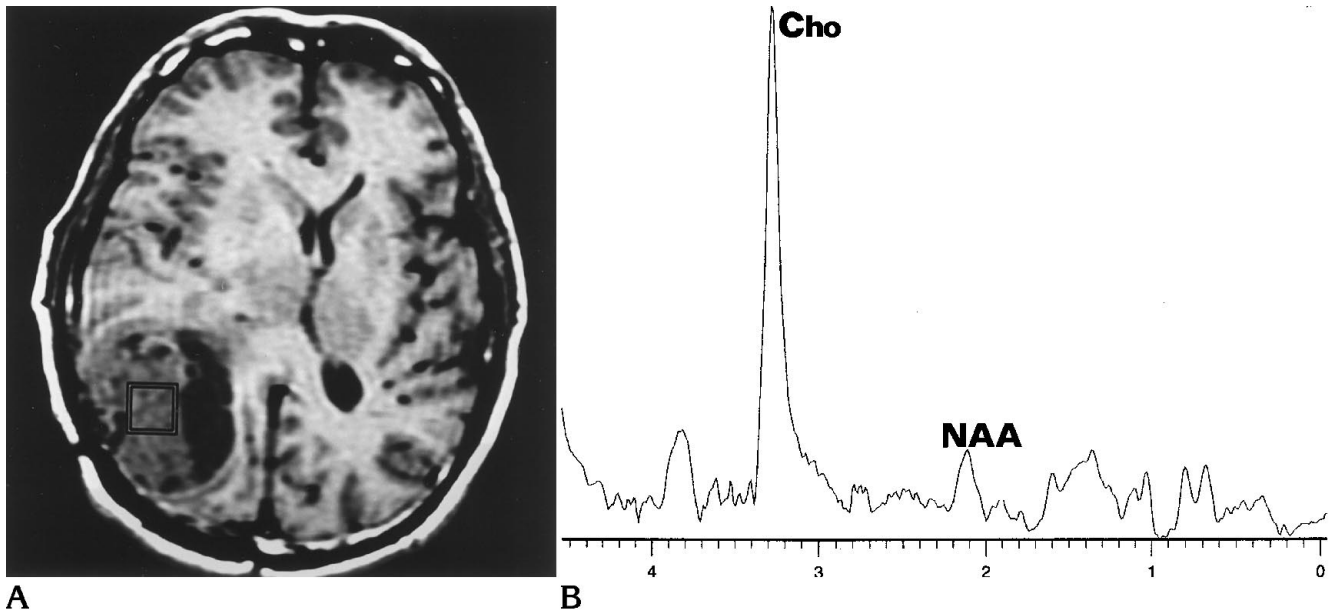


Fig 8. A, MR image of recurrent meningioma. B, The spectrum from the VOI shown in A, acquired with PRESS (2000/272/256). Cho/reference, 6.62 and NAA/reference, 0.99. The Cre peak was not measurable. A small peak at around 1.4 ppm may be a combined peak of alanine and lactate; however, the peak was not reliably measurable with the fitting routine used.

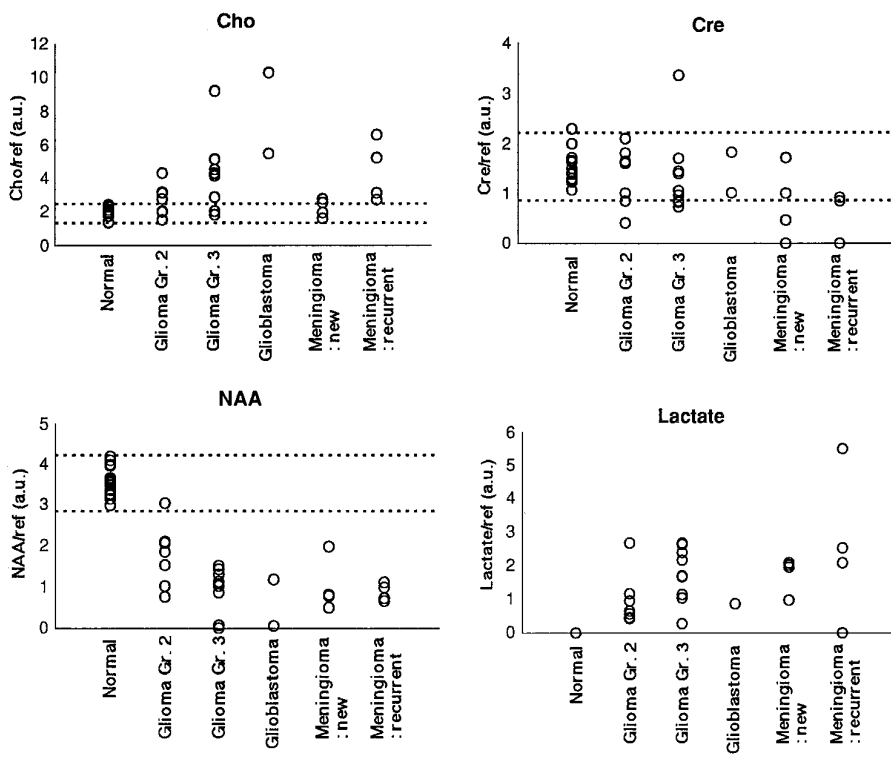


Fig 9. Scatterplots of the semiquantitated metabolite values for each tumor type and the normal frontal white matter. Dotted lines show the normal ranges (mean \pm 2 SD). For the lactate/reference, the normal value is 0. In meningiomas, a peak at around 1.3 to 1.4 ppm was considered to be a combined peak of alanine and lactate and is presented as the lactate/reference value. A.u. indicates arbitrary units; Gr., grade.

TABLE 2: Tumor metabolite

Type of Tumor	Semiquantitation Values				Metabolite Ratios		
	Cho/Ref	Cre/Ref	NAA/Ref	Lactate/Ref	Cho/NAA	Cho/Cre	Cre/NAA
Glioma (n = 17)							
Grade 1 (n = 1)	0.80	0.96	1.72	1.61	0.45	0.84	0.56
Grade 2 (n = 5)	2.78 ± 1.08	1.64 ± 0.40	1.97 ± 0.81†	0.63 ± 0.21	1.79 ± 1.40	1.68 ± 0.43	1.10 ± 0.93
Grade 3 + 4 (n = 11)	4.95 ± 2.66*†	1.39 ± 0.75	0.88 ± 0.56†‡	1.66 ± 0.81†	22.8 ± 48.4	3.79 ± 1.51*†	5.68 ± 9.72
Grade 3 (n = 9)	4.29 ± 2.17	1.38 ± 0.82	0.94 ± 0.55	1.75 ± 0.81	8.33 ± 12.5	3.27 ± 1.42	3.49 ± 6.45
Grade 4 (n = 2)	7.91 ± 3.37	1.43 ± 0.58	0.62 ± 0.79	0.87 (n=1)	80.8 ± 107.7	5.52 ± 0.12	14.43 ± 19.19
Meningioma (n = 8)	3.34 ± 1.71	0.62 ± 0.62§	0.95 ± 0.46†	2.45 ± 1.43†	4.06 ± 2.26†	...	0.71 ± 0.61
New (n = 4)	2.24 ± 0.52	0.80 ± 0.74§	1.02 ± 0.66†	1.76 ± 0.52†	2.86 ± 1.91†	...	0.78 ± 0.55
Recurrent (n = 4)	4.45 ± 1.82†	0.44 ± 0.51†	0.87 ± 0.22†	3.37 ± 1.86†	5.26 ± 2.11†¶	...	0.65 ± 0.75

Note.—Cho indicates choline-containing compounds; Ref, external reference; Cre, creatine/phosphocreatine; and NAA, *N*-acetyl aspartate. Values are mean ± SD. The mean of Cho/Cre was not calculated in meningiomas because Cre was not detectable in some cases. Grade 3 and 4 gliomas were pooled for statistics.

* $P < .01$, grade 2 gliomas vs grade 3 + 4 gliomas.

† $P < .01$, tumor vs normal.

‡ $P < .05$, grade 2 gliomas vs grade 3 + 4 gliomas.

§ $P < .05$, tumor vs normal.

|| $P < .05$, new vs recurrent meningiomas.

¶ $P < .01$, new vs recurrent meningiomas.

indicated that 2 were transitional, 1 was meningotheliomatous, and 1 was fibroblastic. Of the 4 recurrent meningiomas, 2 were transitional (fourth and second recurrences), 1 was atypical (first recurrence), and 1 was meningotheliomatous (first recurrence). None was malignant at histologic examination.

The representative cases are presented in Figures 4 through 8. All 17 gliomas and 8 meningiomas, except 1 grade 1 glioma, showed elevated Cho/NAA ratios. However, 4 of the 17 gliomas (2 grade 2 gliomas and 2 grade 3 gliomas) and 3 of the 8 meningiomas (all newly diagnosed) had Cho/reference values within the normal ranges (Fig 9). In these tumors, the decrease in the NAA peak was the actual cause of the high Cho/NAA ratios.

Figure 9 graphically summarizes the results of the cases in relation to a histologic diagnosis. Statistically significant differences between low-grade gliomas (grade 2) and high-grade gliomas (grades 3 and 4) were shown in the levels of Cho/reference and NAA/reference. The only significant difference between normal brain and grade 2 gliomas was that grade 2 gliomas had a lower NAA/reference value. The Cre/reference values were within the normal range in most of the gliomas and did not reveal any significant change across the malignancy. Lactate was more or less present in all the gliomas. Although high-grade gliomas tended to have higher lactate values than did low-grade gliomas, no sta-

tistically significant difference between malignancies was detected (Table 2). In one of the grade 4 gliomas, there was a large aliphatic signal at 1 to 1.5 ppm, and the lactate was not distinguishable in this case. Metabolite ratios also revealed changes related to malignancy. However, not only were the changes in individual peaks indistinct, but the standard deviations of the metabolite ratios were generally larger than those of the semiquantitation values.

With meningiomas in general, the semiquantitation values of Cho, Cre, and NAA were significantly different from the corresponding normal values, (ie, the Cho/reference value was moderately higher than normal, and the Cre/reference and NAA/reference values were much lower than normal). Although the mean Cho/reference value of the newly diagnosed meningiomas was not significantly different from the normal value, that of recurrent meningiomas was significantly higher than both the normal value and the Cho/reference value for newly diagnosed meningiomas.

In seven of the eight meningiomas, there was a double or triple peak at around 1.3 to 1.4 ppm. This peak can be from lactate or from alanine in meningiomas, but it is difficult to distinguish the lactate peak from the alanine peak with clinical proton MR spectroscopy, in which a static magnetic field of 1.5 T is used (12). Therefore, for the present study, we tentatively classified this peak as a combination of lactate

and alanine. The peak was higher in the recurrent meningiomas than in the newly diagnosed meningiomas on average; however, the difference was not statistically significant.

Discussion

Methodological Issues

Automated proton MR spectroscopy is available in 1.5-T whole-body MR systems (13). The software enables automated shimming and automated water suppression, resulting not only in shortening of the examination time but also in eliminating intraoperator and interoperator variations. However, methods for reproducible, quantitative spectral analysis are still under investigation (14–18). In previous studies, spectroscopic data have been most frequently interpreted by using the metabolite ratios within the spectrum (7, 14, 19–21). But this conventional method has a disadvantage in tumor studies because all the metabolites in tumors may be different from those in normal tissues. Therefore, a quantitative approach is needed, especially for studying brain tumors (1, 15). Some investigators have calculated the metabolite ratios between lesions and the apparently normal brain tissues (5–8, 21–23). However, an obvious question is whether the apparently normal brain tissue, such as contralateral brain, is in fact metabolically normal enough to provide control data (1). To maximize the value of clinical proton MR spectroscopy, we need to introduce a quantitative approach so that we can readily comprehend the dynamic changes in each metabolite.

An absolutely quantitative proton MR spectroscopy is ideal in theory, but at least three major problems related to it need to be solved (15, 24). First, a reliable procedure is needed for any spectral analysis obtained with a short echo time. These spectra are complicated by the contributions of a number of metabolites with short T2 relaxation times. The appropriate analysis of these complex spectra is under investigation (1, 18). Second, a method is needed to distinguish volumetrically the brain tissue compartment within the VOI from other structures such as cerebrospinal fluid, cysts, and necrosis. A promising method, which uses the T2 relaxation property of water protons (which is different in the brain tissue than it is in cerebrospinal fluid) has been proposed by Ernst et al

(17). Third, the T1 and T2 relaxation times of each metabolite must be measured on every occasion by varying the repetition times and echo times over several points. When applied to clinical imaging, this procedure creates a problem for the absolute quantitation because it requires a longer examination time.

We used spectra with long echo times because they provide better reproducibility in spectral analysis by eliminating contributions from metabolites with short T2 relaxation times. We carefully included only the tumor body and not the surrounding brain, cysts, or necrosis. Therefore, most of the spectral changes observed in the present study are attributable to changes in the tumor metabolism. However, the NAA signal was observed in several meningiomas, which should not contain NAA (12), so the spectra may have suffered from some partial volume effects (25). In some cases, the unavoidable inclusion of microcysts or micronecrosis may also have caused lactate and aliphatic signals.

In the present study, the external reference was used to generate the relative quantitation values of the metabolites. A similar approach was used in a study by Kreis et al (24) to show successfully the metabolic changes associated with brain maturation. However, the validity of using an external reference has, until now, been evaluated only partially (26, 27). Therefore, the reproducibility of the present method was first evaluated in the phantom experiments as well as in volunteer studies. The phantom experiment showed that the variation in the reference signal was as small as 2%. The 10-mmol/L solution quantitation experiment showed that the error in the calculated absolute concentration was less than 10%, unless the VOI was located far from the center. The variations in the NAA/reference values obtained from the same location were 5.7% in successive measurements and 10.2% when measurements were obtained on more than one occasion. Although comparable experiments were not found in the literature, we consider these variations to be within acceptable limits for in vivo MR spectroscopic studies. Variations of less than 5% in the NAA/reference values obtained from frontal white matter in 17 different subjects is comparable with results from Webb et al (13) and Kreis et al (14), who showed NAA/Cre ratio variations of 6.7% and 5.0% in 84 and 10 volunteers, respectively.

We did not measure the actual T1 and T2 relaxation times of each metabolite, because we did not want to extend the examination time. Since the spectra were acquired with echo times of 136 and 272 milliseconds in most patients, the T2 relaxation time could be calculated. The calculation of molar concentrations, as well as the changes in the T1 saturation factors, may have been applicable in the present study. However, as seen in Hennig et al (27), the T2 relaxation time and resulting concentrations calculated from spectra with only two different echo times may be erroneous. We therefore chose to continue to use the semiquantitation values.

Clinical Issues

Previous proton MR spectroscopy studies on human brain tumors can be divided, in terms of methodology, into localized single-voxel and the chemical-shift imaging techniques. Spectral interpretations were made by calculation of either metabolite ratios (eg, NAA/Cre, NAA/Cho) or ratios to apparently normal regions (eg, tumor NAA/contralateral brain NAA). The majority of the previous reports (5–8) failed to find spectroscopic parameters that characterize the tumor type or malignancy. Using the single-voxel method, Kugel et al (22) found a clear difference in spectra between gliomas and meningiomas; however, these researchers concluded that the malignancy of gliomas could not be estimated. Only one study (23) suggested a statistically significant dependence of Cho levels on malignancy of gliomas. The ratio of Cho of tumors to that of the contralateral hemisphere was significantly higher in high-grade gliomas than in low-grade gliomas. However, further investigations seem to be necessary before drawing conclusions, because this study (23) included patients not only before treatment but also during and after treatment. These overall results failed to show that proton MR spectroscopy was useful in the noninvasive evaluation of tumor type or malignancy.

On the other hand, Kinoshita et al (12) reported that in vitro proton MR spectroscopy can indicate the types of brain tumors and the degree of malignancy by showing the changes in metabolite concentrations. For example, high-grade astrocytic tumors had lower NAA and Cre concentrations and higher Cho concentrations than did low-grade astrocytomas. Two characteristic features of meningiomas were that NAA

was absent and that Cho was not above normal levels. These researchers suggested that glycine and alanine have diagnostic value in some tumors.

The discrepancy between these results may be due to one of the major advantages of in vitro studies over in vivo studies: in vitro studies allow the researchers to sample more carefully the tumor body and to avoid the inclusion of large necrosis, cyst, and surrounding brain tissues. Therefore, in the present study we strictly limited the VOI to be within the tumor body, and our results indicated that the malignancy of the gliomas can be predicted to a fairly large extent. High-grade gliomas had significantly higher Cho/reference values and lower NAA/reference values than did low-grade gliomas. The Cre/reference value was not an indicator of malignancy.

A few reports (6, 21) suggest that increased choline in the presence of lactate correlated with higher degrees of malignancy in astrocytomas. In the present study, the lactate/reference value tended to be higher in grade 3 and 4 gliomas than in grade 2 gliomas; however, as shown in Table 2 and Figure 9, the lactate/reference value was not a reliable indicator of malignancy. Data from several studies agree with our results showing the varying degrees of lactate across malignancies (7, 22, 23). The reason for this variation may be that lactate arises not only from the tumor itself but also from necrosis or cysts within the tumor.

Our results also showed that recurrent and new meningiomas had different Cho levels. Ott et al (7) reported that malignant meningiomas had higher Cho/Cre ratios than did benign meningiomas. In our patients with meningiomas, the histologic diagnoses were not significantly different in the two groups, and there were no malignant findings. Nevertheless, two of these meningiomas had recurred more than once despite previous complete surgical resections, so they should be considered as clinically more active or malignant. It will be valuable to investigate further whether Cho levels obtained by proton MR spectroscopy can predict the oncologic activity of meningiomas that are histologically indistinct.

Conclusions

Semiquantitative proton MR spectroscopy using an external reference was tested for its

validity and limitations in the evaluation of malignancy of gliomas and meningiomas. Histologic gradings of glioma were, to a great extent, predictable by Cho/reference and NAA/reference values. Recurrent meningiomas were characterized by higher Cho/reference values compared with newly diagnosed meningiomas. The present results indicate the usefulness of proton MR spectroscopy in the evaluation of tumor malignancy noninvasively.

References

- Barker PB, Glickson JD, Bryan N. In vivo magnetic resonance spectroscopy of human brain tumors. *Top Magn Reson Imaging* 1993;5:32-45
- Arnold DL, Shoubridge EA, Villemure JG, Feindel W. Proton and phosphorous magnetic resonance spectroscopy of human astrocytomas in vivo: Preliminary observations on tumor grading. *NMR Biomed* 1990;3:184-189
- Bruhn H, Frahm J, Gyngell ML, et al. Noninvasive differentiation of tumors with use of localized ^1H MR spectroscopy in vivo: initial experience in patients with cerebral tumors. *Radiology* 1989;172:541-548
- Langkowski JH, Wieland J, Bomsdorf H, et al. Preoperative localized in vivo proton spectroscopy in cerebral tumors at 4.0 Tesla: first results. *Magn Reson Imaging* 1989;7:547-555
- Herholz K, Heindel W, Luyten PR, et al. In vivo imaging of glucose consumption and lactate concentration in human gliomas. *Ann Neurol* 1992;31:319-327
- Demaerel P, Johannik K, van Hecke P, et al. Localized ^1H NMR spectroscopy in fifty cases of newly diagnosed intracranial tumors. *J Comput Assist Tomogr* 1991;15:67-76
- Ott D, Hennig J, Ernst T: Human brain tumors: assessment with in vivo proton MR spectroscopy. *Radiology* 1993;186:745-752
- Segebarth CM, Baleriaux DF, Luyten PR, den Hollander JA. Detection of metabolic heterogeneity of human intracranial tumors in vivo by ^1H NMR spectroscopic imaging. *Magn Reson Med* 1990;13:62-76
- Hayes CE, Edelstein WA, Schenck JF, Mueller OM, Eash M. An efficient, highly homogeneous radiofrequency coil for whole-body NMR imaging at 1.5T. *J Magn Reson* 1985;63:622-628
- Frahm J, Bruhn H, Gyngell ML, Merboldt KD, Hänicke W, Sauter R. Localized high-resolution proton NMR spectroscopy using stimulated echoes: initial applications to human brain in vivo. *Magn Reson Med* 1989;9:79-93
- Kleihues P, Burger PC, Scheithauer BW. *Histological Typing of Tumours of the Central Nervous System*, 2nd ed. Berlin, Germany: Springer-Verlag, 1993:11-30
- Kinoshita Y, Kajiwara H, Yokota A, Koga Y. Proton magnetic resonance spectroscopy of brain tumors: an in vitro study. *Neurosurgery* 1994;35:606-614
- Webb PG, Sailasuta N, Kohler SJ, Raidy T, Moats RA, Hurd RE. Automated single-voxel proton MRS: technical development and multisite verification. *Magn Reson Med* 1994;31:365-373
- Kreis R, Ross BD, Farrow NA, Ackerman Z. Metabolic disorders of the brain in chronic hepatic encephalopathy detected with H-1 MR spectroscopy. *Radiology* 1992;182:19-27
- Ross B, Kreis R, Ernst T. Clinical tools for the 90s: magnetic resonance spectroscopy and metabolite imaging. *Eur J Radiol* 1992;14:128-140
- Provencher SW. Estimation of metabolite concentrations from localized in vivo proton NMR spectra. *Magn Reson Med* 1993;30:672-679
- Ernst T, Kreis R, Ross BD. Absolute quantitation of water and metabolites in the human brain, I: compartments and water. *J Magn Reson* 1993;102:1-8
- Kreis R, Ernst T, Ross BD. Absolute quantitation of water and metabolites in the human brain, II: metabolite concentrations. *J Magn Reson* 1993;102:9-19
- Kreis R, Ross BD. Cerebral metabolic disturbances in patients with subacute and chronic diabetes mellitus: detection with proton MR spectroscopy. *Radiology* 1992;184:123-130
- van der Knaap MS, van der Grond J, Luyten PR, den Hollander JA, Nauta JJP, Valk J. ^1H and ^{31}P magnetic resonance spectroscopy of the brain in degenerative cerebral disorders. *Ann Neurol* 1992;31:202-211
- Luyten PR, Marien AJH, Heindel W, et al. Metabolic imaging of patients with intracranial tumors: ^1H MR spectroscopic imaging and PET. *Radiology* 1990;176:791-799
- Kugel H, Heindel W, Ernestus R-I, Bunke J, du Mensil R, Friedmann G. Human brain tumors: spectral patterns detected with localized H-1 MR spectroscopy. *Radiology* 1992;183:701-709
- Fulham MJ, Bizzi A, Dietz MJ, et al. Mapping of brain tumor metabolites with proton MR spectroscopic imaging: clinical relevance. *Radiology* 1992;185:675-686
- Kreis R, Ernst T, Ross BD. Development of the human brain: in vivo quantification of metabolite and water content with proton magnetic resonance spectroscopy. *Magn Reson Med* 1993;30:424-437
- Ernst T, Hennig J, Ott D, Friedburg H. The importance of the voxel size in clinical ^1H spectroscopy of the human brain. *NMR Biomed* 1989;2:216-224
- Narayana PA, Fotedar LK, Jackson EF, Bohan TP, Butler IJ, Wolinsky JS. Regional in vivo proton magnetic resonance spectroscopy of brain. *J Magn Reson* 1989;83:44-52
- Hennig J, Pfister H, Ernst T, Ott D. Direct absolute quantification of metabolites in the human brain with in vivo localized proton spectroscopy. *NMR Biomed* 1992;5:193-199