

Are your **MRI contrast agents** cost-effective?

Learn more about generic **Gadolinium-Based Contrast Agents**.



FRESENIUS
KABI

caring for life

AJNR

**Radiation-induced meningioma evaluated with
positron emission tomography with
fludeoxyglucose F 18.**

H Kado, T Ogawa, J Hatazawa, M Iwase, I Kanno, T Okudera and
K Uemura

This information is current as
of April 19, 2024.

AJNR Am J Neuroradiol 1996, 17 (5) 937-938
<http://www.ajnr.org/content/17/5/937>

Radiation-Induced Meningioma Evaluated with Positron Emission Tomography with Fludeoxyglucose F 18

Hirotsugu Kado, Toshihide Ogawa, Jun Hatazawa, Masaaki Iwase, Iwao Kanno, Toshio Okudera, and Kazuo Uemura

Summary: We describe a patient with radiation-induced meningioma 12 years after cranial irradiation for ectopic germinoma. PET scans with fludeoxyglucose F 18 showed a high glucose metabolic rate in the meningioma despite a benign histologic appearance.

Index terms: Brain neoplasms, therapeutic radiology; Iatrogenic disease or disorder; Meningioma; Positron emission tomography; Radiation, effects

Radiation-induced neoplasms sometimes develop as a result of DNA injury caused by irradiation (1). Meningioma is the most common radiation-induced neoplasm. Radiation-induced meningiomas have been reported to behave aggressively as compared with "spontaneous" meningiomas (2). We evaluated a radiation-induced meningioma by using positron emission tomography and fludeoxyglucose F 18 to determine the metabolic activity of this neoplasm.

Case Report

A 32-year-old man was admitted to our hospital with abrupt disturbance of consciousness. He had undergone a craniotomy for ectopic germinoma in the left basal ganglia area 12 years earlier. After surgical resection of the tumor, he had received a course of radiation therapy with a total dose of 50 Gy by means of a 10-MV linear accelerator. He was discharged with mild right hemiparesis after completion of the radiation therapy.

On the present admission, contrast-enhanced computed tomography (CT) showed a markedly enhancing tumor with surrounding calcification in the left middle cranial fossa that had not been present on contrast-enhanced CT scans 12 years earlier. Magnetic resonance (MR) imaging clearly showed that the tumor was extraaxial in origin (Fig 1A). The location of the tumor corresponded to the previous radiation field.

Positron emission tomography (PET) with fludeoxyglucose F 18 (FDG) showed that glucose metabolism of the central part of the tumor was similar to that in the contralateral gray matter (Fig 1B). The left external carotid angiogram showed that the tumor was fed by the middle meningeal artery. It was diagnosed as a radiation-induced meningioma.

Owing to the tendency of radiation-induced meningiomas to recur, surgical resection with a wide dural margin was performed. Pathohistologic analysis revealed that this tumor was a meningothelial meningioma. However, histologic findings showed no evidence of malignancy.

Discussion

Although many kinds of intracranial radiation-induced neoplasms have been reported, meningioma, sarcoma, and glioma are the most common (3). The criteria for diagnosing a radiation-induced neoplasm are usually defined as follows (3): (a) the second tumor must develop in the radiation field, (b) there is a sufficient delay between irradiation and the development of the second tumor, (c) histologic findings of the second tumor must be different from those of the initial tumor, and (d) there is no family history of tumor diathesis or phakomatosis. As this case did fulfill these criteria, we diagnosed it as a radiation-induced meningioma.

Many reports published previously showed that radiation-induced meningiomas have a strong tendency for aggressive biological behavior (2, 4, 5). There is a slight male predominance, multiple meningiomas are often found, and they have a higher recurrence rate in comparison with "spontaneous" meningiomas. Soffer et al (2) reported an 18% recurrence rate in patients with radiation-induced meningioma.

Received April 28, 1995; accepted after revision September 18.

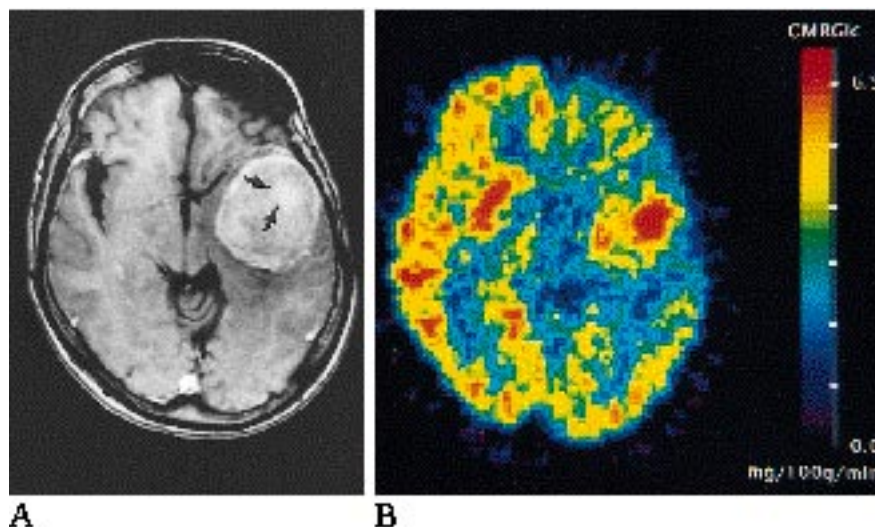
From the Departments of Radiology and Nuclear Medicine (H.K., T.Og., J.H., I.K., T.Ok., K.U.) and Surgical Neurology (M.I.), Research Institute of Brain and Blood Vessels, Akita, Japan.

Address reprint requests to Toshihide Ogawa, MD, Department of Radiology and Nuclear Medicine, Research Institute of Brain and Blood Vessels-Akita, 6-10, Senshu-kubota-machi, Akita City 010, Akita, Japan.

AJNR 17:937-938, May 1996 0195-6108/96/1705-0937 © American Society of Neuroradiology

Fig 1. A, Contrast-enhanced axial T1-weighted gradient-echo MR (450/9 [repetition time/echo time], flip angle, 90°) shows a round, enhancing tumor in the left middle cranial fossa. The tumor is heterogeneously enhanced and the central part (arrows) is markedly enhanced. The gray matter of the insula and the temporal lobe facing the tumor are compressed medially and posteriorly.

B, FDG PET scan shows that the central part of the tumor, which is markedly enhanced, has a high glucose metabolic rate, whereas the glucose metabolic rate of the left frontal and temporal cortices surrounding the tumor is low.



Rubinstein et al (5) reported, on the basis of a histologic analysis, that radiation-induced meningiomas have increased cellularity, greater pleomorphism, higher mitotic rates, and increased frequency of giant cells, and are generally more aggressive in behavior. The histologic findings in our case revealed a typical, benign, meningotheial type tumor without any increased cellularity and greater pleomorphism. Soffer et al (2) reported a higher frequency of malignancy in radiation-induced meningiomas, whereas Harrison et al (4) observed no overt malignancy but a high rate of occurrence of atypical meningiomas in their cases of radiation-induced meningioma.

There are no reports that CT and MR imaging findings are different for radiation-induced meningiomas than for "spontaneous" meningiomas. Montanera et al (6) reported coexisting meningiomas and occlusion of the larger intracranial arteries as a result of extracranial radiation. They stressed that preoperative angiography was necessary in any patient who had a second brain tumor and a history of extracranial radiation.

Di Chiro et al (7) reported that the glucose metabolic rate of tumor tissue was correlated with the degree of malignancy. Functional studies using PET with FDG showed that meningiomas generally have a low glucose metabolic rate (8). On the other hand, Di Chiro et al showed that the glucose metabolic rate of meningiomas correlated with the growth rate of the tumors, independent of their pathohistology. Meningiomas displaying high glycolytic rates

tend to be aggressive, whereas a lower glucose metabolic rate is associated with late recurrence. Therefore, these authors suggested that the glucose utilization rate of meningiomas would be a good index of the rate of recurrence and aggressiveness (7). In this case, the radiation-induced meningioma showed a high glucose metabolic rate, similar to that of contralateral gray matter. These results suggest that this tumor may have aggressive biological behavior despite its benign histologic appearance.

References

- Anderson JR, Treip CS. Radiation-induced intracranial neoplasms. *Cancer* 1984;53:426-429
- Soffer D, Pittaluga S, Feniner M, et al. Intracranial meningiomas following low-dose irradiation to the head. *J Neurosurg* 1983;59:1048-1053
- Marus G, Levin CV, Rutherford GS. Malignant glioma following radiotherapy for unrelated primary tumors. *Cancer* 1986;58:886-894
- Harrison MJ, Wolfe DE, Lau T-S, et al. Radiation-induced meningiomas: experience at the Mount Sinai Hospital and review of the literature. *J Neurosurg* 1991;75:564-574
- Rubinstein AB, Shalit MN, Cohen ML, et al. Radiation-induced cerebral meningioma: a recognizable entity. *J Neurosurg* 1984;61:966-971
- Montanera W, Chui M, Hudson A. Meningioma and occlusive vasculopathy: coexisting complications of past extracranial radiation. *Surg Neurol* 1985;24:35-39
- Di Chiro G, Hatazawa J, David AK, et al. Glucose utilization by intracranial meningiomas as an index of tumor aggressivity and probability of recurrence: a PET study. *Radiology* 1987;164:521-526
- Ericson K, Lilja A, Bergstrom M, et al. Positron emission tomography with (^{11}C)-methyl-L-methionine, (^{11}C)-D-glucose and (^{68}Ga)-EDTA in supratentorial tumors. *J Comput Assist Tomogr* 1985;9:683-689