

Are your MRI contrast agents cost-effective?

Learn more about generic Gadolinium-Based Contrast Agents.



**FRESENIUS
KABI**

caring for life

AJNR

**Chorea-ballismus with nonketotic hyperglycemia
in primary diabetes mellitus.**

P H Lai, R D Tien, M H Chang, M M Teng, C F Yang, H B Pan, C
Chen, J F Lirng and K W Kong

AJNR Am J Neuroradiol 1996, 17 (6) 1057-1064

<http://www.ajnr.org/content/17/6/1057>

This information is current as
of April 10, 2024.

Chorea-Ballismus with Nonketotic Hyperglycemia in Primary Diabetes Mellitus

Ping-Hong Lai, Robert D. Tien, Ming-Hong Chang, Michael M. H. Teng, Chien-Fang Yang, Huay-Ben Pan, Clement Chen, Jiing-Feng Lin, and Koon-Wah Kong

PURPOSE: To describe the neuroimaging (CT, MR, and single-photon emission CT [SPECT]) findings in a series of patients with chorea-ballismus associated with nonketotic hyperglycemia in primary diabetes mellitus and to correlate the imaging findings with the clinical presentation. **METHODS:** The neuroimaging and clinical data from 10 patients with chorea-ballismus associated with nonketotic hyperglycemia in primary diabetes mellitus were evaluated. Family and drug histories, as well as other causes of chorea, were excluded. All 10 patients had CT, 5 also had MR imaging, and 3 had SPECT examinations. Three had follow-up CT and MR imaging studies, and MR findings were correlated with CT findings in 5 cases. Two experienced neuroradiologists, aware of the diagnosis but blinded to the clinical status of the patients, evaluated all images and reached a consensus as to the final interpretation. **RESULTS:** CT studies in 9 of 10 patients showed a hyperdense putamen and/or caudate nucleus; in 1, the CT findings were normal. T1-weighted MR images in all 5 patients who had MR imaging (including the patient with a normal CT study) showed hyperintense lesions without significant T2 signal alternation at the basal ganglia. In all 3 of the patients who had SPECT studies of the brain, the scans revealed hypoperfusion at corresponding areas. All 3 follow-up studies depicted resolution of the lesions in the abnormal basal ganglia. Increased hypointensity on T2-weighted and gradient-echo T2*-weighted images was also observed in the sequential MR images. In all patients, the initial side of involvement correlated well with the neuroimaging findings. The chorea resolved within 2 days after treatment of the hyperglycemia in 9 patients. **CONCLUSION:** In patients with chorea-ballismus associated with nonketotic hyperglycemia in primary diabetes mellitus, CT and T1-weighted MR images show unilateral or bilateral lesions of the putamen and/or caudate. SPECT scans show hypoperfusion. These findings may be related to petechial hemorrhage and/or myelin destruction. Early recognition of these imaging characteristics may facilitate diagnosis of primary diabetes mellitus with hyperglycemia and prompt appropriate therapy.

Index terms: Chorea; Diabetes mellitus; Hyperglycemia

AJNR Am J Neuroradiol 17:1057-1064, June 1996

Chorea and ballismus can result from a variety of conditions, including cerebrovascular dis-

orders, infections, drugs, metabolic abnormalities, neurodegenerative diseases, immunologic disorders, and tumors, as well as from nonketotic hyperglycemia in primary diabetes mellitus (1, 2). These involuntary movements have been described with lesions in the subthalamic nucleus, corpus striatum, cerebral cortex, thalamus, and brain stem (1, 3). Nonketotic hyperglycemia is an unusual cause of chorea-ballismus, and chorea-ballismus is also a rare manifestation of primary diabetes mellitus (1-15). Since chorea-ballismus can be life-threatening (3), recognition of this disorder is important because chorea-ballismus caused by hyperglycemia is a treatable disorder with a good prognosis (2, 4-15).

Received September 27, 1995; accepted after revision January 3, 1996.

From the Departments of Radiology (P.H.L., C.F.Y., H.B.P., C.C.) and Neurology (M.H.C., K.W.K.), Veterans General Hospital- Kaohsiung, National Yang Ming University, National Defense Medical Center, Taiwan, Republic of China; the Department of Radiology, Duke University Medical Center, Durham, NC (P.H.L., R.D.T.); and the Department of Radiology, Veterans General Hospital-Taipei, National Yang Ming University, National Defense Medical Center, Taiwan, Republic of China (M.M.H.T., J.F.L.).

Address reprint requests to Chien-Fang Yang, MD, Department of Radiology, Kaohsiung Veterans General Hospital, 386 Tachung First Rd, Kaohsiung, Taiwan 80780, Republic of China.

AJNR 17:1057-1064, Jun 1996 0195-6108/96/1706-1057

© American Society of Neuroradiology

Clinical information and laboratory data in 10 patients with chorea-ballismus associated with nonketotic hyperglycemia in primary diabetes

Case	Age, y/ Sex	Diabetes Mellitus History	Involved Side	Initial Blood Sugar, mg/dL	Initial Serum Osmolarity, mOsm/kg	Duration, d/ Outcome	Imaging	Time from Chorea Onset to CT	Lesion Location
1	66/M	2 y	R	300	310	2/Good	CT, MR	4 d, 2 mo, 6 mo, 1 y	L putamen
2	78/M	3 y	Bilateral	245	296	2/Good	CT, MR	5 d, 2 mo, 6 mo	Bilateral caudate, putamen; lateral globus pallidus
3	67/M	Unknown	R	337	302	1/Good	CT, MR	7 d, 2 mo, 6 mo	L putamen
4	77/M	Unknown	R	284	300	1/Good	CT, MR	4 d	L caudate, putamen
5	65/M	3 y	R	350	311	2/Good	CT, MR	5 d	L putamen
6	77/M	7 y	R	290	301	1/Good	CT	5 d	L caudate, putamen
7	75/M	3 mo	R	200	305	1/Good	CT	7 d	L caudate, putamen
8	69/M	Unknown	L	254	285	1/Good	CT	7 d	R putamen
9	68/M	4 y	Bilateral	560	360	3/Death	CT	7 d	Bilateral caudate, putamen
10	59/M	Unknown	Bilateral	414	325	2/Good	CT	3 d	Bilateral caudate, putamen

Several case reports have described variable computed tomographic (CT) findings in this disorder, including no abnormalities (4–9), high density in the caudate (10), high density in both the caudate and putamen (11, 12), and high density in just the putamen (13, 14). Three case reports have described magnetic resonance (MR) imaging findings of high-intensity lesions in the basal ganglia on T1-weighted images (13–15). It is probable that some patients with chorea-ballismus on admission might have coincidental hyperglycemia caused by secondary diabetes mellitus in conjunction with other disease processes. Positive neuroimaging findings may help the physician identify structural lesions that could cause chorea and may also facilitate an earlier diagnosis of true primary diabetes with hyperglycemia and prompt appropriate therapy. Our purpose was to study the CT, MR, and single-photon emission CT (SPECT) findings in a series of patients with chorea-ballismus associated with nonketotic hyperglycemia in primary diabetes mellitus and to correlate these imaging findings with the clinical presentation.

Materials and Methods

Over a period of 4 years, we conducted a retrospective review of the records of 10 men with chorea-ballismus associated with nonketotic hyperglycemia in primary diabetes who had CT and/or MR imaging of the brain. These 10 patients were 59 to 78 years old (mean, 70 years); none had a family history of movement disorders; and none had taken any medication that could cause chorea-ballismus (eg, neuroleptic drugs, metoclopramide hydrochloride, or levodopa). Other causes of chorea, including

Wilson disease, thyroid disease, and systemic lupus erythematosus, were also excluded. No patient had evidence of previous infarction in the region of the basal ganglia on CT and/or MR imaging studies.

MR imaging (performed in five patients; cases 1 to 5, see the Table) was done on a 1.5-T superconducting system. Spin-echo T1-weighted images with parameters of 600/20/2 (repetition time/echo time/excitations) and proton density- and T2-weighted images with parameters of 2500/15,90/1 were obtained in the axial plane. Gradient-echo T2*-weighted images were obtained with parameters of 750/50/1 and a 10° flip angle. Images were 5 mm thick with a 2.5-mm gap between sections. The acquisition matrix was 256 × 256, with a 20-cm field of view. Three patients (cases 1 through 3) received follow-up MR examinations at 2 and 6 months, and one patient (case 1) also had a follow-up study at 1 year. The signal intensity of the basal ganglia (caudate nucleus, putamen, globus pallidum) was compared with the signal of the gray matter.

CT studies of the brain were obtained in the axial plane by using 8-mm-thick contiguous sections. Noncontrast CT scans were available in all patients. Three patients (cases 1 through 3) received follow-up CT examinations at 2 and 6 months, and one patient (case 1) also had a follow-up study at 1 year. The abnormal density of the basal ganglia was evaluated as hyperdensity, isodensity, or hypodensity relative to gray matter. Measurements of Hounsfield units (HU) in both basal ganglia were taken in every CT examination. CT scans were obtained from 3 to 7 days after the onset of symptoms, and all MR images were obtained within 3 days after CT. Two experienced neuroradiologists, trained in MR imaging and CT and blinded to the clinical status of the patient, evaluated all images for lesion location, attenuation abnormalities on CT scans, and signal changes on MR images, and reached a consensus as to the final interpretation.

Three patients (cases 1, 3, and 7) were examined with SPECT at 8 days and at 4 months in case 1, and at 14 days in cases 3 and 7, after the onset of chorea. Technetium Tc

99m hexamethylpropyleneamine oxime (HMPAO) brain SPECT, done to evaluate regional blood flow, was performed 10 minutes after an intravenous injection of 370 Mbq of ^{99m}Tc HMPAO. Scanning equipment consisted of a rotating, large-field-of-view gamma camera fitted with a low-energy, high-resolution collimator. Sixty images were acquired for 10 seconds each during a 360° camera rotation. Each image was stored in a 64 × 64-pixel matrix. Reconstruction of the image was performed with attenuation correction, using Hanning filters to produce transaxial sections.

Clinical and Laboratory Data

Six patients had abnormal movements on the right side (cases 1 and 3 through 7), one patient had abnormal movements on the left side (case 8), and three patients had bilateral abnormal movements (cases 2, 9, and 10) noted for several (3 to 7) days at the initial presentation (Table). All patients were conscious except one (case 9), who was comatose. This patient died of acute neurologic deterioration and respiratory arrest of unknown cause 3 days after admission. Autopsy studies were not available. In the nine conscious patients, chorea resolved within 2 days after correction of the hyperglycemia. A history of diabetes mellitus was established in six patients (cases 1, 2, 5 through 7, and 9); the other four had no such history, although they were subsequently proved to have diabetes mellitus during their hospital stay. Initial blood sugar levels ranged from 200 to 560 mg/dL on admission. A history of hypertension could be traced in four patients (cases 4, 7, 8, and 10); however, all patients were normotensive during the hospital course. There were no ketones in the serum, and calculated serum osmolality ranged from normal to mild hyperosmolality (285 to 325 mOsm/kg) in all patients except case 9, who had severe hyperosmolality (360 mOsm/kg).

Results

Initial CT and MR Examinations

The lesions were located in the putamen unilaterally in four patients (cases 1, 3, 5, and 8), in the putamen and caudate unilaterally in 3 patients (cases 4, 6, and 7), in the putamen and caudate bilaterally in two patients (cases 9 and 10), and in the putamen and caudate and lateral portion of the globus pallidus bilaterally in one patient (case 2).

On CT scans, 9 of 10 patients had slightly increased density in the involved caudate nucleus and/or putamen (Figs 1A and 2A). Tissue density was found to be 40 to 51 HU for the areas of increased attenuation in the involved basal ganglia. In the comparatively normal areas of the basal ganglia, tissue density was 33

to 36 HU. One patient (case 5) had normal CT findings.

At MR imaging, all patients (including the patient with a normal CT study) had increased signal intensity in the involved basal ganglia on T1-weighted images (Figs 1B, 2B and C). Abnormalities were delineated better and were more often conspicuous on the MR images than on the CT scans. Proton-density T2-weighted images showed slightly hyperintense signal relative to the contralateral side (Fig 1C), and gradient-echo T2*-weighted images revealed no significant signal alternation in case 1. Proton-density T2-weighted and gradient-echo T2*-weighted images showed no significant signal alternation in the other four patients (cases 2 through 5).

In all patients, the manifestation of chorea-ballismus correlated well with the neuroimaging findings. In the six patients with right-sided symptoms, a lesion was noted on CT scans and/or MR images in the contralateral left basal ganglia. In the one patient with left-sided symptoms, a lesion was found in the right basal ganglia. In the three patients with bilateral chorea-ballismus, CT scans and/or MR images showed lesions in the basal ganglia bilaterally.

Follow-up CT and MR Examinations

In case 1, CT scans showed that the high attenuation in the left putamen had completely resolved after 2 months (Fig 1E), and there was no change at 1 year. T1-weighted MR images in this patient revealed that the hyperintensity had decreased within 6 months and had completely resolved at 1 year (Fig 1F and I). The patient remained well during the year after resolution of chorea-ballismus. In case 2, CT scans showed decreased attenuation and T1-weighted MR images showed decreased signal intensity bilaterally in the abnormal basal ganglia at 2 months. The 6-month follow-up imaging studies showed normal density on CT scans and more decreased signal intensity on MR images. The patient remained well, although bilateral chronic subdural hematoma was noted incidentally (Fig 2D). The third patient (case 3) returned about 2 months later, when a second episode of diabetic hyperglycemia occurred, with hyperkinetic movements of the right arm. Increased signal intensity was noted in the left putamen on T1-weighted images as compared with the first MR

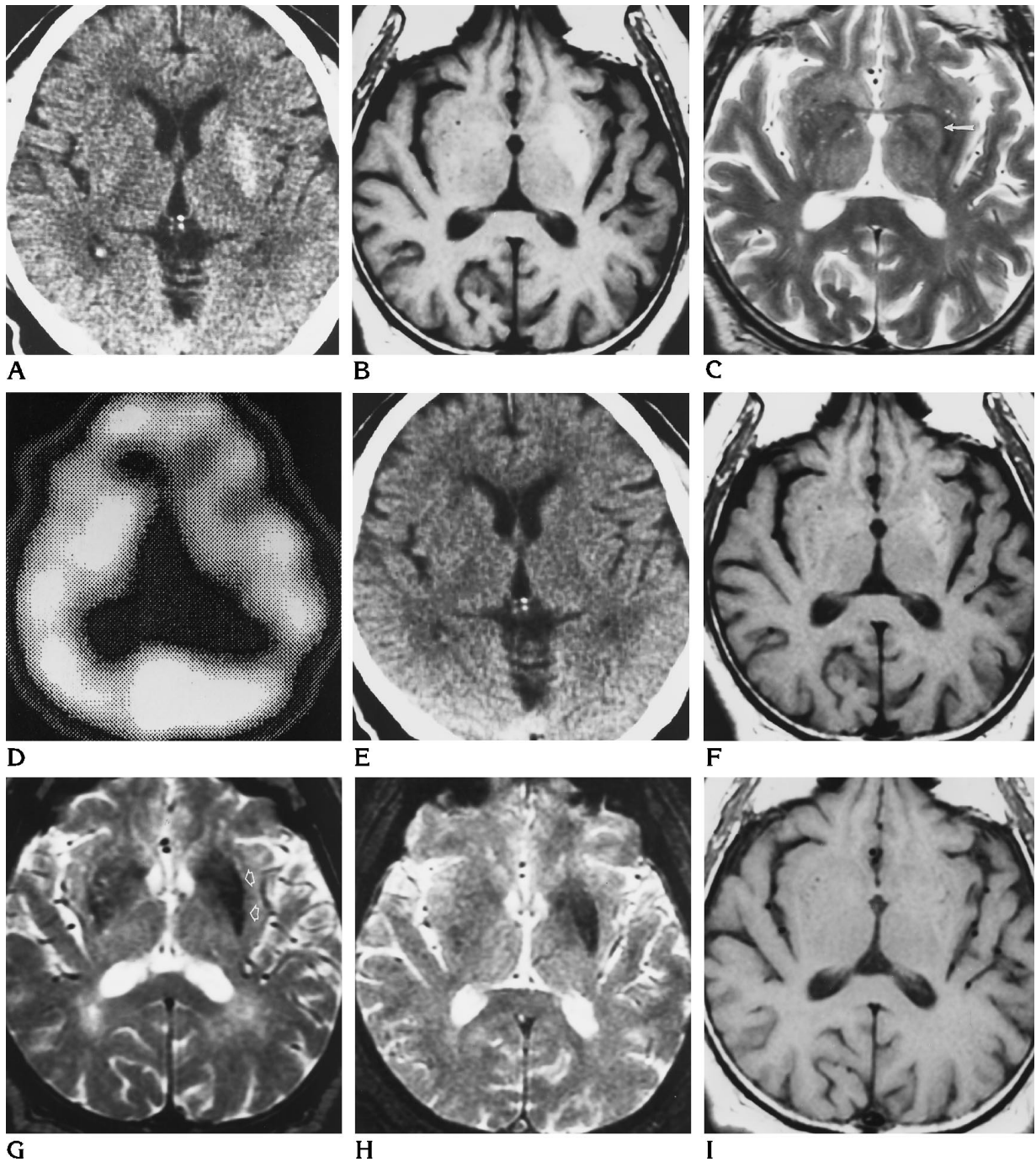


Fig 1. Case 1: 66-year old man with diabetes and abrupt onset of involuntary movements involving right limbs. CT scans were obtained 4 days after hemichorea; MR images at 6 days. (All CT scans were acquired with identical center and window level. All MR images were acquired with identical imaging parameters and were photographed with identical window and level settings.)

A, Unenhanced CT scan shows slightly increased attenuation in the left putamen.

B, Axial T1-weighted (600/20) MR image reveals increased signal intensity, mainly in the left putamen.

C, T2-weighted (2500/90) MR image, which corresponds to B, shows slightly higher signal intensity on the left (arrow) than on the right.

D, HMPAO brain SPECT scan obtained 8 days after hemichorea shows decreased perfusion in regions of the left basal ganglia.

E-H, CT and MR images obtained after 2 months. The high density is resolved on unenhanced CT scan (E). T1-weighted (600/20) MR image (F) shows reduction of hyperintense signal in left putamen. Corresponding T2-weighted (2500/90) MR image (G) shows mildly decreased intensity involving left putamen (arrows). Significant hypointense left putamen is also noted on gradient-echo T2*-weighted (750/50, 10° flip angle) MR image (H).

I, The abnormal signal intensity is completely resolved on T1-weighted (600/20) MR image obtained at same level 1 year later.

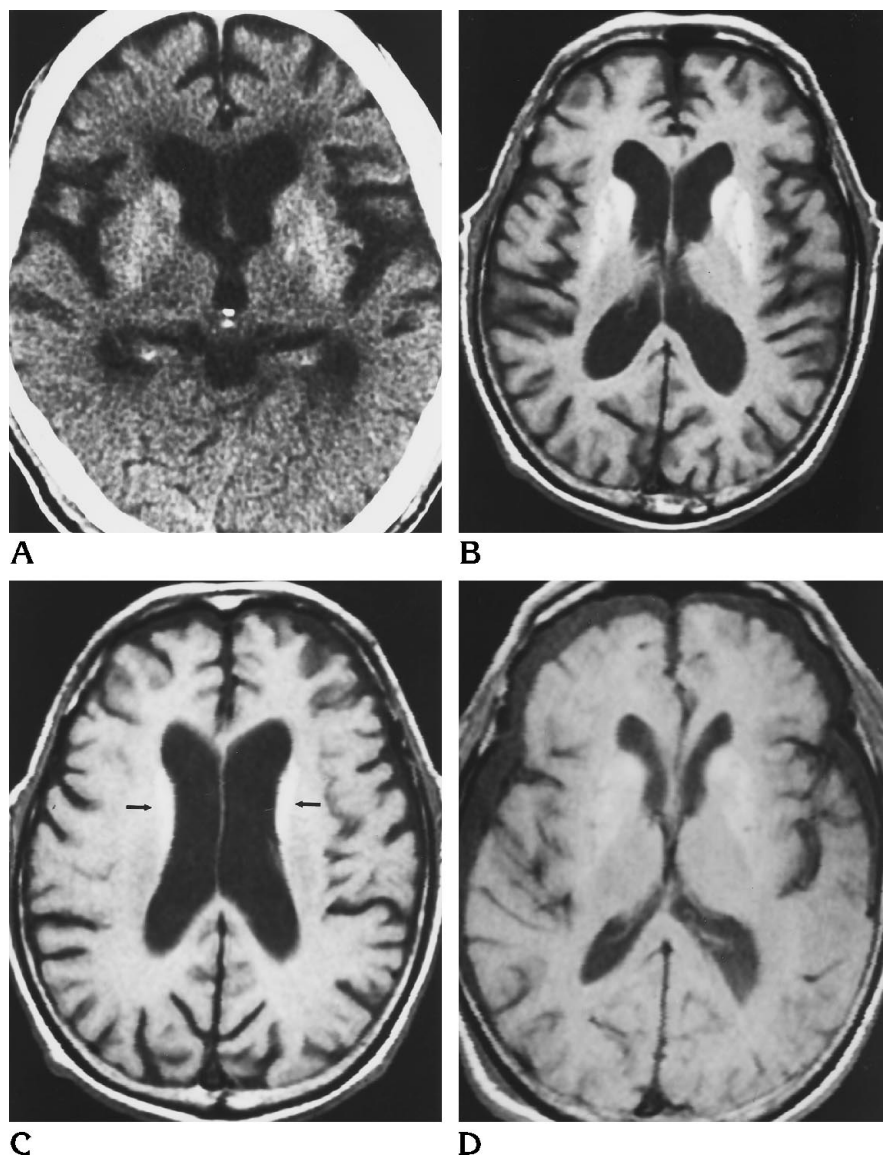


Fig 2. Case 2: 78-year-old man with diabetes in whom bilateral involuntary choreoathetoid movements of the face and limbs developed suddenly. CT scans were obtained 5 days after onset of chorea-ballismus; MR images after 7 days.

A, Unenhanced CT scan shows slightly increased attenuation involving the head of the caudate nucleus, the putamen, and adjacent portion of the globus pallidus bilaterally.

B and C, T1-weighted (600/20) MR images at two consecutive levels show markedly increased signal intensity in the head of the caudate nuclei bilaterally, in the body adjacent to the lateral ventricle (arrows), and in the putamen and adjacent portion of the globus pallidus bilaterally.

D, T1-weighted (600/20) MR image obtained 6 months later shows reduction of hypersignal. Bilateral chronic subdural hematoma is noted incidentally.

image. The chorea resolved after treatment, and the signal intensity was decreased at the 6-month follow-up examination. Increased hypointensity on T2-weighted and gradient-echo T2*-weighted images was observed on the sequential MR images in cases 1 to 3 (Fig 1G and H). Follow-up neuroimaging findings correlated well with the clinical course in these three patients. Nevertheless, resolution of the lesions noted on the imaging studies was slower than the clinical course.

Initial and Follow-up SPECT Examinations

The first HMPAO brain SPECT study (Fig 1D) revealed decreased regional blood flow in the area of the left basal ganglia, corresponding to

CT and MR findings in all patients, and, in one patient, decreased regional perfusion was still noted on follow-up examinations 4 months later.

Discussion

The critical pathophysiological basis for chorea-ballismus associated with nonketotic hyperglycemia in primary diabetes mellitus is unknown. It is probable that underlying chronic focal cerebrovascular diseases in primary diabetes mellitus (16, 17) provide the basis for acute blood-brain barrier dysfunction (18) and synergetic metabolic effects during the hyperglycemic episode (17, 19). Hyperglycemia also produces a global decrease in regional cerebral

blood flow with maximal reduction in the basal ganglia. Thus, the reduction of cerebral blood flow may contribute to the reduction of local amounts of γ -aminobutyric acid. Depletion of corpus striatal γ -aminobutyric acid in nonketotic hyperglycemia may allow increased pallidal activity with resultant dyskinesia (17, 19).

The presence of lesions with increased signal intensity on spin-echo T1-weighted images is unusual; relatively few documented tissue abnormalities have been associated with such signal intensity (20–27). Hyperintense signal in the region of the basal ganglia on T1-weighted MR images has been noted by other investigators (20, 26–30), and has been associated with manganese toxicity in long-term parenteral nutrition (26), chronic liver failure (28), problems of calcium metabolism (20), Wilson disease (27), neurofibromatosis (29), and hypoxic brain changes (30). The lesions reported in connection with the first two conditions were located mainly in the globus pallidus, symmetrically. In the others, there were lesions in additional areas as well. In our series, chorea-ballismus with hyperglycemia was restricted largely to the putamen and/or caudate nucleus.

The differential diagnosis of acutely developing increased density on CT scans includes calcification and hemorrhage (31). An imaging abnormality that has an apparently rapid onset and that disappears within months more or less rules out calcium as a cause (32). In our patients, only slightly increased attenuation in the range of 40 to 51 HU was noted in the abnormal areas of the basal ganglia. Attenuation in the comparatively normal areas of the basal ganglia was about 33 to 36 HU. This finding could be explained by multiple petechial hemorrhages rather than an intracerebral hematoma.

MR examinations of our patients were obtained 6 to 10 days after onset of chorea. Methemoglobin has usually formed by the first week after a hemorrhagic event (24). The presence of methemoglobin from recent petechial hemorrhage, with blood interspersed between brain tissue, could theoretically account for the increased intensity seen at admission on T1-weighted images and for the absence of marked signal alternation seen on T2-weighted and gradient-echo T2*-weighted sequences in patients. The sequential resolution of hyperintense signal on T1-weighted images and the sequential presence of increased hypointensity on T2-weighted and gradient-echo T2*-weighted se-

quences in the basal ganglia with continuous resolution of high density on CT scans also suggest evolution of petechial hemorrhage with hemosiderin deposition.

A review of the neuroimaging findings in patients with chorea associated with hyperglycemia in primary diabetes mellitus (4–15) shows that 11 patients had CT studies only (4–12). Among them, 8 had normal findings (4–9) and the other 3 had high attenuation in the basal ganglia (10–12). Three patients had both CT and MR studies (13–15). Of these, 2 had hyperdense basal ganglia on CT scans (4 and 7 days, respectively, after onset of chorea) and hyperintense signal on T1-weighted MR images (14 and 18 days, respectively, after onset) (13, 14). The third patient had normal CT findings with hyperintense signal on T1-weighted MR images (both studies performed 3 months after onset) (15). There were different schools of thought about the cause of the imaging abnormalities. In three reports of positive CT findings in which there were no MR examinations, basal ganglia calcification (10) and hemorrhage (11, 12) were suggested. Hemorrhage was also considered the cause of imaging abnormalities in two reports in which both MR and CT findings were positive (13, 14). In the article that reported normal CT findings in a patient with abnormal MR results, destroyed myelin in the basal ganglia was suggested as the cause of the high signal on T1-weighted images (15).

Among the 10 patients we studied, we believe the basal ganglia hemorrhage can explain the imaging findings in 9 cases. However, the MR imaging abnormalities in the one patient who had normal CT findings during the acute stage of chorea cannot be easily explained by basal ganglia hemorrhage. The abnormal MR signals may be the result of destroyed myelin. Release of lipids following a breakdown of the myelin sheath in some vascular and metabolic brain diseases can cause T1 and T2 shortening (30, 33, 34). However, we cannot exclude the possibility of the existence of some minute amount of blood that escaped detection by CT. Therefore, the imaging abnormalities may be attributed to petechial hemorrhage in the basal ganglia with some contribution of myelin destruction caused by the disease process.

We found that the locations of lesions shown on both MR images and CT scans correlated well with the initial presentation of the chorea (such as a right basal ganglia lesion with left

extremity chorea, bilateral lesions with bilateral chorea). In all our patients except one, hyperkinesia resolved dramatically after control of the hyperglycemia. This illustrates that acute chorea-ballismus caused by hyperglycemia is a treatable disorder with a good prognosis. Another interesting but important clinical finding is that all the patients reported in the literature, as well as the patients in our study, had primary diabetes mellitus. Indeed, even our four patients who had no history of diabetes were found to have primary diabetes mellitus during their hospitalization. It is possible for a patient with chorea-ballismus to have hyperglycemia at the initial presentation. The hyperglycemia could be the result of either primary or coincidental secondary diabetes mellitus stemming from any of a variety of diseases (16). A positive neuroimaging study should be an indication that the hyperglycemia is most likely due to underlying primary diabetes mellitus. The sequential neuroimaging findings in our patients also correlated well with the clinical course; however, resolution of the lesions on the imaging studies was slower than the clinical progress.

In conclusion, abnormal lesions in the basal ganglia display gradual resolution following treatment on follow-up CT and MR images. SPECT scans show hypoperfusion. Pathologic reports regarding chorea with hyperglycemia are scanty and inconclusive, since hyperglycemia is a treatable disease and most patients survive. However, our neuroimaging findings in this disease are noteworthy, and may shed light on the underlying pathophysiologic changes of this metabolic disorder.

References

1. Padberg GW, Bruyn GW. Chorea: differential diagnosis. In: Vinken PJ, Bruyn GW, Klawans HL, eds. *Handbook of Clinical Neurology*. Amsterdam, the Netherlands: Elsevier; 1986;49:549-564
2. Bedwell SF. Some observations on hemiballismus. *Neurology* 1960;10:619-622
3. Shannon KM. Hemiballismus. *Clin Neuropsychopharmacol* 1990;13:413-425
4. Rector WG, Herlong HF, Moses H. Nonketotic hyperglycemia appearing as choreoathetosis or ballism. *Arch Intern Med* 1982;142:154-155
5. Stone LA, Armstrong RM. An unusual presentation of diabetes: hyperglycemia induced hemiballismus. *Ann Neurol* 1989;26:164
6. Totoritis M, Cornish D, Thompson F. Nonketotic hyperglycemia. *Arch Intern Med* 1982;142:1405
7. Haan J, Kremer HPH, Padberg G. Paroxysmal choreoathetosis as presenting symptom of diabetes mellitus. *J Neurol Neurosurg Psychiatry* 1989;52:133
8. Lapidot T, Galun E. Hyperglycemia as a cause of chorea. *Arch Intern Med* 1989;149:1905
9. Linazasoro G, Urtasun M, Poza JJ, Suarez JA, Marti Masso JF. Generalized chorea induced by nonketotic hyperglycemia. *Mov Disord* 1993;8:119-120
10. Sanfield JA, Finkel J, Lewis S, Rosen SG. Alternating choreoathetosis associated with uncontrolled diabetes mellitus and basal ganglia calcification. *Diabetes Care* 1986;9:100-101
11. Srinivas K, Rao VM, Subbulakshmi N, Bhaskaran J. Hemiballismus after striatal hemorrhage. *Neurology* 1987;37:1428-1429
12. Sethi KD, Allen M, Sethi RK, McCord JW. Chorea in hypoglycemia and hyperglycemia. *Neurology* 1990;40(Suppl 1):337
13. Altafullah I, Pascual-Leone A, Duvall K, Anderson DC, Taylor S. Putaminal hemorrhage accompanied by hemichorea-hemiballismus. *Stroke* 1990;21:1093-1094
14. Nakagawa T, Mitani K, Nagura H, Bando M, Yamanouchi H. Chorea-ballismus associated with nonketotic hyperglycemia and presenting with bilateral hyperintensity of the putamen on MR T1-weighted images: a case report. *Rinsho Shinkeigaku* 1994;34:52-55
15. Nagai C, Kato T, Katagiri T, Sasaki H. Hyperintense putamen in T1-weighted MR images in a case of chorea with hyperglycemia. *AJNR Am J Neuroradiol* 1995;16:1243-1246
16. Foster DW. Diabetes mellitus. In: Wilson JD, Braunwald E, Isselbacher KJ, et al, eds. *Harrison's Principles of Internal Medicine*, 12th ed. New York, NY: McGraw-Hill; 1992;2:1739-1759
17. McCall AL. The impact of diabetes on the CNS. *Diabetes* 1992;41:557-570
18. Williamson JR, Kilo C, Tilton RG. Mechanisms of glucose- and diabetes-induced vascular dysfunction. In: Ruderman NB, Williamson JR, Brownlee M, eds. *Hyperglycemia, Diabetes, and Vascular Disease*. New York, NY: Oxford University Press; 1992:107-132
19. Guisado R, Arief AL. Neurological manifestations of diabetic coma: correlation with biochemical alterations in the brain. *Metabolism* 1975;24:665-679
20. Henkelman RM, Watts JF, Kucharczyk W. High signal intensity in MR images of calcified brain tissue. *Radiology* 1991;179:199-206
21. Maeder PP, Holtas SL, Basibuyuk LN, et al. Colloid cyst of the third ventricle: correlation of MR and CT findings with histology and chemical analysis. *AJNR Am J Neuroradiol* 1990;11:575-581
22. Boyko OB, Burger PC, Shelburne JD, Ingram P. Non-heme mechanisms for T1 shortening: pathologic, CT, MR elucidation. *AJNR Am J Neuroradiol* 1992;13:1439-1445
23. Abe K, Hasegawa H, Kobayashi Y, et al. A gemistocytic astrocytoma demonstrated high intensity on MR images: protein hydration layer. *Neuroradiology* 1990;32:166-167
24. Bradley WG. MR appearance of hemorrhage in the brain. *Radiology* 1993;189:15-26
25. Mihara F, Gupta KL, Murayama S, Lee N, Bond JB, Haik BG. MR imaging of malignant uveal melanoma: role of pulse sequence and contrast agent. *AJNR Am J Neuroradiol* 1991;12:991-996
26. Mirowitz SA, Westrich TJ, Hirsch JD. Hyperintense basal ganglia on T1-weighted MR images in patients receiving parenteral nutrition. *Radiology* 1991;181:117-120
27. Araki Y, Ootani M, Furukawa T, et al. High field MR imaging of the brain in Wilson's disease: new MR findings. *Jpn J Clin Radiol* 1991;36:317-321
28. Inoue E, Hori S, Narumi Y, et al. Portal-systemic encephalopathy: presence of basal ganglia lesions with high signal intensity on MR images. *Radiology* 1991;179:551-555

29. Mirowitz SA, Sartor K, Gado M. High-intensity basal ganglia lesions on T1-weighted MR images in neurofibromatosis. *AJNR Am J Neuroradiol* 1989;10:1159-1163
30. Barkovich AJ. MR and CT evaluation of profound neonatal and infantile asphyxia. *AJNR Am J Neuroradiol* 1992;13:959-972
31. Midroni G, Willinsky R. Rapid postanoxic calcification of the basal ganglia. *Neurology* 1992;42:2144-2146
32. Triulzi F. Cerebral hemorrhage: CT and MR. *Riv Neuroradiol* 1990;3(Suppl 2):39-44
33. Koenig SH. Cholesterol of myelin in the determinant of gray-white contrast in MRI of brain. *Magn Reson Med* 1991;20:285-291
34. Ho VB, Fitz CR, Yoder CC, Geyer CA. Resolving MR features in osmotic myelinolysis (central pontine and extrapontine myelinolysis). *AJNR Am J Neuroradiol* 1993;14:163-167