

Are your **MRI contrast agents** cost-effective?

Learn more about generic **Gadolinium-Based Contrast Agents**.



FRESENIUS
KABI

caring for life

AJNR

Specificity of MR angiography as a confirmatory test of carotid artery stenosis.

D F Kallmes, R A Omary, J E Dix, A J Evans and B J Hillman

AJNR Am J Neuroradiol 1996, 17 (8) 1501-1506

<http://www.ajnr.org/content/17/8/1501>

This information is current as
of April 19, 2024.

Specificity of MR Angiography as a Confirmatory Test of Carotid Artery Stenosis

D. F. Kallmes, R. A. Omary, J. E. Dix, A. J. Evans, and B. J. Hillman

PURPOSE: To estimate from available literature the specificity (true-negative rate) of MR angiography for detecting severe carotid artery stenoses when applied as a confirmatory test after screening with duplex Doppler sonography. **METHODS:** We reviewed the pertinent MR angiographic literature published between 1990 and 1994 and recalculated the specificity of MR angiography after deleting from the database results for normal vessels and for vessels with mild and moderate stenoses, since the study of these vessels is not germane to an exploration of the utility of MR angiography as a confirmatory test. **RESULTS:** Seventeen articles provided data for our analysis. We divided vessels into four categories on the basis of data supplied within each article. Seven of the articles provided data that could be configured to match the categories used in the North American Symptomatic Carotid Endarterectomy Trial (NASCET). In one study, the criterion of severe stenosis was more than 70% constriction, but the moderate category was limited to stenoses of 50% to 69%. The remaining series defined severe stenoses as more than 80% (four series), more than 75% (two series), or more than 60% (three series) constriction. The stated specificity of MR angiography ranged from 64% to 100%. Before revision, 15 of 17 articles had stated specificity values above 75%. Our recalculated values ranged from 18% to 100%. Only seven of 17 studies would have had MR angiographic specificity of greater than 75%. Nine of 17 articles would have had specificities of less than 60%. For all articles specifically identifying vessels with false-positive findings at sonography, the specificity of MR angiography was 16%. **CONCLUSION:** To base specificity values for MR angiography as a confirmatory test of carotid artery stenosis on studies that include nondiseased vessels incurs spectrum bias. The actual specificity for MR angiography as a confirmatory test remains unknown, but it is lower than that reported in the literature.

Index terms: Arteries, magnetic resonance; Efficacy studies; Magnetic resonance angiography

AJNR Am J Neuroradiol 17:1501-1506, September 1996

Magnetic resonance (MR) angiography has been proposed as an alternative to conventional catheter angiography to confirm the diagnosis of severe carotid artery stenoses as determined by means of duplex Doppler sonography and to guide decisions regarding the need for carotid endarterectomy (1-3). However, these studies included a high proportion of severely stenosed vessels; consequently, they did not convincingly address the ability of MR angiography to show vessels incorrectly identified as severely

stenosed at sonography. This function is critical to the role of a confirmatory test. Thus, for a confirmatory test, the standard of measurement is specificity, or the true-negative rate.

Specificities cited for MR angiography approximate 90%, supporting a confirmatory role for MR angiography (1, 4). However, these reported specificity values are based on studies that included contralateral, nondiseased vessels. When MR angiography is used as a confirmatory test for vessels identified as positive for disease by sonography, at issue is the value of MR angiography in correctly showing vessels that were misdiagnosed at sonography. Thus, specificity calculations for MR angiography should be based only on vessels falsely identified as positive at sonography. Contralateral carotid arteries should not be included in specific-

Received November 8, 1995; accepted after revision March 1, 1996.

From the Department of Radiology, University of Virginia Health Sciences Center, Charlottesville, VA 22901. Address reprint requests to D. F. Kallmes, MD.

AJNR 17:1501-1506, Sep 1996 0195-6108/96/1708-1501

© American Society of Neuroradiology

ity calculations when assessing MR angiography as a confirmatory test unless the contralateral vessel also was diagnosed as severely stenosed at sonography. Inclusion of nondiseased, contralateral vessels, easily identified as normal on MR angiograms but not representative of vessels that will be addressed by MR angiography as a confirmatory test, leads to spectrum bias and inappropriately optimistic results (5–8).

In this study, we surveyed the available literature to estimate the specificity of MR angiography when used as a confirmatory test after sonographic examination, with particular attention to possible spectrum bias introduced by inclusion of contralateral, nondiseased vessels.

Materials and Methods

Identification of MR Angiographic Literature. We searched the Medline database for English-language articles published between 1990 and 1994 by using the index terms *carotid artery*; *carotid artery, stenosis*; *carotid arteries, MR*; and *carotid arteries, sonography*. Additional articles referenced in the articles identified in Medline were also included. Twenty-eight articles were identified (1–3, 9–28, 30–34), 20 via the Medline search and eight via references found in the other articles.

Definition of Normal and Stenosed Vessels. Calculations of specificity required that we define a discrete cutpoint between positive and negative sonographic results and MR angiographic results. We focused on a cutpoint between moderate and severe stenosis, because the North American Symptomatic Carotid Endarterectomy Trial (NASCET) showed a definite benefit of carotid endarterectomy for stenosis greater than 70% (40). Because of the diverse definitions of stenosis found among articles, four categories of stenosis were defined: normal vessels and vessels with mild, moderate, and severe stenoses. Seven of the articles (9, 10, 16, 19, 22, 26, 33) provided data that could be configured to match the categories used in NASCET. One article used more than 70% constriction as a definition of severe stenosis, but limited its moderate category to 50% to 69% stenoses (27). The remaining series defined severe stenoses as more than 80% (11, 15, 17, 18), more than 75% (2, 21), or more than 60% (12, 14, 37) constriction. We considered the term *severe stenosis* to represent a “positive” or diseased vessel; the terms *normal vessel* or *mild* or *moderate stenosis* were considered to represent a “negative” or nondiseased vessel, since such a vessel is not one for which a patient would undergo endarterectomy.

Recalculation of Specificity Values. Several authors have suggested the use of MR angiography in lieu of conventional angiography to confirm a positive sonographic result (1–3). Thus, the pertinent measurement is the true-negative rate of MR angiography, not for all vessels but for

a population limited to vessels identified as positive for disease at sonography. Published reports of MR angiography include in their population of vessels not only sonographically positive arteries but also contralateral, sonographically negative arteries. Compared with sonographically positive vessels, these contralateral, sonographically negative vessels are identified relatively easily as negative at MR angiography, resulting in overestimation of the specificity of MR angiography.

Fortunately, even though most MR angiography series do not distinguish between ipsilateral, sonographically positive and contralateral, sonographically negative vessels, they do offer data for multiple categories of stenosis (ie, normal, mild, moderate, severe). Any group of vessels that would be highly unlikely to be erroneously identified as positive at sonography could be removed from the MR angiography database. This would allow the removal of some contralateral vessels with resultant partial correction of specificity.

In this regard, we removed vessels in the normal and mild stenosis category from the MR angiography database, since it is highly unlikely that these vessels would be erroneously referred to as positive at sonography performed to confirm the results of MR angiography. We substantiate this view by noting that in pooled data from nine sonography series (5, 10, 15, 16, 29, 35–39), only 18 (2%) of 772 normal vessels and mild stenoses were misclassified at sonography as severe stenoses. Furthermore, Dawson et al (36) noted that, sonographically, vessels were almost never miscategorized by more than a single severity category.

As a result, our revised specificity values are based entirely on the vessels in the moderate stenosis category. Note that even these revised specificity values represent overestimations of confirmatory MR angiographic specificity, because within the moderate stenosis category there are three types of vessel. The first group includes vessels that are overestimated as severe at sonography (false-positive sonographic findings), which are the precise vessels upon which confirmatory MR angiographic specificity values should be based. These would be skewed toward the upper end of the moderate category, since they have already been overestimated at sonography as severe. As such, they represent the most challenging vessels to identify as negative at confirmatory MR angiography (ie, low specificity). The second group includes contralateral moderate stenoses accurately identified as negative by sonography. The third group consists of unexamined moderate stenoses from series that do not state explicitly whether screening sonography was performed. Inadvertent inclusion of these latter two types of moderate stenoses cause overestimation of MR angiographic specificity, since, compared with false-positive sonographic findings, they are relatively easily identified as negative at MR angiography.

Exclusionary Criteria for Articles. Two reviewers independently analyzed the methods used in the MR angiographic series reported in the literature. Articles were excluded from further review if (a) the results of MR angiography were not compared with conventional film-

Number of findings underestimated, correctly estimated, and overestimated with MR angiography in 17 studies

Author	Normal Findings at Conventional Angiography			Mild Findings at Conventional Angiography				Moderate Findings at Conventional Angiography			Calculated Specificity,* %	Revised Specificity,* %
	Findings at MR Angiography			Findings at MR Angiography				Findings at MR Angiography				
	Normal	Mild	Moderate	Normal	Mild	Moderate	Severe	Mild	Moderate	Severe		
Pavone (22)	5	4	...	2	18	6	8	2	96	80
Litt (18)	5	2	1	2	14	3	8	11	76	42
DeMarco (11)	11	6	2	5	3	7	79	30
Heiserman (21)	30	5	...	7	7	1	...	1	4	4	93	56
Young (33)	32	7	...	11	13	3	95	89
Huston (17)	23	4	3	1	6	15	3	14	80	18
Blatter (19)	38	4	...	4	4	7	88	53
Riles (15)	1	5	10	6	3	...	6	19	62	24
Anson (2)	2	1	6	4	3	82	57
Masaryk (26)	16	6	12	2	94	90
Mittl (16)	17	2	...	2	10	13	70	48
Turnipseed (10)	4	0	2	6	...	100	100
Pan (9)	5	11	16	...	6	7	2	96	87
Spartera (12)	30	4	3	2	9	5	91	69
Chiesa (14)	30	1	...	3	22	8	88	76
White (34)	27	12	3	2	7	6	2	7	3	7	91	59
Laster (27)	114	4	...	1	15	4	97	80

* Calculated specificity is based on all vessels (both ipsilateral and contralateral) included in study cited; revised specificity includes only moderately stenosed vessels.

screen or selective digital subtraction angiography (the generally accepted standard) (1, 13); (b) the test results could not be entered into a contingency table, based on degree of stenosis, for determination of specificity (20, 30); (c) the method of measuring stenosis was not specified (13, 28); (d) fewer than 20 patients were included in the study (24, 25, 31); or (e) there was no distinction made between normal vessels and mild and moderate stenoses (making it impossible to apply our assumptions and calculate revised specificity) (3, 23, 32). Discrepancies between the two reviewers regarding inclusion of articles were arbitrated by a third reviewer. The concordance rate between the two primary reviewers for article inclusion was 86% (24 of 28 articles). Eleven of 28 articles were excluded.

Results

Of the articles reviewed, five series enrolled patients on the basis of a positive sonographic result (10, 14, 17, 22, 33); one series enrolled patients after screening with sonography or MR angiography (34); nine series enrolled patients on the basis of availability of both MR angiography and conventional angiography (9, 11, 12, 16, 18, 19, 21, 26, 27); one series enrolled patients prospectively on the basis of anticipated need for carotid endarterectomy (2); and one series enrolled patients who had undergone

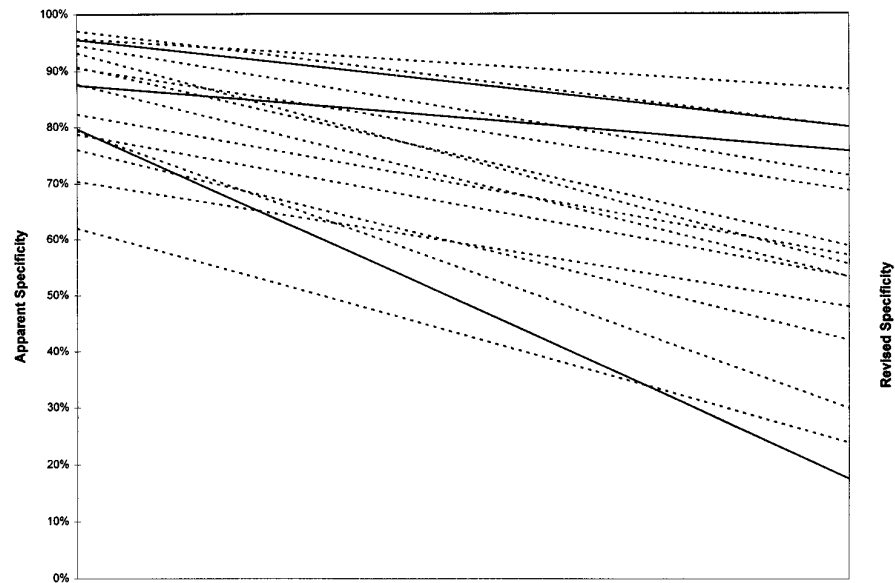
sonography, conventional angiography, and MR angiography (15). All series included both carotid arteries from each patient in their results.

A summary contingency table is presented in the Table, which details the performance of MR angiography, where the standard of reference is considered to be conventional (catheter) angiography. Figure 1 shows the relative specificities of the various studies, both before and after revision.

The stated specificity of MR angiography ranged from 64% to 100%. Before revision, 15 of 17 articles had stated specificity values above 75%. After eliminating normal and mildly stenotic vessels to estimate the actual specificity of MR angiography as a confirmatory test, the specificity ranged from 18% to 100%. The value of 100% was derived from a study detailing eight moderate stenoses. Following revision, seven of 17 studies had MR angiographic specificities of greater than 75% when MR angiography was used as a confirmatory test, and only four of these studies had specificities greater than 80%. Nine of 17 articles had specificities of less than 60%.

The mean specificity for MR angiography including all negative vessels ($86.9\% \pm 10.6\%$)

Fig 1. Relative specificities of the various studies before and after revision. The *solid lines* represent studies that specifically stated that all enrolled patients had undergone previous imaging examinations; the *dashed lines* represent all other studies. Values along the left portion of the figure represent specificity values based on all negative vessels; values along the right portion represent specificity values based only on moderately stenosed vessels.



was significantly higher than the mean revised specificity ($62.2\% \pm 24.5\%$) ($P < .0001$).

Discussion

This study addresses the expected specificity for MR angiography as a confirmatory test for a positive sonographic examination based on a review of available literature. Our results suggest that the specificity of MR angiography is relatively poor for a population of vessels screened as positive for disease by sonography, calling into question the practice of recommending carotid endarterectomy on the basis of concordant positive findings at sonography and MR angiography.

Other investigators have estimated the specificity of confirmatory MR angiography to be as high as 90% (1, 4). The studies reporting these specificities included both carotid arteries from each patient in their calculations, whether the vessels had been diagnosed as diseased or not. Contralateral vessels determined to be negative at sonography have a spectrum of findings that makes them easy to identify as negative by the confirmatory MR angiogram, thus falsely improving apparent specificity. Moreover, the confirmatory MR angiogram is obtained to assure that vessels diagnosed at sonography as positive are actually severely stenosed. An MR angiographic result for a contralateral vessel that had been diagnosed as normal by sonography has little clinical relevance.

Some of the studies included in our analysis,

especially those that enrolled patients on the basis of availability of both MR angiography and conventional angiography, may not have intended to address the use of MR angiography as a confirmatory test. The goals of their research were different from ours. We do not imply that those authors erred when including both vessels in specificity calculations. However, these studies are being cited inappropriately as supportive of a confirmatory role for MR angiography.

The ideal method for calculating specificity of MR angiography as a secondary test would have been to focus on false-positive sonographic results. This computation was impossible for most of the articles we reviewed. Only three of the 17 articles offered data regarding MR angiographic findings specifically for false-positive sonographic results. Mittl et al (16) reported seven false-positive vessels by sonography, all of which were also overestimated at MR angiography. Riles et al (15) reported 11 false-positive vessels by sonography, all of which were also overestimated on MR angiography. Mattle et al (32) reported three false-positive vessels by sonography that were correctly identified as negative at MR angiography. Thus, in support of our analysis of the larger population of vessels we reviewed, of 21 definite false-positive sonographic cases reported in the literature, MR angiographic findings led to overestimation of 18 vessels as severely stenosed (specificity, 16%).

It might be argued that we inappropriately included some studies in our analysis, since studies enrolling patients on the basis of avail-

ability of MR angiography and conventional angiography did not necessarily include patients who had been examined with sonography. However, false-positive sonographic findings represent the most challenging vessels for investigators to identify as negative by MR angiography, since these stenoses have already been overestimated at sonography. Unexamined moderate stenoses would be more likely than false-positive sonographic findings to be correctly diagnosed as negative at MR angiography. As such, inclusion of any unexamined moderate stenoses would have falsely elevated our revised specificity values.

Calculation of specificity required the definition of a discrete cutpoint, above which test results were considered positive and below which test results were considered negative. This practice is not easily applied to carotid atherosclerosis, since there is a continuum of possible stenoses. Our methods are based on NASCET results reported to date, which are limited to severe stenoses. Until NASCET data regarding moderate stenoses are available, the distinction between moderate and severe stenoses remains critical.

One of the basic assumptions in this analysis was that conventional angiography represents the standard of reference. This assumption is arguable, since there is significant interobserver variability in interpreting the findings of conventional angiography. Furthermore, a stenosis that was not round in the axial plane would tend to be underestimated by projection angiography, unless the projections obtained were perfectly tangential to the narrowest span of the stenosis (41, 42). It is possible that in some vessels designated as false-positive for stenosis at MR angiography, there actually was a severe stenosis missed by conventional angiography. The impact of this limitation is difficult to define. The standard of evidence is a recurring problem in the assessment of diagnostic technologies for which there currently is not an acceptable solution. As noted above, the thrust of our analysis was not to determine the actual accuracy of MR angiography but to identify a source of bias that limits applicability of current MR angiographic research.

We did not aim to question the use of MR angiography in general for evaluating the carotid arteries. Our focus was narrow: to call into question the current practice of using MR angiography to confirm positive sonographic re-

sults. Carotid MR angiography has other potential value, including its use in determining the level of a carotid stenosis and, possibly, in uncovering tandem lesions.

Research to date has not appropriately defined the value of using MR angiography to confirm a positive sonographic finding of carotid atherosclerotic disease. Specificities based on contralateral or unexamined vessels cannot be applied to an examined population of vessels. Future research should distinguish between ipsilateral and contralateral vessels for any examined population to allow appropriate calculations of specificity.

References

1. Polak JE, Kalina P, Donaldson MC, O'Leary DH, Whitemore AD, Mannick JA. Carotid endarterectomy: preoperative evaluation of candidates with combined Doppler sonography and MR angiography. *Radiology* 1993;186:333-338
2. Anson JA, Heiserman JE, Drayer BP, Spetzler RF. Surgical decisions on the basis of magnetic resonance angiography of the carotid arteries. *Neurosurgery* 1993;32:335-343
3. Lustgarten JH, Solomon RA, Quest DO, Khanji AG, Mohr JP. Carotid endarterectomy after noninvasive evaluation by duplex ultrasonography and magnetic resonance angiography. *Neurosurgery* 1994;34:612-619
4. Polak JF. Noninvasive carotid evaluation: carpe diem. *Radiology* 1993;186:329-331
5. Polak JF, Dobkin GR, O'Leary DH, Wang AM, Cutler SS. Internal carotid artery stenosis: accuracy and reproducibility of color-Doppler-assisted duplex imaging. *Radiology* 1989;173:793-798
6. Begg CB. Biases in the assessment of diagnostic tests. *Stat Med* 1987;6:411-423
7. Ransohoff DF, Feinstein AR. Problems of spectrum and bias in evaluating the efficacy of diagnostic tests. *N Engl J Med* 1978;299:926-930
8. Rozanski A, Diamond GA, Berman D, Forrester JS, Morris D, Swan HJC. The declining specificity of exercise radionuclide ventriculography. *N Engl J Med* 1983;309:518-522
9. Pan XM, Anderson CM, Reilly LM, et al. Magnetic resonance angiography of the carotid artery combining two- and three-dimensional acquisitions. *J Vasc Surg* 1992;16:609-618
10. Turnipseed WD, Kennell TW, Turski PA, Acher WD, Hoch JR. Combined use of duplex imaging and magnetic resonance angiography for evaluation of patients with symptomatic ipsilateral high-grade stenosis. *J Vasc Surg* 1993;17:832-840
11. DeMarco JK, Nesbit GM, Wesbey GE, Richardson D. Prospective evaluation of extracranial carotid stenosis: MR angiography with maximum-intensity projections and multiplanar reformation compared with conventional angiography. *AJR Am J Roentgenol* 1994;163:1205-1212
12. Spartera C, Morettini G, Marino G, et al. Detection of internal carotid artery stenosis: comparison of 2D-MR angiography, duplex scanning, and arteriography. *J Cardiovasc Surg* 1993;34:209-213
13. Kido DK, Panzer RJ, Szumowski J, et al. Clinical evaluation of stenosis of the carotid bifurcation with magnetic resonance angiography techniques. *Arch Neurol* 1991;48:484-489

14. Chiesa R, Melissano G, Casettano R, et al. Three dimensional time-of-flight magnetic resonance angiography in carotid artery surgery: a comparison with digital subtraction angiography. *Eur J Vasc Surg* 1993;7:171-176
15. Riles TS, Eidelman EM, Litt AW, Pinto RS, Oldford F, Thoe Schwartzberg GWS. Comparison of magnetic resonance angiography, conventional angiography, and duplex scanning. *Stroke* 1992;23:341-346
16. Mittl RL, Broderick J, Carpenter JP, et al. Blinded-reader comparison of magnetic resonance angiography and duplex ultrasonography for carotid artery bifurcation stenosis. *Stroke* 1994;25:4-10
17. Huston J, Lewis BD, Wiebers DO, Meyer FB, Reiderer SJ, Weaver AL. Carotid artery: prospective blinded comparison of two-dimensional time-of-flight MR angiography with conventional angiography and duplex US. *Radiology* 1993;186:339-344
18. Litt AW, Eidelman EM, Pinto RS, et al. Diagnosis of carotid artery stenosis: comparison of 2DFT time-of flight MR angiography with contrast angiography in 50 patients. *AJNR Am J Neuroradiol* 1991;12:149-154
19. Blatter DD, Bahr AL, Parker DL, et al. Cervical carotid MR angiography with multiple overlapping thin-slab acquisition: comparison with conventional angiography. *AJR Am J Roentgenol* 1993;161:1269-1277
20. Anderson CM, Lee RE, Levin DL, de la Torre Alonso S, Saloner D. Measurement of internal carotid artery stenosis from source MR angiograms. *Radiology* 1994;193:219-226
21. Heiserman JE, Drayer BP, Fram EK, et al. Carotid artery stenosis: clinical efficacy of two-dimensional time-of-flight MR angiography. *Radiology* 1992;182:761-768
22. Pavone P, Marsili L, Catalano C, et al. Carotid arteries: evaluation with low-field-strength MR angiography. *Radiology* 1992;184:401-404
23. Polak JF, Bajakian RL, O'Leary DH, Anderson MR, Donaldson MC, Jolesz FA. Detection of internal carotid artery stenosis: comparison of MR angiography, color Doppler sonography, and arteriography. *Radiology* 1992;182:35-40
24. Furuya Y, Isoda H, Hasegawa S, Takahashi M, Kaneko M, Uemura M. Magnetic resonance angiography of extracranial carotid and vertebral arteries, including their origins: comparison with digital subtraction angiography. *Neuroradiology* 1992;35:42-45
25. Kido DK, Barsotti JB, Rice LZ, et al. Evaluation of the carotid artery bifurcation: comparison of magnetic resonance angiography and digital subtraction arch aortography. *Neuroradiology* 1991;33:48-51
26. Masaryk AM, Ross JS, DiCello MC, Modic MT, Paranandi L, Masaryk TJ. 3DFT MR angiography of the carotid bifurcation: potential and limitations as a screening examination. *Radiology* 1991;179:797-804
27. Laster RE, Acker JD, Halford HH, et al. Assessment of MR angiography versus arteriography for evaluation of cervical carotid bifurcation disease. *AJNR Am J Neuroradiol* 1993;14:681-688
28. Wesbey GE, Bergan JJ, Morland SI, et al. Cerebrovascular magnetic resonance angiography: a critical evaluation. *J Vasc Surg* 1992;16:619-632
29. Ballard JL, Fleig K, De Lange M, Killeen JD. The diagnostic accuracy of duplex ultrasonography for evaluating carotid bifurcation. *Am J Surg* 1994;168:123-126
30. Sitzer M, Furst G, Fischer H, et al. Between-method correlation in quantifying internal carotid stenosis. *Stroke* 1993;24:1513-1518
31. Wilkerson DK, Keller I, Mezrich R, et al. The comparative evaluation of three-dimensional magnetic resonance for carotid artery disease. *J Vasc Surg* 1991;14:803-811
32. Mattle HP, Kent KC, Edelman RR, Atkinson DJ, Skillman JJ. Evaluation of the extracranial carotid arteries: correlation of magnetic resonance angiography, duplex ultrasonography, and conventional angiography. *J Vasc Surg* 1991;13:838-845
33. Young GR, Humphrey PRD, Shaw MDM, Nixon TE, Smith ETS. Comparison of magnetic resonance angiography, duplex ultrasound, and digital subtraction angiography in assessment of extracranial internal carotid artery stenosis. *J Neurol Neurosurg Psychiatry* 1994;57:1466-1478
34. White JS, Russell WL, Greer MS, Whittle MT. Efficacy of screening MR angiography and Doppler ultrasonography in the evaluation of carotid artery stenosis. *Am Surg* 1994;60:341-348
35. Poindexter JM, Shah PM, Clauss RH, Babu SC. The clinical utility of carotid duplex scanning. *J Cardiovasc Surg* 1991;32:64-68
36. Dawson DL, Zierler RE, Kohler TR. Role of arteriography in the preoperative evaluation of carotid artery disease. *Am J Surg* 1991;161:619-624
37. Jacobs NM, Grant EG, Schellinger D, Byrd MC, Richardson JD, Cohan SL. Duplex carotid sonography: criteria for stenosis, accuracy, and pitfalls. *Radiology* 1985;154:385-391
38. Steinke W, Kloetzsch C, Hennerici M. Carotid artery disease assessed by color Doppler flow imaging: correlation with standard Doppler sonography and angiography. *AJNR Am J Neuroradiol* 1990;11:259-266
39. Robinson ML, Sacks D, Perlmutter GS, Marinelli DL. Diagnostic criteria for carotid duplex sonography. *AJR Am J Roentgenol* 1991;151:1045-1049
40. North American Symptomatic Carotid Endarterectomy Trial Collaborators. Beneficial effect of carotid endarterectomy in symptomatic patients with high-grade stenoses. *N Engl J Med* 1991;325:445-453
41. Alexandrov AV, Bladin CF, Maggisano R, Norris JW. Measuring carotid stenosis: time for a reappraisal. *Stroke* 1993;24:1292-1296
42. Toole JF, Castaldo JE. Accurate measurement of carotid stenosis: chaos in methodology. *J Neuroimaging* 1994;4:222-230