

Are your **MRI contrast agents** cost-effective?

Learn more about generic **Gadolinium-Based Contrast Agents**.



FRESENIUS  
KABI

caring for life

**AJNR**

**Hydroxyapatite cement to repair skull base defects: radiologic appearance.**

J L Weissman, C H Snyderman and B E Hirsch

*AJNR Am J Neuroradiol* 1996, 17 (8) 1569-1574

<http://www.ajnr.org/content/17/8/1569>

This information is current as  
of April 20, 2024.

# Hydroxyapatite Cement to Repair Skull Base Defects: Radiologic Appearance

Jane L. Weissman, Carl H. Snyderman, and Barry E. Hirsch

**PURPOSE:** To describe the radiologic appearance of hydroxyapatite cement (HAC), which, when mixed with liquid, forms a paste that can be contoured to osseous defects and, over time, becomes "osseointegrated" (native bone grows into the pores of the HAC and forms a strong chemical bond with the substance). **METHODS:** Between March 1992 and June 1993, 24 adults (16 men, eight women) underwent skull base surgery that included reconstruction or closure with HAC. Fourteen patients had HAC placed in the paranasal sinuses or facial bones, and 10 had HAC placed in the mastoid cavity. **RESULTS:** HAC is homogeneously radiopaque on CT scans and plain radiographs. Large amounts (ablating a frontal sinus or mastoid air cells) are readily seen; small amounts are inconspicuous. On MR images, HAC is a signal void. Infected HAC in one patient was surrounded by enhancing soft tissue on MR images, separated from native bone by an irregular radiolucent cleft on CT scans. **CONCLUSIONS:** HAC is a valuable addition to the surgical armamentarium for the repair of skull base defects. More experience will determine the time course for normal osseointegration, as well as the typical appearance of infection.

**Index terms:** Skull, base; Skull, surgery; Surgery, reconstructive

*AJNR Am J Neuroradiol* 17:1569-1574, September 1996

Most of the human skeleton is made of calcium phosphate in the form of hydroxyapatite (1). Synthetic hydroxyapatite is a strong, brittle, biocompatible ceramic. Its strength makes it useful for augmenting bone (2), but hydroxyapatite blocks are not easily sculpted (2, 3). Non-ceramic hydroxyapatite cement (HAC) can be mixed with liquid to form a paste. Unlike ceramic hydroxyapatite blocks, HAC paste can be precisely molded and contoured to fill osseous defects. Osseointegration occurs with time, as native bone grows into the HAC.

HAC was used to reconstruct or seal defects of the skull base and facial bones in 24 patients at our institution. The normal and abnormal appearance of HAC on plain radiographs, com-

puted tomographic (CT) scans, and magnetic resonance (MR) images are presented here.

## Materials and Methods

Between March 1992 and June 1993, 24 adults underwent surgical procedures involving the paranasal sinuses, anterior skull base, or temporal bone for which wound closure and reconstruction included the use of HAC. In this investigational capacity, use of HAC was approved by the Food and Drug Administration (4) and the Institutional Review Board of our medical center.

The study group included 16 men and eight women, ranging in age from 27 to 72 years at the time of surgery. Five patients had benign or malignant neoplasms arising from the paranasal sinuses or requiring a paranasal sinus approach for tumor access (meningioma, chordoma); seven had nonneoplastic diseases of the paranasal sinuses (infection, mucocele, polyposis); two had sustained facial trauma; and 10 had undergone temporal bone surgery (acoustic neuroma, cholesteatoma, Meniere disease, cerebrospinal fluid otorrhea) (see Table).

Postoperative imaging was performed in accordance with investigational protocol. However, many patients lived far away and had subsequent studies performed at other facilities; these studies were not available for retrospective review. The following studies were available to us: postoperative CT scans of 15 patients, postoperative MR studies of five patients (all but one of whom had also had

---

Received December 26, 1995; accepted after revision March 25, 1996.  
Presented in part at the annual meeting of the American Society of Head and Neck Radiology, Pittsburgh, Pa, May 1995.

From the Departments of Radiology (J.L.W.) and Otolaryngology (J.L.W., C.H.S., B.E.H.), University of Pittsburgh (Pa) Medical Center.

Address reprint requests to Jane L. Weissman, MD, University of Pittsburgh Medical Center, Department of Radiology, Room D-132 PUH, 200 Lothrop St, Pittsburgh, PA 15213.

AJNR 17:1569-1574, Sep 1996 0195-6108/96/1708-1569

© American Society of Neuroradiology

**Twenty-four patients in whom hydroxyapatite cement was placed during surgery to repair skull base defects**

Patient	Sex	Diagnosis	Location of Hydroxyapatite Cement
1	F	Adenoid cystic carcinoma of maxillary sinus	Temporalis fossa
2	M	Squamous cell carcinoma of maxillary sinus and nasal cavity	Frontal sinus
3	M	Frontal fractures	Frontal sinus
4	M	Frontal sinus mucocele	Frontal sinus
5	M	Acoustic neuroma	Mastoid cavity
6	M	Meningioma of infratemporal fossa and orbit	Ethmoidal sinus
7	M	Frontal fractures	Frontal sinus
8	F	Acoustic neuroma	Mastoid cavity
9	F	Paranasal sinus polyposis	Frontal sinus
10	M	Cerebrospinal fluid leak after acoustic neuroma	Mastoid cavity
11	M	Frontal osteomyelitis	Frontal sinus
12	F	Subperiosteal, frontal, and ethmoidal infection	Frontal sinus
13	F	Frontal sinusitis	Frontal sinus
14	F	Acoustic neuroma	Mastoid cavity
15	M	Frontal sinusitis after frontal craniotomy	Frontal sinus
16	M	Acoustic neuroma	Mastoid cavity
17	M	Acoustic neuroma	Mastoid cavity
18	M	Cerebrospinal fluid leak after acoustic neuroma	Mastoid cavity
19	M	Squamous cell carcinoma of frontal sinus and orbital cavity	Frontal sinus
20	M	Acoustic neuroma	Mastoid cavity
21	F	Chordoma	Orbitoethmoidal sinus
22	M	Ethmoidal mucoceles	Frontal sinus
23	F	Meniere disease	Mastoid cavity
24	M	Cerebrospinal fluid leak after cholesteatoma	Mastoid cavity

CT scans), and plain radiographs of 13 patients (all but three of whom had had CT or MR studies or both). The intervals between surgery and radiologic studies available for this investigation varied from 1 day to 2 years. All CT studies included bone and soft-tissue algorithms. All MR studies included spin-echo T1-weighted sequences and either conventional or fast spin-echo T2-weighted sequences.

**Results**

*Appearance*

On plain radiographs and CT scans, HAC is densely radiopaque (Figs 1–6). On all MR pulse sequences used, HAC is a signal void (Figs 4C and 5B) that does not enhance after administration of contrast material. The largest amounts of HAC were used to obliterate the frontal sinuses (Figs 1–3) and mastoid cavities after the air cells were removed (Figs 5 and 6). Small amounts of HAC, such as the thin layer applied to repair a mastoid tegmen defect, are quite subtle, and may be indistinguishable from native bone, even on CT scans (Fig 6). An intermediate amount of HAC sealed a sinus ostium (Fig 4).

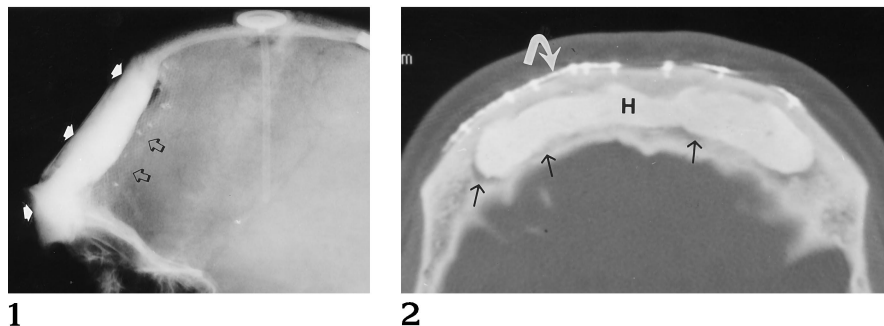
In one patient with a pronounced defect from a prior frontal craniotomy, HAC was augmented with titanium mesh (Fig 1). HAC was also used to reattach native bone after an osteotomy (Fig 3A and B).

On CT scans, HAC is much more easily identified on bone algorithms (Fig 4A) than on soft-tissue algorithms (Fig 4B). On tissue algorithms, HAC may be indistinguishable from native bone or, in the immediate postoperative period, blood.

On MR images, HAC exhibits a signal void identical to the signal void of cortical bone and air (Figs 4C and 5B). The normal interface be-

Fig 1. Patient 11 (HAC in frontal defects). Lateral plain radiograph shows homogeneously radiopaque HAC filling a large frontal defect (*white arrows*). The HAC is augmented by a faintly opaque titanium mesh (*black arrows*).

Fig 2. Patient 22 (HAC in frontal defects). Axial CT scan (bone algorithm) shows the frontal sinus completely filled with HAC (*H*). A thin radiolucent cleft separates HAC from native bone (*black arrows*). During surgery, the anterior table of the sinus was removed then replaced and held in place with plates (*curved arrow*).



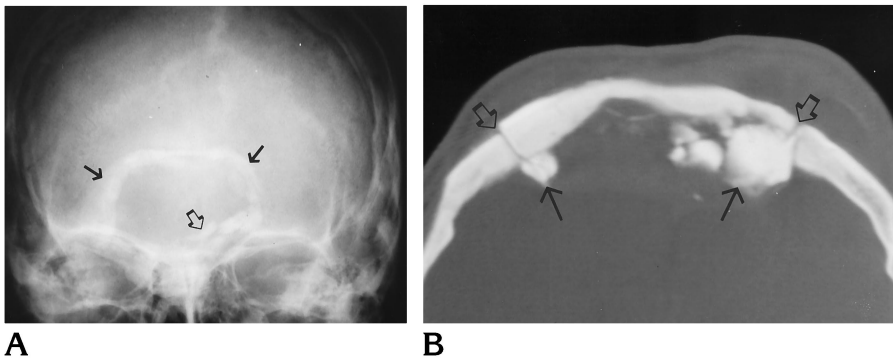


Fig 3. Patient 4 (HAC in frontal defects).

A, Frontal plain radiograph shows a rim of HAC surrounding the frontal osteotomy (solid arrows). The HAC was used as cement to hold the bone in place, and in some places it extruded beyond the osteotomy (open arrow).

B, Axial CT scan (bone algorithm) shows the HAC (solid arrows) extruding beyond the margins of the osteotomy (open arrows).

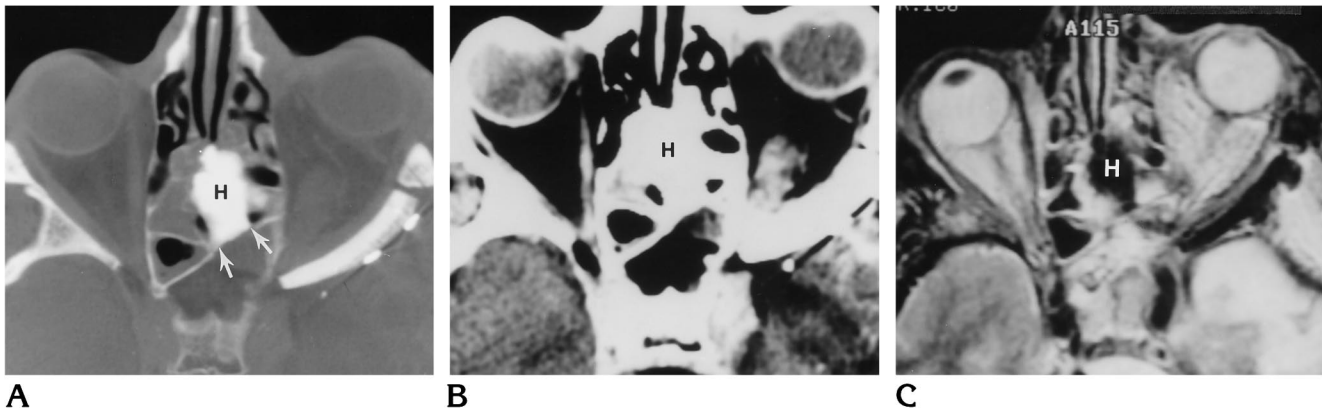

Fig 4. Patient 6 (HAC sealing the ostium of the sphenoidal sinus).

A, Axial CT scan (bone algorithm) shows amorphous HAC (H) in the upper nasal cavity and posterior ethmoidal sinus, occluding the ostium of the sphenoidal sinus (arrows).

B, On the corresponding soft-tissue algorithm, the HAC (H) could be mistaken for native bone or blood.

C, Axial fast spin-echo T2-weighted (4000/80 [repetition time/echo time]) MR image shows the signal void of the HAC (H). Without the CT study, this could easily be misinterpreted as air.

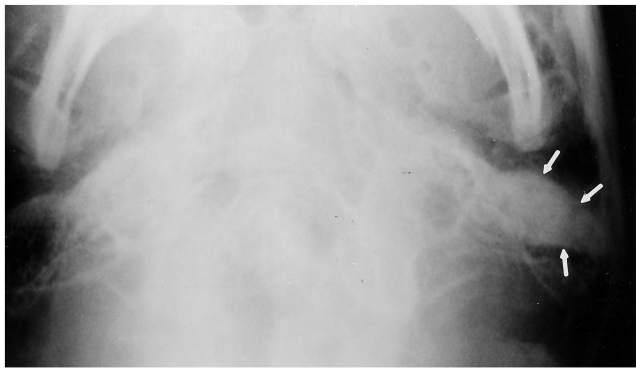tween HAC and native bone may be a thin line of soft tissue (Fig 5B) or may not be seen well. This interface may enhance faintly.

None of our patients had two consecutive CT studies or two consecutive MR studies available for review, which would have allowed assessment of change in appearance over time.

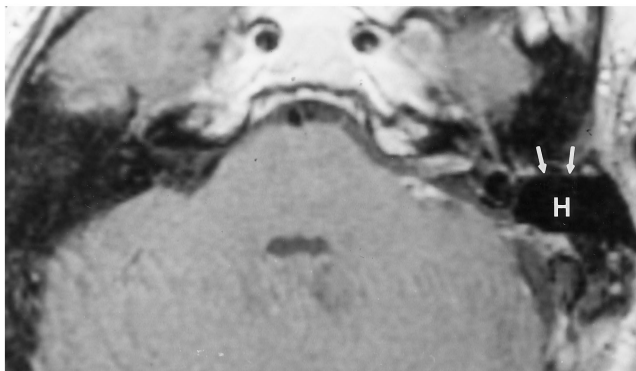### Complications

In four patients, the HAC had to be removed, in only one case because the HAC itself was abnormal (Fig 7). This patient had HAC placed to seal a cerebrospinal fluid leak (otorrhea) that developed after a mastoidectomy for cholesteatoma. Almost 2 years later, a draining fistula developed over the mastoid. On the CT scan, there was an irregular radiolucent cleft between the bone and the HAC (Fig 7A). The corresponding MR images showed soft tissue in this cleft (Fig 7B) that enhanced intensely after ad-

ministration of contrast material (Fig 7C). At surgery, granulation tissue surrounded the HAC, and the HAC was soft and pasty and not osseointegrated. Another patient underwent obliteration of the frontal sinus and nasofrontal duct with HAC for chronic infections (Fig 8A). Four months later, infection recurred in the frontal bone and adjacent soft tissues (Fig 8B). The CT scan showed erosion of native bone, which extended up to the HAC. Although there was no change in the appearance of the HAC (Fig 8B), both the bone and the HAC were removed. Two patients with malignant tumors required removal of the HAC. One patient's temporalis myofascial flap became necrotic 3 days after surgery. Removing the HAC facilitated surgical access to remove the flap and subsequent reconstruction. In the other patient, recurrent tumor developed that did not involve the HAC, but the cement was removed to facilitate the surgical approach.



A



B

Fig 5. Patient 10 (HAC in the mastoid cavity).

A, Submentovertical view of the mastoid cavity shows the homogeneously dense HAC on the left side (*arrows*).

B, Axial contrast-enhanced T1-weighted (600/25) MR image shows the well-defined signal void of the HAC (*H*). A thin, almost imperceptible rim of soft-tissue signal surrounds the HAC (*arrows*).

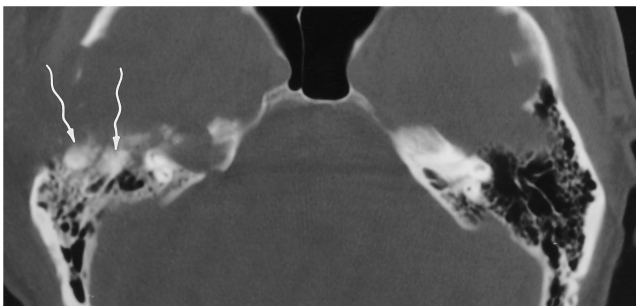
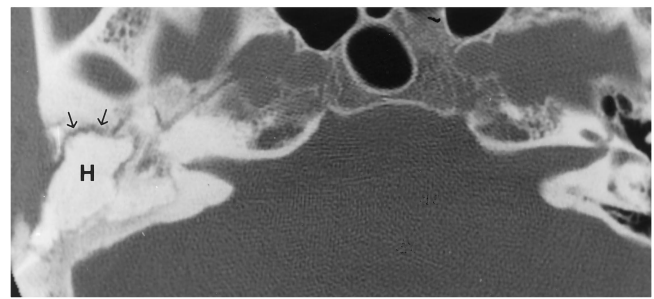


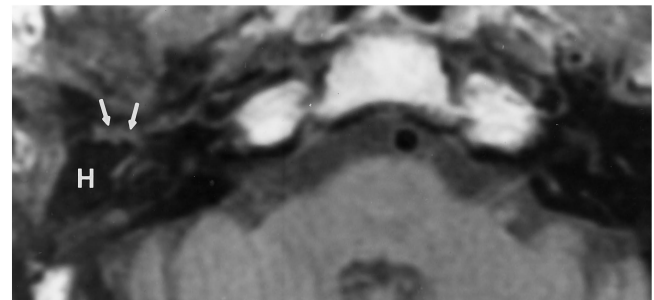
Fig 6. Patient 16 (HAC in the mastoid cavity). Axial CT scan (bone algorithm) shows two small foci of HAC (*arrows*) that could be overlooked as native bone.

**Discussion**

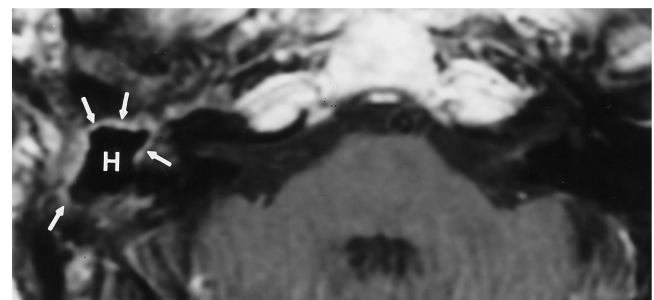
Many materials have been used for surgical repair of facial bone and skull base defects. Metal plates, silicon, methylmethacrylate, autogenous bone, and hydroxyapatite blocks suit many purposes, but (except for methylmethacrylate) are not easily molded or shaped. They



A



B



C

Fig 7. Patient 24 (HAC complications).

A, Axial CT scan (bone algorithm) shows HAC (*H*) in the right mastoidectomy defect. An irregular radiolucent cleft (*arrows*) separates the HAC from the surrounding native bone.

B, Corresponding axial T1-weighted (525/25) MR image shows soft tissue in this cleft (*arrows*) surrounding the signal void of the HAC (*H*).

C, After administration of contrast material, T1-weighted (625/25) image shows enhancement of the soft tissue (*arrows*) while the HAC remains a signal void (*H*). At surgery to remove the cement, the HAC was soft and surrounded by granulation tissue.

are also subject to infection, degeneration, reabsorption, and extrusion (1, 3).

Hydroxyapatite ( $Ca_{10}[PO_4]_6[OH]_2$ ) is a form of calcium phosphate that is stable (not resorbed) and biocompatible (does not elicit a foreign-body inflammatory response) (1). Until recently, hydroxyapatite was available only as ceramic blocks and granules (3). The nonceramic cement currently under investigation is a fine powder. When mixed with water, saline, or blood, the powder forms a paste (1) that is

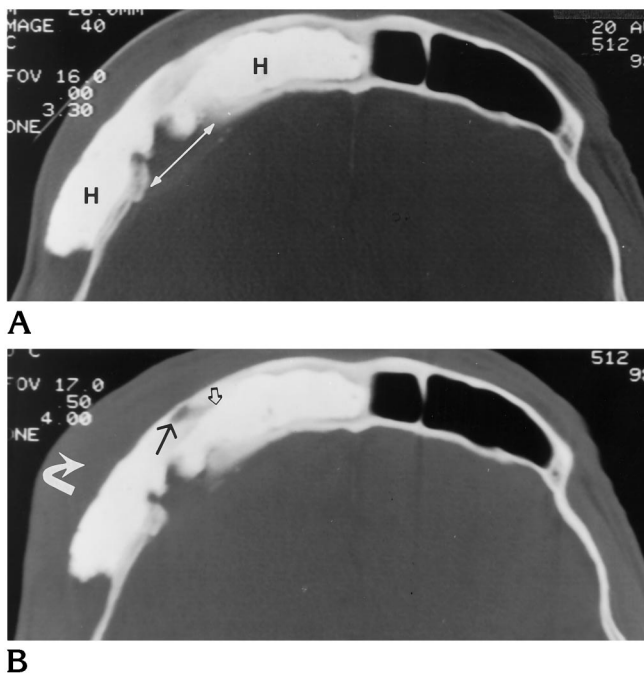


Fig 8. Patient 15 (HAC complications).

A, Axial CT scan (bone algorithm) shows the right frontal sinus obliterated by HAC (H). The inner table was disrupted at surgery (arrow).

B, On CT scan obtained 3 months later, there was prefrontal swelling (curved arrow) and a new radiolucency in the bone adjacent to (solid arrow) but not extending into (open arrow) the HAC. The infected bone and the HAC were removed.

similar to plaster of Paris (5) and can be molded and contoured to fill bone defects (Figs 1, 3A, and 5A). The paste hardens in approximately 15 minutes. Over the subsequent months, native bone grows into the pores of the HAC and forms a strong chemical bond with the material, in a process called *osseointegration* (1, 3).

HAC is not as strong as ceramic hydroxyapatite blocks. However, for non-weight-bearing sites, such as facial bones and skull base, this is not an important limitation (1).

As expected for the main constituent of bone and teeth (1), hydroxyapatite is homogeneously radiopaque on CT scans (Figs 2, 3B, 4A, and 4B) and plain radiographs (Figs 1A, 3A, and 5A). Presumably, the calcium content, lack of mobile hydrogen protons, or very short T2 relaxation time is responsible for the signal void on MR images (Figs 4C and 5B).

An important reason to be aware of the appearance of HAC is to avoid mistaking it for a disease process. Conceivably, HAC could mimic devitalized (sclerotic) bone, a blastic metastasis, an osteoma, or osteomyelitis on CT

scans. On MR images, the signal void could be mistaken for air, which would raise the possibility of a fistula or abscess in an obliterated frontal sinus or craniotomy. In the mastoid cavity, the signal void of HAC on MR images could be interpreted as pneumatized (clear) air cells. The HAC would then come as a surprise to the surgeon who had planned to drill through normal mastoid air cells.

The number of follow-up studies was too small to draw conclusions about the radiologic appearance of the development of osseointegration. Serial CT scans would reveal the time course of normal (uncomplicated) osseointegration. It is not yet known whether persistence of the thin, linear radiolucency between native bone and HAC indicates absence of osseointegration (or incomplete osseointegration). Similarly, on MR images, a thin line of soft-tissue signal between HAC and surrounding bone was seen in one uncomplicated case (Fig 5B).

An irregular, wide radiolucent interface between HAC and native bone on CT scans (Fig 7A) and enhancing soft tissue on MR images (Fig 7B and C) indicated infection in one patient. It would be dangerous to make generalizations from this solitary case. In one study of HAC obliteration of the frontal sinuses of cats, the investigators claimed that bone replaced the cement, beginning at the periphery. A radiograph of a specimen section 18 months after placement of the HAC showed no space between bone and HAC (5). However, neither in vivo radiographs nor CT scans were included (5). For hip prostheses (in humans), more than 2 mm of radiolucency between barium-impregnated polymethylmethacrylate cement and native bone suggests infection or loosening (6). Similar observations may apply to the HAC-bone interface. Persistence of a thin linear radiolucency between HAC and native bone (more apparent on CT scans than on plain radiographs) may be normal within the first months after surgery. This is similar to the findings for hip replacements. Further studies will shed light on the time course for radiologic osseointegration.

Ophthalmologists place hydroxyapatite globe prostheses in the orbit after enucleation. Holes are drilled to allow vessels to grow in and vascularize the prostheses. On MR images (7), enhancement of the prosthesis after administration of contrast material indicates vasculariza-

tion. It will be interesting to see whether HAC ever becomes vascularized.

At present, HAC is still undergoing review by the Food and Drug Administration and so is unavailable for routine clinical use. However, approval is anticipated, and HAC is likely to become widely available.

### Conclusion

HAC is a valuable addition to the surgical armamentarium. CT scans (bone algorithms) show HAC better than plain radiographs or MR images do. Large defects repaired with HAC are unlikely to be misinterpreted; small amounts of HAC are easier to overlook or misinterpret. Familiarity with the varied appearances of this material, in both uncomplicated and complicated (infected) states, may help prevent misdiagnoses.

### Acknowledgment

We are grateful to Sabrina Jennings for her secretarial expertise in the preparation of this manuscript.

### Addendum

The Food and Drug Administration has approved use of hydroxyapatite cement as of September 1996.

### References

1. Costantino PD, Friedman CD, Jones K, Chow LC, Pelzer HJ, Sisson GA. Hydroxyapatite cement, I: basic chemistry and histologic properties. *Arch Otolaryngol Head Neck Surg* 1991;117:379-384
2. Kamerer DB, Hirsch BE, Snyderman CH, Costantino P, Friedman CD. Hydroxyapatite cement: a new method for achieving watertight closure in transtemporal surgery. *Am J Otol* 1994;15:47-49
3. Shindo ML, Costantino PD, Friedman CD, Chow LC. Facial skeletal augmentation using hydroxyapatite cement. *Arch Otolaryngol Head Neck Surg* 1993;119:185-190
4. Snyderman CH, Costantino P, Friedman CD (principal investigators). *Investigative Device Exemption No. G910073*. Washington, DC: Food and Drug Administration, 1991
5. Friedman CD, Costantino PD, Jones K, Chow LC, Pelzer HJ. Hydroxyapatite cement, II: obliteration and reconstruction of the cat frontal sinus. *Arch Otolaryngol Head Neck Surg* 1991;117:385-389
6. Goergen TG. Imaging following joint surgery. In: Resnick D, Niwayama G, eds. *Diagnosis of Bone and Joint Disorders*. 2nd ed. Philadelphia, Pa: Saunders; 1988
7. Hamilton HE, Christianson MD, Williams JP, Thomas RA. Evaluation of vascularization of coralline hydroxyapatite ocular implants by magnetic resonance imaging. *Clin Imaging* 1992;16:243-246