

Are your **MRI contrast agents** cost-effective?

Learn more about generic **Gadolinium-Based Contrast Agents**.



FRESENIUS
KABI

caring for life

AJNR

Single-photon emission CT in the evaluation of recurrent brain tumor in patients treated with gamma knife radiosurgery or conventional radiation therapy.

J L Kline, R B Noto and M Glantz

This information is current as of April 18, 2024.

AJNR Am J Neuroradiol 1996, 17 (9) 1681-1686
<http://www.ajnr.org/content/17/9/1681>

Single-Photon Emission CT in the Evaluation of Recurrent Brain Tumor in Patients Treated with Gamma Knife Radiosurgery or Conventional Radiation Therapy

J. L. Kline, R. B. Noto, and M. Glantz

PURPOSE: To differentiate radiation necrosis from tumor recurrence using single-photon emission CT (SPECT). **METHODS:** Forty-two thallium-201 SPECT scans were obtained in 33 adult patients. All patients had previously been treated with either conventional external-beam radiation therapy (XRT) (26 patients) or gamma knife radiosurgery (16 patients) and had subsequent contrast-enhanced MR examinations before nuclear medicine imaging. Patients were injected intravenously with 4 mCi of thallos chloride Tl 201 with rapid acquisition of SPECT scans thereafter. Findings on thallium-201 SPECT scans were categorized as either positive or negative on the basis of an abnormal focus of increased activity in the area of the known lesion. Evaluation of the accuracy of the thallium-201 SPECT scan was made by correlation with subsequent histologic or cytologic analysis (28 cases) or, in cases in which biopsy was not performed, by subsequent clinical course or MR findings (14 cases). **RESULTS:** For all patients in this series, the sensitivity and specificity of thallium-201 SPECT scans in detecting tumor recurrence were 94% and 63%, respectively. The sensitivity and specificity for patients who had been treated with XRT were 95% and 60%, respectively. The sensitivity and specificity for patients who had been treated with gamma knife therapy were 92% and 67%, respectively. Tumor/scalp (T/S) ratios were calculated for all patients. High T/S ratios (>2.0) had a positive predictive value for tumor recurrence of 92%. T/S ratios less than 0.5 had a negative predictive value for tumor recurrence of 83%. **CONCLUSION:** Thallium-201 SPECT is a sensitive and accurate test to differentiate tumor recurrence from radiation necrosis in a population of patients with abnormal MR findings. This technique was equally efficacious in patients who had undergone gamma knife radiosurgery and in those who had received XRT.

Index terms: Brain neoplasms, computed tomography; Radiation, gamma knife; Radiation, necrosis; Single-photon emission computed tomography

AJNR Am J Neuroradiol 17:1681–1686, October 1996

Current advances in the treatment of primary brain neoplasms have created a unique problem in the subsequent evaluation of the tumor bed. Tumor recurrence and radiation necrosis cannot be reliably distinguished by either contrast-enhanced computed tomography (CT) or magnetic resonance (MR) imaging, since both

processes produce disruption of the blood-brain barrier (1, 2). Previous studies have shown positron emission tomography to be effective in distinguishing recurrent tumor from radiation changes; however, the cost is high and availability limited to only a few institutions (3).

Thallos chloride Tl 201 (thallium-201) is a radiopharmaceutical that is used in both planar imaging and single-photon emission computed tomography (SPECT). Thallium-201 has been shown to be effective not only in differentiating radiation necrosis from recurrent tumor but also in predicting the histologic grade of astrocytic tumors (4–6).

Previous reports have described the use of thallium-201 SPECT in patients with primary brain neoplasms who have been treated with

Received December 27, 1995; accepted after revision May 7, 1996.

Presented in part at the annual meeting of the American Society of Neuroradiology, Chicago, Ill, April 1995.

From the Departments of Diagnostic Imaging (J.L.K., R.B.N.) and Neurology (M.G.), Brown University School of Medicine, Providence, RI.

Address reprint requests to J. L. Kline, MD, Department of Diagnostic Imaging, Rhode Island Hospital, Brown University School of Medicine, Providence, RI 02906.

AJNR 17:1681–1686, Oct 1996 0195-6108/96/1709–1681

© American Society of Neuroradiology

surgery, conventional external-beam radiation therapy (XRT), and chemotherapy (6–8). We studied a group of 33 patients with pathologically proved primary brain neoplasms who all had thallium-201 SPECT brain scans after treatment by either XRT or the newer technique of gamma knife radiosurgery. We examined the overall accuracy of thallium-201 SPECT in differentiating radiation necrosis from recurrent tumor. We then divided the patients into two groups, those treated with conventional XRT and those treated with gamma knife radiosurgery, to determine whether the accuracy of thallium-201 SPECT is dependent on the type of radiation treatment received.

Materials and Methods

Patient Population

Fifteen women and 18 men with a mean age of 55 years underwent thallium-201 SPECT imaging. A total of 42 scans were obtained. Each patient had prior pathologic confirmation of primary brain neoplasm. At the time of initial diagnosis, 21 patients had glioblastoma multiforme, eight patients had anaplastic astrocytoma, and four patients had low-grade glioma.

Twenty-one patients had been treated with conventional XRT with or without paclitaxel chemotherapy and 12 patients had undergone gamma knife therapy. A total dose of 60 Gy fractionated over 6 weeks was administered to those receiving conventional XRT. For the gamma knife patients, a single dose of 40 Gy was prescribed to the 50% isodose line, corresponding to the enhancing margin of the tumor. Patients were examined with MR imaging 1 month after completing treatment and every 2 to 3 months thereafter. In all cases, MR images obtained before the thallium-201 SPECT scan revealed an abnormal area that could have represented recurrent tumor or radiation necrosis.

Eight patients had more than one thallium-201 SPECT scan, including seven patients with two scans and one patient with three scans. Each scan was classified as positive or negative on the basis of subsequent pathologic or clinical follow-up. Serial thallium-201 SPECT scans were obtained in these patients when there were symptoms of clinical progression with an equivocal MR finding. The time interval between thallium-201 SPECT scans ranged from 1 month to 15 months, with a mean of 6.2 months.

Imaging Protocol

SPECT imaging was initiated 10 minutes after the intravenous administration of 4 mCi of thallium-201. Images of the brain were acquired with a continuous 360° rotation for 30 minutes on a dual-head camera. A 128 × 128 matrix was used with a 20% symmetric window centered at 80 keV. Images were reconstructed using a filtered back-projection technique with a Wiener filter. Each scan section was equal to one pixel in thickness, or 4.67 mm.

Images were subsequently reconstructed in the transverse oblique (parallel to the canthomeatal line), coronal, and sagittal planes.

Thallium-201 Data Analysis

The thallium-201 transverse oblique, coronal, and sagittal scans were assessed qualitatively for areas of abnormal tracer uptake. These were graded as either positive or negative for abnormality on the basis of visual analysis. In addition, a circular region of interest with a diameter of 14 mm was placed over the area of maximal thallium-201 activity on the transaxial scans. If no abnormality could be detected, a circular region of interest of the same size was placed over an area corresponding to the MR abnormality. A circular region of interest was then placed over the area of maximal contralateral scalp activity. In concordance with prior studies (5, 6), uptake was determined to be high, moderate, or low in comparison with maximal scalp uptake in the contralateral hemisphere, according to a thallium-201 tumor/scalp ratio. The ratio was calculated as average counts per pixel in the region of interest for the tumor divided by average counts per pixel in the contralateral scalp area. Areas were categorized as having no significant uptake (ratios < 0.5), low uptake (ratios ranging from 0.5 to 0.9), moderate uptake (ratios ranging from 1.0 to 1.9), or high uptake (ratios > 2.0) (5). All thallium-201 studies were compared with the abnormal MR images. Interpretations were performed by two experienced nuclear medicine radiologists.

Pathologic Analysis

In 25 cases, tissue samples were obtained after thallium-201 SPECT imaging by either stereotactic biopsy or resection. Three patients had positive cerebrospinal fluid cytologic results.

Clinical Diagnosis

In 11 cases, a clinical diagnosis of tumor recurrence was made on the basis of the patient's clinical course after the thallium-201 scan. All patients with a clinical diagnosis of tumor recurrence had compelling clinical or follow-up MR evidence of recurrent tumor, and all patients with the clinical diagnosis of tumor recurrence died within a mean period of 7 months.

Three patients considered to be clinically tumor-free have been followed up for an average of 11 months and have shown no clinical or MR evidence of recurrent tumor.

Results

True-Positive Studies

The overall number of true-positive studies irrespective of prior treatment was 32. In 22 of these studies there was positive histologic or pathologic correlation. Ten of these patients

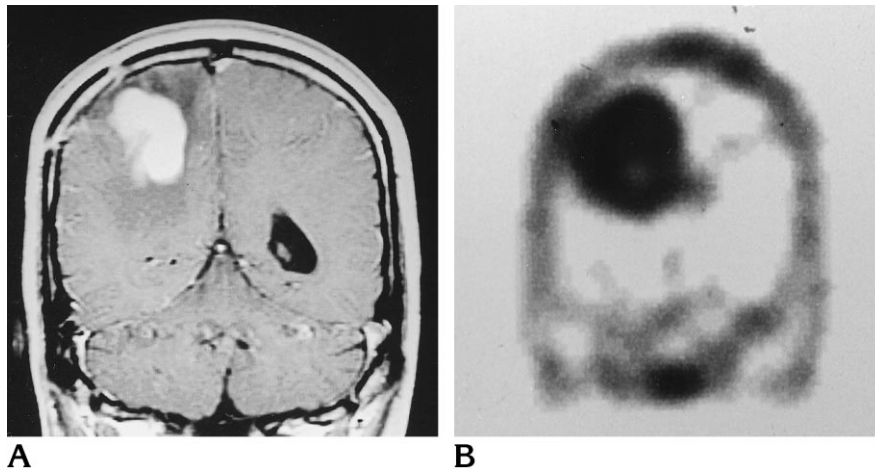


Fig 1. Thirty-eight-year-old man with glioblastoma multiforme.

A, Contrast-enhanced T1-weighted MR image shows an abnormal area of enhancement in the right parietal lobe.

B, Thallium-201 SPECT scan shows a corresponding area of increased activity. T/S ratio is 3.5.

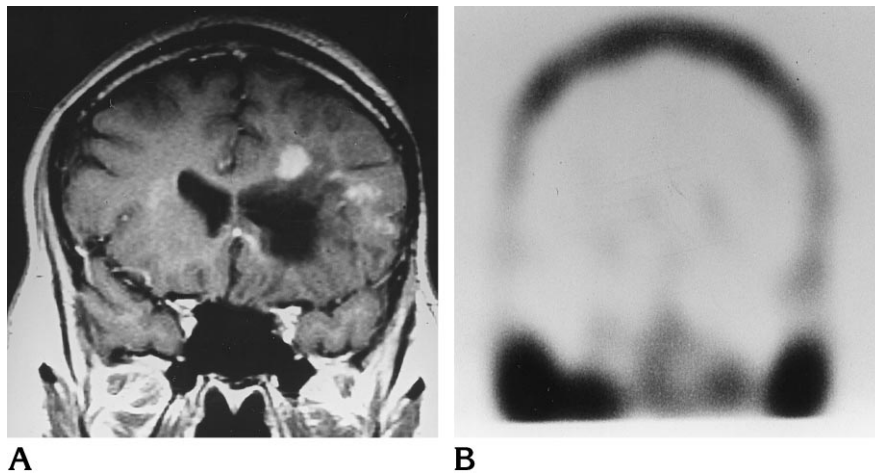


Fig 2. Thirty-seven-year-old man with a glioblastoma multiforme.

A, Contrast-enhanced T1-weighted image shows an area of abnormal enhancement in the left posterior frontal lobe.

B, Thallium-201 SPECT scan shows no corresponding increase in thallium uptake.

were considered to have tumor recurrence on the basis of clinical follow-up studies.

Twenty of the 32 patients had been treated with XRT. Thirteen had histologic correlation, seven had positive clinical studies, and the remaining 12 had been treated with gamma knife radiosurgery. Nine of those 12 patients had histologic correlation, and the other three had positive clinical findings. Figure 1 shows a true-positive thallium-201 SPECT scan.

True-Negative Studies

The overall number of true-negative studies irrespective of prior treatment was five (Fig 2). Two of these scans had histologic correlation and three had clinical correlation.

Three of the above patients received prior treatment with XRT. All were considered to be tumor-free on the basis of clinical findings. The remaining two patients had received gamma

knife treatment. These patients all had histologic correlation.

False-Positive Studies

Overall, three patients had false-positive findings on thallium-201 SPECT scans. Of these, two patients had been treated with XRT and one had received gamma knife treatment. All three scans were discordant with subsequent stereotactic biopsy results.

False-Negative Studies

Overall, two patients had false-negative findings on thallium-201 SPECT scans. One had received treatment with XRT, and SPECT studies were discordant with subsequent pathologic findings; the other had received gamma knife treatment, and was thought to have recurrent tumor on the basis of clinical follow-up evidence.

Of the 42 scans, 35 were interpreted qualitatively as positive and seven were interpreted as negative. Pathologic and clinical follow-up results for all patients are shown in Table 1. Twenty-six patients had been treated with XRT and 16 had received gamma knife treatment. These findings translate into a sensitivity of 94% and specificity of 63% for thallium-201 SPECT scans in detecting tumor recurrence. The overall accuracy was 88%. Among patients who had been treated with XRT, the sensitivity and specificity of thallium-201 SPECT scans in the detection of tumor recurrence were 95% and 60%, respectively, with an accuracy of 89%. For patients who had received gamma knife radiosurgery, sensitivity and specificity of thallium-201 SPECT scans in the detection of tumor recurrence were 92% and 67%, respectively, with an accuracy of 88%.

Tumor/Scalp Ratios

Of the 42 thallium-201 scans, 12 showed a tumor/scalp (T/S) ratio consistent with high up-

take of thallium-201 (>2.0), 13 showed a moderate uptake of thallium-201 (1.0 to 1.9), and five showed a low uptake of thallium-201 (0.5 to 0.9). Six scans showed a T/S ratio of less than 0.5. Six scans were not evaluated quantitatively, as the data were irretrievable. The distribution of T/S ratios and predictive values by treatment group are shown in Table 2. The relationship between T/S ratio and tumor type at the time of initial biopsy is shown in Table 3.

The positive predictive value for scans with high and moderate T/S ratios was 96%. For low T/S scans, positive predictive value was 60%. For scans in which the T/S ratio was less than 0.5, the negative predictive value was 83%.

Discussion

Thallium is a potassium analog that has been used for many years in myocardial perfusion imaging. Although the precise mechanism of uptake into tumor cells is unknown, it appears to rely on a combination of factors, including disruption of the blood-brain barrier, cellular

TABLE 1: Pathologic and clinical correlation with thallium-201 SPECT scans for patients who received prior treatment with external-beam radiation therapy (XRT) or gamma knife radiosurgery (GKR)

	Positive Pathologic Correlation		Positive Clinical Correlation		Negative Pathologic Correlation		Negative Clinical Correlation	
	XRT	GKR	XRT	GKR	XRT	GKR	XRT	GKR
	Positive thallium-201 SPECT studies	13	9	7	3	2	1	0
Negative thallium-201 SPECT studies	1	0	0	1	0	2	3	0

TABLE 2: Tumor/scalp (T/S) ratios for patients who received prior treatment with external-beam radiation (XRT) or gamma knife radiosurgery (GKR)

T/S Ratio	True-Positive Studies		False-Positive Studies		True-Negative Studies		False-Negative Studies	
	XRT	GKR	XRT	GKR	XRT	GKR	XRT	GKR
High	7	4	1	0	0	0	0	0
Moderate	7	6	0	0	0	0	0	0
Low	2	1	1	1	0	0	0	0
Less than 0.5	0	0	0	0	3	2	0	1
Not obtained	4	1	0	0	0	0	1	0

TABLE 3: Tumor/scalp (T/S) ratio with respect to patient's tumor type at time of initial biopsy

	T/S Ratio				
	High	Moderate	Low	Less than 0.5	No Data
Glioblastoma multiforme	9	7	3	3	4
Anaplastic astrocytoma	1	6	1	1	1
Low-grade glioma	2	0	1	2	1

metabolic activity, and Na^+ , K^+ -ATPase (adenosinetriphosphatase) activity (6, 9, 10). The latter two components allow the distinction of viable tumor cells from such changes as radiation necrosis, since radionecrotic tissue does not have an active transport mechanism or the necessary enzyme for thallium-201 uptake. Kasarov et al (11) found an increased level of the Na^+ , K^+ -ATPase enzyme in transformed fibroblasts, suggesting that this enzyme is present in increased levels in tumor cells. The enzyme is also believed to be present in increasing amounts as histologic grade increases. Thus, studies of the preoperative use of thallium-201 have shown a positive correlation between the amount of thallium-201 uptake and the histologic grade of tumor (2).

In the past, positron emission tomography with fludeoxyglucose F 18 (FDG) was the only technique available that could be reliably used to differentiate radiation necrosis from recurrent or residual brain tumor. This functional technique demonstrates the glucose metabolic state in an area of parenchymal abnormality detected by CT or MR imaging. FDG uptake in a lesion that was greater than or equal to uptake in an adjacent area of cerebral cortex was interpreted as evidence of active tumor. Decreased uptake was interpreted as evidence of no residual or recurrent tumor. Positron emission tomography enables the clinician to distinguish radiation necrosis from active tumor with a quoted sensitivity of 88% and specificity of 81% (3, 12). Unfortunately, the technique is expensive and availability is limited. These problems spurred the development of alternative imaging methods, such as thallium-201 SPECT.

The gamma knife delivers a single, high dose of ionizing radiation from 201 fixed cobalt-60 sources (13). Only at the point where all 201 beams converge into a finely focused beam is enough radiation delivered to injure pathologic tissue, thus sparing adjacent healthy brain tissue and other neural structures. Target location is accomplished with the use of MR imaging, CT, or arteriography, along with a specially designed stereotactic head frame attached to the patient's scalp. The gamma knife is used most effectively in the treatment of intracranial tumors with a size of up to approximately 3 cm. A conceptually related technique, LINAC radiosurgery, uses a modified conventional linear accelerator to accomplish the same goal. Together, these two methods of stereotactic

radiosurgery have become widespread in the treatment of primary and metastatic brain tumor (13, 14).

Previous studies have shown that imaging with thallium-201 SPECT is an efficacious and much less costly method of differentiating radiation necrosis from tumor recurrence than positron emission tomography (5-7). Those studies, however, contained fewer subjects than ours and looked only at patients who had received conventional XRT. In our evaluation of 26 scans obtained in patients who had received XRT and 16 scans obtained in patients who had undergone gamma knife radiosurgery, we did not find statistically significant differences between the two groups in the sensitivity, specificity, or accuracy of thallium-201 SPECT in differentiating radiation necrosis from tumor recurrence. The low specificity of thallium-201 SPECT as compared with its high sensitivity is attributed to the aggressive nature of the disease process being evaluated. Furthermore, only a few of the patients scanned (eight) had no clinical evidence of recurrent disease, and this small number may partially account for the low specificity.

As shown in Table 3, we did not find a consistent correlation between the T/S ratio and histologic grade of tumor. This differs from findings in previous studies. We suspect that this is because the patients in our study, unlike those reported by others, were treated before their evaluation with thallium-201 SPECT (2). The tumor cells remaining after conventional or gamma knife radiation probably differ in many ways from the cells composing the original tumor.

Overall, we found that thallium-201 SPECT scans had an excellent predictive value for differentiating residual or recurrent tumor from radiation necrosis, especially when quantitative techniques were used. In addition, one of the three false-positive thallium-201 SPECT scans was necessarily considered false positive because results of a subsequent stereotactic biopsy showed radiation necrosis only. However, this patient had a rapid clinical deterioration, and follow-up thallium-201 SPECT imaging 1 month later showed even higher T/S ratios in the same area. Results of a repeat stereotactic biopsy 1 month after the initial negative biopsy findings were positive for recurrent tumor. In retrospect, this case probably represented a false-negative stereotactic biopsy result rather

than a false-positive thallium-201 SPECT finding. This occurrence points out a second potential benefit of thallium-201 SPECT imaging. Stereotactic brain biopsies obtain small tissue samples from very small areas of brain. The thallium-201 SPECT scan can be used to help direct the stereotactic biopsy to an area of abnormal thallium-201 uptake, especially when coregistration techniques are used, and thereby potentially decrease the frequency of false-negative results.

Of the three-false positive scans, two showed a low T/S ratio. These scans were visually categorized as positive. Results of a subsequent biopsy were negative for tumor recurrence. This discrepancy may reflect criteria that are too strict for tumor recurrence. On the basis of our results, scans with a T/S ratio between 0.5 and 0.9 should actually be considered indeterminate, since the positive predictive value for these was only 60% whereas the positive predictive value for T/S ratios greater than or equal to 1.0 was 96%. This finding emphasizes the benefit of performing quantitative analysis rather than visual analysis alone.

The single false-positive result in which the T/S was greater than 1.0 is an enigma. The initial T/S ratio was high (2.2). Results of a stereotactic biopsy showed radiation necrosis only, and the patient is doing well clinically 3 years after biopsy, with no MR evidence of tumor progression.

There were two false-negative scans in our study. In one of these patients, we were unable to evaluate the scan retrospectively or to generate a T/S ratio, as the data were irretrievable. The second patient had progressive clinical symptoms, but the SPECT findings were negative, with a T/S ratio equal to 0. A repeat SPECT scan 1 month later showed positive findings, with a T/S ratio equal to 1.7. The patient's initial symptoms occurred 9 months after gamma knife therapy and may have been partially attributable to radiation necrosis. The rapid proliferation and progression of glioblastoma multiforme, however, is well documented, and during the 1-month interval the tumor may have grown rapidly, producing a subsequent positive thallium-201 SPECT finding. Of note, in all patients who had serial SPECT scans that showed disease recurrence, the subsequent scans showed increasing T/S ratios. This correlated with the continued progression of disease.

In summary, we found that scanning with

thallium-201 SPECT was a sensitive and accurate method for differentiating radiation necrosis from recurrent tumor. The sensitivity and accuracy of the study did not differ whether prior treatment was with XRT or gamma knife radiosurgery. Quantitative analysis is very helpful, with a positive predictive value of 96% for those with a T/S greater than or equal to 1.0 and a negative predictive value of 83% for those with a T/S less than 0.5. Of the five patients with T/S ratios of 0.5 to 0.9, only three were positive, and these cases should probably be categorized as indeterminate.

References

1. Dooms GC, Hecht S, Brant-Zawadski M, et al. Brain radiation lesions: MR imaging. *Radiology* 1985;158:149-155
2. Black KL, Hawkins RA, Kim KT, et al. Use of thallium-201 SPECT to quantitate malignancy grade of gliomas. *J Neurosurg* 1989;71:342-346
3. DiChiro G, Oldfield TF, Wright DC, et al. Cerebral necrosis after radiation therapy and/or intraarterial chemotherapy for brain tumors: PET and neuropathologic studies. *AJNR Am J Neuroradiol* 1987;8:1083-1091
4. Oriuchi N, Tamura M, Shibasaki T, et al. Clinical evaluation of thallium-201 SPECT in supratentorial gliomas: relationship to histologic grade, prognosis and proliferative activities. *J Nucl Med* 1993;34:2085-2090
5. Carvalho P, Schwartz R, Alexander E II, et al. Detection of recurrent gliomas with quantitative thallium-201, technetium-99m HMPAO single photon emission computerized tomography. *J Neurosurg* 1992;77:565-569
6. Schwartz R, Carvalho P, Alexander E III, et al. Radiation necrosis versus high grade recurrent glioma: differentiation by using dual-isotope SPECT with ²⁰¹Tl and ^{99m}Tc-HMPAO. *AJNR Am J Neuroradiol* 1991;12:1187-1192
7. Moustafa H, Omar W, Ezzal I, et al. ²⁰¹Tl single photon emission tomography in the evaluation of residual and recurrent astrocytoma. *Nuc Med Commun* 1994;15:140-143
8. Vertosick FT, Selder RG, Grossman SJ, et al. Correlation of thallium-201 single photon emission computed tomography and survival after treatment failure in patients with glioblastoma multiforme. *Neurosurgery* 1994;34:396-401
9. Brismar T, Collins VP, Kesselberg M. Thallium-201 uptake relates to membrane potential and potassium permeability in human glioma cells. *Brain Res* 1989;500:30-36
10. Mountz JM, Raymond PA, McKeever PE, et al. Specific localization of thallium 201 in human high grade astrocytoma by microautoradiography. *Cancer Res* 1989;49:4053-4056
11. Kasarov LB, Friedman H. Enhanced Na⁺-K⁺ activated adenosine triphosphatase activity in transformed fibroblasts. *Cancer Res* 1974;34:1862-1865
12. Valk PE, Budinger TF, Levin VA, et al. PET of malignant cerebral tumors after interstitial brachytherapy. *J Neurosurg* 1988;69:830-837
13. Flickenger JC, Loeffler JS, Larson DA. Stereotactic radiosurgery for intracranial malignancies. *Oncology* 1994;8:81-86
14. Alexander E III, Coffey R, Loeffler JS. Radiosurgery for gliomas. In: Alexander E III, Loeffler JS, Lunsford LD, eds. *Stereotactic Radiosurgery*. New York, NY: McGraw Hill; 1993:207-219