AJNR

Dual origin of the vertebral artery mimicking dissection.

T E Nogueira, A A Chambers, M T Brueggemeyer and T J Miller

AJNR Am J Neuroradiol 1997, 18 (2) 382-384
http://www.ajnr.org/content/18/2/382

Dual Origin of the Vertebral Artery Mimicking Dissection

Thomas E. Nogueira, A. Alan Chambers, Mary T. Brueggemeyer, and Timothy J. Miller

Summary: Vertebral artery injury may occur at the time of cervical fracture or dislocation. Congenital vertebral artery variations, especially a double vertebral artery origin, may be responsible for angiographic findings that mimic vertebral artery dissection. Two cases of cervical spine fracture with ipsilateral double vertebral artery are presented. Conventional cerebral angiography is the easiest and best way to make this diagnosis and to exclude vertebral artery dissection.

Index terms: Arteries, anatomy; Arteries, dissection; Arteries, vertebral

Vertebral artery injuries resulting from major cervical spine trauma are much more common than once thought. Recent studies of patients with cervical spine trauma show vertebral artery injury in 24% (1–3) (M. I. Rothman et al, paper presented at the annual meeting of the American Society of Neuroradiology, Chicago, April 1995). More severe cervical spine trauma, particularly subluxation of the facet joint or fracture of the transverse foramen, carries a higher rate of vertebral artery injury. Dissection from blunt trauma appears to be more common in the upper cervical spine, especially in the C-1 to C-3 location (4, 5). The purpose of this article is to describe the origin of the double vertebral artery, a developmental variant that may angiographically resemble a dissected vertebral artery (6–8).

Case Reports

Case 1

A 39-year-old woman had pain on the left side of the lower part of the neck and paresthesias in the left arm after being involved in a motor vehicle accident. A plain radiograph of the cervical spine showed a fracture involving the left posterior elements of C-6. A computed tomographic (CT) scan confirmed a fracture of the left C-6 pedicle and left C-6 lamina (Fig 1A). Since the fracture was close to the left foramen transversarium, vertebral angiography was done to exclude dissection. The left vertebral artery was catheterized directly at its origin from the aortic arch, and an initial injection of a small amount of contrast material showed irregularity of the lumen, corresponding to the site of the fracture (Fig 1B). This raised the possibility of dissection. However, a lateral view done with a more vigorous hand injection showed retrograde filling of a vessel extending from the C5–6 level of the left vertebral artery to the left subclavian artery. A dual origin of the left vertebral artery both from the aortic arch and the left subclavian artery was recognized (Fig 1C). The abnormality seen at the site of the fracture was in fact due to unopacified blood streaming into the left vertebral artery from the subclavian origin. The patient's cervical fracture was treated conservatively with a collar and her symptoms resolved.

Case 2

A 27-year-old man was involved in a motor vehicle accident that resulted in multiple injuries, including fractures of the ankle and humerus. A cervical spine series showed a rotary subluxation of C-6 on C-7. A CT scan showed a unilateral locked facet and associated fracture of the C-7 superior articular process with a bone fragment projecting into the right foramen transversarium of C-6. Angiography, performed on the third hospital day with selective injection of the vertebral arteries bilaterally, showed no vascular injury. However, the injection of the right vertebral artery showed an abrupt change in the diameter of the vertebral artery that raised the possibility of a dissection. Subclavian artery injection on the right showed two separate arterial trunks arising from the right subclavian artery that joined at the level of the C-6 foramen transvasarium to form the main right vertebral artery (Fig 2). The C6–7 dislocation was internally reduced and stabilized with posterior fusion plates. The patient left the hospital after 10 days with no neurologic impairment.

Received January 2, 1996; accepted after revision April 9.

From the Department of Radiology, University of Cincinnati (Ohio) Medical Center (T.E.N., A.A.C.), and the Departments of Surgery (M.T.B.) and Radiology (T.J.M.), the Good Samaritan Hospital, Cincinnati.

Address reprint requests to A. Alan Chambers, MD, Department of Radiology, University of Cincinnati Medical Center, 234 Goodman St, M.L. 742, Cincinnati, OH 45267.

AJNR 18:382–384, Feb 1997 0195-6108/97/1802–0382

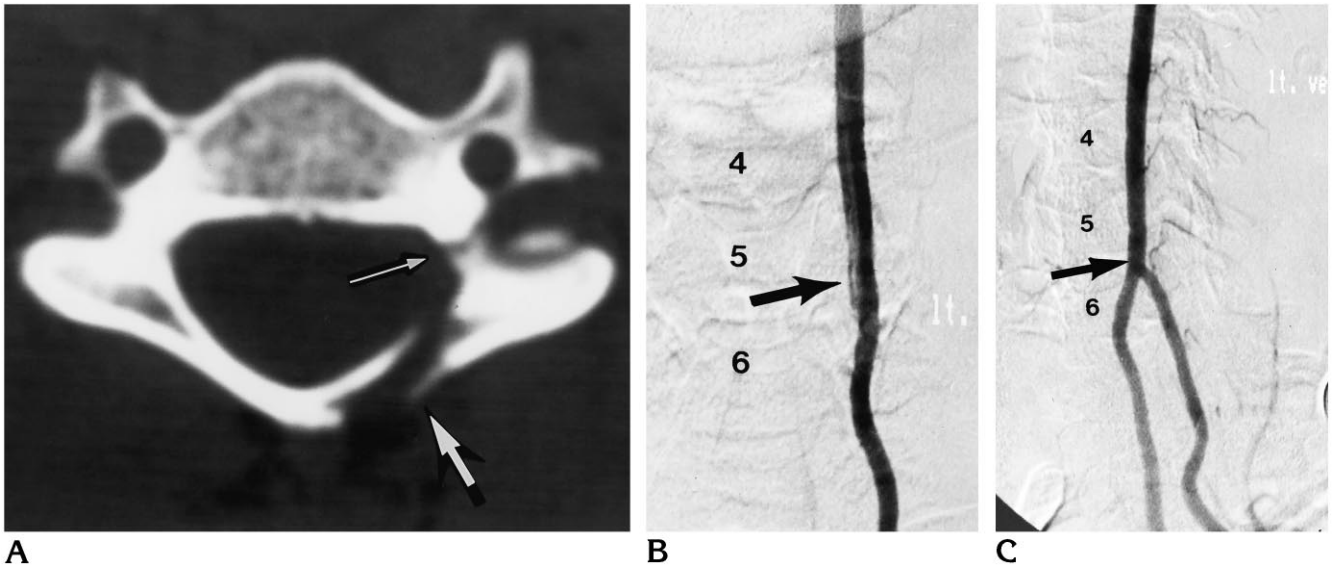

Fig 1. A 39-year-old woman with pain on the left side of the lower part of the neck and paresthesias in the left arm.

A, CT scan at the C-6 level shows a left-sided fracture of the C-6 pedicle (*wide arrow*) and lamina (*thin arrow*).

B, Left vertebral artery injection from the origin of the aortic arch (arch images not available) shows streaming at the C-6 level (*arrow*).

C, Repeat left vertebral artery injection shows reflux into a second trunk originating from the left subclavian artery. *Arrow* shows where trunks join.

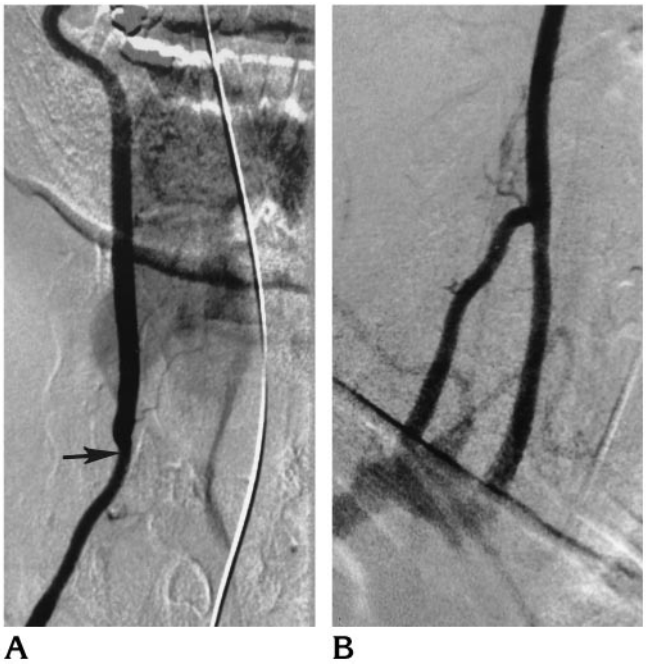

Fig 2. A 27-year-old man with fractures of the ankle and humerus.

A, Right vertebral artery injection shows a change in vessel diameter at C-6 (*arrow*).

B, Right subclavian artery injection shows dual origin of right vertebral artery.

Discussion

Dissection of the vertebral artery may occur spontaneously or as a result of trauma. Abrupt cervical rotation may cause damage to the vertebral artery. Approximately 15° of normal flexion and extension of the neck is possible at the atlantooccipital joint, and this motion is limited by the atlantooccipital membrane. The vertebral artery penetrates this membrane and may become kinked, stretched, or narrowed at the C1–2 interspace when the head is suddenly rotated. This kinking, stretching, or narrowing of the vertebral artery may result in intimal tearing, subintimal dissection, and subsequent thrombosis with vertebral artery occlusion. The thrombus may cause vascular obstruction, leading to posterior fossa infarction. If the dissection propagates intracranially, the vessel is no longer tamponaded by the surrounding bone and musculature of the neck, and the dissection may track through the media and adventitia, rupturing into the subarachnoid space and resulting in devastating subarachnoid hemorrhage. However, vertebral artery dissection or occlusion is most commonly limited to the extradural segment of the vessel.

Nevertheless, intradural and combined intradural/extradural dissections have been reported (9, 10). Fractures involving the transverse pro-

cesses, especially fractures into the foramen transversarium, may damage the artery within its bony confines (3). Likewise, subluxations of one vertebral body upon another, particularly with perched or locked facets, may exert undue tension and traction on the artery and result in dissection (2).

The vertebral artery usually arises from the subclavian artery, sometimes dually from the aorta and rarely from a common carotid artery (11, 12). Conventional angiography currently remains the standard of reference for examining the carotid and vertebral arteries. Typical findings of vertebral artery dissection on conventional angiograms include irregular stenosis with or without pseudoaneurysm, double lumen, intimal flap, or occlusion (2, 13). The reliability of magnetic resonance (MR) imaging and MR angiography in the diagnosis of vertebral artery dissection is still controversial, but these techniques are becoming more dependable owing to technical advances in MR angiography. The typical appearance of dissection on MR images is an eccentric signal void surrounded by a semilunar hyperintensity corresponding to the mural hematoma (14).

Findings of dissection at duplex sonography include absent flow signal, low bidirectional flow, poststenotic low blood flow velocities, no diastolic flow, and direct visibility of a stenotic segment. The sensitivity of duplex sonography combined with transcranial Doppler sonography in detecting vertebral artery injuries proved by conventional angiography or MR angiography is 64% to 86% (15, 16). We have found that conventional digital subtraction angiography is the most rapid, accurate, and ultimately least expensive way to rule out vertebral artery dissection in a trauma patient who has a cervical collar in place and who is often on MR-incompatible monitoring and life-support machines.

If MR imaging is planned in the cervical spine or cord, MR angiography is suggested as a means to visualize the vertebral arteries. Although of potentially greater clinical use in the future, MR angiography with its sensitivity of 60% and sonography (even if transcranial Doppler sonography is available) with a sensitivity of 64% to 86% often are not practical or sufficiently accurate in the acute trauma setting of potentially devastating vertebral artery dissection.

Summary

Vertebral artery dissection is often seen after significant cervical spine trauma, especially with a facet joint subluxation or transverse process fracture. Vertebral artery dissection is best diagnosed with conventional angiography. Rare vertebral artery anomalies in the form of bifid origin may mimic vertebral artery dissection at conventional angiography. Failure to recognize such an anomaly might result in nonindicated anticoagulation and/or therapeutic vertebral artery occlusion intended to prevent embolization, with attendant risks of the therapeutic intervention.

References

1. Friedman D, Flanders A, Thomas C, Millar W. Vertebral artery injury after acute cervical spine trauma: rate of occurrence as detected by MR angiography and assessment of clinical consequences. *AJNR Am J Neuroradiol* 1995;164:443–447
2. Willis BK, Greiner F, Orrison WW, et al. The incidence of vertebral artery injury after midcervical spine fracture or subluxation. *Neurosurgery* 1994;34:435–442
3. Woodring JH, Lee, Duncan V. Transverse process fractures of the cervical vertebrae: are they insignificant? *J Trauma* 1993;34:797–802
4. O'Sullivan RM, Graeb DA, Nugent RA, Robertson WD, Lapointe JS. Carotid and vertebral artery trauma: clinical and angiographic features. *Australas Radiol* 1991;35:47–55
5. Cornacchia LG, Abitbol JJ, Heller J, Schneiderman G, Garfin S, Marshall LF. Blunt injuries to the extracranial cerebral vessels associated with spine fractures. *Spine* 1991;16:S506–S510
6. Sugita S, Abe T, Okura A, et al. MRI demonstration of double origin of the left vertebral artery: case note. *Neuroradiology* 1995; 37:295–296
7. Hasimoto H, Ohnishi H, Yuasa T, et al. Duplicate origin of the vertebral artery: report of two cases. *Neuroradiology* 1987;29: 301–303
8. Eisenberg RA, Vines RS, Taylor SB. Bifid origin of the left vertebral artery. *Radiology* 1986;159:429–430
9. DeBehnke DJ, Brady W. Vertebral artery dissection due to minor neck trauma. *J Emerg Med* 1994;11:27–31
10. Jabre A. Subintimal dissection of the vertebral artery in subluxation of the cervical spine. *Neurosurgery* 1991;29:912–915
11. Newton TH, Mani RL. The vertebral artery. In Newton TH, Potts DG, eds. *Radiology of the Skull and Brain: Angiography.* St Louis, Mo: Mosby; 1974;2:1659–1677
12. Wasserman B, Mikulis D, Manzione J. Origin of the right vertebral artery from the left side of the aortic arch proximal to the origin of the left subclavian artery. *AJNR Am J Neuroradiol* 1992;13:355–358
13. Glauser J, Hastings O, Mervant M, et al. Dissection of the vertebral arteries: case report and discussion. *J Emerg Med* 1994;12:307–315
14. Levy C, Laissy JP, Raveau V, et al. Carotid and vertebral artery dissections: three-dimensional time-of-flight MR angiography and MR imaging versus conventional angiography. *Radiology* 1994; 190:97–103
15. Sturzenegger M, Mattle HP, Rivoir A, et al. Ultrasound findings in spontaneous extracranial vertebral artery dissection. *Stroke* 1993; 24:1910–1921
16. Hoffmann M, Sacco RL, Chan S, et al. Noninvasive detection of vertebral artery dissection. *Stroke* 1993;24:815–819