

**Are your MRI contrast agents cost-effective?**

Learn more about generic Gadolinium-Based Contrast Agents.



**FRESENIUS  
KABI**

caring for life

**AJNR**

**Percutaneous transluminal angioplasty of the internal carotid artery with a continuous-perfusion dilatation catheter.**

T Tsurutani, T Orita and T Kitahara

*AJNR Am J Neuroradiol* 1997, 18 (4) 696-698

<http://www.ajnr.org/content/18/4/696>

This information is current as of April 19, 2024.

---

# Percutaneous Transluminal Angioplasty of the Internal Carotid Artery with a Continuous-Perfusion Dilatation Catheter

Tohru Tsurutani, Tetsuji Orita, and Tetsuhiro Kitahara

**Summary:** A patient who lost consciousness and had a convulsion caused by brain ischemia during balloon inflation in connection with percutaneous transluminal angioplasty was successfully treated with a continuous-perfusion dilatation catheter without complications.

**Index terms:** Arteries, transluminal angioplasty; Catheters and catheterization, instruments

Percutaneous transluminal angioplasty (PTA) is a frequently successful method for treating stenosis of the craniocervical arteries (1–3). However, PTA of lesions of the carotid artery is less likely to be performed because of the risk of thromboembolism and the success of carotid endarterectomy in such cases (3, 6). Thus, PTA may be indicated for patients who are at higher than average risk for carotid endarterectomy. We describe a patient with stenosis of the left cervical carotid artery, and occlusion of the right carotid artery who was unable to tolerate even a few seconds of perfusion interruption by balloon inflation because of poor collaterals. However, with the use of a continuous-perfusion balloon catheter (4, 5), the procedure was implemented safely and successfully.

## Case Report

A 68-year-old man who had had a craniotomy for a right-sided hypertensive hemorrhage (which had left him with mild left hemiparesis) was admitted to our hospital 9 years later with alteration of consciousness and right-sided hemiparesis. Conjugate gaze deviation to the left was also evident, and there was a difference in blood pressure between the two arms.

Cerebral angiography showed that the left internal carotid artery had a 79% stenosis in the cervical portion and a 60% stenosis in the C-5 portion (Fig 1A and B). The right internal carotid artery was occluded in the cervical portion, and the middle cerebral artery territory was fed by collat-

erals from the external carotid artery, mainly by anastomotic channels from the superficial temporal artery via a burr hole (Fig 1C and D). The right vertebral artery showed a 50% stenosis at its origin, and the left subclavian artery was totally occluded.

The day after admission, the patient's consciousness level and right hemiparesis had improved. A cerebral blood flow study revealed hypoperfusion of the left cerebral hemisphere. We therefore attempted PTA of the left cervical internal carotid artery.

One month after admission, using the Seldinger method, we inserted a JB2-type 7F catheter (Cook, Bloomington, Ind) into the left common carotid artery and an ultrathin PTA catheter (Target Therapeutics, Fremont, Calif) into the stenotic portion. Ten seconds after balloon inflation, the patient lost consciousness and suffered a convulsion, which affected his right upper and lower limbs. Deflation of the balloon led to resolution of all symptoms. After providing protection with corticosteroids, phenytoin, and mannitol, we attempted PTA again, but the same complication recurred after the same length of time, and the somatosensory evoked potential (SEP) monitor showed prolongation of the N20 wave.

A second PTA was attempted 2 weeks later. This time, however, we used a continuous-perfusion dilatation catheter (Speedflow, Schneider, Tokyo, Japan) (Fig 1E), a type of balloon catheter that can supply blood while the balloon is inflated. The balloon was inflated to 4 atm for 30 seconds without the patient's experiencing a recurrence of the prior symptoms. The balloon was then inflated to 5 atm for 30 seconds as the procedure was repeated. No change was evident in the patient's clinical status or on the SEP monitor, and the angiograms showed that the stenotic portion of the artery was adequately dilated (Fig 1F and G).

## Discussion

PTA of craniocervical vessels was attempted by Sundt et al in 1980 (7). Since then, the vertebrobasilar arteries have been the main vessels targeted. PTA of the carotid arteries has been hampered by the possibility of distal em-

---

Received April 3, 1996; accepted after revision August 14.

From the Department of Neurosurgery, Shuto General Hospital, 1000-1 Kogaisaku, Yanai, Yamaguchi 742, Japan. Address reprint requests to Tohru Tsurutani, MD.

AJNR 18:696–698, Apr 1997 0195-6108/97/1804-0696 © American Society of Neuroradiology

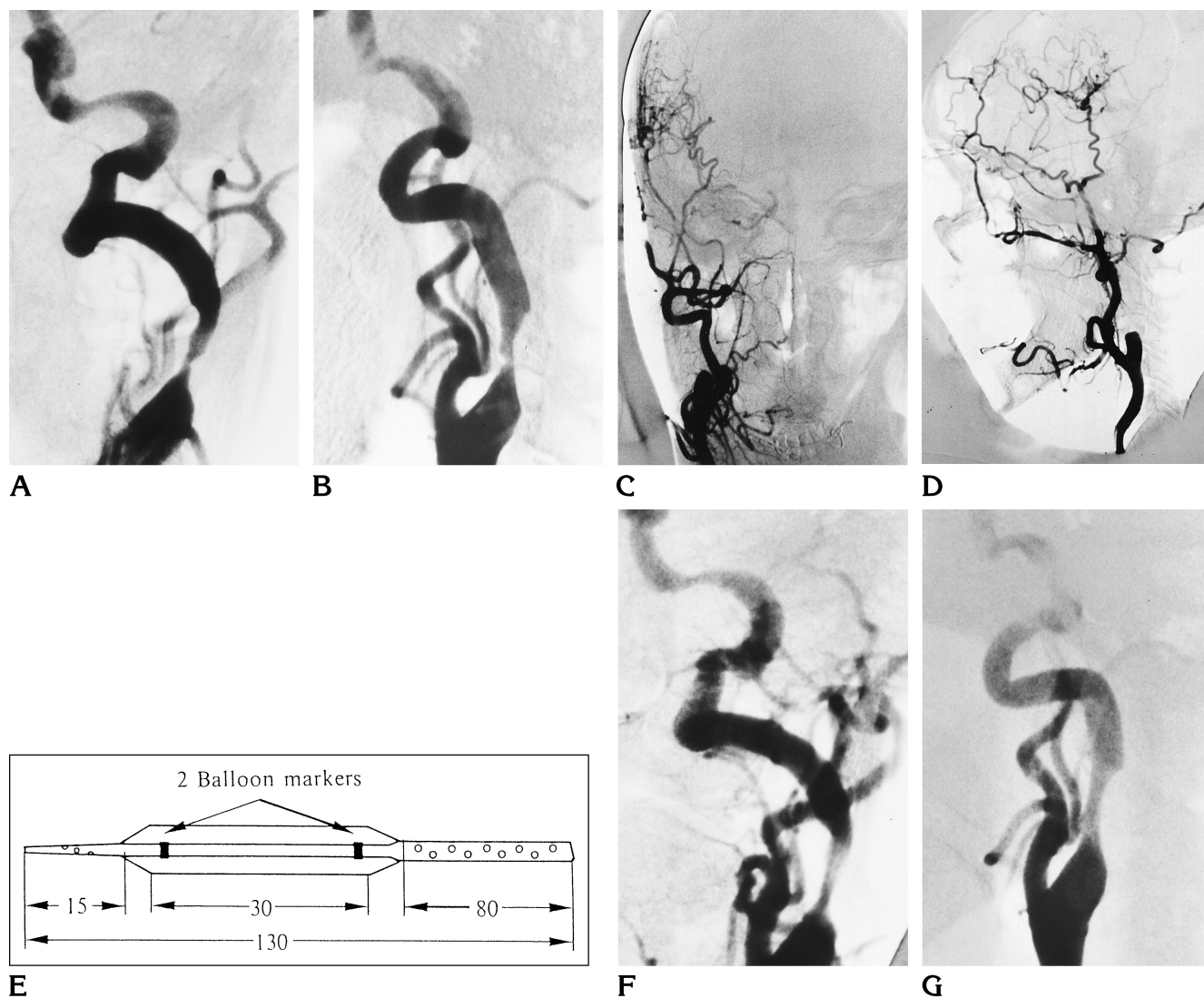


Fig 1. A 68-year-old man with alteration of consciousness, right-sided hemiparesis, and history of craniotomy for right-sided hypertensive hemorrhage.

A, Left carotid angiogram (anteroposterior view) shows 79% stenosis of the cervical internal carotid artery and 60% stenosis of the C-5 portion.

B, Left carotid angiogram (lateral view) shows 75% stenosis of the cervical internal carotid artery.

C and D, Right carotid angiograms (anteroposterior [C] and lateral [D] views) show occlusion of the right internal carotid artery at the cervical portion. Spontaneous anastomotic vessels arise from the superficial temporal artery via the burr hole. Other collaterals arise from the external carotid artery.

E, Drawing shows the tip of the continuous-perfusion balloon catheter. Several pores on the catheter proximal and distal to the dilated section are connected via the internal through-lumen (units are millimeters).

F and G, After surgery, left carotid angiograms (anteroposterior [F] and lateral [G] views) show 68% and 55% stenosis, respectively, of the cervical internal carotid artery.

bolism and the comparative success of carotid endarterectomy (1). Recently, carotid PTA has been shown to normalize impaired hemodynamics resulting from carotid stenosis in the same way as carotid endarterectomy (8), and a stroke rate of less than 5% has been reported (9). Furthermore, carotid endarterectomy for patients with contralateral carotid occlusion has been shown to carry a high perioperative risk in comparison with patients in whom the contralateral artery is patent (10). Maintenance of cerebral perfusion is considered to be an important factor in the prevention of stroke in such patients. Compared with carotid endarterectomy, the occlusion time during PTA is much shorter, about 30 to 60 seconds, so that use of medications to protect the brain during balloon inflation is not usually required. In fact, the majority of patients with carotid artery stenosis who have been treated with PTA had no symptoms during balloon inflation. However, some patients cannot tolerate periods of occlusion even as short as this because of the presence of very poor collaterals (1). During carotid endarterectomy, carotid occlusion decreases perfusion to below the critical limit of 10 mL/100 g per minute in about 8% of cases (11). This event is likely to have occurred in our patient.

During coronary intervention, a continuous-perfusion catheter is often used when acute occlusion occurs or when it is necessary to facilitate longer inflation times without causing ischemia. We used a perfusion Speedflow catheter, which has a perfusion capability of 100 mL per minute at 100 mm Hg, to perform PTA safely without complications. The technique was no more troublesome than when a usual balloon catheter is used. Furthermore, this procedure has the advantage of not requiring a time lag for perfusion interruption, even as com-

pared with a surgical shunt. The largest balloon in this series has a diameter of 4 mm. For PTA of the internal carotid artery, a larger balloon with a softer shaft might be required to allow its insertion into the tortuous craniocervical arteries. This instrument appears promising for treatment of carotid stenosis that shows marked hemodynamic impairment.

## References

1. Fong YT, Violet M, Grant H, et al. Percutaneous transluminal angioplasty of the carotid artery. *AJNR Am J Neuroradiol* 1986; 7:349-358
2. Courtheoux P, Tournade A, Theron J, et al. Transcutaneous angioplasty of vertebral artery atheromatous ostial stricture. *Neuroradiology* 1985;27:259-264
3. Higashida RT, Tsai FY, Halbach V, et al. Transluminal angioplasty for atherosclerotic disease of the vertebral and basilar arteries. *J Neurosurg* 1993;78:192-198
4. Raimund E, Werner C, Busch U, et al. New balloon catheter for prolonged percutaneous transluminal coronary angioplasty and bypass flow in occluded vessels. *Cathet Cardiovasc Diagn* 1986; 12:116-123
5. Turi ZG, Campbell CA, Gottimukkala MV, et al. Preservation of distal coronary perfusion during prolonged balloon inflation with an autoperfusion angioplasty catheter. *Circulation* 1987;6:1273-1280
6. DeMonte F, Peerless SJ, Rankin RN. Carotid transluminal angioplasty with evidence of distal embolization. *J Neurosurg* 1989;70: 138-141
7. Sundt TM Jr, Smith HC, Campbell JK, et al. Transluminal angioplasty for basilar artery stenosis. *Mayo Clinic Proc* 1980;55:673-680
8. Markus HS, Clifton A, Buckenham T, et al. Improvement in cerebral hemodynamics after carotid angioplasty. *Stroke* 1996;27: 612-626
9. Brown MM. Balloon angioplasty for cerebrovascular disease. *Neurol Res* 1992;14(suppl):159-163
10. Mackey WC, O'Donnell TF Jr, Callow AD. Carotid endarterectomy contralateral to an occluded carotid artery: perioperative risk and late results. *J Vasc Surg* 1990;11:778-785
11. Spetzler RF, Martin N, Hadley MN, Thompson RA, Wilkinson E, Raudzens PA. Microsurgical endarterectomy under barbiturate protection: a prospective study. *J Neurosurg* 1986;65:63-73