

**Are your MRI contrast agents cost-effective?**

Learn more about generic Gadolinium-Based Contrast Agents.



**FRESENIUS  
KABI**

caring for life

**AJNR**

**Posttraumatic extracranial aneurysm of the  
internal carotid artery: combined  
endovascular treatment with coils and stents.**

G E Klein, D H Szolar, J Raith, H Frühwirth, O Pascher and  
K A Hausegger

This information is current as  
of April 10, 2024.

*AJNR Am J Neuroradiol* 1997, 18 (7) 1261-1264  
<http://www.ajnr.org/content/18/7/1261>

---

# Posttraumatic Extracranial Aneurysm of the Internal Carotid Artery: Combined Endovascular Treatment with Coils and Stents

Günther E. Klein, Dieter H. Szolar, Johann Raith, Hannes Frühwirth, Ortwin Pascher, and Klaus A. Hausegger

**Summary:** We report a case of a posttraumatic extracranial pseudoaneurysm of the internal carotid artery that was treated successfully via embolization with Guglielmi detachable coils and placement of a Wallstent after surgical repair failed.

**Index terms:** Aneurysm, embolization; Interventional neuroradiology

Posttraumatic aneurysms of the distal extracranial internal carotid artery (ICA) are rare, especially those induced by blunt trauma (1). Because of the inaccessibility of the distal vessel in the skull base, surgical repair may be difficult or impossible (2, 3). Endovascular techniques for the embolization of aneurysms and pseudoaneurysms have been used in different locations (4, 5), and the use of Guglielmi detachable coils (GDCs) has significantly increased the safety and efficacy of the treatment of intracranial aneurysms (6, 7). However, a limitation in the use of these coils occurs in aneurysms with a wide neck, because of the risk of coil migration or coil protrusion into the parent artery. We report the use of combined stent implantation and endovascular coil placement in the treatment of a posttraumatic extracranial ICA aneurysm.

## Case Report

A 30-year-old woman who had had a car accident resulting in blunt trauma to the neck 14 years earlier presented with a pseudoaneurysm of the left ICA. The aneurysm was just below the skull base and was found incidentally at magnetic resonance imaging. Three-dimensional computed tomographic angiography and intraarterial digital subtraction angiography of the ICA confirmed the presence of a pseudoaneurysm that had a wide neck and caused narrowing of the ICA at the level of the aneurysm (Fig 1A). After surgical repair failed, the patient was ad-

mitted to our department for occlusion of the aneurysm by means of endovascular treatment.

We performed bilateral intracranial carotid angiography with and without manual compression of the contralateral cervical segment of the carotid artery to assess the perfusion pattern of the anterior communicating artery. Subsequently, to prove the competency of the circle of Willis, we placed a balloon catheter (Meditech, Boston Scientific Corp, Watertown, Mass) into the left ICA, and a test occlusion was done for 20 minutes. The patient's tolerance was evaluated by neurologic examination and by electroencephalography (EEG). During and after the test occlusion, neither neurologic symptoms nor pathologic changes on EEG were observed. Then, a 6F guiding catheter (Envoy, Cordis Corp, Miami, Fla) was placed into the cervical segment of the ICA below the aneurysm.

The aneurysm extended 30 mm craniocaudally, 15 mm anteroposteriorly, and 16 mm mediolaterally. The diameter of the ICA was 4.8 mm above and 5.4 mm below the aneurysm. The neck of the aneurysm was 7 mm in maximum diameter. Superselective catheterization of the aneurysm was performed with a microcatheter of variable stiffness (Tracker-18, Target Therapeutics, Fremont, Calif). Implantation of 11 GDCs (Target Therapeutics) resulted in dense packing of nearly the entire aneurysm. Coils ranged in diameter from 5 to 14 mm; a total length of 310 cm was inserted. Although parts of the coil network protruded into the stenotic lumen of the ICA (Fig 1B), a control angiogram revealed normal perfusion.

The second part of the procedure consisted in placement of a Wallstent (Schneider AG, Zürich, Switzerland), which was 6 mm in diameter and 37 mm in length. A straight extra-stiff guidewire (Amplatz, William Cook Europe, Bjaeverskov, Denmark) was passed through the narrowed segment of the ICA to allow advancement of the Wallstent over the guidewire. The Wallstent was delivered to cover the entire narrowed segment of the ICA and the wide neck of the aneurysm. Control angiograms via a 6F diagnostic catheter (Headhunter, Cordis Corp) showed that the normal caliber and patency of the ICA had been reconstituted and that the aneurysm remained occluded

---

Received July 22, 1996; accepted after revision October 31.

From the Departments of Radiology (G.E.K., D.H.S., K.A.H., J.R.) and Vascular Surgery (H.F., O.P.), Karl-Franzens Medical School and University Hospital Graz (Austria).

Address reprint requests to Günther E. Klein, MD, Department of Radiology, Karl-Franzens Medical School and University Hospital Graz, Auenbruggerplatz 9, 8036 Graz, Austria.

AJNR 18:1261-1264, Aug 1997 0195-6108/97/1807-1261 © American Society of Neuroradiology

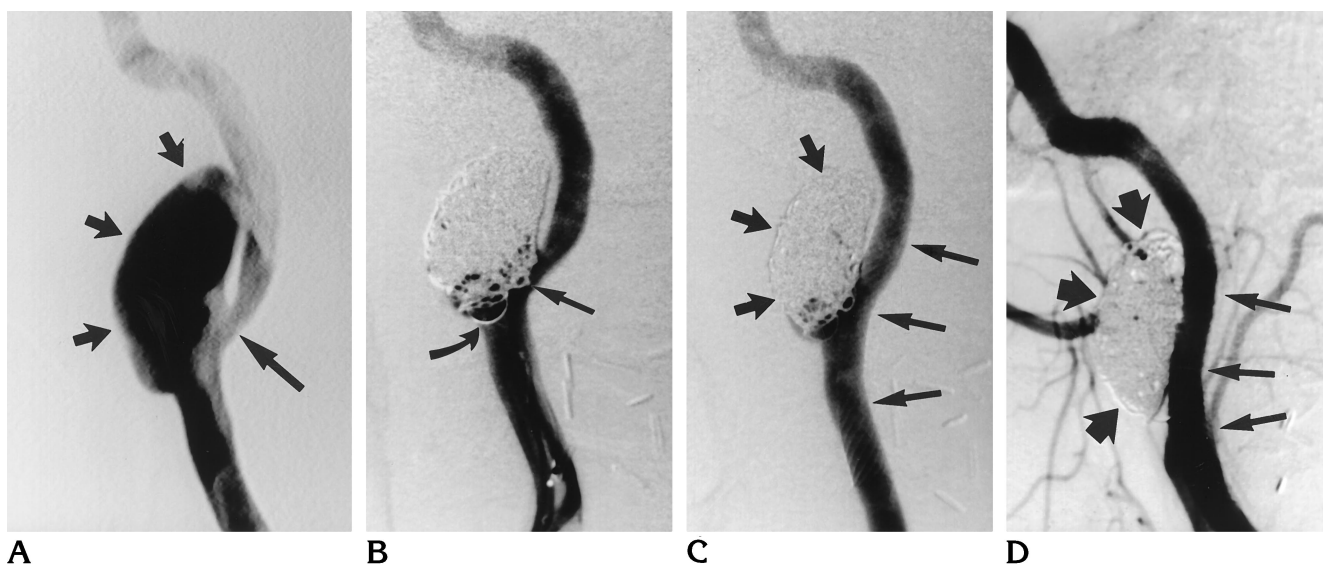


Fig 1. A 30-year-old woman with a left cervical ICA pseudoaneurysm.

A, Left internal carotid injection, lateral view, shows pseudoaneurysm (*short arrows*) and narrowed ICA (*long arrow*).

B, Left ICA angiogram after embolization with GDCs shows the coils protruding into the parent artery (*arrows*).

C, Left ICA angiogram after embolization and stent placement shows the occluded pseudoaneurysm (*short arrows*) and the remodeled stented carotid artery (*long arrows*).

D, At 6-month follow-up, left common carotid angiogram shows total occlusion of the pseudoaneurysm (*short arrows*) and normal width and patency of the stented segment of the ICA (*long arrows*).

(Fig 1C). The previously protruding loops of coils were pushed into the cavity of the aneurysm by the expanded stent.

A total of 10 000 immunizing units of heparin was administered during the procedure. Heparinization (1000 ImmU/h) was continued for the first 3 days after the procedure. Subsequently, antiplatelet medication was given for 6 months. Follow-up angiography 6 months after the procedure showed the pseudoaneurysm to be totally occluded, with patency of the stented segment of the ICA (Fig 1D).

## Discussion

Posttraumatic high cervical ICA pseudoaneurysms are rare, especially when caused by blunt trauma (1). The more common location is 1.5 to 3 cm distal to the bifurcation of the common carotid artery (8). At this level, the hypoglossal nerve and external carotid artery branches cross the ICA. In the case of a blunt cervical trauma with sudden hyperextension (whiplash injury), a mechanism of strangulation of the ICA by the hypoglossal nerve, causing injury to the wall of the artery, has been described (9, 10). Common sequelae of this type of trauma are dissections and occlusions of the ICA; pseudoaneurysms are uncommon findings (1, 3, 8). Treatment of cervical ICA aneurysms or pseudoaneurysms may be indicated because of

the potential risk of rupture of the aneurysm, which can also be a source of cerebral emboli (11–13). A test occlusion of the ICA (14) is performed to determine the feasibility of sacrificing the ICA by occlusion in case of inability to preserve the parent artery.

Endovascular coil embolization of aneurysms is becoming a well-established technique used in intracranial and extracranial locations (5, 15, 16). Detachable balloons have been used in primary treatment of aneurysms and in secondary trapping of aneurysms within the carotid as well as vertebral basilar locations (17). However, these balloons carry the risk of deflating, resulting in misembolization and aneurysmal rupture (18). In the treatment of aneurysms with conventional coils, two problems can occur: failure to achieve a stable position of the first coil and risk of losing the final coil. Both problems are encountered less frequently when GDCs are used.

Currently, GDCs are used primarily for embolotherapy within the intracranial circulation (6, 7). The main advantage of GDCs is the ability to control their detachment, allowing a more precise placement and therefore a safer and more successful procedure (6, 7). In the event of achieving an inadvertent coil position (ie, into the parent vessel), the coil can be with-

drawn and reinserted. In our case, during placement of the first coil, which was 14 mm in diameter and 30 cm in length, some loops protruded into the parent vessel. However, after replacement of the coil it was possible to achieve a stable position within the aneurysm before detachment. The flexibility and softness of GDCs better enable the physician to fully pack the aneurysm, fill any irregular outpouching, and separate the aneurysm from the circulation. Furthermore, electrothrombosis occurs adjacent to the coil during electrolytic coil detachment, which may accelerate the thrombotic occlusion of the aneurysm.

Surgical repair of aneurysms located above a plane between the mandibular angle and the mastoid process can be problematic, because of the inaccessibility of the distal vessel at the skull base (2, 3). In our case, such a surgical attempt failed. From the interventional point of view, however, we had to consider and manage two problems relating to this complex abnormality: the wide neck of the aneurysm and the significant narrowing of the ICA at the origin of the aneurysm. Wide-necked aneurysms still represent a limitation of the GDC system, because of the risk of coils migrating or bulging into the parent artery. The aneurysm could be packed with GDCs, but under these circumstances there is a high and predictable risk of occluding the ICA. Alternatively, placement of a covered stent could solve this problem by remodeling the narrowed lumen of the ICA and separating the aneurysm from the circulation.

To date, there have been a few experimental reports on the use of covered stents. These studies yielded different results, and investigators observed a relatively large number of complications, such as vasculitis and reocclusion of the vessel (19). Owing to the age of our patient, we did not want to take the risk of using a covered stent, so we decided to use a noncovered vascular stent. Several studies have demonstrated that noncovered vascular stents provide acceptable long-term patency rates in iliac arteries (20). The stent is placed so that it covers the mouth of the aneurysm from the lumen of the vessel and thus disrupts the usual blood-flow pattern into the aneurysm (21–25). Although this may lead to some decreased blood flow to the aneurysm, the application of a Wall-stent alone may not be sufficient to initiate thrombosis within the large aneurysm. Therefore, combined treatment with GDCs and a non-

covered stent was undertaken. The aneurysm was packed densely with GDCs followed by stenting of the narrowed segment so as to achieve remodeling of the lumen to protect it against the protruding coils. Furthermore, we thought that even after incomplete primary embolization of the aneurysm with GDCs, the stent would markedly reduce the flow into the aneurysm as well as its outflow, thus increasing the tendency toward embolization. Since the Wall-stent has a self-expanding force, an additional balloon dilatation was not necessary. Recently, a few authors have described the successful combined treatment of experimental wide-necked aneurysms with stent implantation and coil placement (26–28).

In conclusion, the combined endovascular treatment of an ICA pseudoaneurysm with GDCs and an endovascular stent seems to be minimally invasive, safe, and efficient. The value may be greatest in those patients in whom surgical repair is contraindicated or has failed. However, long-term follow-up examinations are required to confirm this encouraging initial result.

## References

1. Cogbill TH, Moore EE, Meissner M, et al. The spectrum of blunt injury to the carotid artery: a multicenter perspective. *J Trauma* 1994;37:473–479
2. Purdue GF, Pellegrini RV, Arena S. Aneurysms of the high internal carotid artery: a new approach. *Surgery* 1981;89:268–270
3. Pretre R, Reverdin A, Kalonji T, Faidutti B. Blunt carotid artery injury: difficult therapeutic approaches for an underrecognized entity. *Surgery* 1994;115:357–381
4. Uflacker R. Transcatheter embolization of arterial aneurysms. *Br J Radiol* 1986;59:317–324
5. Cascasco AE, Aymard A, Gobin YP, et al. Selective endovascular treatment of 71 intracranial aneurysms with platinum coils. *J Neurosurg* 1993;19:3–10
6. Guglielmi G, Viñuela F, Dion J, Duckwiler G. Electrothrombosis of saccular aneurysms via endovascular approach, II. *J Neurosurg* 1991;75:8–14
7. Scotti G, Rigluc C, Simionato F, Ming Hua Li. Endovascular therapy of intracranial aneurysms with GDC. *Riv Neuroradiol* 1994;7: 789–795
8. Dauber A, Hoffmann K, Zenker H-J, Hufen V. Bilaterale Carotisstenose nach schwerem craniocervicalem Trauma. *Chirurg* 1991; 62:433–436
9. Balzer K. Das Entrapment-Phänomen der Arteria carotis interna. *Zentralbl Chir* 1994;119(Suppl):128–130
10. Wozasek GE, Balzer K. Strangulation of the internal carotid artery by the hypoglossal nerve. *J Trauma* 1990;33:32–335
11. Lima A, Branco G, Costa J, Goulao A, Mauricio C, Vital P. A posttraumatic visual defect with late exacerbation associated with an aneurysm of the cervical internal carotid artery. *Acta Med Port* 1994;7:483–486
12. Applegate LJ, Pritz MB, Pribram HF. Traumatic pseudoaneurysm

- of the cervical carotid artery: the value of arteriography. *Neurosurgery* 1990;26:312-315
13. Moreau P, Albat B, Thevenet A. Surgical treatment of extracranial internal carotid artery aneurysm. *Ann Vasc Surg* 1994;8:409-416
  14. Vazquez Anon V, Aymard A, Gobin YP, et al. Balloon occlusion of the internal carotid artery in 40 cases of giant intracavernous aneurysm: technical aspects, cerebral monitoring, and results. *Neuroradiology* 1992;34:245-251
  15. Morse SS, Clark RA, Puffenbarger A. Platinum microcoils for therapeutic embolization: nonneuroradiologic applications. *AJR Am J Roentgenol* 1990;155:401-403
  16. Rao VR, Mandalam RK, Joseph S, et al. Embolization of large saccular aneurysms with Gianturco coils. *Radiology* 1990;175:407-410
  17. Higashida RT, Halbach VV, Dowd ChF, Barnwell SL, Hieshima GB. Intracranial aneurysms: interventional neurovascular treatment with detachable balloons: results in 215 cases. *Radiology* 1991;178:663-670
  18. Lina JR, Jaques P, Mandell V. Aneurysm rupture secondary to transcatheter embolization. *AJR Am J Roentgenol* 1979;132:553-556
  19. Link J, Grabener M, Linstedt U, Stock U, Heller M. Percutaneous treatment of constructed carotid aneurysms with covered stents in a swine model. *Radiology* 1995;197:309
  20. Sapoval MR, Long AL, Pagny JY, et al. Outcome of percutaneous intervention in iliac artery stents. *Radiology* 1996;198:481-486
  21. Wakhloo AK, Schellhammer F, de Vries J, Haberstroh J, Schumacher M. Self-expanding and balloon-expandable stents in the treatment of carotid aneurysms: an experimental study in a canine model. *AJNR Am J Neuroradiol* 1994;15:493-502
  22. Geremia G, Haklin M, Brennecke L. Embolization of experimentally created aneurysms with intravascular stent devices. *AJNR Am J Neuroradiol* 1994;15:1223-1231
  23. Grotenhuis JA, de Vries J, Tacl S. Angioscopy-guided placement of balloon-expandable stents in the treatment of experimental carotid aneurysms. *Minim Invasive Neurosurg* 1994;37:56-60
  24. Chalmers RT, Brittenden J, Bradbury AW. The use of endovascular stented grafts in the management of traumatic false aneurysms: a caveat. *J Vasc Surg* 1995;22:337-338
  25. Horowitz MB, Miller G III, Meyer Y, Carstens G III, Purdy PD. Use of intravascular stents in the treatment of internal carotid and extracranial vertebral artery pseudoaneurysms. *AJNR Am J Neuroradiol* 1996;17:693-696
  26. Szikora I, Guterman LR, Wells KM, Hopkins LN. Combined use of stents and coils to treat experimental wide-necked carotid aneurysms: preliminary results. *AJNR Am J Neuroradiol* 1994;15:1091-1102
  27. Turjman F, Massoud TF, Ji C, Guglielmi G, Viñuela F, Robert J. Combined stent implantation and endosaccular coil placement for treatment of experimental wide-necked aneurysms: a feasibility study in swine. *AJNR Am J Neuroradiol* 1994;15:1087-1090
  28. Massoud TF, Turjman F, Ji C, et al. Endovascular treatment of fusiform aneurysms with stents and coils: technical feasibility in a swine model. *AJNR Am J Neuroradiol* 1995;16:1953-1963