

---

# Disseminated Miliary Cerebral Candidiasis

Ping-Hong Lai, Shu-Ming Lin, Huay-Ben Pan, and Chien-Fang Yang

**Summary:** We present a case of disseminated intracranial infection by *Candida albicans* in a 5-year-old girl who had fever and a change of consciousness after surgery for complex congenital heart malformation. MR imaging revealed multiple small ring-enhancing hemorrhagic abscesses. One year after antifungal treatment, the abscesses and ventriculomegaly were almost completely resolved. The patient was discharged in a stable but vegetative condition.

**Index terms:** Brain, infection; Brain, magnetic resonance

*Candida albicans* is the most common nosocomial fungal infection (1, 2). Because the neurologic signs and symptoms of *C albicans* infection are vague and fleeting, most cases of central nervous system (CNS) candidiasis are diagnosed just before death or during postmortem pathologic study (3–5). Computed tomographic (CT) findings include large abscesses associated with osteolysis (5) and multiple granulomas and abscesses (6, 7). Magnetic resonance (MR) images show granuloma formation (8) and brain abscess associated with vascular invasion (9). We describe the MR characteristics of CNS disseminated candidiasis in a 5-year-old girl with fever and a change in consciousness after surgery for congenital heart disease.

## Case Report

A 5-year-old girl had complex congenital heart disease with a double outlet of the right ventricle and a small left ventricle. She had received a palliative shunt twice before, and her current admission was to establish a cavapulmonary connection. Empirical antibiotics, including cefazolin and gentamicin, were administered after the operation. *Pseudomonas* sepsis, a change in consciousness, and upper gastrointestinal bleeding developed on day 7. Antibiotics were changed to ceftazidime sodium and amikacin sulfate. The patient's general condition improved and

mentation became clear. However, fever, sepsis, and a change in consciousness recurred on day 18. Cerebrospinal fluid (CSF) analysis revealed a red blood cell count of  $260 \times 10^6/L$ , white blood cells of  $9 \times 10^6/L$ , a protein level of 1.32 g/L, and a glucose level of 3.8 mmol/L. The central venous catheter was changed, and cultures of the blood, urine, and CSF were taken.

Cranial MR imaging was performed with T1-weighted sequences before and after contrast administration (Fig 1A and B), proton density- and T2-weighted sequences (Fig 1C and D), and gradient-echo T2\*-weighted sequences (Fig 1E). Images were 5 mm thick with a 2.5-mm gap between sections. The acquisition matrix was  $256 \times 256$ , with a 20-cm field of view. No calcification was noted on the follow-up CT study. All cultures, including those from the tip of the central venous catheter, blood, urine, and CSF, showed *C albicans*. On day 22, the antibiotic treatment was discontinued and intravenous fluconazole was administered instead of amphotericin B because of the poor condition of the patient and the potential severe side effects of amphotericin B. A repeat CSF study showed absence of *C albicans* on day 29. After stabilization of vital signs on day 32, intravenous amphotericin B combined with fluconazole was administered and the patient's general condition improved progressively. However, she remained in a stupor.

Because of the development of hydrocephalus noted on the CT scan, external ventricular drainage was done on day 42. This was discontinued on day 49 and a ventriculoperitoneal shunt was performed owing to progressive hydrocephalus. Repeat MR imaging at 2 months, 6 months, and 1 year after antifungal therapy revealed a decrease in the number of lesions, and the presence of ventriculomegaly. Healing of the abscesses was noted after 1 year of antifungal therapy (Fig 1F).

## Discussion

The prevalence of candidal infections of the CNS found at autopsy has changed dramatically in recent years (1, 2, 10). As a result of widespread use of parenteral hyperalimentation,

---

Received July 23, 1996; accepted after revision October 23.

From the Departments of Radiology (P-H.L., H-B.P., C-F.Y.) and Pediatrics (S-M.L.), Veterans General Hospital-Kaohsiung, National Yang Ming University, National Defense Medical Center, Taiwan, Republic of China.

Address reprint requests to Chien-Fang Yang, MD, Department of Radiology, Veterans General Hospital-Kaohsiung, 386 Ta-Chung First Rd, Kaohsiung, Taiwan 80780, Republic of China.

AJNR 18:1303–1306, Aug 1997 0195-6108/97/1807–1303 © American Society of Neuroradiology

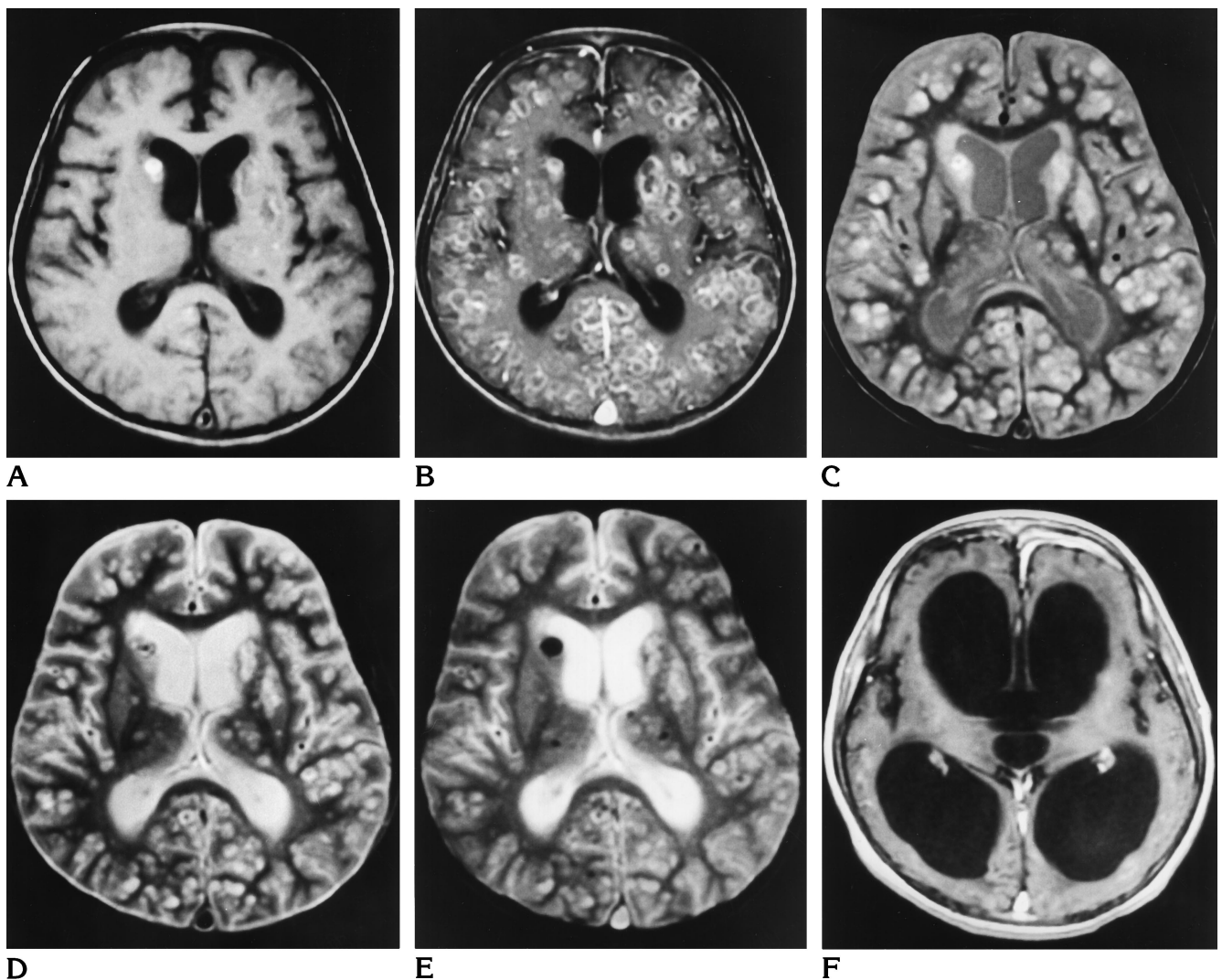


Fig 1. MR findings in a 5-year-old girl with fever and a change in consciousness after surgery for congenital heart disease.

A, T1-weighted image (500/30/2 [repetition time/echo time/excitations]) reveals hyperintense nodules in the head of right caudate nucleus and left corpus striatum.

B, T1-weighted image after intravenous administration of contrast material shows numerous ring-enhancing lesions.

C and D, Proton density- and T2-weighted images (2800/30,90/1) show that the lesions are hyperintense. Some have less intense centers.

E, Gradient-echo T2\*-weighted image (750/50/1, 100° flip angle) reveals multiple lesions, some of which have hypointensity due to the magnetic susceptibility effect of the hemorrhage.

F, Contrast-enhanced image obtained 1 year later shows almost complete healing of the diffuse abscesses after specific antifungal therapy. Ventriculomegaly and a thin left frontal subdural hematoma are noted.

tion, aggressive chemotherapy, corticosteroids, and other immunosuppressive therapies, and owing to increases in intravenous drug abuse, many more patients are at risk for the development of opportunistic infections than in years past. Among the opportunistic fungi that typically infect immunocompromised hosts, *Candida* organisms have emerged as dominant (1, 2, 10).

In our patient, the major risk factors for can-

didemia were complex congenital heart disease and the invasive nature of open-heart surgery, the use of a central venous catheter, associated *Pseudomonas aeruginosa* infection, and treatment with antibiotics before the onset of candidemia and CNS infection (2, 3, 11).

There are seven clinically important species of *Candida*, including *C albicans*, *C tropicalis*, *C krusei*, *C stellatoidea*, *C parapsilosis*, *C pseudotropicalis*, and *C guilliermondii*. Of these, *C al-*

*bicans* most often causes CNS infection, although there have been reports of meningitis due to *C tropicalis* and embolic abscess due to *C guilliermondii* (3, 4). Primary candidiasis of the brain and meninges is rare, whereas the CNS is frequently involved in disseminated candidiasis. However, CNS candidiasis is usually indolent initially, the most consistent features being progressive confusion and lethargy (3, 4). Less than half the patients with CNS candidiasis have CSF pleocytosis or hypoglycorrhachia. A delay in treatment of more than 2 weeks after onset of symptoms always results in a poor prognosis (12).

Disseminated fungal infections are uncommon but, when identified, *C albicans* is usually the culprit (13). Meningeal involvement in candidal infection is rather uncommon except in neonates (1, 2). *Candida* organisms tend to cause focal necrosis in the area around the microcirculation, producing microabscesses (1, 2, 14–16) located mainly at the gray–white matter junction, in the basal ganglia, and in the cerebellum (2, 15, 16). All parts of the CNS are involved with no apparent areas of predilection. A microabscess is defined as a lesion less than 3 mm in diameter consisting of a localized collection of polymorphonuclear leukocytes associated with tissue necrosis (15). *Candida* organisms also have a predilection for vascular structures (16), and may cause vasculitis, intraparenchymal hemorrhage, mycotic aneurysms, and thrombosis of small vessels with secondary infarction (1, 17). Our patient had hemorrhagic lesions, consistent with a common characteristic of *Candida* infection. Granulomalike lesions and large abscess are rare (1, 16).

Microorganisms that are known to cause abscesses include *Staphylococcus aureus*, streptococci, gram-negative bacteria, anaerobes, and others such as *Nocardia* organisms, *Mycobacteria tuberculosis*, *Toxoplasma gondii*, and fungi (14). The most common organisms implicated in the development of multiple microabscesses are *C albicans* and *Staphylococcus aureus* (15). Common differential diagnoses of multiple, small, ring-enhancing lesions include infection with *C albicans* and *S aureus*, tuberculosis (18), metastasis, and multiple sclerosis. Together with the patient's history and laboratory data, MR imaging can help establish a diagnosis of candidiasis even in patients whose symptoms are suggestive of intracranial neoplasm. The effect of medical treatment can be

monitored by MR studies, in which even small residues of initially extensive lesions can be seen.

Because of the infrequent occurrence of CNS candidiasis in children, experience with antifungal chemotherapy is limited. Amphotericin B is the principal drug used; however, some patients are unable to tolerate amphotericin B treatment (19). Other antifungal agents have not been tried in a sufficient number of cases of CNS fungal infection to determine their efficiency, toxicity, or ideal dosage. Fluconazole reaches high levels in the CSF after administration, and it may be useful in the treatment of candidiasis (20). In our patient, treatment with a combination of amphotericin B and fluconazole resulted in steady improvement of the clinical symptoms and signs.

In conclusion, this case highlights the fact that analysis of CSF in cases of parenchymal infections generally yields negative or inconspicuous findings unless the infection has already encroached on the subarachnoid space. On MR images, small abscesses combined with hemorrhage can be seen, and delays in antimicrobial therapy should be avoided. Familiarity with the MR findings of CNS disseminated candidiasis in the appropriate clinical setting may result in a heightened level of awareness of this infection and, consequently, in earlier diagnosis and treatment.

## Acknowledgments

We thank Lee-Ren Yeh, Pao-Chin Chiu, and Clement Chen for clinical assistance.

## References

1. Lipton SA, Hickey WF, Morris JH, Loscalzo J. Candidal infection in the central nervous system. *Am J Med* 1984;76:101–108
2. Parker JC Jr, McCloskey JJ, Lee RS. Human cerebral candidiasis: a postmortem evaluation of 19 patients. *Hum Pathol* 1981;12:23–28
3. Salaki JS, Louria DB, Chmel H. Fungal and yeast infections of the central nervous system: a clinical review. *Medicine* 1984;63:108–132
4. Lyons RW, Andriole VT. Fungal infections of the CNS. *Neurol Clin* 1986;4:159–170
5. Chaabane M, Krifa H, Ladeb MF, et al. Cerebral candidiasis: CT appearance. *Pediatr Radiol* 1989;19:436
6. Thron A, Wietholter H. Cerebral candidiasis: CT studies in a case of brain abscess and granuloma due to *Candida albicans*. *Neuroradiology* 1982;23:223–225
7. Kamitsuka MD, Nugent NA, Conrad PD, Swanson TN. *Candida*

- albicans* brain abscesses in a premature infant treated with amphotericin B, flucytosine and fluconazole. *Pediatr Infect Dis J* 1995; 14:329-331
8. Sze G, Zimmerman RD. The magnetic resonance imaging of infections and inflammatory diseases. *Radiol Clin North Am* 1988; 26:839-859
  9. Burgert SJ, Classen DC, Burke JP, Blatter DD. Candidal brain abscess associated with vascular invasion: a devastating complication of vascular catheter-related candidemia. *Clin Infect Dis* 1995;21:202-205
  10. Parker JC Jr, McCloskey JJ, Lee RS. The emergence of candidosis: the dominant postmortem cerebral mycosis. *Am J Clin Pathol* 1978;69:31-36
  11. Stamos JK, Rowley AH. Candidemia in a pediatric population. *Clin Infect Dis* 1995;20:571-575
  12. DeVita VT II, Utz JP, Williams T, Carbone PP. *Candida* meningitis. *Arch Intern Med* 1966;117:527-535
  13. Faix RG. Systemic *Candida* infections in infants in intensive care nurseries: high incidence of central nervous system. *J Pediatr* 1984;105:616-622
  14. Becker LE. Infections of the developing brain. *AJNR Am J Neuroradiol* 1992;13:537-549
  15. Pendlebury WW, Perl DP, Munoz DG. Multiple microabscesses in the central nervous system: a clinicopathologic study. *J Neuro-pathol Exp Neurol* 1989;48:290-300
  16. Roessmann U, Friede RL. Candidal infection of the brain. *Arch Pathol* 1967;84:495-498
  17. Scaravilli F. Parasitic and fungal infections of the nervous system. In: Adams JH, Corsellis JAN, Duchon LW, eds. *Greenfield's Neuropathology*. London, England: Edward Arnold; 1984:324-337
  18. Chang KH, Han MH, Roh JK, et al. Gd-DTPA enhanced MR imaging in intracranial tuberculosis. *Neuroradiology* 1990;32:19-25
  19. Weisse M, Aronoff SC. *Candida*. In: Nelson WE, Behrman RE, Kliegman RM, Arvin AM, eds. *Textbook of Pediatrics*. 15th ed. Philadelphia, Pa: Saunders; 1996:940-942
  20. Scheven M, Junemann K, Schramm H, Huhn W. Successful treatment of a *Candida albicans* sepsis with a combination of flucytosine and fluconazole. *Mycoses* 1992;35:315-316