AJNR

Duplex carotid sonography in distinguishing acute unilateral atherothrombotic from cardioembolic carotid artery occlusion.

K Kimura, K Yonemura, T Terasaki, Y Hashimoto and M Uchino

AJNR Am J Neuroradiol 1997, 18 (8) 1447-1452
http://www.ajnr.org/content/18/8/1447

Duplex Carotid Sonography in Distinguishing Acute Unilateral Atherothrombotic from Cardioembolic Carotid Artery Occlusion

Kazumi Kimura, Kiminobu Yonemura, Tadashi Terasaki, Yoichiro Hashimoto, and Makoto Uchino

PURPOSE: To distinguish between acute complete unilateral cardioembolic and atherothrombotic internal carotid artery (ICA) occlusion by using duplex carotid sonography. **METHODS:** We studied 11 patients with cardioembolic ICA occlusion (CE group), 32 patients with atherothrombotic ICA occlusion (AT group), and 25 patients with normal angiographic findings (control group). We obtained B-mode scans and measured the end-diastolic flow velocity (EDV) in both common carotid arteries within 3 days of the onset of symptoms. Side-to-side ratios of EDV (ED ratio) were calculated by dividing the flow velocity on the unaffected side by that on the affected side. **RESULTS:** In the AT group, the proximal ICA was full, with a large area of heterogeneous and partially calcified plaque, and the EDV (10.9 ± 6.1 cm/s) was significantly lower than that in the control group (20.3 ± 6.0 cm/s). The ED ratio was greater than 1.4 in all but one patient. In three patients in the CE group, B-mode scans showed a mobile, echogenic intravascular structure in the proximal ICA. The EDV (1.8 ± 3.4 cm/s) was significantly lower than that in the control and AT groups. The ED ratio was greater than 1.4 in all cases. **CONCLUSION:** We conclude that B-mode scans and the EDV in the common carotid artery can help to distinguish between acute cardioembolic and atherothrombotic ICA occlusion.

Index terms: Arteries, carotid, internal; Arteries, stenosis and occlusion; Arteries, ultrasound

AJNR Am J Neuroradiol 18:1447–1452, September 1997

Duplex carotid sonography is a useful technique in the diagnosis of internal carotid artery (ICA) (1–3) and vertebral artery (4) occlusion. In the acute phase of ICA occlusion it is important to distinguish between embolic and atherothrombotic stroke, because if there is an embolic ICA occlusion, the source of the emboli, such as atrial fibrillation or flutter, myocardial infarction, congestive heart failure, cardiomyopathy, atrial myxoma, and mitral or aortic valve disease, should be determined. Recurrent strokes are more likely among patients in whom the pathogenesis is cardioembolic than among those whose stroke is of atherothrombotic origin (5); in addition, the 1-month mortality after cardioembolic stroke is higher than that after atherothrombotic stroke (6). Anticoagulants may be prescribed to prevent recurrent cardioembolic stroke (7), a point that is clinically important in the treatment of acute stroke.

Our objective was to determine whether it was possible to discriminate between cardioembolic and atherothrombotic ICA occlusion by using duplex carotid sonography.

Patients and Methods

We studied 43 consecutive patients who presented with acute cardioembolic or atherothrombotic ICA occlusion between June 1, 1994, and March 30, 1996. In all patients, duplex carotid sonography and angiography were performed on the same day within 3 days after the onset of symptoms. ICA occlusion was diagnosed in all patients by means of intraarterial or intravenous digital subtraction angiography. The patients included 28 men and 15 women (mean age, 72 ± 9 years). Eleven patients had cardioembolic ICA occlusion (CE group) and 32 patients had atherothrombotic

Received October 29, 1996; accepted after revision February 5, 1997.

From the Departments of Cerebrovascular Disease (K.K., K.Y.), and Neurology (Y.H.), Kumamoto (Japan) City Hospital; the Department of Neurology, Cerebrovascular Center, Saiseikai Kumamoto Hospital (T.T.); and the Department of Neurology, Kumamoto University School of Medicine (M.U.).

Address reprint requests to Kazumi Kimura, MD, Cerebrovascular Division, Department of Medicine, National Cardiovascular Center, 5-7-1 Fujishirodai, Suita, Osaka 565, Japan.

AJNR 18:1447–1452, Sep 1997 0195-6108/97/1808–1447

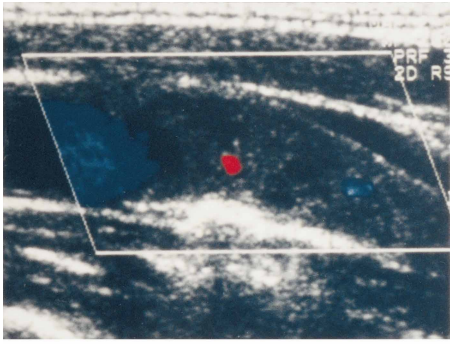

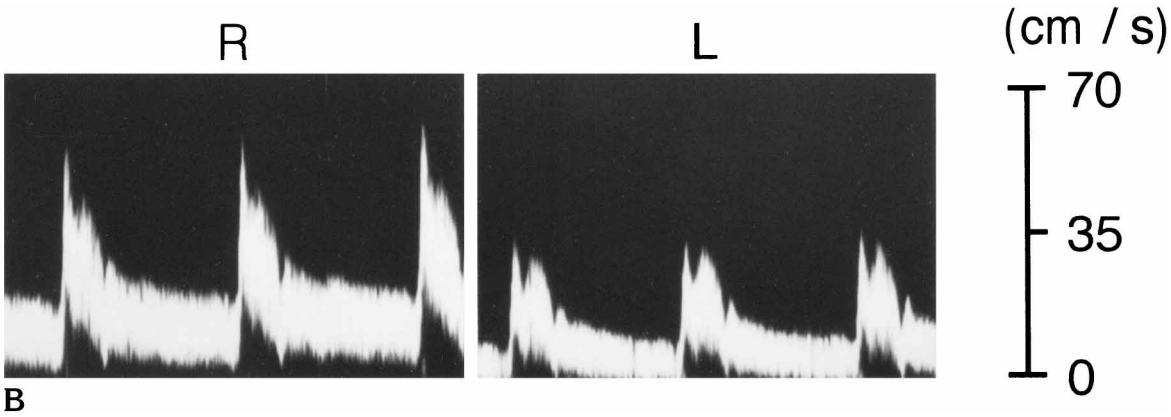

Fig 1. Color Doppler flow imaging and Doppler flow waveforms of a patient with left ICA occlusion due to atherothrombotic stroke.

A, Color Doppler flow image shows the anterograde (*blue*) flow in systole and the retrograde (*red*) flow in diastole proximal to the stump in the affected ICA occlusion. Color Doppler flow signal could not be detected in the lumen at the ICA origin. The lumen at the origin of the ICA was filled with large, heterogeneous, partially calcified plaque.

B, The left CCA end-diastolic velocity was 7.9 cm/s, the right CCA end-diastolic velocity was 19.9 cm/s, and the side-to-side ratio of the end-diastolic velocity was 2.5.

ICA origin occlusion (AT group). The clinical diagnosis of CE occlusion was made when a patient met at least two of the following three criteria (8–10): sudden onset of clinical symptoms; demonstration of a cardiac source of emboli, such as atrial fibrillation or flutter, recent myocardial infarction, congestive heart failure, and mitral or aortic valve disease; and evidence of embolization to other parts of the body. In all patients in the CE group, onset of symptoms was sudden; 10 patients had atrial fibrillation and one patient had acute inferior myocardial infarction. Two patients had embolization of the iliac artery. Angiographic findings showed distal occlusion without stenosis at the origin of the ICA. The clinical diagnosis of AT occlusion was made in patients who did not meet the above criteria but who had extracranial ICA occlusion that was thought to be due to atherosclerosis. Angiographic findings of all these patients showed rounded or pointed stump occlusion at the origin of the ICA. In the AT group, 23 patients had acute carotid territory stroke, seven had an acute occlusion of the central retinal artery, and two had transient ischemic attacks. For this study, ICA siphon occlusion without a cardiac source of emboli was excluded because it was difficult to distinguish an AT from a CE pathogenesis.

The control group comprised 25 patients (14 men and 11 women; mean age, 66 ± 13 years) with normal findings on bilateral carotid angiograms. Of these, 11 patients had lacunar infarction, nine had cerebral embolism, three had transient ischemic attacks, one had cerebral hemorrhage, and one had vertigo.

We obtained B-mode scans and measured the flow velocity by pulsed Doppler sonography in both common carotid arteries (CCAs). The transducer was operated at 5 to 10 MHz for B-mode imaging and Doppler functions. The pulse repetition frequency was mainly 5000 Hz, and the low-pass filter was 50 Hz.

B-Mode and Color Doppler Flow Imaging

Both carotid arteries were examined in all patients. Imaging was performed while the subjects were lying in the supine position with the head turned away from the side being scanned and the neck extended. The transducer was placed on the neck using the anterior oblique and posterior longitudinal approach. The CCA and ICA were first visualized with B-mode scans in the longitudinal and transverse planes and were then scanned using color Doppler flow imaging. The proximal ICA was investigated for morphologic abnormalities.

Blood Flow Velocity in the CCA

On longitudinal scans, the sample volume was set in the CCA, which was displayed as linearly as possible. A rangegate pulsed Doppler sample volume, 5 to 7 mm in size, was used to measure the blood flow velocity of the CCA. Special care was taken to keep the incident angle between the CCA and the beam at 30° to 60°. First, we measured the end-diastolic flow velocity of both CCAs and determined the mean value of five consecutive cardiac cycles.

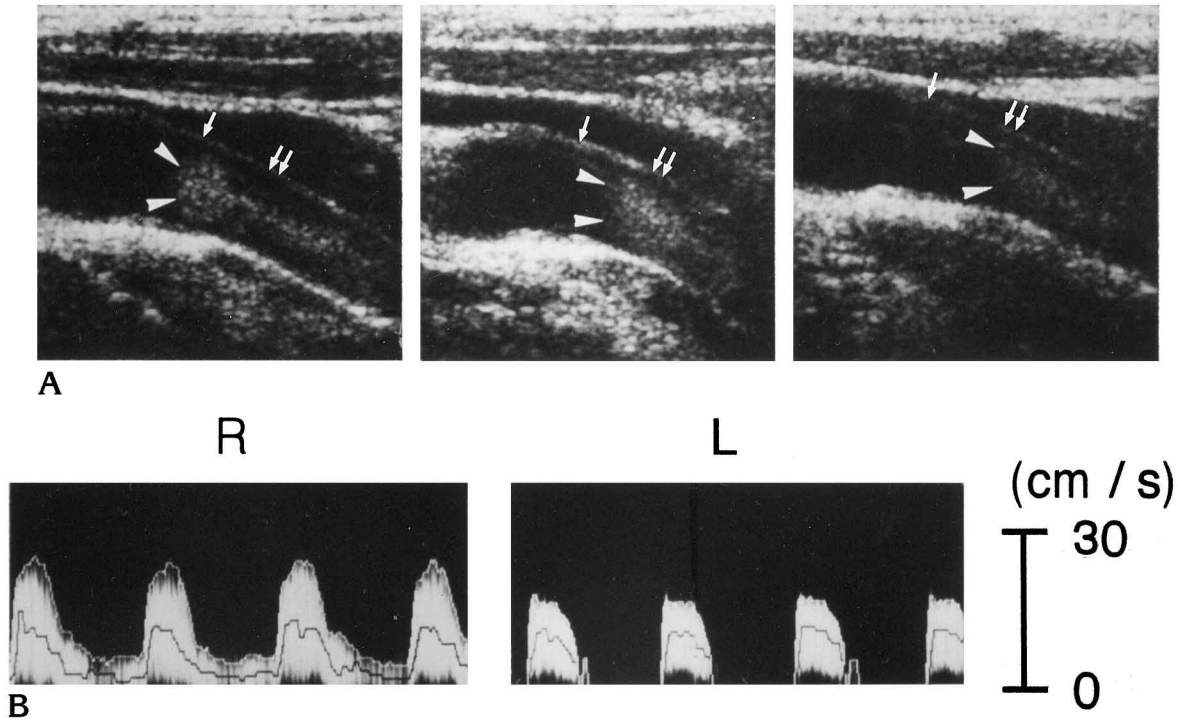

Fig 2. B-mode scan and Doppler flow waveforms of a patient with left ICA occlusion due to cardioembolic stroke.

A, B-mode scan shows that the movement of the echogenic intravascular structure (*arrowheads*) was synchronous with the cardiac cycle in the origin of the ICA. The intravascular structure moved quickly from the proximal to the distal ICA during systole, whereas during diastole the intravascular structure moved slowly from the distal to the proximal ICA. The intravascular structure (*left*) was located at the proximal ICA origin in the end-diastole of the cardiac cycle (*single arrow*). The intravascular structure (*middle*) was midway between the position of the end-diastole and the end-systole during the systole of the cardiac cycle. The intravascular structure (*right*) was located at the distal ICA origin in the end-systole of the cardiac cycle (*double arrows*).

B, Left CCA end-diastolic velocity cannot be detected; right CCA end-diastolic velocity was 10.0 cm/s.

Diagnosis of cardioembolic and atherothrombotic ICA occlusion from findings on B-mode scans and from blood flow velocity findings in the CCA

	B-Mode Scan Findings	Color Flow Imaging	Blood Flow Velocity	
			ED Ratio	End-Diastolic Velocity*
CE group	A mobile, echogenic, intravascular structure or Normal‡	Reversed blood flow† and Absent color Doppler signals	>1.4	1.8 ± 3.4
AT group	Heterogeneous and partially calcified plaque	Reversed blood flow† or No flow	>1.4	10.9 ± 6.1
Control group	Normal	Normal	<1.4	20.3 ± 6.0

Note.—CE group indicates patients with cardioembolic ICA occlusion; AT group, patients with atherothrombotic ICA occlusion; control group, normal bilateral carotid angiograms; and ED ratio, the side-to-side ratio of the end-diastolic flow velocity.

* Values are the mean ± SD

† Reversed blood flow: the anterograde flow in systole and the retrograde flow in diastole.

‡ Normal means there were no abnormalities in the origin of the ICA due to distal ICA occlusion.

These velocities were then corrected with the incident angle. Then, the side-to-side ratio of the end-diastolic flow velocity (ED ratio) was calculated by dividing the velocity on the unaffected side by that on the affected side in the CE and AT groups. In the control group, the ED ratio was obtained by dividing the velocity on the faster side by the slower velocity.

The age and flow velocity data for each group were expressed as the mean plus or minus the standard deviation (SD). For the analysis of velocity data, we used the unpaired *t* test. A *P* value of less than .05 was accepted as indicating a significant difference.

Results

B-Mode and Color Doppler Flow Imaging

In the control group, B-mode scans showed no morphologic abnormalities at the bifurcation or in the proximal ICA in any of the patients.

In all patients in the AT group, the proximal ICA was full, with a large heterogeneous and partially calcified area of plaque (Fig 1). Color flow Doppler imaging showed the anterograde

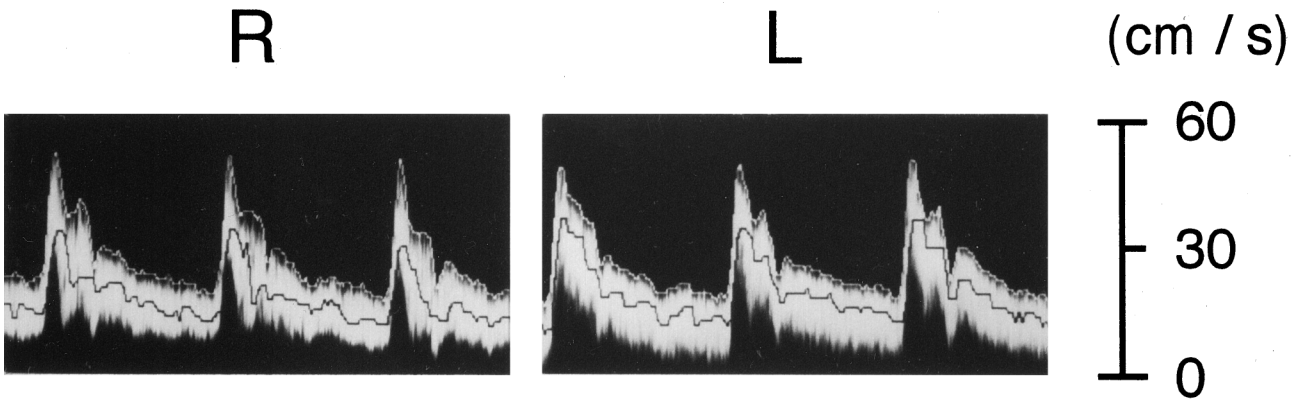

Fig 3. Doppler flow waveforms of a patient in the control group. Right CCA end-diastolic velocity was 23.0 cm/s, left CCA end-diastolic velocity was 28.2 cm/s, and the side-to-side ratio of the end-diastolic velocity was 1.2.

flow in systole and retrograde flow in diastole proximal to the stump in the affected ICA. It indicated a hemodynamically significant ICA occlusion and suggested that these patients had suffered an atherothrombotic ICA occlusion.

In the CE group, eight patients had no morphologic abnormalities at the bifurcation or in the proximal ICA. But in three cases, B-mode scans showed a mobile, echogenic intravascular structure in the proximal ICA, which probably represented a thrombus (Fig 2 and Table). The movement of the echogenic intravascular structure was synchronous with the cardiac cycle. The intravascular structure moved quickly from the proximal to the distal ICA during the systole of the cardiac cycle, whereas, during the diastole of the cardiac cycle, the intravascular structure moved slowly from the distal to the proximal ICA. This finding is characteristic of cardioembolic ICA occlusion. In eight patients with no morphologic abnormalities, color Doppler flow imaging showed absent color Doppler signals or anterograde flow in systole and retrograde flow in diastole in the affected ICA. It indicated a hemodynamically significant ICA occlusion.

Blood Flow Velocity in the CCA

The end-diastolic flow velocities in both CCAs were measured in the 68 patients. The typical waveforms in the AT, CE, and control groups are shown in Figures 1, 2, and 3. The end-diastolic flow velocities and the ED ratio in each group are shown in Figures 4 and 5 and in the Table.

In the control group, the end-diastolic flow velocity in 50 CCAs was 20.3 ± 6.0 cm/s, and the ED ratio was 1.2 ± 0.1; all values were less than 1.4 (mean ED ratio value +2 SD).

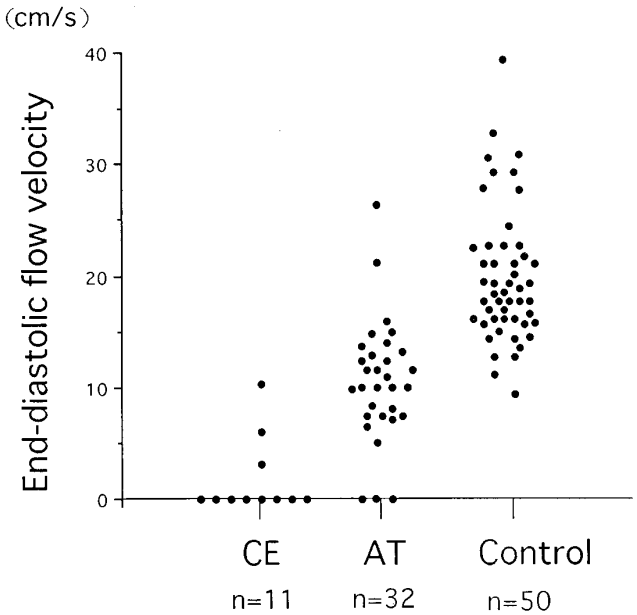

Fig 4. The CCA end-diastolic flow velocity in the CE, AT, and control groups. In the CE group, the end-diastolic flow velocity was significantly lower than that in the control and AT groups ($P < .01$).

In the AT group, the end-diastolic flow velocity (10.9 ± 6.1 cm/s) on the affected side was significantly lower than that in the control group ($P < .01$). Only in three of 32 patients could the end-diastolic flow velocity on the affected side not be detected. The ED ratio was greater than 1.4 in all but one patient.

In the CE group, the end-diastolic flow velocity (1.8 ± 3.4 cm/s) on the affected side, which

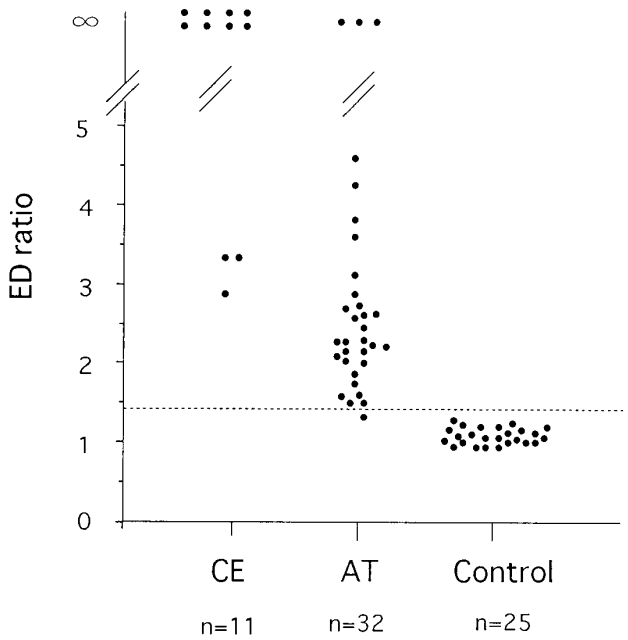

Fig 5. Side-to-side ratios of corrected end-diastolic velocities (ED ratios) in the CE, AT, and control groups. The AT and CE groups could be easily distinguished from the control group by the ED ratio. The *dotted line* indicates the mean value + 2 SD of the end-diastolic ratio (1.4) in the control group. In eight of the 11 patients in the CE group, the CCA end-diastolic flow velocity on the affected side cannot be detected, which was significantly lower than that in the control and AT groups ($P < .01$).

was zero in eight patients, was significantly lower than that in the control and AT groups ($P < .01$). In the remaining three patients it was 3.0, 6.0, and 10.3 cm/s, respectively. The ED ratio was greater than 1.4 in all patients.

The CE and AT groups could easily be distinguished from the control group on the basis of the ED ratio (>1.4).

Discussion

Duplex carotid sonography is a useful tool for diagnosing ICA occlusion (1–3). On the basis of the B-mode scan findings, our results indicated that 32 patients suffered an atherothrombotic ICA occlusion. In three patients in the CE group, B-mode scans showed a mobile, echogenic intravascular structure in the origin of the ICA. In patients with acute cardioembolic ICA occlusion, the embolus was usually lodged at the top of the bifurcation of the ICA (10). We suspect that mobile, echogenic intravascular structures are fresh thrombi that extend from the ICA bifurcation to the origin of the ICA. It is also possible that these patients had an embolus lodged in the proximal ICA that subsequently lysed and then lodged more distally in the ICA. Steinke et al (11) reported that mobile, thin, echogenic intravascular structures were visible on B-mode scans in 15% of their patients with a dissected ICA. We believe, therefore, that ICA occlusion caused by dissection would not be different from cardioembolism on the basis of carotid sonographic findings alone.

Recently, Yasaka et al (3) reported that the side-to-side ratio of end-diastolic velocity in the CCA can serve to identify the site of occlusion in the ICA in patients with acute cardioembolic stroke. In our study, the ED ratio in the CCA of all patients in the control group was less than 1.4, while in 42 of 43 patients in the group with ICA occlusion it was greater than 1.4. An ED ratio of more than 1.4 may also occur with atherothrombotic siphon occlusion or aortogenic embolic ICA occlusion or with extracranial ICA dissection. Therefore, the finding of a CCA ED ratio of more than 1.4 in the absence of plaque of ICA origin or a mobile intravascular structure is a likely indication of a distal obstructive lesion of diverse causes.

The end-diastolic flow velocity in the CE group was lower than that in the AT group. In eight of these 11 patients the end-diastolic flow velocity was zero. The end-diastolic flow velocity is considered to reflect the peripheral resistance. Angiographic findings showed a difference in the site of occlusion between the CE and AT groups; namely, the distal segment for the CE group versus the origin of the ICA for the AT group. When the origin of the ICA is occluded, the blood flows to the external carotid artery (ECA) in systole and diastole, whereas when the distal segment of the ICA is occluded, in systole the blood flow of the CCA is anterograde to the ICA and ECA, and in diastole the blood flow of the ICA origin returns retrograde to the CCA. Furthermore, in patients with acute cardioembolic ICA occlusion, the embolus is suddenly lodged in the ICA, and as a result there is insufficient time to develop collateral circulation. In patients with atherothrombotic ICA occlusion, progression of arterial occlusion permits a greater opportunity to develop collateral circulation over the course of time. As a result, the peripheral resistance in the CE group is higher than that in the AT group, and therefore, if the end-diastolic flow velocity in the CCA cannot be detected by duplex carotid sonogra-

phy, it is more likely to represent a CE occlusion than an AT occlusion.

We conclude that B-mode scans and the end-diastolic flow velocity in the CCA may help to distinguish differences between acute cardioembolic and atherothrombotic ICA occlusion.

References

1. Fell G, Phillips DJ, Chikos PM, Harley JD, Thiele BL, Strandness DE. Ultrasonic duplex scanning for disease of the carotid artery. *Circulation* 1981;6:1191–1195
2. Hoshino H, Takagi M, Takeuchi I, Akutsu T, Takagi Y, Ebihara S. Recanalization of intracranial carotid occlusion detected by duplex carotid sonography. *Stroke* 1989;20:680–689
3. Yasaka M, Omae T, Tsuchiya T, Yamaguchi T. Ultrasonic evaluation of the site of carotid axis occlusion in patients with acute cardioembolic stroke. *Stroke* 1992;23:420–422
4. Kimura K, Yasaka M, Moriyasu H, Tsuchiya T, Yamaguchi T. Ultrasonographic evaluation of vertebral artery to detect vertebrobasilar axis occlusion. *Stroke* 1994;25:1006–1009
5. Sage JI, Van Uiter RL. Risk of recurrent stroke in atrial fibrillation and nonvaluvular heart disease. *Stroke* 1983;14:668–676
6. Bogousslavsky J, Van Melle G, Regli F. The Lausanne stroke registry: analysis of 1,000 consecutive patients with first stroke. *Stroke* 1988;19:1083–1092
7. Marsh EE III, Adams HP Jr, Biller J, et al. Use of antithrombotic drugs in treatment of acute ischemic stroke: a survey of neurologists in practice in the United States. *Neurology* 1989;39:1631–1634
8. Adams HP, Bendixen BH, Kappelle LJ, et al. TOAST investigator: classification of subtype of acute ischemic stroke. Definitions for use in a multicenter clinical trial. *Stroke* 1993;24:35–41
9. National Institute of Neurological Disorders and Stroke. Classification of cerebrovascular diseases III. *Stroke* 1990;21:637–680
10. Yamaguchi T, Minematsu K, Choki J, Ikeda M. Clinical and neuroradiological analysis of thrombotic and embolic cerebral infarction. *Jpn Circ J* 1984;48:50–58
11. Steinke W, Rautenberg W, Schwartz A, Hennerici M. Noninvasive monitoring of internal carotid artery dissection. *Stroke* 1994;25:998–1005