

Are your **MRI contrast agents** cost-effective?

Learn more about generic **Gadolinium-Based Contrast Agents**.



**FRESENIUS  
KABI**

caring for life

**AJNR**

**Paraganglioma of the cauda equina with  
associated intramedullary cyst: MR findings.**

S H Faro, A R Turtz, R A Koenigsberg, F B Mohamed, C Y  
Chen and H Stein

*AJNR Am J Neuroradiol* 1997, 18 (8) 1588-1590

<http://www.ajnr.org/content/18/8/1588>

This information is current as  
of April 17, 2024.

# Paranganglioma of the Cauda Equina with Associated Intramedullary Cyst: MR Findings

Scott H. Faro, Alan R. Turtz, Robert A. Koenigsberg, Feroze B. Mohamed, Cheng-Yu Chen, and Herman Stein

**Summary:** The MR imaging features of a paranganglioma of the cauda equina with associated spinal cord cysts are presented. MR imaging showed the tumor to be isointense with the spinal cord on all pulse sequences and to enhance homogeneously. The intramedullary cysts had increased signal intensity on proton density- and T2-weighted images, and involved the cervical and thoracic regions.

**Index terms:** Spinal cord, neoplasms; Cauda equina; Paranganglioma

Parangangliomas are neuroendocrine tumors that derive embryologically from accessory organs of the peripheral nervous system or paraganglia (1). The tumor cells contain secretory granules that have peptides characterized by unique biochemical pathways involving amine precursor uptake and decarboxylation. Parangangliomas occur most often within the adrenal medulla. The most common extraadrenal sites are the carotid body and jugular bulb. Other locations include the middle ear, thyroid, mediastinum, tracheobronchial tree, gastrointestinal tract, and pancreas. They are also found within the central nervous system, occurring at such sites as the pineal region, sella turcica and petrous ridge, and cauda equina. We describe the radiologic features of a pathologically proved paranganglioma of the cauda equina with an associated spinal cord cyst.

## Case Report

A 46-year-old woman had a 6-month history of lower back pain, which radiated down both legs. She had no history of bowel or bladder dysfunction. Physical examination revealed slight weakness of the lower extremities below L-3 and an absent left knee jerk. No sensory loss

was demonstrated, and findings at computed tomography (CT) of the lumbar spine were interpreted as normal. The patient was treated conservatively with bed rest and analgesics.

Because of persistent symptoms 2 months after the CT study, a magnetic resonance (MR) imaging examination of the cervical, thoracic, and lumbar sacral spine was performed. This study showed spinal cord cysts of slightly increased signal intensity on T1-weighted images, and increased signal intensity on proton density- and T2-weighted images that involved the cervical and thoracic spinal cord. An intradural mass was seen at the conus medullaris and proximal cauda equina (Fig 1A). The mass was isointense with spinal cord on all pulse sequences and enhanced prominently after administration of contrast material. A focal area of marked enhancement was present within the superior portion of the tumor (Fig 1B and C). At surgery, the tumor appeared as a soft, well-encapsulated vascular mass.

Microscopy showed large areas of loose microcystic architecture and cells separated by vascular fibrous septa. The tumor had small, irregular, round nuclei with interspersed large neurons arranged in round groups, representing azellballen pattern (Fig 1D). Immunostains were negative for fibrillary acidic protein and positive for synaptophysin and chromogranin. No mitotic figures were present.

The patient's signs and symptoms resolved after surgery, and a 1-year follow-up MR imaging study of the spine showed no evidence of tumor recurrence.

## Discussion

Parangangliomas are rare within the central nervous system and may arise in the sella turcica, pineal region, and petrous ridge. These tumors may also be found in the cauda equina. Patients typically present with clinical signs and symptoms referable to a lesion in the cauda equina, manifested by lower lumbar pain, sen-

Received July 19, 1996; accepted after revision November 20.

From the Departments of Radiologic Sciences (S.H.F., R.A.K., F.B.M.) and Neurosurgery (A.R.T.), Medical College of Pennsylvania and Hahnemann University, Philadelphia; the Department of Radiology, Tri-Service General Hospital, National Defense Medical Center, Taiwan, Republic of China (C.-Y.C.); and the Department of Surgery/Neurosurgery, Robert Wood Johnson School of Medicine at Camden (NJ) (H.S.).

Address reprint requests to Scott H. Faro, MD, Department of Radiologic Sciences, Medical College of Pennsylvania and Hahnemann University, 3300 Henry Ave, Philadelphia, PA 19129.

AJNR 18:1588-1590, Sep 1997 0195-6108/97/1808-1588 © American Society of Neuroradiology

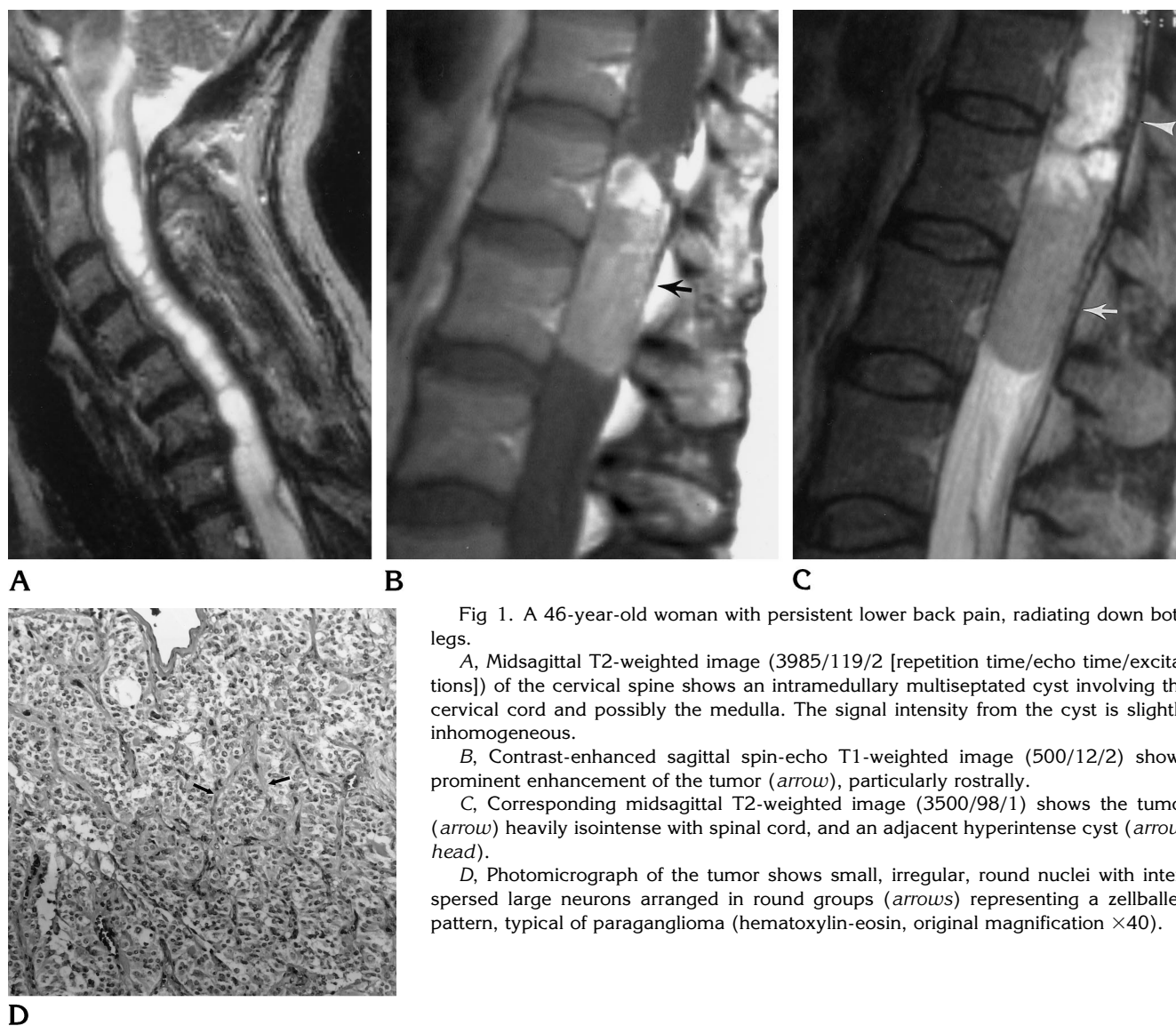


Fig 1. A 46-year-old woman with persistent lower back pain, radiating down both legs.

A, Midsagittal T2-weighted image (3985/119/2 [repetition time/echo time/excitations]) of the cervical spine shows an intramedullary multiseptated cyst involving the cervical cord and possibly the medulla. The signal intensity from the cyst is slightly inhomogeneous.

B, Contrast-enhanced sagittal spin-echo T1-weighted image (500/12/2) shows prominent enhancement of the tumor (*arrow*), particularly rostrally.

C, Corresponding midsagittal T2-weighted image (3500/98/1) shows the tumor (*arrow*) heavily isointense with spinal cord, and an adjacent hyperintense cyst (*arrow-head*).

D, Photomicrograph of the tumor shows small, irregular, round nuclei with interspersed large neurons arranged in round groups (*arrows*) representing a Zellballen pattern, typical of paraganglioma (hematoxylin-eosin, original magnification  $\times 40$ ).

sory or motor loss to the lower extremities, and bowel and bladder dysfunction (1). The duration of symptoms varies from days to years. There is a slight male predominance, and patients are generally between 13 and 70 years old. Cerebrospinal fluid protein is usually elevated. Pathologically, these are solid, highly vascularized, slow-growing intradural extramedullary masses. They are well encapsulated and originate from the proximal filum terminale. Cystic components may be found within the tumors. Complete surgical resection is considered curative and subtotal resection often leads to recurrence. Slow growth and delayed recurrence make long-term follow-up of these lesions necessary.

The MR imaging findings of paragangliomas

arising in the cauda equina have been described in several reports (2-7). In five of 11 cases, MR images obtained after administration of contrast material showed enhancement of the tumor. The MR imaging findings are generally nonspecific, with the tumor relatively isointense with spinal cord on T1-weighted images and hyperintense on T2-weighted images. In a few cases, heterogeneous signal intensity has been observed on T2-weighted images. Hypointense tumor margins on T2-weighted images, suggesting paramagnetic effects from hemosiderin, may also be seen. The salt-and-pepper appearance on T2-weighted images, considered characteristic of paragangliomas within the head and neck, has also been described in lesions arising in the cauda equina (8). In the cauda

equina, the solid portion of the tumor has been described as isointense with spinal cord on T2-weighted images in three cases (4, 6, 7). In one case, serpiginous flow voids were seen capping the tumor, which were believed to be caused by either hypervascularity of the tumor or compression of the veins by the mass (6).

In our case, a solid tumor was isointense with spinal cord on all pulse sequences, and the mass showed prominent contrast enhancement. Associated with the tumor were spinal cord cysts of complex signal intensity resulting from elevated proteins within the cystic fluid. The pathogenesis of the cysts is not well understood. Perhaps the normal flow of cerebrospinal fluid was blocked inferiorly by the tumor, thus creating a pressure differential and forcing fluid into the spinal cord with subsequent creation of cysts. Another plausible hypothesis is that the cysts were created by fluid extravasated from abnormal tumor vessels into the interstitial space in the spinal cord.

The differential diagnosis of a mass in the cauda equina region includes ependymoma, nerve sheath tumor, meningioma, lipoma, epidermoid, and hematogenous or drop metastasis (6, 9). Ependymoma is the most common tumor in this location. Ependymomas and nerve sheath tumors are relatively hyperintense on T2-weighted images. In our case, a lipoma or epidermoid tumor could be excluded owing to their relatively typical signal characteristics and lack of enhancement. A meningioma was included in the differential diagnosis because these tumors are typically isointense with spinal

cord on all sequences and show homogeneous contrast enhancement.

In summary, we have presented the MR imaging findings of a paraganglioma arising in the cauda equina. The lesion was relatively isointense with spinal cord on all pulse sequences and was associated with intramedullary cysts of complex signal intensity. The presence of intramedullary cysts in association with a paraganglioma of the cauda equina is a rare finding.

## References

1. Sonneland PRL, Scheithauer BW, Lechago J, et al. Paraganglioma of the cauda equina region: clinico-pathologic study of 31 cases with special reference to immunocytochemistry and ultrastructure. *Cancer* 1986;15:1720-1735
2. Hayes E, Lippa C, Davidson R. Paragangliomas of the cauda equina. *AJNR Am J Neuroradiol* 1989;10:S45-S47
3. Pigott TJD, Lowe JS, Morrell K, et al. Paraganglioma of the cauda equina: report of three cases. *J Neurosurg* 1990;72:455-458
4. Iliya AR, Davis RP, Seidman RJ. Paraganglioma of the cauda equina: case report with magnetic resonance description. *Surg Neurol* 1991;35:366-367
5. Wester DJ, Falcone S, Green BA, et al. Paraganglioma of the filum: MR appearance. *J Comput Assist Tomogr* 1993;17:967-969
6. Aggarwal S, Deck JHN, Kucharczyk W. Neuroendocrine tumor (paraganglioma) of the cauda equina: MR and pathological findings. *AJNR Am J Neuroradiol* 1993;14:1003-1007
7. Boukobza M, Foncin JF, Dowling-Carter D. Paraganglioma of the cauda equina: magnetic resonance imaging. *Neuroradiology* 1993;35:459-460
8. Olsen WL, Dillon WP, Kelly WM, Normal D, Brant-Zawadzki M, Newton TH. MR imaging of paragangliomas. *AJNR Am J Neuroradiol* 1986;7:1039-1042
9. Enzmann DR, DeLaPaz RL. Spinal cord tumors and extramedullary tumors. In: Enzmann DR, DeLaPaz RL, Rubin JB, eds. *Magnetic Resonance of the Spine*. St Louis, Mo: Mosby; 1990:301-352