

Are your **MRI contrast agents** cost-effective?

Learn more about generic **Gadolinium-Based Contrast Agents**.



**FRESENIUS  
KABI**

caring for life

**AJNR**

**Duplicated odontoid process: plain radiographic and CT appearance of a rare congenital anomaly of the cervical spine.**

M Garant, K Oudjhane, A Sinsky and A M O'Gorman

*AJNR Am J Neuroradiol* 1997, 18 (9) 1719-1720

<http://www.ajnr.org/content/18/9/1719>

This information is current as of April 17, 2024.

---

# Duplicated Odontoid Process: Plain Radiographic and CT Appearance of a Rare Congenital Anomaly of the Cervical Spine

M. Garant, K. Oudjhane, A. Sinsky, and A. M. O'Gorman

**Summary:** We describe a duplication of the odontoid process in a 6-year-old patient that included a partially fused midline ossicle on the anterior arch of C-1, fusion of the anterior lip of the foramen magnum and the arch of C-1, and an incomplete bony posterior arch of C-1.

**Index term:** Spine, abnormalities and anomalies

The most common anomaly of the odontoid process is the os odontoideum, but there also is a spectrum of variations ranging from hypoplasia to complete aplasia (1–9). Duplication of the odontoid process is rare, and the exact embryologic anomaly (or anomalies) leading to its occurrence is unknown. We present the plain radiographic and computed tomographic (CT) findings in a 6-year-old patient with duplication of the odontoid process.

## Case Report

A 6-year-old girl was unable to rotate her head more than approximately 20° to the right or left. She was otherwise healthy, and findings at neurologic examination were unremarkable.

Radiographs of the cervical spine (Fig 1A and B) showed complete duplication of the odontoid process. There was bony discontinuity of the posterior arch of C-1, and the anterior arch was hypertrophic. CT with multiplanar reformatting confirmed the plain film findings (Fig 1C–E). The appearance of the anterior arch of C-1 was due to the presence of a partly fused midline ossicle. In addition, partial fusion between the anterior lip of the foramen magnum and the anterior arch of the atlas was present (Fig 1C–E). The occipital condyles were unremarkable.

## Discussion

The odontoid process forms from different ossification centers. Two centers normally appear on each side of the midline around the fifth

or sixth month of fetal life (1–4). These two centers usually fuse by 1 year of age (2–4). When there is a delay in fusion, a longitudinal midline cleft may be seen (1, 4). Duplication of the odontoid process most likely is the result of a lack of fusion of these two centers of ossification (1–4).

The exact etiologic factors involved in the pathogenesis of the duplicated odontoid process are unknown. Mesenchymal anomalies or vascular insults are possible but remain hypothetical. Lack of midline fusion in patients older than 1 year has been attributed to regional immaturity (1). This terminology implies that the two ossification centers should eventually fuse. We agree that this is a likely scenario in some cases in which this lack of maturity represents an isolated finding. In our case, this hypothesis is unlikely given the associated anomalies of the atlas and skull base. Previous work describing the embryology of the developing spine (1–4) suggest that the anomalies in this patient could all be subsequent to abnormal resegmentation and/or migration of the craniovertebral sclerotomes.

Radiologic evaluation of suspected anomalies of the upper cervical spine and craniovertebral junction usually begins with plain film radiography. Flexion-extension radiographs may be added to detect abnormal spine motion. When anomalies are detected, as in this case, CT with multiplanar reformatting is ideal to further assess the craniovertebral junction.

## Acknowledgments

We extend our gratitude to R. S. Glikstein and R. del Carpio-O'Donovan for their help and valuable suggestions.

---

Received August 12, 1996; accepted after revision November 26.

From the Department of Medical Imaging, Montreal (Quebec, Canada) Children's Hospital, McGill University.

Address reprint requests to Marc Garant, MD, Department of Radiological Sciences, Neuroradiology Section, Room B2-188 CHS, UCLA Medical Center, 10833 Le Conte Ave, Los Angeles, CA 90095.

AJNR 18:1719–1720, Oct 1997 0195-6108/97/1809–1719 © American Society of Neuroradiology

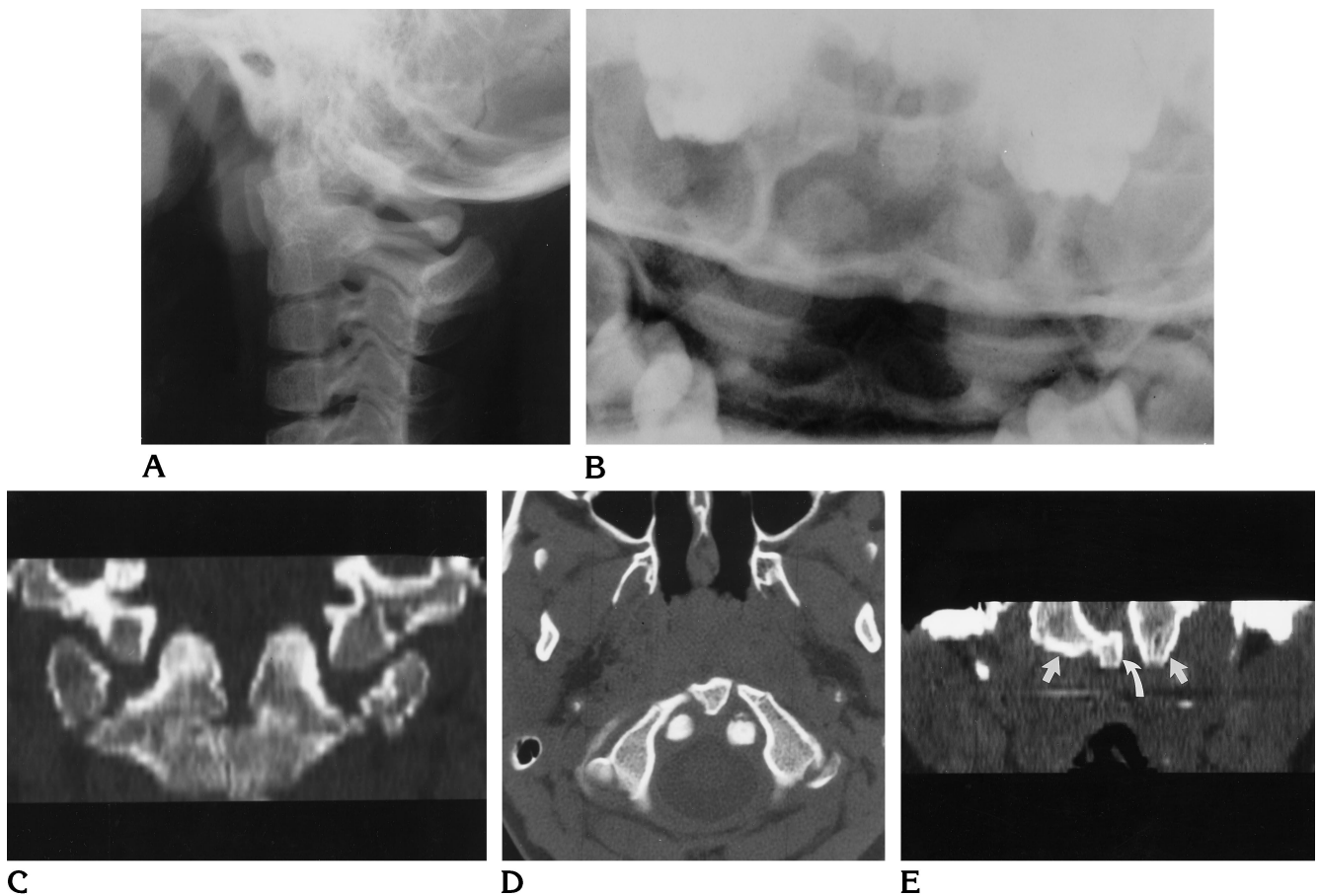


Fig 1. A 6-year-old girl with duplicated odontoid process.

A and B, On plain radiographs, lateral (A) and odontoid (B) views of the cervical spine show the duplicated odontoid process and hypertrophic anterior arch of C-1. The duplicated odontoid is appreciated only in B.

C-E, Reformatted coronal (C) and axial (D) CT scans show the duplicated odontoid process and midline ossicle of the anterior arch of C-1. Reformatted coronal CT scan (E) shows fusion of the anterior lip of the foramen magnum (straight arrows) and C-1 (curved arrow).

## References

1. Stevens JM, Chong WK, Barber C, Kendall BE, Crockard HA. A new appraisal of abnormalities of the odontoid process associated with atlanto-axial subluxation and neurological disability. *Brain* 1994;117:133-148
2. Crockard HA, Stevens JM. Craniovertebral junction anomalies in inherited disorders: part of the syndrome or caused by the disorder? *Eur J Pediatr* 1995;154:504-512
3. Truex RC Jr, Johnson CH. Congenital anomalies of the upper cervical spine. *Orthop Clin North Am* 1978;9:891-900
4. Hensinger RN, Fielding JW, Hawkins RJ. Congenital anomalies of the odontoid process. *Orthop Clin North Am* 1978;9:901-912
5. Gunther SF. Congenital anomaly of the cervical spine: fusion of the occiput, atlas, and odontoid process. *J Bone Joint Surg (Am)* 1980;62:1377-1378
6. Bernini FP, Muras I. Case report 332. *Skeletal Radiol* 1985;14:226-230
7. Ulmer JL, Elster AD, Ginsberg LE, Williams DW III. Klippel-Feil syndrome: CT and MR of acquired and congenital abnormalities of cervical spine and cord. *J Comput Assist Tomogr* 1993;17:215-224
8. Swischuk LE, Fagan CJ, Sarwar M. Persistence of the dens as the body of C1: a case report of a rare anomaly. *Radiology* 1978;127:330
9. Smoker WRK. Craniovertebral junction: normal anatomy, craniometry, and congenital anomalies. *Radiographics* 1994;14:255-277