

Are your **MRI contrast agents** cost-effective?

Learn more about generic **Gadolinium-Based Contrast Agents**.



**FRESENIUS  
KABI**

caring for life

**AJNR**

**Middle cerebral artery variations: duplicated and accessory arteries.**

M Komiyama, H Nakajima, M Nishikawa and T Yasui

*AJNR Am J Neuroradiol* 1998, 19 (1) 45-49

<http://www.ajnr.org/content/19/1/45>

This information is current as of April 20, 2024.

# Middle Cerebral Artery Variations: Duplicated and Accessory Arteries

Masaki Komiyama, Hideki Nakajima, Misao Nishikawa, and Toshihiro Yasui

**PURPOSE:** Our goal was to analyze the anatomic similarity between the duplicated middle cerebral artery (MCA) and the accessory MCA and their relationship to the early branches of the MCA.

**METHODS:** We reviewed stereoscopic angiograms of duplicated MCAs in four patients and accessory MCAs in four patients with reference to the origin, size, and cortical supply of these anomalous vessels, along with the presence of perforating arteries and the recurrent artery of Heubner (RAH).

**RESULTS:** The duplicated MCAs supplied the cortical territory of the temporopolar and the anterior temporal and/or middle temporal arteries. The accessory MCAs supplied the cortical territory of the orbitofrontal and/or prefrontal arteries. The duplicated MCAs had perforating arteries in three of four cases and coexisted with the RAH in three of four cases, whereas the main MCA had perforating arteries in all four cases. The accessory MCA had perforating arteries in all four cases and coexisted with the RAH in three of four cases, whereas the main MCA had perforating arteries in one of four cases.

**CONCLUSION:** A consistent cortical supply by the duplicated MCA and the accessory MCA to the anterior temporal lobe and the anterior frontal lobe, respectively, and its similarity to the cortical supply by the early branches of the MCA suggest that development of duplicated and/or accessory MCAs is an anomalously early ramification of the early branches of the MCA.

In 1962, Crompton (1) described the accessory middle cerebral artery (MCA), which included duplication of the MCA, and the anomalous vessel originating from the A1 portion of the anterior cerebral artery (ACA), which coursed parallel to the MCA. In 1973, Teal et al (2) proposed using the term *MCA duplication* to characterize the two vessels originating from the distal end of the internal carotid artery, and the term *accessory MCA* to describe the anomalous vessel originating from the ACA. We use Teal's classification because it is widely accepted. Although there are several explanations for the duplicated MCA and the accessory MCA (3–6), their embryologic origins are still an open question. The early branch of the MCA proximal to the bifurcation or the trifurcation supplies either the anterior temporal lobe or the anterior frontal lobe (7). We found a great similarity between the cortical territory of this early branch of the MCA and that of the duplicated or accessory MCA. This prompted us to review these anomalous vessels to postulate a theory as to their common origin. Knowledge of the anomalous ramification

of the MCA is important for the surgical treatment of cerebral aneurysms (1, 8–10) and for understanding the collateral blood supply in cerebral ischemia (11) associated with duplicated or accessory MCAs.

## Methods

We observed duplicated MCAs in four patients and accessory MCAs in four patients, who included five men and three women, 29 to 81 years of age (mean age, 60 years) (Table). Patients 1 through 4 were examined for an aneurysmal subarachnoid hemorrhage, patient 5 was examined for a brain tumor (craniopharyngioma), patient 6 was examined for paraganglioma in the nasal cavity, and patients 7 and 8 were examined for ischemic stroke. All the patients except patient 6 underwent four-vessel stereoscopic cerebral angiography. Two patients were studied by magnified cut-film angiography and the remaining six were examined by digital subtraction angiography. The duplicated and accessory MCAs were reviewed with special attention to the origin of the vessels, the size of the vessels at their origin, their course, the presence or absence of perforating arteries and the recurrent artery of Heubner (RAH), and the cortical distribution. We also determined the possibility of associated vascular lesions, such as cerebral aneurysms, vascular stenosis, and occlusion.

## Results

We encountered two duplicated MCAs and two accessory MCAs among 500 consecutive cerebral an-

---

Received February 14, 1997; accepted after revision June 17.

From the Department of Neurosurgery, Osaka City General Hospital, 2–13–22, Miyakojima-Hondouri, Miyakojima, Osaka 534 Japan. Address reprint requests to Masaki Komiyama, MD.

Summary of eight patients with duplicated or accessory middle cerebral arteries

Case	Age,y Sex	Anomalous Vessel	Origin of Dup/Acc MCA	Size				Course of Dup/ Acc MCA	Perforator of Dup/ Acc MCA	Perforator of Main MCA	RAH	Cortical Area	Associated Disease
				ICA	MCA	ACA	Dup/ Acc MCA						
1	29/M	Dup MCA	Proximal ICA	1.0	0.90	0.60	0.50	Parallel	+	+	+	TP, AT	ICA aneurysm
2	46/F	Dup MCA	Proximal ICA	1.0	0.76	0.71	0.29	Temporal swing	+	+	-	TP, AT	ICA aneurysm
3	67/F	Dup MCA	Proximal ICA	1.0	0.71	0.60	0.37	Temporal swing	+	+	+	TP, AT, MT	M1 aneurysm
4	66/M	Dup MCA	Proximal ICA	1.0	0.92	0.69	0.32	Temporal swing	-	+	+	TP, AT	MCA bifurcation aneurysm; Ant comm artery aneurysm
5	54/M	Acc MCA	Proximal ACA	1.0	0.87	0.72	0.37	Parallel	+	+	+	OF	Craniopharyngioma
6	81/F	Acc MCA	Proximal ACA	1.0	0.86	0.75	0.44	Parallel	+	-	+	OF, PF	Paraganglioma
7	63/M	Acc MCA	Distal ACA	1.0	0.69	0.71	0.26	Parallel	+	-	-	OF, PF	ICA and MCA occlusion
8	71/M	Acc MCA	Distal ACA	1.0	0.75	0.75	0.60	Parallel	+	-	+	OF, PF	ICA and MCA occlusion

Note.—ACA indicates anterior cerebral artery; Acc, accessory; Ant comm, anterior communicating; AT, anterior temporal; Dup, duplicated; ICA, internal carotid artery; MCA, middle cerebral artery; MT, middle temporal; OF, orbitofrontal; PF, prefrontal; RAH, recurrent artery of Heubner; and TP, tempopolar. Parallel means parallel to the horizontal portion of the middle cerebral artery; temporal swing means sharp anterior curve in the vessels in the sylvian fissure toward the temporal lobe.

giograms, indicating a prevalence of 0.4% for each. The size of the vessels is expressed as a relative value, in which the diameter of the internal carotid artery at its distal end is defined as 1.0. In patients 7 and 8, the internal carotid artery and the MCA were occluded by cardiogenic emboli, but preocclusion or postrecanalization angiography was available for measurement. A summary of the cases is provided in the Table.

The duplicated MCAs originated between the anterior choroidal artery and the distal end of the internal carotid artery (Figs 1 and 2). The relative size of the duplicated MCAs was 0.29 to 0.50, whereas that of the main MCA trunks was 0.71 to 0.92 mm. The duplicated MCA coursed in the sylvian fissure with an anterior sharp curve to the temporal lobe in three patients, or coursed parallel to the horizontal portion of the MCA in one patient. In both cases, the duplicated MCA reached the territory of the tempopolar and the anterior and/or middle temporal arteries. The duplicated MCA had perforating arteries in three of four cases. The main MCA had perforating arteries in all four cases. An ipsilateral RAH was observed in three of four cases. Ruptured cerebral aneurysms were discovered in all cases. The aneurysms were located between the duplicated MCA and the main MCA (patients 1 and 2), at the horizontal portion of the main MCA (patient 3), or at the bifurcation of the main MCA (patient 4). In patient 4, an additional unruptured aneurysm of the anterior communicating artery was also observed.

The accessory MCAs originated from the proximal A1 portion of the ACA in patients 5 and 6 (see Fig 3),

and from the distal A1 segment near the anterior communicating artery in patients 7 and 8 (see Fig 4). The accessory MCAs were smaller than the ACAs and the main MCAs in all four cases. The relative size of the accessory MCAs was 0.26 to 0.60 whereas that of the main MCAs was 0.69 to 0.87. In all cases, they coursed almost parallel to the main MCA trunks and terminated in the territory of the orbitofrontal artery in one case and in the territory of the orbitofrontal and prefrontal arteries in three cases. The accessory MCAs had perforating arteries in all four cases. The main MCA had perforating arteries in one of four patients. The RAH was observed in three of four cases. In patients 7 and 8, both the main MCA and the distal portion of the internal carotid artery were occluded by the cardiogenic emboli.

## Discussion

### Classification

The frequency of MCA duplication is reported to be 0.2% to 2.9% (1, 5, 10, 12–14); that of the accessory MCA, 0.3% to 4.0% (1, 13, 15, 16). In our series, the frequency of each of the anomalies was 0.4%. Teal et al (2) and Manelfe (cited in Abanou et al [4]) classified the duplicated MCA and the accessory MCA according to the origins of their vessels (Fig 5). Manelfe classified the accessory MCA into three types: type 1 is an anomalous vessel that arises from the internal carotid artery at a point proximal to its bifurcation (the duplicated MCA in Teal's classification), type 2 originates from the proximal portion of

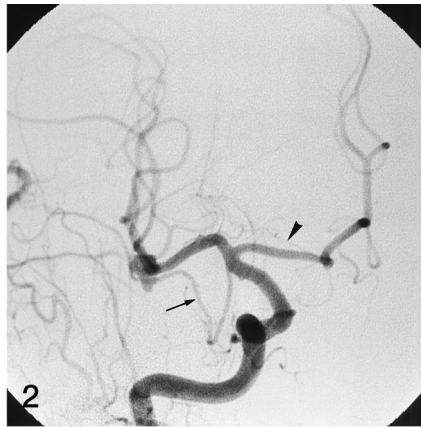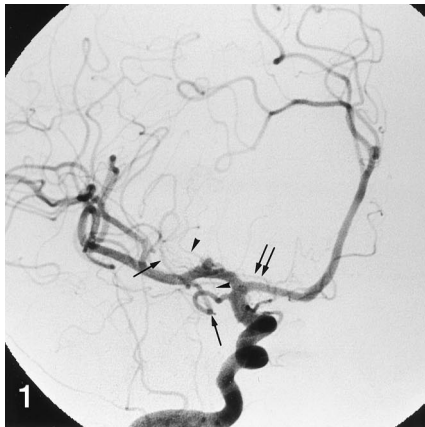


FIG 1. Patient 3: duplicated MCA in a 67-year-old woman with a ruptured aneurysm of the horizontal portion of the main MCA. *Single arrows* indicate the duplicated MCA that terminates in the temporopolar, anterior, and middle temporal territories. Both the main MCA and the duplicated MCA have perforating arteries. *Arrowheads* indicate the perforating artery, which originates from the duplicated MCA. *Double arrows* indicate the recurrent artery of Heubner.

FIG 2. Patient 4: duplicated MCA in a 66-year-old man with a ruptured aneurysm at the bifurcation of the MCA. The duplicated MCA (*arrow*) courses, with a sharp angle toward the temporal lobe, parallel to the main MCA. The duplicated MCA has no perforating artery and terminates in the temporopolar and anterior temporal territories. *Arrowhead* indicates the recurrent artery of Heubner.

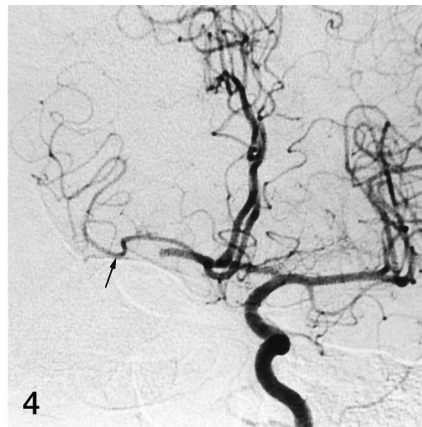
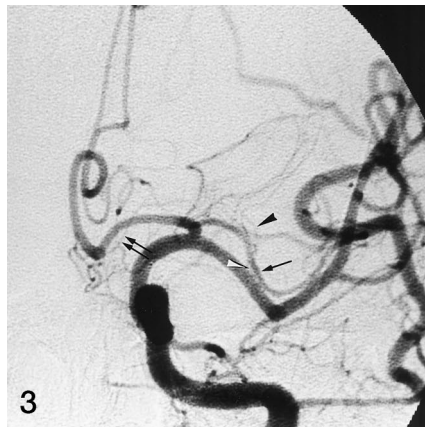

FIG 3. Patient 5: accessory MCA in a 54-year-old man with craniopharyngioma. The accessory MCA (*single arrow*) originates from the proximal portion of the anterior cerebral artery. This vessel has perforating arteries and terminates in the orbitofrontal territory. The main MCA also has perforating arteries (*arrowheads*). *Double arrows* indicate the recurrent artery of Heubner.

FIG 4. Patient 7: accessory MCA in a 63-year-old man with embolic occlusion of the distal internal carotid artery and the MCA. The accessory MCA (*arrow*) supplies the territories of the orbitofrontal and prefrontal arteries. The accessory MCA has perforating arteries. There is no recurrent artery of Heubner.

the ACA, and type 3 originates from the distal portion of the A1 segment of the ACA near the anterior communicating artery. It is often difficult to distinguish a duplication of the MCA from the accessory MCA originating from the proximal ACA (type 2 in Manelfe's classification). This is because the accessory MCA of Manelfe's type 2 can also be regarded as a variant of the duplicated MCA. Lasjaunias and Berenstein (6) modified Manelfe's classification. They regarded the accessory MCA of Manelfe's type 1 (the duplicated MCA in Teal's classification) as the main MCA, and the counterpart of the distal, main MCA as the accessory MCA. According to this classification, the accessory MCAs of type 1 and type 2 are identical except for the amount of cortical territory supplied by the accessory MCAs.

#### *Size and Presence of Perforating Arteries*

The duplicated MCAs were smaller than the main MCAs in our series; however, the main MCAs and the duplicated MCAs occasionally had the same diameter, or the main MCAs were smaller than the duplicated MCAs (1, 2, 7, 9, 10, 14). Although Abanou et al (4) and Lasjaunias and Berenstein (6)

reported that the duplicated MCA is a pure cortical vessel without perforating arteries, our results and those of others, conflict with this finding. Umansky et al (14) reported that both the duplicated MCA and the main MCA have perforating arteries to the anterior perforated substance. Crompton (1) observed that the duplicated MCAs occasionally have perforating arteries. We also noticed that the perforating artery arose from the duplicated MCA in three cases. It is generally accepted that the accessory MCA frequently has perforating arteries to the anterior perforated substance (7, 15, 17). Thus, we believe that both the duplicated MCA and the accessory MCA may have perforating arteries.

#### *Cortical Territories of the Accessory and Duplicated MCAs*

Teal et al (2) refer to the MCA that bifurcates within 0.5 cm from its origin as the early branching MCA, and they distinguish this from the duplicated MCA. Gibo et al (7) and Umansky et al (18) described the early branch of the MCA proximal to the bifurcation or the trifurcation supplying the temporal or frontal lobes. They found that the early branch to



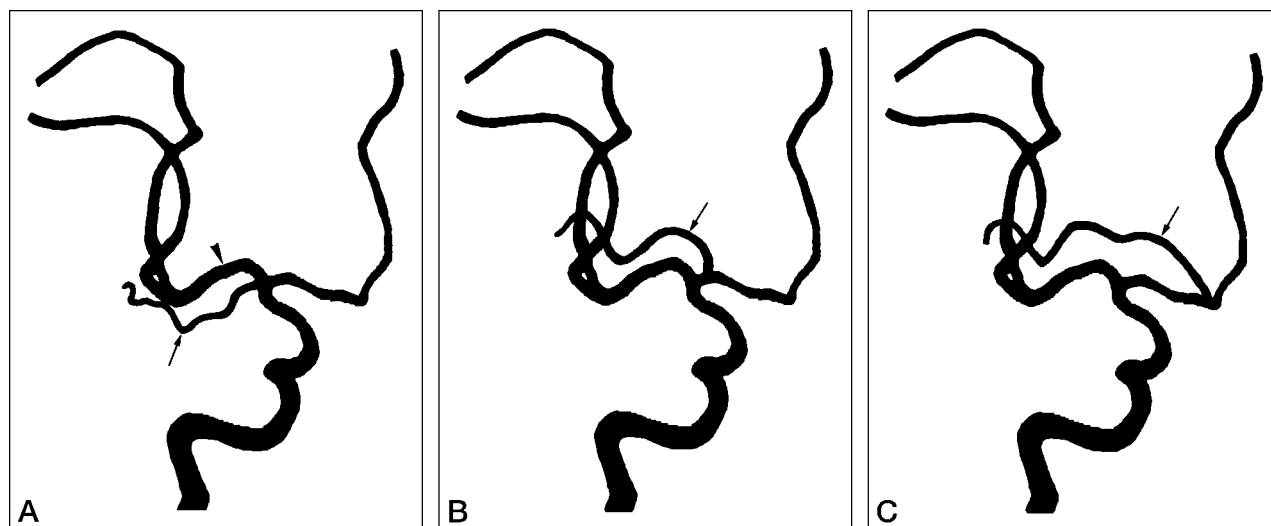


FIG 5. Classification of the duplicated and accessory MCA. By Teal's classification (2), arrow in A indicates the duplicated MCA and that in B and C the accessory MCAs. By Manelfe's classification (cited in Abanou et al [4]), arrow in A indicates the accessory MCA, type 1; that in B, type 2; and that in C, type 3. Lasjaunias and Berenstein (6) use Manelfe's classification, but they regard the artery indicated by the arrow in A as the main MCA while the artery indicated by the arrowhead is regarded as the accessory MCA.

the temporal lobe terminated in the temporopolar and anterior temporal areas; the early branch of the MCA to the frontal lobe supplied the orbitofrontal and prefrontal areas. In a study of the MCA's perforating arteries, Umansky et al (18) found that 5.3% of them originated from the early temporal branch and 0.4% originated from the early frontal branch. The early branches of the MCA may have the perforating arteries, as is the case with the duplicated and accessory MCA.

Jain (13) reported that both the duplicated MCA and the accessory MCA course in the sylvian fissure and supply the territory of the lateral part of the orbital surface of the frontal lobe. Abanou et al (4) reported that the duplicated MCA (Manelfe's type 1) and the accessory MCA that originates near the anterior communicating artery (Manelfe's type 3) have identical cortical supplies to the orbitofrontal area, and sometimes to the anterior temporal area. Other studies, as well as our own, show contradictory results. Gibo et al (7) described a patient who had both a duplicated and an accessory MCA in which the duplicated artery was distributed to the temporopolar and anterior and middle temporal areas, and the accessory MCA terminated in the orbitofrontal and prefrontal areas. Umansky et al (14) reported a case of duplication of the MCA in which the main MCA furnished blood supply to the frontal and parietal lobes while the duplicated MCA furnished it to the temporal lobe. The duplicated MCAs in our series consistently reached the temporopolar as well as the anterior and/or middle temporal territories. The accessory MCA supplied the territory of the orbitofrontal, prefrontal, precentral, and/or central arteries (11, 14, 16, 17). Thus, the cortical areas supplied by the early branches of the MCA are similar to those of the duplicated and accessory MCA, although the extent of vascular supply may vary.

#### *Origins of the Accessory MCA and the Duplicated MCA*

Phylogenetically, the MCA develops after the ACA, and the ACA is considered a continuation of the primitive internal carotid artery. Thus, the MCA can be regarded as a branch of the ACA (6, 19). Embryologically, the MCA can be recognized in a 7- to 12-mm embryo as twigs from the internal carotid artery proximal to the ACA. By the 16- to 18-mm stage, the MCA has become more prominent and supplies branches that spread over the cerebral hemisphere (20).

Several explanations have been offered for the development of the accessory MCA. Handa et al (3) thought it to be a hypertrophied RAH. Takahashi et al (5) extended Abbie's idea that the RAH is phylogenetically the remnant vessel between the ACA and the MCA (8) by arguing that the accessory ACA is a remnant anastomotic vessel between the ACA and the MCA. Tran-Dinh (17) supported Handa's explanation, but Teal et al (2) disagreed with Handa on the grounds that a) the perforating arteries do not always originate from the accessory MCA, b) the RAH coexists with the accessory MCA, and c) the accessory MCA courses lateral to the anterior perforating substance where the RAH enters. The fact that the accessory MCA frequently has perforating arteries and that the RAH can be multiple (16, 21, 22) calls these objections into question.

Manelfe (cited in Abanou et al [4]) hypothesized that the duplicated MCA and the accessory MCA begin as an outward budding of the internal carotid artery and the ACA, respectively, and then undergo development as a distinct entity with constant cortical supply. Although we support this idea, Manelfe's description of the accessory MCA of type 1 and type 3, which have identical cortical supplies, is contradictory

to our results. Lasjaunias and Berenstein (6) explained by phylogenetic analysis that the accessory MCA (Manelfe's type 2 and 3) and the main (distal) MCA (Manelfe's type 1) can be regarded as an enlarged RAH or RAH-like vessel with cortical supply. They thought that the accessory MCAs have the perforating arteries while the duplicated MCAs are purely cortical branches, without perforating arteries. Duplicated MCAs, however, may have perforating arteries.

As stated above, the MCA may be regarded as a branch of the ACA phylogenetically. Owing to a similar cortical supply, we believe that the duplicated MCA is embryologically the anomalously early ramification of the early branch of the MCA, which originates from the distal end of the internal carotid artery. The duplicated MCA may have perforating arteries and can coexist with the RAH. It consistently supplies the anterior temporal lobe. Similarly, we believe that the accessory MCA is the anomalously early ramification of the early branch of the MCA, which originates from the A1 portion of the ACA. The accessory MCA may have perforating arteries and can coexist with the RAH. It consistently supplies the anterior frontal lobe. Thus, anomalously early ramification of the early branch of the MCA may occur either proximal or distal to the origin of the main MCA trunk as suggested by Manelfe (cited in [4]). In the proximal location, the early branch runs to the anterior temporal lobe as the duplicated MCA. In the distal location, it runs to the anterior frontal lobe as the accessory MCA.

#### *Associated Vascular Lesions and Clinical Significance*

An association between the duplicated MCA, or the accessory MCA, and cerebral aneurysms has been well documented (1, 8–10). It is not clear whether this association is a chance occurrence or whether they are related by an unknown mechanism. The four patients in our series had ruptured aneurysms in association with duplicated MCAs. In practice, it is not surgically challenging to treat these aneurysms, but preoperative recognition of such vascular anomalies is important. In ischemic stroke, the accessory MCA can be a collateral to the anterior frontal lobe, but it cannot supply enough flow to the main MCA territory (11). Similarly, the duplicated MCA can be a collateral to the anterior temporal lobe, but it does not seem to supply enough flow to the main MCA territory.

#### **Conclusions**

On the basis of our observations of duplicated MCAs and accessory MCAs, we postulate that duplication of the MCA is the anomalously early ramification of the early branch of the MCA supplying the anterior temporal lobe and that the accessory MCA is the anomalously early ramification of the early branch of the MCA supplying the anterior frontal

lobe. Knowledge of anomalous early ramification of the MCA is important in the surgical dissection of cerebral aneurysms and in understanding the collateral blood supply in ischemic stroke associated with duplicated or accessory MCAs.

#### **Acknowledgment**

We thank James Sweet, Georgetown University, Washington, DC for assistance in the preparation of this manuscript.

#### **References**

1. Crompton MR. **The pathology of ruptured middle-cerebral aneurysms with special reference to the differences between the sexes.** *Lancet* 1962;2:421–425
2. Teal JS, Rumbaugh CL, Bergeron RT, Segall HD. **Anomalies of the middle cerebral artery: accessory artery, duplication, and early bifurcation.** *AJR Am J Roentgenol* 1973;118:567–575
3. Handa J, Shimizu Y, Matsuda M, Handa H. **The accessory middle cerebral artery: report of further two cases.** *Clin Radiol* 1970;21:415–416
4. Abanou A, Lasjaunias P, Manelfe C, Lopez-Ibor L. **The accessory middle cerebral artery (AMCA): diagnostic and therapeutic consequences.** *Anat Clin* 1984;6:305–309
5. Takahashi S, Hoshino F, Uemura K, Takahashi A, Sakamoto K. **Accessory middle cerebral artery: is it a variant form of the recurrent artery of Heubner?** *AJNR Am J Neuroradiol* 1989;10:563–568
6. Lasjaunias P, Berenstein A. **Internal Carotid Artery (ICA) Anterior Division, III: Surgical Neuroangiography.** Berlin, Germany: Springer-Verlag; 1990:111–151
7. Gibo H, Carver CC, Rhoton AL, Lenkey C, Mitchell RJ. **Microsurgical anatomy of the middle cerebral artery.** *J Neurosurg* 1981;54:151–169
8. Stabler J. **Two cases of accessory middle cerebral artery, including one with an aneurysm at its origin.** *Br J Radiol* 1970;43:314–318
9. Yasargil MG, Smith RD. **Association of middle cerebral artery anomalies with saccular aneurysms and moyamoya disease.** *Surg Neurol* 1976;6:39–43
10. Kwak R, Kuwahara K, Niizuma H, Suzuki J. **Anomalies of the middle cerebral artery with intracranial saccular aneurysms: duplication and fenestration.** *Neurol Surg (Tokyo)* 1979;7:691–696
11. Komiyama M, Nishikawa M, Yasui T. **The role of the accessory middle cerebral artery as a collateral blood supply.** *AJNR Am J Neuroradiol* 1997;18:587–590
12. Alpers BJ, Berry RG, Paddison RM. **Anatomical studies of the circle of Willis in normal brain.** *Arch Neurol Psychiatry* 1959;81:409–418
13. Jain KK. **Some observations on the anatomy of the middle cerebral artery.** *Can J Surg* 1964;7:134–139
14. Umansky F, Dujovny M, Ausman JI, Diaz FG, Mirchandani HG. **Anomalies and variations of the middle cerebral artery: a microanatomical study.** *Neurosurgery* 1988;22:1023–1027
15. Watanabe T, Togo M. **Accessory middle cerebral artery. Report of four cases.** *J Neurosurg* 1974;41:248–251
16. Marinkovic S, Milisavljevic M, Kovacevic M. **Anatomical bases for surgical approach to the initial segment of the anterior cerebral artery: microanatomy of Heubner's artery and perforating branches of the anterior cerebral artery.** *Surg Radiol Anat* 1986;8:7–18
17. Tran-Dinh H. **The accessory middle cerebral artery: a variant of the recurrent artery of Heubner (A. centralis longa)?** *Acta Anat* 1986;126:167–171
18. Umansky F, Gomes FB, Dujovny M, et al. **The perforating branches of the middle cerebral artery: a microanatomical study.** *J Neurosurg* 1985;62:261–268
19. Abbie AA. **The morphology of the fore-brain arteries, with especial reference to the evolution of the basal ganglia.** *J Anat* 1934;68:433–470
20. Padget DH. **The development of the cranial arteries in the human embryo.** *Contrib Embryol* 1948;32:205–261
21. Ahmed DS, Ahmed RH. **The recurrent branch of the anterior cerebral artery.** *Anat Rec* 1967;157:699–700
22. Gomes F, Dujovny M, Umansky F, et al. **Microsurgical anatomy of the recurrent artery of Heubner.** *J Neurosurg* 1984;60:130–139