

**Are your MRI contrast agents cost-effective?**

Learn more about generic Gadolinium-Based Contrast Agents.



**FRESENIUS  
KABI**

caring for life

**AJNR**

**Internal carotid artery narrowing in children with retropharyngeal lymphadenitis and abscess.**

P A Hudgins, J H Dorey and I N Jacobs

*AJNR Am J Neuroradiol* 1998, 19 (10) 1841-1843

<http://www.ajnr.org/content/19/10/1841>

This information is current as of April 19, 2024.

# Internal Carotid Artery Narrowing in Children with Retropharyngeal Lymphadenitis and Abscess

Patricia A. Hudgins, Jason H. Dorey, and Ian N. Jacobs

**BACKGROUND AND PURPOSE:** Our purpose was to describe the association between narrowing of the internal carotid artery (ICA) and retropharyngeal abscess in children.

**METHODS:** Neck CT scans from 13 consecutive children with suppurative retropharyngeal lymphadenitis and abscess were evaluated retrospectively for asymmetric ICA diameters at the level of the abscess. Clinical status at the time of illness was established via a chart review. Twenty control CT scans obtained from pediatric patients with normal imaging findings were evaluated prospectively to determine symmetry and size of the ICA.

**RESULTS:** Mean diameter of the normal ICA, contralateral to the retropharyngeal abscess, was 5 mm (range, 3–8 mm), while mean diameter ipsilateral to the abscess was 3 mm (range, 1–5 mm). The diameters of the normal and abnormal ICAs were statistically significantly different. All children were neurologically normal. The right and left ICAs in children with normal CT findings in the neck were symmetrical in diameter.

**CONCLUSION:** Despite dramatic narrowing of the ICA ipsilateral to retropharyngeal lymphadenitis and abscess, no children in this series had neurologic deficits, suggesting that such narrowing is a common, benign, and, most likely, incidental imaging finding.

Retropharyngeal abscess, a collection of purulent fluid in the retropharyngeal space, is thought to occur in the pediatric population after nasopharyngitis or middle ear infection spreads to the retropharyngeal nodes, which then may suppurate and rupture (1). Although frank abscess via this mechanism is now less common than in the past, owing to earlier diagnosis and treatment with broad-spectrum antibiotics, retropharyngeal inflammatory disease still occurs. Lateral neck radiographs, once the mainstay of diagnosis of retropharyngeal abscess, have been replaced by cross-sectional imaging, especially when complications of abscess are suspected clinically (2–4).

Complications of retropharyngeal abscess can be life-threatening; they include airway compromise, mediastinitis, pneumonia, empyema, pyopneumothorax, purulent pericarditis, and transverse myelopathy

(2, 5, 6). Internal carotid artery (ICA) rupture associated with retropharyngeal abscess has been described, but is uncommon with the wide availability of antibiotics (7, 8). To our knowledge, neurologic deficits arising from vasospasm of the ICA have not been reported as a complication of retropharyngeal abscess. The purpose of this study was to determine the effects of retropharyngeal abscess on the cervical ICA as well as the potential neurologic sequelae from compromise of this vessel.

## Methods

Thirteen consecutive pediatric patients with retropharyngeal abscess constituted the study population. Eight subjects were girls and five were boys; ages ranged from 3 months to 17 years. Five patients were 2 years old or younger, six were 2 to 5 years old, and two were older than 5 years (one was 5½ and one was 17). The duration of symptoms before medical attention was sought ranged from 2 to 4 days (mean, 3.3 days). Symptoms included fever, stiff neck, irritability, stridor, increased respiratory rate, dysphagia, and torticollis. Twelve of the 13 patients underwent incision and drainage; one patient was treated with antibiotics alone. The most common organism isolated (five patients) was  $\beta$ -hemolytic streptococcus. Other organisms included gram-negative aerobes and a variety of anaerobes. In all children, preoperative neurologic examinations were performed by the pediatric otolaryngologist, the otolaryngology resident, and the attending emergency room physician, and consisted of evaluation of level of consciousness, cranial nerve involvement, and sensorimotor function.

Received November 17, 1997; accepted after revision July 2, 1998.

Presented at the annual meeting of the Radiological Society of North America, Chicago, November 1995.

From the Department of Radiology, Emory University School of Medicine (P.A.H.); the Department of Radiology, P.O. Box 412, Fairhope, AL (J.H.D.); and the Department of Otolaryngology, Children's Hospital of Pittsburgh, PA (I.N.J.).

Address reprint requests to Patricia A. Hudgins, MD, Department of Radiology, Section of Neuroradiology, Emory University School of Medicine, 1364 Clifton Rd, NE, Atlanta, GA 30322.

All patients had preoperative contrast-enhanced CT scans of the neck. All CT studies were performed after intravenous administration of 2 mL/kg of nonionic contrast material via a hand bolus and drip technique during quiet respiration; mAs was 200, kV(p) was 120, and section thickness was 3 mm. Four patients had spiral CT and nine had conventional CT. For the spiral CT studies, a pitch of 1 was chosen, and reconstruction intervals were 3 mm. Both soft tissue and bone windows were photographed.

A retrospective review was performed by two experienced neuroradiologists for the presence of a retropharyngeal necrotic or suppurative lymph node as well as for retropharyngeal fluid. The ICA ipsilateral to the suppurative node was measured at the narrowest portion, using hand-held calipers. This level was usually either the lower nasopharyngeal or upper portion of the oropharynx and was chosen by consensual agreement between the two readers. The diameter of the contralateral ICA was measured at the same level. Any displacement of the vessel by the inflammatory process or distortion of fat surrounding the vessel was also noted. Other characteristics that were assessed were the presence, size, and level of other adenopathy, and the degree of airway compromise. All neck CT scans included the brain. The studies were assessed for ventricular size and presence of intra- or extraaxial lesions.

Twenty pediatric patients who had normal findings on CT scans of the neck constituted the control population. All control subjects were imaged with similar CT scan parameters after IV administration of contrast material. The diameter of the ICA was measured using a similar technique and at a similar level.

## Results

All CT scans revealed prominence of both left and right retropharyngeal nodes. In all children, although both nodes were prominent, the findings were asymmetric, with central low density and surrounding soft-tissue fullness evident in one node (six on the right side, seven on the left). The contralateral retropharyngeal node was solid in appearance, without central low density, and was thought to be a reactive node without suppuration. Distortion of fat planes was evident around the ICAs on all scans on the side of infection. All scans revealed a low-density fluid collection in the retropharyngeal space, with no significant peripheral enhancement, no septa, and extension of the collection across the midline. None of the collections extended caudally into the thoracic retropharyngeal space or the mediastinum. Nonsuppurative, reactive nodes were seen in all children in the submandibular/submental chain, the high and mid jugular chains, and the posterior triangle (levels I, II, III, and V).

The mean diameter of the ICA ipsilateral to the suppurative node was 3 mm (range, 1–5 mm) (see Table). Contralateral to the lesion, on the uninvolved side, the mean diameter of the ICA was 5 mm (range, 3–8 mm) (Fig 1). In summary, the normal and abnormal ICAs were statistically significantly different at the  $P < .001$  level. Therefore, the diameter of the ipsilateral ICA was decreased by an average of 53% and in some cases by as much as 80% relative to the unaffected side (Fig 2). In only one case were the ICA diameters equivalent. The distal ICAs in the post-styloid region resumed normal caliber and were equivalent in size to the contralateral ICAs. In all cases the narrowed ICA ipsilateral to the suppurated retropharyngeal lymph node was displaced in either a poste-

**ICA diameter (mm) in 13 children with retropharyngeal lymphadenitis and abscess**

Age (y)	Ipsilateral to Infection	Normal
1 to 2		
	4	8
	2	4
	3	3
	2	6
	2	5
2 to 5		
	4	6
	1	5
	2.5	3
	3	5
	5	8
	3	6
Older than 5		
	2.5	6
	3	6

rior or lateral direction by the retropharyngeal abscess. Enhancement within the arteries was homogeneous, with no suggestion of thrombosis. The ipsilateral internal jugular veins were also displaced posterolaterally and appeared flattened from mass effect. All enhanced normally without evidence of thrombosis.

CT scans in the control population were obtained either for lymphoma staging or suspected neck mass. One of these 20 control subjects was younger than 2 years old, five were less than 5 years old, and 14 were between 5 and 19 years old. Although older control subjects constituted the majority of this population, our goal in assessing this group was not to determine the normal size of the ICA on CT scans but to establish symmetry in size within individuals. All CT findings in this population were normal. Among control subjects, ICAs were symmetrical in size, with a mean diameter of 5.5 mm for both the right and left ICAs at the oropharyngeal level. These findings were statistically significant in that there was no variation in size between the two sides in the same patient ( $P < .001$ ).

A retrospective chart review of the preoperative neurologic examination showed that no child had a neurologic deficit. Findings on head CT scans, performed in all patients, were normal. All patients recovered from the retropharyngeal inflammatory process with no neurologic deficits.

## Discussion

Despite the widespread availability of antibiotics, retropharyngeal infection after nasopharyngitis or middle ear infection is still encountered in the pediatric population. Bacterial pharyngitis, involvement of retropharyngeal nodes, suppuration of the nodes, and rupture into the suprahyoid retropharyngeal space are thought to be the sequence of events leading to retropharyngeal abscess in children (1, 9).

Complications of retropharyngeal abscess include airway compromise, mediastinitis, rupture and aspira-

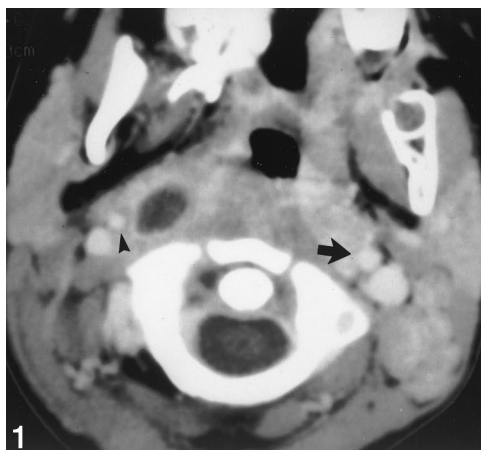


FIG 1. 1-year-old child with retropharyngeal lymphadenopathy and abscess. Note the suppurative right retropharyngeal node medial to the right ICA (arrowhead), which is smaller in diameter than the left ICA (arrow). Right ICA diameter, 4 mm; left ICA diameter, 8 mm.

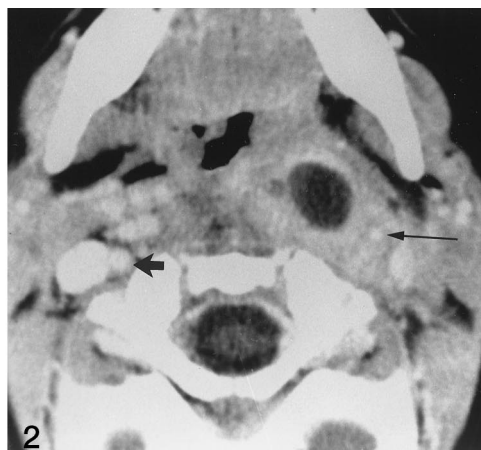


FIG 2. 2½-year-old child with left retropharyngeal lymphadenopathy. Note marked narrowing of the left ICA (long arrow), perivascular enhancing inflammatory soft tissue, and lateral displacement of the ICA and jugular vein. Right ICA is normal (short arrow). Left ICA diameter, 1 mm; right ICA diameter, 5 mm.

tion of purulent material, and empyema. Neurologic complications are rare. Epidural abscess and transverse myelopathy are spinal complications that have been reported (5). Both are likely to be more common when the retropharyngeal abscess follows osteomyelitis/diskitis rather than pharyngeal infection.

Arterial complications of head and neck infections are rare, whereas venous complications are more common. Septic thrombophlebitis, especially jugular vein thrombosis, is a known sequela of deep neck infections (10). Jugular thrombophlebitis, or Lemierre syndrome, affects adolescents following oropharyngeal infection and is caused by fusobacterium septicemia (11). Although carotid artery rupture and hemorrhage have been reported as a complication of deep neck abscess (7, 8, 12), to our knowledge, this is the first report of ICA diameter narrowing secondary to retropharyngeal abscess in the pediatric population. The narrowing may have resulted from simple mass effect, as all the involved vessels were displaced posteriorly or laterally. Spasm associated with the surrounding inflammatory process is another explanation. Inflammatory changes within the vessel wall could also account for the decrease in lumen diameter.

Despite the changes in diameter of the ICAs, none of the children had neurologic deficits, and all had normal findings on head CT scans. There are several possible explanations for the lack of deficit despite arterial narrowing. In adult patients, even complete occlusion of the ICA does not always result in stroke, either because of an intact circle of Willis or because of the recruitment of collaterals from another intracranial supply or from one external carotid artery to the ICA. In children, the leptomeningeal collaterals are particularly robust. Most cerebral infarctions in adults are a result of emboli from plaque at the bifurcation. In the child with relatively abrupt narrowing from spasm, plaque development, ulceration, platelet aggregation, and intraplaque hemorrhage presumably do not occur and therefore neither does embolic stroke.

## Conclusion

We reported the findings in 13 consecutive children with retropharyngeal suppurative lymphadenitis and associated retropharyngeal space abscess following pharyngeal infection. All had narrowing and displacement of the ICA ipsilateral to the suppurated retropharyngeal node. Despite narrowing of the ICA, none had neurologic deficits, suggesting that this is a common, benign, and, most likely, incidental imaging finding.

## References

1. Sneed WF, Miller RH, Mintz AA. **Retropharyngeal pseudomasses.** *South Med J* 1984;77:528–538
2. Ravindranath T, Janakiraman N, Harris V. **Computed tomography in diagnosing retropharyngeal abscess in children.** *Clinical Pediatr* 1993;32:242–244
3. Ungkanont K, Yellon RF, Weissman JL, et al. **Head and neck space infections in infants and children.** *Otolaryngol Head Neck Surg* 1995;112:375–382
4. Glasier CM, Stark JE, Jacobs RF, et al. **CT and ultrasound imaging of retropharyngeal abscesses in children.** *AJNR Am J Neuroradiol* 1992;13:1191–1195
5. Heilbronn YD, Tovi F, Hirsh M, Ronen J. **Transverse cervical myelopathy: an unusual complication of retropharyngeal abscess.** *Head Neck Surg* 1984;6:1051–1053
6. Watanabe M, Ohshika Y, Aoki T, et al. **Empyema and mediastinitis complicating retropharyngeal abscess.** *Thorax* 1994;49:1179–1180
7. Salinger S, Pearlman SJ. **Hemorrhage from pharyngeal and peritonsillar abscess.** *Arch Otol* 1933;18:464–509
8. Alexander DW, Leonard JR, Trail ML. **Vascular complications of deep neck abscess.** *Laryngoscope* 1968;78:361–370
9. Mukherji SK, Holliday RA. **Retropharyngeal infections.** In: Som PM, Curtin HD, eds. *Head and Neck Imaging*. 3rd ed. St. Louis: Mosby-Year Book; 1996;1:460–461
10. Barratt GE, Koopmann CF, Coulthard SW. **Retropharyngeal abscess: a ten-year experience.** *Laryngoscope* 1984;94:455–463
11. De Sena S, Rosenfeld DL, Santos S, Keller I. **Jugular thrombophlebitis complicating bacterial pharyngitis (Lemierre's syndrome).** *Pediatr Radiol* 1996;26:141–144
12. Mafee MF. **Infections of the neck.** In: Valvassori GE, Buckingham RA, Carter BL, Hanafee WN, Mafee MF, eds. *Head and Neck Imaging*. New York: Thieme Medical; 1988:264–265