

Are your **MRI contrast agents** cost-effective?

Learn more about generic **Gadolinium-Based Contrast Agents**.



**FRESENIUS
KABI**

caring for life

AJNR

Systemic sarcoidosis with bilateral orbital involvement: MR findings.

E M Simon, G H Zoarski, M I Rothman, Y Numaguchi, M T Zagardo and J M Mathis

AJNR Am J Neuroradiol 1998, 19 (2) 336-337

<http://www.ajnr.org/content/19/2/336>

This information is current as of April 19, 2024.

Systemic Sarcoidosis with Bilateral Orbital Involvement: MR Findings

Erin M. Simon, Gregg H. Zoarski, Michael I. Rothman, Yuji Numaguchi,
Michael T. Zagardo, and John M. Mathis

Summary: A 43-year-old woman with diplopia had a disconjugate gaze on physical examination. MR images revealed enlarged, abnormally enhancing extraocular muscles and lacrimal glands bilaterally. Biopsy results were consistent with sarcoidosis. Chest radiographs and CT scans were normal. Clinical and MR findings improved after appropriate medical therapy.

Sarcoidosis is a well-described entity with protean manifestations, usually presenting in adults in their third through fifth decades (1, 2). Noncaseating granulomas, the histopathologic hallmark of the disease, have been reported in nearly every organ. Most commonly affected are the hilar and paratracheal lymph nodes, pulmonary parenchyma, skin, and eyes (3). Twenty to twenty-five percent of all patients have ophthalmic involvement; 7% to 19% of patients with systemic disease present with ocular symptoms (2, 4). Isolated orbital disease is uncommon and is usually limited to the lacrimal glands. Extralacrimal sarcoidosis is rare and, when present, is nearly always unilateral (3, 5). We describe the magnetic resonance (MR) imaging findings in a case of bilateral orbital involvement as the initial manifestation of systemic sarcoidosis.

Case Report

A 43-year-old woman was referred to our institution for evaluation of horizontal and vertical diplopia that began after an episode of eyelid swelling and blurred vision 3 months earlier. The patient had no significant medical history. Physical examination revealed disconjugate eye movement. Computed tomographic (CT) examination of the orbits showed enlarged extraocular muscles. MR imaging of the brain and orbits performed on a 1.5-T scanner revealed enlargement of the superior and lateral rectus muscles bilaterally. The MR studies included sagittal T1-weighted (450/16/1 [repetition time/echo time/excitations]), axial and coronal T1-weighted (650/11/2) sequences, and proton density-(2500/30/1) and T2-weighted (2500/90/1) whole-brain sequences; and axial noncontrast and contrast-enhanced fat-suppressed T1-weighted 3-mm orbital sequences. The right inferior rectus and left medial rectus muscles were also enlarged. The lacrimal glands were enlarged bilaterally and showed prominent abnormal enhancement. The extraocular muscles showed markedly diminished signal on T2-weighted images. The intraconal fat, optic nerves, and sclera were normal (Fig 1A-D).

Thyroid function tests, routine blood chemistries, complete blood count, erythrocyte sedimentation rate, antinuclear anti-

bodies, and rheumatoid factor were normal. Chest radiographs and CT scans, serum lysozyme, and serum calcium levels were normal. Serum angiotensin-converting enzyme (ACE) level was elevated at 162 U/L (normal, 14 to 63 U/L).

A biopsy was performed of the left lacrimal gland and left medial rectus muscle. Microscopic examination of tissue from both areas revealed multiple, well-defined, noncaseating granulomas with macrophages, multinucleated giant cells, and lymphocytes in both specimens, consistent with sarcoidosis.

After 8 weeks, following a course of oral prednisone and very slow taper, the patient reported marked clinical improvement with normal extraocular movements and only mild residual vertical diplopia. Repeat MR examination revealed marked interval reduction in size of the extraocular muscles and lacrimal glands, despite mild persistent abnormal enhancement in the left medial and superior rectus muscles and diminished T2-weighted signal intensity throughout the extraocular muscles (Fig 1E-G). Serum ACE level decreased to 63 U/L.

Discussion

Ophthalmologic involvement in sarcoidosis is frequent. Anterior uveitis, the most common manifestation, occurs in up to 85% of patients; posterior uveitis is the most common cause of visual morbidity (4, 6). Other manifestations are less frequently encountered and include lacrimal gland infiltration; optic nerve, chiasmatic, and/or sheath involvement; retrobulbar masses; exophthalmos; proptosis; eyelid swelling and palpable lid masses; optic radiation (meningovascular) infiltration; and bone destruction (5, 7-11). Extraocular muscle involvement is rare but has been reported (5, 6).

Stannard et al (6) described a 39-year-old man with extraocular muscle enlargement with tendinous involvement, among other manifestations. The imaging description in that case was based only on orbital CT findings. Carmody et al (5) described the MR findings in 15 patients with presumed ($n = 3$) or proved ($n = 12$) ophthalmologic sarcoidosis. Three patients had MR evidence of lacrimal disease, defined by gland enlargement, isointense signal relative to muscle on T1-weighted images, hypointense signal on T2-weighted images, and homogeneous enhancement. In two patients, these findings were bilateral. One patient also had extraocular muscle infiltration on MR images that was "markedly hypointense" on T2-weighted images. Although contrast material was not administered in this case, the authors concluded that it should be used whenever ophthalmologic sarcoidosis is among the differential diagnostic considerations and, in the proper clinical setting, these patients can be given a trial of steroids, which may be valuable in noninvasively distinguishing orbital sarcoidosis

Received September 6, 1996; accepted after revision January 16, 1997.

From the Department of Diagnostic Radiology, University of Maryland Medical Center, Baltimore (E.M.S., G.H.Z., M.I.R., Y.N., M.T.Z., J.M.M.), and the Department of Diagnostic Radiology, University of Rochester (NY) Medical Center (Y.N.).

Address reprint requests to Gregg H. Zoarski, MD, Diagnostic Radiology, University of Maryland Medical Center, 22 S Greene St, Baltimore, MD 21201.

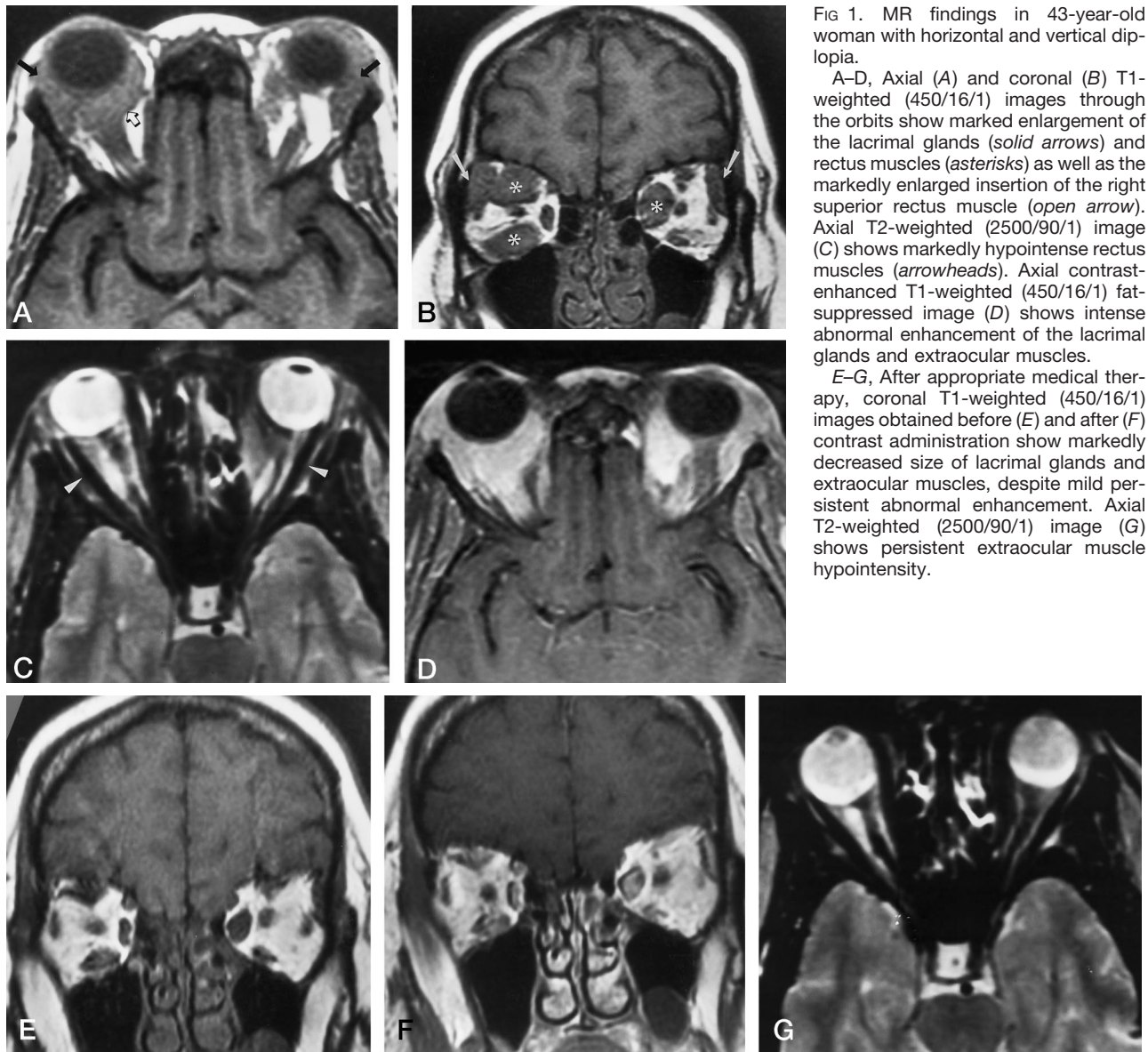


FIG 1. MR findings in 43-year-old woman with horizontal and vertical diplopia.

A–D, Axial (A) and coronal (B) T1-weighted (450/16/1) images through the orbits show marked enlargement of the lacrimal glands (solid arrows) and rectus muscles (asterisks) as well as the markedly enlarged insertion of the right superior rectus muscle (open arrow). Axial T2-weighted (2500/90/1) image (C) shows markedly hypointense rectus muscles (arrowheads). Axial contrast-enhanced T1-weighted (450/16/1) fat-suppressed image (D) shows intense abnormal enhancement of the lacrimal glands and extraocular muscles.

E–G, After appropriate medical therapy, coronal T1-weighted (450/16/1) images obtained before (E) and after (F) contrast administration show markedly decreased size of lacrimal glands and extraocular muscles, despite mild persistent abnormal enhancement. Axial T2-weighted (2500/90/1) image (G) shows persistent extraocular muscle hypointensity.

from other neoplastic, granulomatous, and infiltrative disorders (5). As reported by Atlas et al (12), the lack of hyperintensity on T2-weighted sequences may favor a diagnosis of benign infiltration, such as sarcoidosis or pseudotumor, over malignant diseases, such as lymphoma or metastasis. Of their 15 patients, 10 of 11 studies performed in patients with these more benign processes showed isointense signal relative to normal muscle or fat on T2-weighted images. Interestingly, the MR studies in our patient manifested markedly diminished T2-weighted signal intensity in the involved structures relative to fat and muscle, which persisted after successful treatment with steroids.

In conclusion, although biopsy is often required, the diagnosis of orbital sarcoid should be considered in patients with MR evidence of extraocular muscle enlargement either with or without lacrimal gland disease.

References

1. Hoover DL, Khan JA, Giangiacomo J. **Pediatric ocular sarcoidosis.** *Surv Ophthalmol* 1986;30:215–228
2. Obenaus CD, Shaw HE, Sydnar CF, Klintworth GK. **Sarcoidosis and its ophthalmic manifestations.** *Am J Ophthalmol* 1978;86:648–655
3. Collison JMT, Miller NR, Green WR. **Involvement of orbital tissues by sarcoid.** *Am J Ophthalmol* 1986;102:302–307
4. Som PM, Sacher M, Weitzner I, Lustgarten JS, Mindel J. **Sarcoidosis of the optic nerve.** *J Comput Assist Tomogr* 1982;6:614–616
5. Carmody RF, Mafee MF, Goodwin JA, Small K, Haery C. **Orbital and optic pathway sarcoidosis: MR findings.** *AJNR Am J Neuroradiol* 1994;15:775–783
6. Stannard K, Spalton DJ. **Sarcoidosis with infiltration of the external ocular muscles.** *Br J Ophthalmol* 1985;69:562–566
7. Imes RK, Reifschneider JS, O'Connor LE. **Systemic sarcoidosis presenting initially with bilateral orbital and upper lid masses.** *Ann Ophthalmol* 1988;20:466–469
8. Paina S, Gellmann E, Gazzocchi M. **Unilateral exophthalmos resulting from chronic sarcoidosis of the orbit with apparently no other localization.** *Ann Ital Med Intern* 1991;6:665–668
9. Queimadelos V, Arduan AO, Castrillo JM, Jimenez Casado M. **Cranial sarcoidosis with exceptional localization in the orbital vertex.** *Rev Clin Esp* 1990;187:399–403
10. Wolk RB. **Sarcoidosis of the orbit with bone destruction.** *AJNR Am J Neuroradiol* 1984;5:204–205
11. Signorini E, Cianciulli E, Ciorba E, Pelliccioli GP, Caputo N, Salvolini U. **Rare multiple orbital localizations of sarcoidosis: a case report.** *Neuroradiology* 1984;26:145–147
12. Atlas SW, Grossman RI, Savino PJ, et al. **Surface-coil MR of orbital pseudotumor.** *AJNR Am J Neuroradiol* 1987;8:141–146