

Efficacy of Fast Screening MR in Children and Adolescents with Suspected Intracranial Tumors

L. Santiago Medina, David Zurakowski, Katherine R. Strife, Richard L. Robertson,
Tina Young Poussaint, and Patrick D. Barnes

PURPOSE: Our purpose was to determine the sensitivity, specificity, and receiver operator characteristic (ROC) curve of a fast screening MR protocol in children and adolescents with suspected intracranial tumors.

METHODS: One hundred forty-one patients (mean age, 9.7 years; range, 2 months to 23.5 years) with suspected brain tumor were entered in a case-control study. Eighty-seven patients had intracranial tumors (31 suprasellar/hypothalamic, 27 supratentorial, 26 infratentorial, and three pineal) and 54 patients in the control group had other disorders. Two neuroradiologists reviewed blindly a detailed three-sequence conventional protocol (acquisition time, 8 minutes 27 seconds) and a two-sequence fast screening MR protocol (acquisition time, 4 minutes 44 seconds).

RESULTS: Sensitivity and specificity of the fast screening protocol for intracranial tumors was 100% and 92.6%, respectively. The areas under the ROC curves were 0.966 for the fast screening and 0.980 for the conventional MR protocol. No diagnostic performance difference was found between the ROC curves using the A_z index. A κ statistic of .93 for both examinations indicated excellent interobserver agreement. Additional MR sequences and other neuroimaging studies were not deemed necessary to exclude the presence of an intracranial tumor.

CONCLUSION: A fast dual-plane brain MR protocol may be adequate to screen children and adolescents thought to have an intracranial tumor. The less than 5 minute acquisition time allows a complete examination (including preparation) to be performed in 10 to 15 minutes. Future studies are recommended before this time-efficient neuroimaging examination is incorporated into clinical practice.

Brain tumors constitute the largest group of solid neoplasms in children and are second only to leukemia in their overall frequency during childhood (1, 2). However, their annual rate of occurrence is only about three per 100 000 (3). Intracranial tumors in children are notorious for their protean clinical manifestations, which may include headache, vomiting, irritability, and failure to thrive with or without a focal neurologic deficit (2, 3). Sixty-nine percent of children with brain tumors have associated headaches (4). On the other hand, headache is a very common symptom in childhood and adolescence, and is rarely

associated with an intracranial tumor. Migraine, one of the most common causes of headache, has a prevalence of 2.4% to 3.1% in childhood and increases to 6.4% to 14.8% in adolescence (5). Because the presence or absence of a brain tumor has a significant impact on patient management, clinicians rely heavily on the results of computed tomography (CT) and/or magnetic resonance (MR) imaging to determine the mode of treatment.

Faster CT scanners allow increased patient throughput, less sedation time, and lower per-patient cost. Disadvantages of CT include posterior fossa beam-hardening artifacts and potential reaction to iodinated contrast material and, to a lesser extent, ionizing radiation (6). MR imaging, with its high soft-tissue characterization, multiplanar capability, and lack of ionizing radiation, has emerged as a technically optimal imaging method (7). However, its higher sedation rate, added cost and time, hamper its universal use as the first imaging examination. Therefore, implementation of an accurate and more time-efficient imaging protocol at a lower per-patient cost

Received May 14, 1997; accepted after revision August 26.

Supported in part by a grant from the Society for Pediatric Radiology.

From the Department of Radiology, Children's Hospital Medical Center, 3333 Burnet Ave, Cincinnati, OH 45229.

Address reprint request to L. Santiago Medina, MD, MPH, Department of Radiology, Section of Health Services and Policy, Children's Hospital Medical Center, 333 Brunet Ave, Cincinnati, OH 45229.

TABLE 1: Brain MR Protocols

Protocol Pulse Sequence	Characteristics						
	TR/TE/ Excitations	Sections	Acquisition Time, min*	Matrix Size	Thickness, mm†	Field of View	Echo Train Length
Conventional							
Sagittal T1-weighted	600/11/2	14	3:41	256 × 128	5	24	...
Axial fast spin-echo proton density-weighted	2000/17/1	18	2:23	256 × 192	5	24	8
Axial fast spin-echo T2-weighted	3200/85/1	18	2:23	256 × 192	5	24	8
Fast screening							
Limited sagittal T1-weighted‡	300/11/2	7	2:21	256 × 128	5	24	...
Axial fast spin-echo T2-weighted	3200/85/1	18	2:23	256 × 192	5	24	8

* Includes autoprescan time.

† 2.5-mm gap.

‡ Expected parameters.

and without the risks of iodinated contrast material, sedation, and ionizing radiation is desirable.

To our knowledge, no large analytical studies have been performed in children or adolescents to determine the minimum number of MR sequences required to screen for an intracranial tumor. Hence, the number of MR sequences usually ranges from two to seven, depending on institutional preference.

Our current conventional brain MR protocol to exclude an intracranial tumor includes three routine sequences, for an actual acquisition time of 8 minutes 27 seconds. Images with short repetition time (TR)/echo time (TE) (T1-weighted), long TR/short TE (proton density-weighted), and long TR/TE (T2-weighted) are obtained in at least the axial and sagittal planes. Postcontrast T1-weighted images are obtained in selected cases in which further characterization of an intracranial tumor is required. In a pilot study of 315 children who had a brain MR study because of headache, 28 (9%) had brain tumors (8). Upon review of the cases, all intracranial lesions were identified on the axial fast spin-echo T2-weighted or limited midline-centered sagittal conventional spin-echo T1-weighted images.

We hypothesized that a fast screening MR protocol, with only axial fast spin-echo T2-weighted and limited midline-centered sagittal conventional spin-echo T1-weighted images, would have the same sensitivity for depicting intracranial tumors as the conventional MR protocol, and could be used as a screening neuroimaging examination. To test this hypothesis, we performed a case-control study with children and adolescents in whom a brain tumor was suspected. A blinded comparative analysis between the fast and conventional screening MR protocols was performed using as the standard of reference the final diagnosis as determined by a combination of clinical, histopathologic, laboratory, and imaging findings.

Methods

Subjects

One hundred and forty-one patients with suspected intracranial tumors were studied. The mean age was 9.7 years

(SD = 5.1 years), with a range of 2 months to 23.5 years. Twenty (14%) of the patients were less than 4 years old and 27 (19%) were between 4 and 7 years old. There were 77 boys (55%) and 64 girls (45%).

Study Design

A case-control study design was selected because of the low prevalence of intracranial tumors in children and adolescents (9). All patients in the study were referred for an MR examination to exclude a brain tumor. Clinical indications included a chief complaint of: headache in 105 (74%) of the 141 patients, colon severe vomiting in 15 (11%), gait abnormality in eight (6%), abnormal neurologic findings in seven (5%), and lethargy in six (4%). The medical history was obtained and examination was performed by a neurologist, neurosurgeon, or neurologist-in-training with an attending neurologist in 124 (88%) of the patients and by a pediatrician in 17 (12%). Patients with a history of CNS surgery, radiation therapy, or chemotherapy were excluded from the study.

The study population was divided into case and control groups. The case group included children with intracranial tumors of various sizes and histopathologic composition and in different anatomic locations. The control group included children and adolescents with other CNS disorders. All the control group patients were referred for an MR examination to exclude a brain tumor. The 1990–1996 neuroradiology database was stratified and a representative case mix for each study group was selected. Power analysis was performed to determine the sample size required to establish whether the protocols were equivalent (10).

All patients were studied on a 1.5-T system. Patients were examined with two different sets of brain MR protocols (Table 1). The conventional protocol set included the following three complete pulse sequences: sagittal conventional spin-echo T1-weighted, axial fast spin-echo proton density-weighted, and axial fast spin-echo T2-weighted images. The fast screening protocol set included only limited midline-centered images from the whole sagittal conventional spin-echo T1-weighted sequence (only seven from the total of 14 images) and all the images of the axial fast spin-echo T2-weighted sequence.

Study Analysis and Statistics

The fast and conventional screening protocols were interpreted independently by two experienced pediatric neuroradiologists who were blinded to the study population case mix, clinical data, and other imaging studies. All patient-identifying marks, including age, sex, or history, were covered with a black mask. In all cases, the fast screening protocol was interpreted first, followed by the conventional protocol. The cases were reviewed in random order with at least a 2-week interval be-

TABLE 2: Histopathology and Anatomic Location of Intracranial Tumors in 87 Patients

Location	Glial Tumors							Medulloblastoma
	Cerebellar	Craniocervical	Tectal	Brain Stem	Optic/ Hypothalamic	Cerebral Hemisphere		
Posterior fossa	5	2	1	7	0	0	7	
Supratentorial	0	0	0	0	0	10	0	
Pineal	0	0	0	0	0	0	0	
Suprasellar/hypothalamic	0	0	0	0	19	0	0	
Total	5	2	1	7	19	10	7	

	Craniopharyngioma	Pineal Cell	Germ Cell	Ependymoma	Vascular Lesion	Arachnoid Cyst	Others*	Total
Posterior fossa	0	0	0	2	2	0	0	26
Supratentorial	0	0	0	1	5	7	4	27
Pineal	0	2	1	0	0	0	0	3
Suprasellar/hypothalamic	7	0	4	0	0	0	1	31
Total	7	2	5	3	7	7	5	87

* Others included one each of choroid plexus papilloma, hamartoma, ganglioglioma, primitive neuroectodermal tumor, and Rathke's cleft cyst.

tween the two studies. This was done to avoid test interpretation and memory recollection bias (11). Results of the independent readings were analyzed using the κ statistic to measure the degree of interobserver agreement (12). Subsequently, the two neuroradiologists did a joint interpretation of all discrepant cases. Disagreements were resolved by a third, equally qualified, pediatric neuroradiologist.

Receiver operator characteristic (ROC) curves were obtained using a five-point confidence-rating scale: 1 = definitely not, 2 = probably not, 3 = possible, 4 = probable, and 5 = definite. Test sensitivity and specificity were based on the presence or absence of an intracranial tumor rather than on a determination of the exact histopathology. The questionnaire also included information regarding imaging findings, clinical significance, size of the lesion, differential diagnosis, need for additional MR sequences or neuroimaging examinations (ie, CT or angiography), and technical quality of the study.

The final diagnosis was determined from a combination of clinical, histopathologic, laboratory, and imaging findings. In 92 (65%) of the patients, at least one follow-up examination was performed at the neurology or neurosurgery clinic. The mean follow-up period was 4.2 months (range, 1 week to 2.9 years). In 49 (35%) of the patients, follow-up was performed by the referring physician.

Sensitivity and specificity, with 95% confidence limits (CL), were estimated using standard statistical formulas and were based on the consensus data (13). ROC curve analysis was performed because it provided a description of disease detectability independent of both disease prevalence and decision threshold effects (14). ROC curve analysis was done using the MedCalc statistical package (MedCalc Software, Mariakerke, Belgium). The areas under the ROC curves were compared by using the A_z index with a 95% CL for each protocol (15).

The need for additional MR sequences and neuroimaging studies was compared between the fast and conventional screening MR protocols using Fisher's exact test (16). All P values are two-tailed with an α level of .05 as the criterion for statistical significance.

Results

Findings in the Study Population

The case group included 87 patients (62%) with intracranial tumors (Table 2) whereas the control group had 54 patients (38%) with other CNS disorders (Table 3). Patients in the case group had a total

TABLE 3: Control Group of 54 Patients with Other Disorders

	Diagnosis	
	No.	(%)
Migraine	30	55.5
Other headache disorder	6	11.1
Seizure disorder	4	7.4
Encephalitis	3	5.6
Encephalomalacia	2	3.7
Chiari I	3	5.6
Endocrine disorder	2	3.7
Others*	4	7.4
Total	54	100

* Others included one each of neuronal heterotopia, mitochondrial disorder, pseudotumor cerebri, and sinus mucocele.

of 31 suprasellar/hypothalamic lesions (36%), 27 supratentorial lesions (31%), 26 infratentorial lesions (30%), and three pineal lesions (3%). The mean diameter of the intracranial lesions was 2.7 cm (SD = 1.4 cm; range, 0.5 to 6 cm). Among patients who were referred to exclude a brain tumor and were found to have other disorders (control group), the most common findings were migraine, other headache disorders, seizure disorders, encephalitis, and Chiari I malformation (Table 3). All fast and conventional screening MR protocols were considered of definite or probable diagnostic imaging quality.

Protocol Analysis

The interobserver agreement for brain tumors had a κ statistic of .93 for both the fast and conventional screening protocols. The sensitivity for intracranial tumors was 100% (95% CL = 95.9, 100) for both protocols. The specificity was 92.6% (95% CL = 82.1, 98) and 100% (95% CL = 93.5, 100) for the fast and conventional screening protocols, respectively. Four false-positive studies and no false-negative examinations were identified with the fast screening protocol. The false-positive studies included two questionable

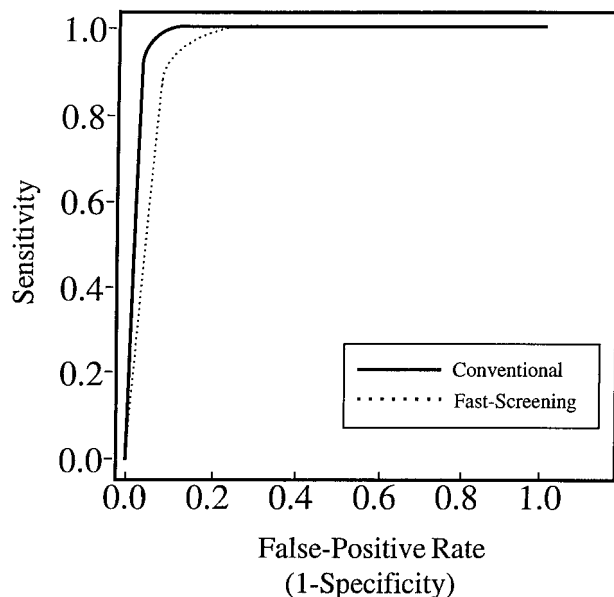


FIG 1. ROC curves for the fast and conventional screening MR protocols.

small arachnoid cysts, which were considered to be normal variants on additional sequences, one probable developmental lesion, which was not documented on additional sequences, and one probable white matter lesion, which was determined to be an artifact on the conventional examination.

Figure 1 shows the ROC curves for the detection of intracranial tumors with each MR protocol. The area under the ROC curve was 0.966 (95% CI = 0.920, 0.989) for the fast screening MR protocol. For the conventional MR protocol, the area under the ROC curve was 0.980 (95% CI = 0.941, 0.996). The A_z index indicated no statistical difference between the two ROC curves ($P = .26$). The statistical power for assessing the equivalence of the fast and conventional screening MR protocols was 90%.

In the control group, no difference was identified between the fast and conventional screening MR protocol in the detection of cortical and white matter lesions among patients with encephalitis ($n = 3$), encephalomalacia ($n = 2$), neuronal heterotopia ($n = 1$), and mitochondrial disorder ($n = 1$). Likewise, both protocols revealed all Chiari I malformations ($n = 3$) and the sinus mucocele ($n = 1$).

Time Analysis

The conventional protocol had an acquisition time of 8 minutes 27 seconds (Table 1) and a total protocol time (patient positioning, study localization, and sequence acquisition) of 17 to 22 minutes. The limited midline-centered sagittal T1-weighted images (only seven sections) could be obtained in 2 minutes 21 seconds by reducing the TR to 300. In a 23-year-old volunteer, midline sagittal T1-weighted images obtained with TRs of 300 and 600 showed no difference in diagnostic quality. Therefore, the fast screening

protocol had an acquisition time of 4 minutes 44 seconds (Table 1) and a total protocol time of 10 to 15 minutes.

Additional MR Sequences and Examinations

A two-tailed Fisher's exact test revealed no statistical difference between the two protocols in terms of requests for additional MR sequences ($P = .61$) or neuroimaging examinations to exclude a brain tumor ($P = .12$). In the presence of an intracranial tumor, however, additional imaging sequences were considered to be useful for better characterization and pre-treatment planning.

Discussion

The 141 children and adolescents in this study had a wide spectrum of diagnoses, histopathologic findings, and anatomic locations of lesions (Tables 2 and 3), as well as tumors as small as 0.5 cm. The sensitivity of the fast screening MR protocol for intracranial tumors was 100% (95% CL = 95.9, 100) and the specificity was 92.6% (95% CL = 82.1, 98.0). The areas under the ROC curves were 0.980 and 0.966 for the conventional and fast screening protocols, respectively. Diagnostic performance (A_z index) was not statistically different ($P = .26$) for the two protocols. Interobserver agreement was excellent, with a κ statistic of .93 for both protocols (17).

The diagnostic performance of the fast screening MR protocol in detecting intracranial tumors may allow its use as a screening examination. Because of the low prevalence of CNS tumors among children and adolescents, most patients would have negative fast screening studies, and thus would not require additional imaging. However, once a positive fast screening MR study were identified, characterization of the abnormality with additional MR sequences or other neuroimaging examinations is usually required to determine whether the patient had a surgical or a nonsurgical intracranial tumor. Since the specificity of the fast screening examination is 92.6% (false positive rate = $1 - \text{specificity}$; ie, $7.4\% = 1 - 92.6\%$) [18], additional MR sequences may be necessary to ascertain the presence of a false-positive study. A proposed decision tree for the work up of patients in whom a brain tumor is suspected is illustrated in Figure 2.

In the event that a space-occupying lesion is identified by either the fast or conventional brain MR protocols, neither study provides all the pertinent information to fully characterize the intracranial lesion. Brain MR studies in children, therefore, should be monitored regardless of the protocol so that sequences such as multiplanar contrast-enhanced T1-weighted examinations can be ordered appropriately. This is especially true in the child who is sedated. Implementation of the fast screening brain MR study should not alter the required close supervision of pediatric brain MR examinations.

In a 4-year retrospective study, brain tumors were

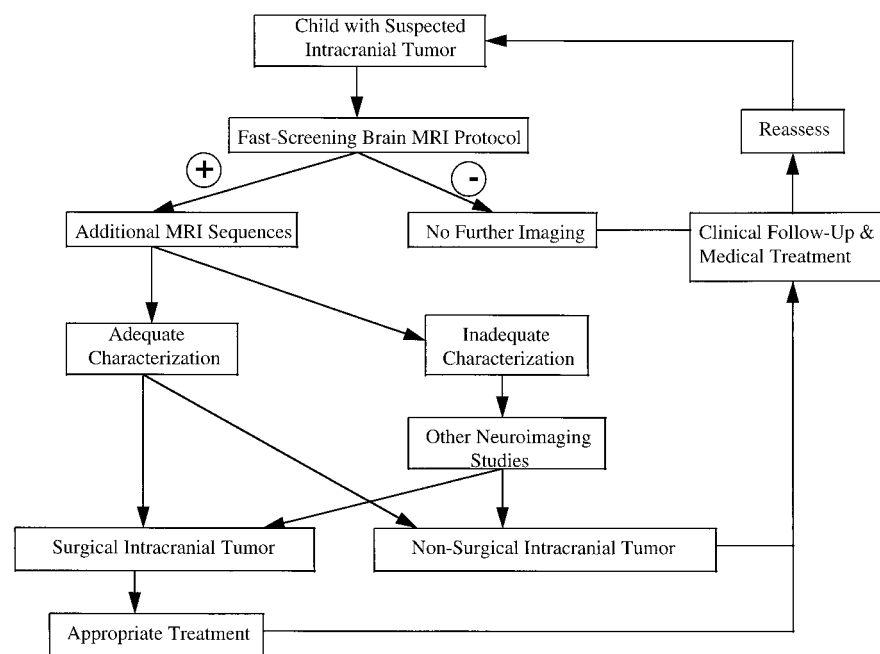


FIG 2. Decision tree for use in children in whom intracranial tumor is suspected. For patients with a negative fast screening MR imaging protocol, no further imaging is recommended; for those with a positive fast screening MR protocol, further characterization with other MR sequences or neuroimaging studies is recommended to determine the presence or absence of a surgical lesion. All patients require clinical follow-up with periodic reassessment.

detected in 28 (9%) of 315 children with headache, but only 13 (4%) required surgical intervention (8). Therefore, more than 90% of children with headache referred for MR imaging to exclude a brain tumor could be studied with the fast screening protocol alone. Implementation of this more time-efficient protocol may increase patient throughput while preserving the diagnostic performance of brain MR imaging.

By design, this case-control study had a population with a high prevalence of brain tumors. Since the sensitivity and specificity are characteristics of a test, they are independent of the prevalence of disease (14, 18). Therefore, we were able to determine the sensitivity and specificity of the brain MR protocols by using a broad case mix of intracranial tumors.

Forty-seven patients in this group were less than 7 years old; 27 (57%) were between 4 and 7 years old. It has been our experience that older children can have a nonsedated brain MR examination if the scanning time is short. With other cross-sectional imaging techniques, such as CT, sedation rates have decreased with the advent of faster scanners. The fast screening MR protocol, therefore, has the potential to decrease the sedation rate.

CT, which is commonly used as a screening study for brain tumor, has its limitations (7). Beam-hardening artifacts degrade posterior fossa images. Midline lesions in the suprasellar, hypothalamic, and pineal areas may be difficult to identify. The fast screening MR protocol detected lesions of various sizes and histopathologic composition in the brain stem, suprasellar, hypothalamic, and pineal regions (Table 2) without the risks of iodinated contrast material (6) or ionizing radiation. Therefore, our preliminary results suggest that a fast screening brain MR study may be a time-efficient brain tumor screening examination.

Additional analytic studies are needed to confirm

the findings described here. Multicenter prospective randomized trials should be performed to compare the different neuroimaging techniques. In addition, decision analysis and cost-effectiveness studies are required to determine optimal neuroimaging strategies in children and adolescents with suspected brain tumors.

Conclusion

Recent changes in health care have emphasized the importance of time-efficient MR protocols that preserve diagnostic performance. Our study suggests that a fast dual-plane MR study may be adequate to screen children and adolescents thought to have a brain neoplasm. The less than 5 minute acquisition time allows a complete examination (including preparation) to be performed in 10 to 15 minutes. Future studies are recommended before this time-efficient neuroimaging examination is incorporated into clinical practice.

References

1. Young JL, Miller RW. **Incidence of malignant tumors in U.S. children.** *J Pediatr* 1975;86:254-258
2. Pollack IF. **Brain tumors in children.** *N Engl J Med* 1994;331:1500-1507
3. The Childhood Brain Tumor Consortium. **The epidemiology of headache among children with brain tumor.** *J Neurooncol* 1991;10:31-46
4. Honig PJ, Charney EB. **Children with brain tumor headaches: distinguishing features.** *Am J Dis Child* 1982;136:121-124
5. Barlow CF. **Headaches migraine in childhood.** *Clin Dev Med* 1984;91:1-216
6. Dunnick NR, Cohan RH. **Cost, corticosteroids, and contrast media.** *AJR Am J Roentgenol* 1994;162:527-529
7. American College of Physicians. **Magnetic resonance imaging of the brain and spine: a revised statement.** *Ann Intern Med* 1994;120:872-875
8. Medina LS, Pinter JD, Zurawski D, et al. **Children with head-**

- ache: clinical predictors of surgical space occupying lesions and the role of neuroimaging. *Radiology* 1997;202:819–824
9. Hennekens CH, Buring JE. *Epidemiology in Medicine*. Boston, Mass: Little, Brown; 1987;132–152
 10. Donner A. Approaches to sample size estimation in the design of clinical trials: a review. *Stat Med* 1984;3:199–214
 11. Begg CB, McNeil BJ. Assessment of radiologic tests: control of bias and other design considerations. *Radiology* 1988;167:565–569
 12. Agresti A. *Categorical Data Analysis*. New York, NY: Wiley; 1990; 366–370
 13. Byth CR. Approximate binomial confidence limits. *J Am Stat Assoc* 1986;81:843–855
 14. Metz CE. Basic principles of ROC analysis. *Semin Nucl Med* 1978;7:283–298
 15. Metz CE. ROC methodology in radiologic imaging. *Invest Radiol* 1986;21:720–733
 16. Everitt B. *The Analysis of Contingency Tables*. London, England: Chapman and Hall; 1992:14–18
 17. Rosner B. *Fundamentals of Biostatistics*. New York, NY: Duxbury Press; 1995:426
 18. Weinstein MC, Fineberg HV. *Clinical Decision Analysis*. Philadelphia, Pa: Saunders; 1980:75–130