

# Transvenous Embolization as the Primary Therapy for Arteriovenous Fistulas of the Lateral and Sigmoid Sinuses

Robert C. Dawson, III, Gregory J. Joseph, David S. Owens, and Daniel L. Barrow

**PURPOSE:** We report on the evolution in one institution from transarterial embolization for the treatment of dural arteriovenous fistulas of the lateral and sigmoid sinuses to the safer and more durable technique of transvenous endovascular therapy for the majority of these lesions.

**METHODS:** Arterial, venous, and combined embolizations were performed for 24 fistulas of the lateral and sigmoid sinuses between August 1991 and December 1996. The patients were followed up clinically for 2 to 63 months, with a mean follow-up period of 30 months.

**RESULTS:** Nine patients had arterial embolization without transvenous treatment: five of the nine had angiographic and clinical obliteration of their fistulas; two of the nine, with unusual lesions, required surgery; and the remaining two had recurrences and were not retreated. Seven patients had both arterial embolization and coil embolization (packing) of the dural sinuses, four after arterial embolization had failed to cure the lesions; in all seven, the fistulas were obliterated angiographically and clinically. Eight patients had only transvenous coil embolization of the dural sinuses; all eight were cured. One patient had minimal arterial embolization during the primary venous embolization procedure. Complications occurred in two patients, both related to arterial embolization with ethanol.

**CONCLUSION:** Our experience suggests that arterial embolization of dural arteriovenous fistulas of the lateral and sigmoid sinuses is associated with a low cure rate and high rate of recurrence, whereas transvenous endovascular packing of the involved segment of the sinus results in a high cure rate that obviates arterial embolization or surgical excision in most cases.

The traditional treatment of arteriovenous fistulas of the transverse and sigmoid sinuses is surgical excision of the involved portion of the dura, sinus, and tentorial edge to completely devascularize the malformation (1). More recently, endovascular techniques, including transarterial and transvenous embolization, have been developed to treat these lesions completely or palliatively, either alone or in conjunction with surgery (1-15). Because most arteriovenous fistulas of the lateral sinus are associated with a benign natural history, treatment must be associated with low morbidity to justify any therapeutic intervention. Advances in the field of endovascular therapy

have provided therapeutic alternatives to surgery that are effective and safe.

We report on the treatment of 24 patients with arteriovenous fistulas of the lateral and sigmoid sinuses managed at our institution since the formation of a dedicated cerebrovascular team. The primary purpose of this report is to emphasize the evolution of treatment at our institution from transarterial embolization, with or without surgery, to transvenous endovascular obliteration of the involved segment of the sinus. The latter has become the preferred method of treatment.

## Methods

Between August 1991 and December 1996, 24 patients with dural arteriovenous fistulas of the lateral and sigmoid sinuses were treated at our institution by transarterial and/or transvenous embolization procedures and/or surgical excision. The subjects included 15 women and nine men. The women ranged in age from 40 to 80 years, with an average age of 57; men ranged in age from 32 to 71 years, with an average age of 51. Symptoms included hemorrhage (n = 1), dementia (n = 2), abducens nerve palsy (n = 1), subjective bruit (n = 23), headache (n = 7), and vertigo (n = 1). Among the patients with bruit, 19 described it as life-altering or disabling. Two patients had a history of remote, severe head trauma.

---

Received December 19, 1996; accepted after revision August 23, 1997.

Presented in part at the annual meeting of the American Society of Neuroradiology, Chicago, Ill, April 1995.

From the Departments of Radiology (R.C.D., G.J.J., D.S.O) and Neurological Surgery (D.L.B.), Emory University School of Medicine, Atlanta, Ga.

Address reprint requests to Robert C. Dawson, III, MD, Department of Radiology, Emory University School of Medicine, 1364 Clifton Rd, NE, Atlanta, GA 30322.

Using the classification of Lalwani et al (16), we identified seven patients who had type I lesions with normal antegrade venous drainage without venous restriction or cortical venous drainage. Twelve patients had type II lesions with antegrade venous drainage and retrograde flow in the sinus to the torcular Herophili with or without cortical venous drainage; four patients had type III lesions with retrograde and cortical venous drainage; and one patient had a type IV lesion with cortical venous drainage only.

All patients were initially managed by endovascular techniques and only two required subsequent surgical treatment. All embolizations were performed using real-time digital subtraction fluoroscopic roadmapping. Microcatheters were generally used, although occasionally stainless steel coils (Gianturco) were delivered via 5F catheters with a 0.038-inch internal diameter via a transvenous route. Procedures on some elderly or uncooperative patients were performed under general anesthesia, but most patients had local anesthesia and intravenous sedation while monitored by a member of the anesthesiology staff.

All patients were observed in a dedicated neurosurgical intensive care unit overnight, and discharged 24 to 36 hours after embolization. Clinical examinations were performed on an outpatient basis 3 to 6 weeks after discharge. In addition, all patients were examined on a long-term follow-up basis and interviewed by telephone to confirm unchanged clinical status. Angiographic follow-up was obtained in all 15 patients who underwent transvenous embolization with or without transarterial embolization. The time range was 1 to 42 months, with a mean angiographic follow-up time of 7.5 months for this subgroup of patients.

The initial endovascular treatment included transarterial embolization alone (n = 9), a combination of transarterial and transvenous embolization (n = 7), and transvenous embolization alone (n = 8). Arterial embolizations were performed with polyvinyl alcohol (PVA), cyanoacrylate, coils, 95% ethanol, or combinations of these agents. Transvenous embolization was accomplished by packing the lesions with platinum and stainless steel coils. Initially, transvenous embolizations were performed in cases in which transarterial occlusion was incomplete; eventually, they were the primary method of closure without transarterial embolization.

All but three embolization procedures were performed from transfemoral arterial or venous approaches. Two transjugular approaches were used in patients in whom anatomic considerations precluded a transfemoral venous route. In one patient, the internal jugular vein had been surgically interrupted; in the other, there was apparent thrombosis of a portion of the left internal jugular vein with tortuous collaterals. In a third patient, for whom a transjugular approach was anticipated, cervical irradiation in childhood had resulted in fibrotic occlusion of the internal jugular vein. This anatomic condition, in conjunction with an occluded transverse sinus, eventually necessitated a surgical approach to cure the fistula after treatment by arterial embolization proved incomplete.

## Results

The results of transvenous embolization therapy in our 24 patients with dural arteriovenous fistulas of the lateral and sigmoid sinuses are summarized in the Table. Typical arteriograms are illustrated in Figures 1 and 2.

### *Transarterial Embolization Alone*

Nine patients underwent arterial embolization of the supplying arteries alone. Five (55.5%) of these nine were cured angiographically and clinically. In two patients, the condition persisted or recurred; both

reported initial improvement in their subjective bruit and refused further therapy. One of these patients died of unrelated causes less than a year after treatment. Two patients remained sufficiently symptomatic as to require surgery. One patient, who presented with severe dementia, had an extremely aggressive fistula with bilateral internal and external carotid artery supply and cortical venous drainage. Four transarterial embolizations with cyanoacrylate, PVA, coils, and 95% ethanol failed to completely obliterate the fistula. The patient's transverse sinus was surgically skeletonized and excised along with the tentorial edge, resulting in obliteration of the fistula and improvement in the dementia. Another patient, who presented with proptosis and an abducens nerve palsy, had an isolated fistula in the short segment of the sigmoid sinus. Drainage was directed retrogradely through the inferior petrosal sinus, the cavernous sinus, and into the cortical veins. Prior cervical irradiation had resulted in isolation of this segment of the sinus due to fibrosis of the internal jugular vein, a situation that precluded transvenous catheterization and necessitated surgery to access the affected sinus. A craniotomy was created above and below the involved segment of sinus. The sinus was skeletonized, and intraoperative carotid angiography failed to show any fistula as did follow-up angiography 2 months later. The proptosis and abducens nerve palsy resolved.

Of the five patients cured by transarterial embolization, two required two embolizations and three had one embolization. None of these patients had fistulas associated with cortical venous drainage. In one, a small amount of 95% alcohol (1 mL) was used as an additive embolic agent. The remaining four patients were embolized with PVA alone.

### *Transarterial and Transvenous Embolization*

Seven patients had both arterial embolization and transvenous coil packing of the involved sinus. Four had transvenous embolizations after arterial embolizations failed to cure the lesions. Three had minimal arterial embolizations after transvenous packing left a minimal residual fistula on the immediate postprocedural arteriogram. All seven of these patients had complete angiographic and symptomatic resolution. None had recurrence on clinical or angiographic follow-up.

### *Transvenous Embolization Alone*

Eight patients had only transvenous coil packing of the affected sinus. All eight had documented angiographic obliteration of the fistula and resolution of symptoms. None had recurrence on clinical or angiographic follow-up studies.

### *Complications*

Two patients had complications, both resulting from transarterial embolization. One patient had a

## Transvenous Embolization Therapy for Dural Arteriovenous Fistulas of the Lateral and Sigmoid Sinuses

Patient	Signs/Symptoms	Cortical Venous Drainage	Therapy	Outcome	Complications/Comments	Follow-up, mo
1	Bruit		Transarterial and transvenous embolizations	Cure	None	35
2	Bruit		Two transarterial embolizations twice	Cure	None	39
3	Dementia, white matter changes on MR	+	Four transarterial embolizations (PVA, coils, glue) and surgical excision	Clinical cure	Much improvement, independent life, improved dementia	53
4	Bruit		Transarterial embolization (PVA)	Not cured	Recurrent symptoms in 6 weeks (mild), death unrelated to procedure	12
5	Bruit, dementia	+	Transarterial embolization (PVA)	Cure	Cranial nerve VII palsy, resolved in 6 months	36
6	Bruit		Transarterial embolization	Cure	None	23
7	Headaches, bruit, history of auto accident		Transarterial and transvenous embolizations	Cure	None	63
8	Bruit	+	Transarterial and transvenous embolizations	Cure	Cranial nerves IX, X, XI, XII palsies; significant improvement but permanent impairment of left shoulder; swallowing difficulties; decreased voice and strength	30
9	Bruit		Transarterial embolization	Cure	None	30
10	Bruit		Transarterial and transvenous embolizations	Cure	None	43
11	Bruit, intracranial hemorrhage	+	Transarterial embolization	Cure	Unable to work, but independent	28
12	Pulsatile bruit		Transvenous and transarterial embolizations	Cure	Coincident fibromuscular dysplasia	37
13	Bruit, headache		Transvenous and transarterial embolizations	Cure	None	28
14	Bruit		Transvenous embolization	Cure	None	39
15	Bruit, traumatic headaches		Transvenous and minimal transarterial embolizations	Cure	None	24
16	Bruit		Transarterial embolization	Not cured, not retreated	Decreased bruit	33
17	Bruit		Transarterial embolization	Cure	None	52
18	Bruit		Transvenous embolization	Cure	Required surgery	19
19	Palsy of cranial nerve VI, exophthalmus		Transarterial embolization and surgery	Cure	None	20
20	Bruit	+	Transvenous embolization	Cure	None	18
21	Bruit, vertigo		Transvenous embolization	Cure	None	18
22	Bruit		Transvenous embolization	Cure	None	16
23	Bruit		Transvenous and minimal transarterial embolizations	Cure	None	16
24	Bruit		Transvenous embolization	Cure	None	2

left-sided facial nerve palsy, which developed after injection of 0.2 mL of 95% ethanol in the left middle meningeal artery well above the foramen spinosum. The palsy resolved in 6 months. A second patient had had a near total obliteration of a fistula by transvenous coil embolization. However, a small isolated segment was noted to drain via the vein of Labbé. Transarterial embolization was performed owing to concern for potential venous infarction and hemorrhage. Injection of 0.1 mL of ethanol into the posterior division of the ascending pharyngeal artery, (following negative lidocaine provocation), resulted in palsies of the right ninth, 10th, 11th, and 12th cranial

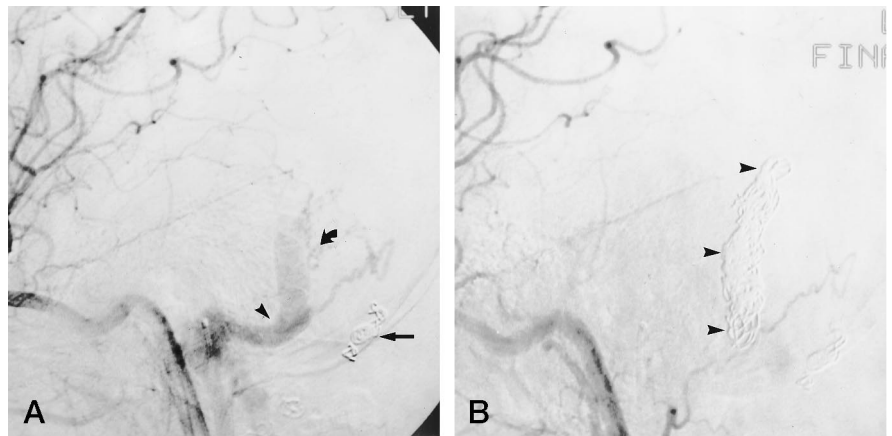
nerves. Follow-up at 2-1/2 years showed improvement but persistent mild palsies. In neither of these cases was the ethanol opacified.

### Discussion

Intracranial dural arteriovenous fistulas (malformations) are uncommon lesions, constituting only 10% to 15% of all intracranial arteriovenous malformations (17). A substantial but undetermined fraction of these lesions involve the lateral and sigmoid sinuses. Patients usually present with subjective bruit, although other symptoms and signs, including head-

FIG 1. A, Left common carotid arteriogram, lateral projection, 1 week after arterial embolization of left occipital artery with PVA and platinum microcoils (*straight arrow*). Sigmoid sinus (*arrowhead*) continues to fill early via transmastoid branch of the occipital artery, which, owing to proximal occlusion of the occipital artery, has been recruited by the ascending pharyngeal artery (*curved arrow*).

B, Left common carotid arteriogram, lateral projection, after embolization of sigmoid sinus by tightly packing it with platinum microcoils (*arrowheads*); the sinus no longer shows any opacification.



ache, dementia, cranial neuropathies, proptosis, vertigo, and intracranial hemorrhage, may coexist or be predominant (2, 3, 5–9, 11, 12, 14, 15, 17–24). While it is generally agreed that the lesions are abnormal arteriovenous communications in the dural reflections of the sinus, there is no widespread agreement as to the event triggering the condition. Houser et al (10) proposed that partial recanalization of a thrombosed sinus results in the development of a small fistula that leads in some way to the recruitment of multiple dysplastic vessels into the sinus wall. Intimal thickening then further narrows the sinus lumen, in theory resulting in increased venous pressure and a continuous cycle of increasing stricture leading to more fistulas. Nishijima et al (25) confirmed that the sinus wall is the site of the fistulas, but only one of their three pathologic specimens showed evidence of thrombus within the affected sinus. None of the three specimens showed a direct shunt from artery to sinus lumen, but rather to veins within the wall, and secondarily into the sinus lumen. An arteriovenous fistula occurring after intracranial surgery has also been described (14).

There is nearly uniform agreement that cortical venous drainage portends a poor clinical course. Several classification schemes have been proposed, their common theme relating to the aggressive nature of lesions with cortical venous drainage (16, 20, 26). The degree of venous restriction strongly predicts which lesions are accompanied by either intracranial hemorrhage or a nonhemorrhagic neurologic deficit (27). The authors of all classification protocols advocate early and aggressive therapy for lesions with reversal of flow in the cortical vein. While the presence of cortical venous flow reversal may be predictive of a high rate of venous infarction and hemorrhage, additional related symptoms of bruit, vertigo, dementia, myelopathy, or cranial neuropathy may also be life-altering, if not life-threatening. Such patients may also deserve, require, or demand treatment. Until recently, surgery has been the lone practical treatment for lateral sinus fistulas (28). Sundt and Piepgras (1) described in detail their experience with 27 patients. Despite their meticulous surgical technique, they reported two deaths resulting from the operation and two hemorrhagic venous infarctions.

Chandler and Friedman (29) reported successful radiosurgical treatment of a frontal dural arteriovenous malformation, but to our knowledge there is no documentation of a series of patients with arteriovenous fistulas being cured by radiosurgery. While this technique may hold promise as a treatment for some of these lesions, the long latency period required for radiation effects to occur negatively impacts its utility.

A considerable body of literature has been amassed detailing arterial and venous embolization techniques, primarily as adjuncts to surgical resection, but also as curative therapy for these lesions. Mullan and Johnson (13) were early proponents of venous-sided treatment of dural arteriovenous malformations, and advocated them as a safe and effective alternative to transarterial or surgical techniques. Barnwell et al (19) described seven patients with arteriovenous fistulas in the sinus wall but with patent sinuses and drainage entirely via cortical veins. We have not seen this variant, but such a condition might not lend itself to transvenous embolization. Halbach et al (8) reported their experience with 23 patients. Of the six who had a combination of arterial embolization and surgery, four were cured and two improved; the other 17 patients had arterial embolizations with a variety of embolic agents, primarily cyanoacrylate, and 10 (59%) of these patients were cured. In another series from the same institution, Halbach et al (9) described their limited experience with transvenous embolization, chiefly as an adjunct to surgery. Seven patients had preoperative arterial embolization followed by craniotomy and direct packing of the sinus with wire coils or embolization by direct cyanoacrylate injection. Four (57%) of these patients were completely cured and three had marked reduction in their shunts. Four additional patients had transfemoral venous coil embolization without arterial embolization, but only one (25%) of them was cured. The authors reported two transient complications. While they mention transvenous embolization as part of their larger series, they do not recommend this method of embolization, owing to their poor cure rate (25%) in the four patients treated by venous embolization alone.

A recent article by Urtasun et al (15) describes their experience with transvenous embolization of 20

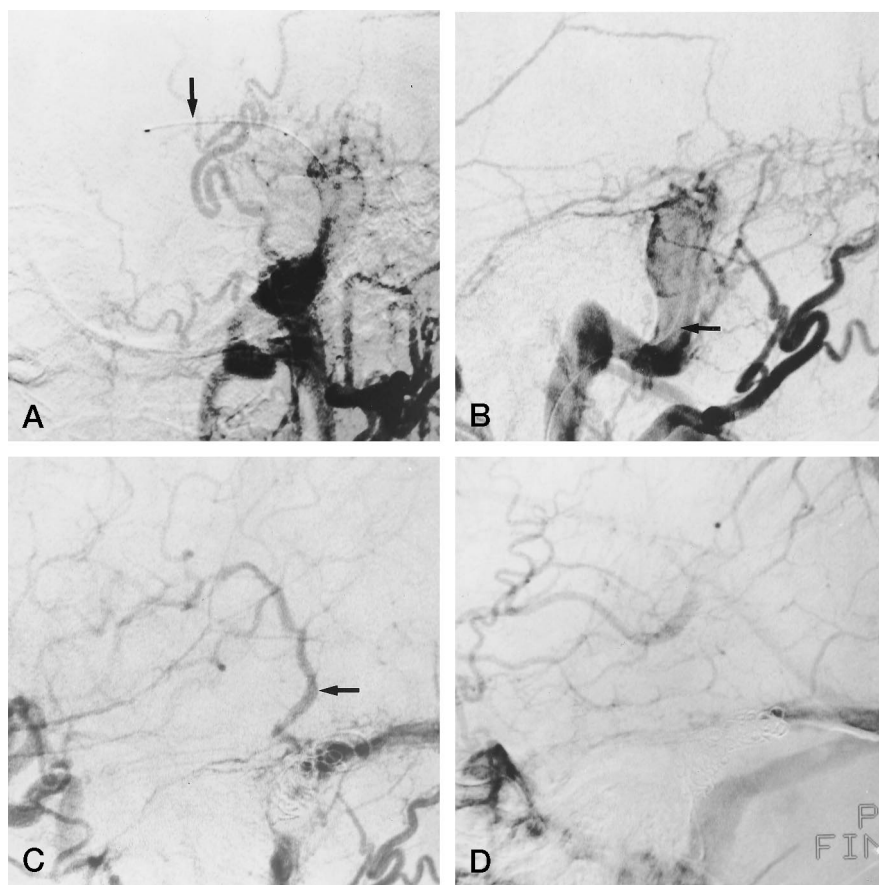


FIG 2. Left external carotid arteriograms in anteroposterior (A) and lateral (B) projections show typical fistula with multiple dural arteries shunting into the sigmoid sinus with antegrade flow only. Note transvenous catheter in place in the sigmoid sinus (arrow).

C, Left common carotid arteriogram, lateral projection. As transvenous packing of the sinus progresses, antegrade flow into the sinus is decreased, but retrograde flow develops into a cortical vein (arrow). This situation requires further packing to prevent potential venous infarction.

D, Left common carotid arteriogram, lateral projection, late venous phase, after embolization of the occipital artery and further coil packing of the affected sinus. Note complete ablation of the fistula.

dural arteriovenous fistulas of the lateral and sigmoid sinus. Sixteen (80%) of 20 patients treated transvenously were cured angiographically. However, 16 (80%) of the 20 patients underwent a total of 29 arterial side embolizations in addition to transvenous therapy. Only four (20%) were treated by venous embolization alone, and all were cured.

Early in our series, most patients underwent partial transarterial embolizations followed by surgical excision of the fistulous dural segment. As with many other arteriovenous malformations, transarterial embolization alone resulted in a high rate of recurrence owing to recruitment of a new arterial supply to the fistula and recanalization of embolized arterial segments. In this group of transarterial failures, transvenous embolization was found to effectively supplement the less effective therapy. Two additional patients underwent initial partial transvenous embolization with only minimal transarterial embolization required to obliterate the fistula entirely. Finally, we used transvenous embolization treatment exclusively, employing arteriography only to help us visualize the fistulas intraprocedurally while packing the sinus from the most distal portion of the involved segment to the most proximal. It became apparent that tight transvenous packing resulted in complete obliteration of the fistula without transarterial therapy.

In only one patient in whom transvenous sinus packing was performed with antegrade flow in the vein of Labbé observed, and this segment of sinus was not

packed. Transvenous sinus packing was performed safely in patients in whom the vein was either not visible or showed only retrograde flow. In these patients, it is presumed that cerebral venous collateralization allows adequate drainage for the territory of this or other cortical veins. Angiograms in the late venous phase must be diligently scrutinized for evidence of either normal functioning of the involved sinus or for significant use of the sinus by cortical veins for primary drainage. Often, anastomosis with the vein of Trolard or the middle cerebral vein will be apparent, allowing satisfactory alternative drainage pathways.

It is not known whether further occlusion of venous outflow tracts by coil packing will result in the formation of other intracranial fistulas, so patients must be followed up both clinically and angiographically. Although development of lateral sinus fistulas has been reported with both traumatic and surgical interruption of a normally functioning sinus, we are not aware of patients in whom an additional fistula has arisen after either surgical or endovascular therapy, and this must be presumed to be an uncommon occurrence (14).

Of the 15 patients who had technically successful dense packing of the affected sinuses throughout the entire length of the abnormality, all had symptomatic and angiographic obliteration of their fistula. Four of the 15 required transvenous therapy to achieve a cure after failure of primary arterial embolization. The

three who had arterial embolization in conjunction with primary transvenous packing probably would not have required arterial embolization had the coil pack been tighter or had angiographic follow-up been delayed. Importantly, none of our transvenous procedures resulted in any morbidity or mortality.

The described treatment for these lesions requires attention to changes in the venous outflow that occur during therapy. As evidenced in Figure 2, obstructing outflow during treatment can redirect venous flow. Thus, partial or inadequate treatment might convert a more benign lesion into one with potential for hemorrhagic or ischemic complications.

The two complications in this series serve to emphasize the safety benefit of transvenous therapy. Both occurred with transarterial use of nonopacified ethanol. In the patient in whom a negative provocative challenge with lidocaine was obtained, it is likely that reflux occurred quickly during the embolization, negating the meaning of the test. These patients were treated early in our series, and this agent is no longer used for this application.

### Conclusion

On the basis of our experience, we established the current protocol in which dural arteriovenous fistulas of the lateral and sigmoid sinuses are treated, when possible, solely by transvenous embolization. This practice is used in any patient with cortical venous drainage or whose life is impaired by associated symptoms. Surgical excision or surgical access for transvenous packing is reserved for those unusual lesions that we are unable to treat completely by transvenous embolization or for instances in which anatomic peculiarities preclude endovascular venous access to the fistula. Transarterial embolization is reserved as an adjunct to transvenous embolization. The shortcomings of our study include a relatively small patient population, the continuing evolution of technology and techniques, a somewhat limited patient follow-up, and absence of cohort control subjects. Nonetheless, we believe that transfemoral, transvenous embolization is a safe and efficacious method for treating dural arteriovenous malformations of the lateral and sigmoid sinuses when the involved sinus is endovascularly accessible.

### References

1. Sundt TM, Piepgras DG. **The surgical approach to arteriovenous malformations of the lateral and sigmoid dural sinuses.** *J Neurosurg* 1983;59:32-39
2. Awad IA, Little JR, Akrawi WP, Ahl J. **Intracranial dural arteriovenous malformations: factors predisposing to an aggressive neurological course.** *J Neurosurg* 1990;72:839-850
3. Barnwell SL, Halbach VV, Higashida RT, Hieshima G, Wilson CB. **Complex dural arteriovenous fistulas: results of combined endovascular and neurosurgical treatment in 16 patients.** *J Neurosurg* 1989;71:352-358
4. Brown RD, Wiebers DO, Nichols DA. **Intracranial dural arteriovenous fistulae: angiographic predictors of intracranial hemorrhage and clinical outcome in nonsurgical patients.** *J Neurosurg* 1994;81:531-538
5. Ferman M, Reizine D, Melki JP, Riche MC, Merland JJ. **Long term follow-up of 43 pure dural arteriovenous fistulae (AVF) of the lateral sinus.** *Neuroradiology* 1987;29:348-353
6. Gelwan MJ, Choi IS, Berenstein A, Pile-Spellman JMD, Kuper-Smith MJ. **Dural arteriovenous malformations and papilledema.** *Neurosurgery* 1988;22:1079-1084
7. Gobin YP, Houdart E, Rogopoulos A, Casasco A, Bailly AL, Merland JJ. **Percutaneous transvenous embolization through the thrombosed sinus in transverse sinus dural fistula.** *AJNR Am J Neuroradiol* 1993;14:1102-1105
8. Halbach VV, Higashida RT, Hieshima GB, Goto K, Norman D, Newton TH. **Dural fistulas involving the transverse and sigmoid sinuses: results of treatment in 28 patients.** *Radiology* 1987;163:443-447
9. Halbach VV, Higashida RT, Hieshima GB, Mehringer CM, Hardin CW. **Transvenous embolization of dural fistulas involving the transverse and sigmoid sinuses.** *AJNR Am J Neuroradiol* 1989;10:385-392
10. Houser OW, Campbell JK, Campbell RJ, Sundt TM. **Arteriovenous malformation affecting the transverse dural venous sinus: an acquired lesion.** *Mayo Clin Proc* 1979;54:651-661
11. Ishi K, Goto K, Ihara K, et al. **High-risk dural arteriovenous fistulae of the transverse and sigmoid sinuses.** *AJNR Am J Neuroradiol* 1987;8:1113-1120
12. Kosnik EJ, Hunt WE, Miller CA. **Dural arteriovenous malformations.** *J Neurosurg* 1974;40:322-329
13. Mullan S, Johnson DL. **Combined sagittal and lateral sinus dural fistulae occlusion.** *J Neurosurg* 1995;82:159-165
14. Watanabe A, Takahara Y, Ibuchi Y, Mizukami K. **Two cases of dural arteriovenous malformation occurring after intracranial surgery.** *Neuroradiology* 1984;26:375-380
15. Urtasun F, Biondi A, Casasco A, et al. **Cerebral dural arteriovenous fistulas: percutaneous transvenous embolization.** *Radiology* 1996;199:209-217
16. Lalwani AK, Dowd CF, Halbach VV. **Grading venous restrictive disease in patients with dural arteriovenous fistulas of the transverse/sigmoid sinus.** *J Neurosurg* 1993;79:11-15
17. Newton TH, Cronquist S. **Involvement of dural arteries in intracranial arteriovenous malformations.** *Radiology* 1969;93:316-320
18. Aminoff MJ. **Vascular anomalies in the intracranial dura mater.** *Brain* 1973;96:601-612
19. Barnwell SL, Halbach VV, Dowd CF, Higashida RT, Hieshima GB, Wilson CB. **A variant of arteriovenous fistulas within the wall of dural sinuses: results of combined surgical and endovascular therapy.** *J Neurosurg* 1991;74:199-204
20. Cognard C, Gobin YP, Pierot L, et al. **Cerebral dural arteriovenous fistulas: clinical and diagnostic correlation with a revised classification of venous drainage.** *Radiology* 1995;194:671-680
21. De Marco JK, Dillon WP, Halbach VV, Tsuruda JS. **Dural arteriovenous fistulas; evaluation with MR imaging.** *Radiology* 1990;175:193-199
22. Lasjaunias P, Chiu M, TerBrugge K, Tolia A, Hurth M, Berenstein M. **Neurological manifestations of intracranial dural arteriovenous malformations.** *J Neurosurg* 1986;64:724-730
23. Newton TH, Greitz T. **Arteriovenous communication between the occipital artery and transverse sinus.** *Radiology* 1966;87:824-828
24. Obrador S, Soto M, Silvela J. **Clinical syndromes of arteriovenous malformations of the transverse: sigmoid sinus.** *J Neurol Neurosurg Psychiatry* 1975;38:436-451
25. Nishijima M, Takaku A, Endo S, et al. **Etiological evaluation of dural arteriovenous malformations of the lateral and sigmoid sinuses based on histopathological examinations.** *J Neurosurg* 1992;76:600-606
26. Borden JA, Wu JK, Shucart WA. **A proposed classification for spinal and cranial dural arteriovenous fistulous malformations and implications for treatment.** *J Neurosurg* 1995;82:166-179
27. Davies MA, TerBrugge K, Willinsky R, Coyne T, Saleh J, Wallace MC. **The validity of classification for the clinical presentation of intracranial dural arteriovenous fistulas.** *J Neurosurg* 1996;85:830-837
28. Thompson BG, Doppman JL, Oldfield EH. **Treatment of cranial dural arteriovenous fistulae by interruption of leptomeningeal venous drainage.** *J Neurosurg* 1994;80:617-623
29. Chandler HC, Friedman WA. **Successful radiosurgical treatment of dural arteriovenous fistula: case report.** *Neurosurgery* 1993;33:139-142